

Genetic Mapping to 10q23.3-q24.2, in a Large Italian Pedigree, of a New Syndrome Showing Bilateral Cataracts, Gastroesophageal Reflux, and Spastic Paraparesis with Amyotrophy

Marco Seri,¹ Roberto Cusano,¹ Paola Forabosco,¹ Roberta Cinti,¹ Francesco Caroli,¹ Paolo Picco,² Rita Bini,⁴ Vincenzo Brescia Morra,⁵ Giuseppe De Michele,⁵ Margherita Lerone,¹ Margherita Silengo,⁶ Ivana Pela,⁴ Carla Borrone,² Giovanni Romeo,⁷ and Marcella Devoto³

¹Laboratorio Genetica Molecolare and ²II Divisione Pediatrica, Istituto G. Gaslini, Genoa; ³Dipartimento di Oncologia, Biologia e Genetica, Università di Genova, Genoa, Italy; ⁴Università di Firenze, Ospedale Pediatrico Meyer, Florence, Italy; ⁵Dipartimento di Scienze Neurologiche, Università Federico II di Napoli, Naples, Italy; ⁶Istituto di Discipline Pediatriche, Università di Torino, Turin, Italy; and ⁷IARC, Lyon, France

Summary

We have recently observed a large pedigree with a new rare autosomal dominant spastic paraparesis. In three subsequent generations, 13 affected individuals presented with bilateral cataracts, gastroesophageal reflux with persistent vomiting, and spastic paraparesis with amyotrophy. Bilateral cataracts occurred in all affected individuals, with the exception of one patient who presented with a chorioretinal dystrophy, whereas clinical signs of spastic paraparesis showed a variable expressivity. Using a genomewide mapping approach, we mapped the disorder to the long arm of chromosome 10 on band q23.3-q24.2, in a 12-cM chromosomal region where additional neurologic disorders have been localized. The spectrum of phenotypic manifestations in this family is reminiscent of a smaller pedigree, reported recently, confirming the possibility of a new syndrome. Finally, the anticipation of symptoms suggests that an unstable trinucleotide repeat may be responsible for the condition.

Introduction

An interesting pedigree showing a genetic disorder inherited in an autosomal dominant fashion, and probably representing a rare syndrome, has recently been observed. The affected members of this large, three-generation family (fig. 1) show bilateral cataracts, gastro-

esophageal reflux with persistent vomiting, and spastic paraparesis with amyotrophy.

Congenital cataracts account for 10%–30% of blindness in children, and the phenotype is clinically heterogeneous. Although X-linked and autosomal recessive transmission of hereditary cataracts have been observed, the most frequent mode of inheritance is autosomal dominant (Merin 1991). In addition, cases of congenital cataracts may have a genetic cause, either as part of a systemic disease or as a nonsyndromic Mendelian trait.

Eleven distinct dominant loci of congenital cataracts have been mapped so far (Hejtmancik 1998): the Volkman “zonular progressive” cataract (MIM 115665; Eiberg et al. 1995) and a “posterior polar” cataract (MIM 116600; Ionides et al. 1997) to 1p; the Coppock type “zonular pulverulent” cataract (MIM 116200; Renwick and Lawler 1963) to the chromosomal region 1q21-q25; the Coppock-like “nuclear pulverulent” cataract (MIM 123660; Brakenhoff et al. 1994) to 2q33-q36; and two different forms, the Marner zonular progressive cataract (MIM 116800; Eiberg et al. 1988) and the posterior polar cataract (Maumenee 1979), to 16q22.1. Two additional types, the “cerulean” (MIM 115660; Armitage et al. 1995) and the “zonular sutural” cataract (MIM 600881; Padma et al. 1995), have been mapped to the long arm of chromosome 17 in the q24 and q11-12 regions, respectively. A second locus for the cerulean type has been mapped to 22q (MIM 601547; Kramer et al. 1996). Recently, a locus for the “anterior polar” cataract has been localized to 17p (MIM 601202; Berry et al. 1996), whereas a second locus for the zonular pulverulent cataract has been mapped to 13q (MIM 601885; Mackay et al. 1997).

Spastic paraplegia is also a genetically heterogeneous disease. Indeed, autosomal dominant, autosomal recessive, and X-linked recessive varieties of spastic paraplegia have been recognized, and >1 recessive or dominant forms exist. The majority of the reported families

Received July 6, 1998; accepted for publication December 17, 1998; electronically published February 2, 1999.

Address for correspondence and reprints: Dr. Marco Seri, Laboratorio di Genetica Molecolare, Istituto G. Gaslini, Largo G. Gaslini n. 5, 16148 Genova Quarto, Italy. E-mail: genseq@tin.it

© 1999 by The American Society of Human Genetics. All rights reserved. 0002-9297/99/6402-0030\$02.00

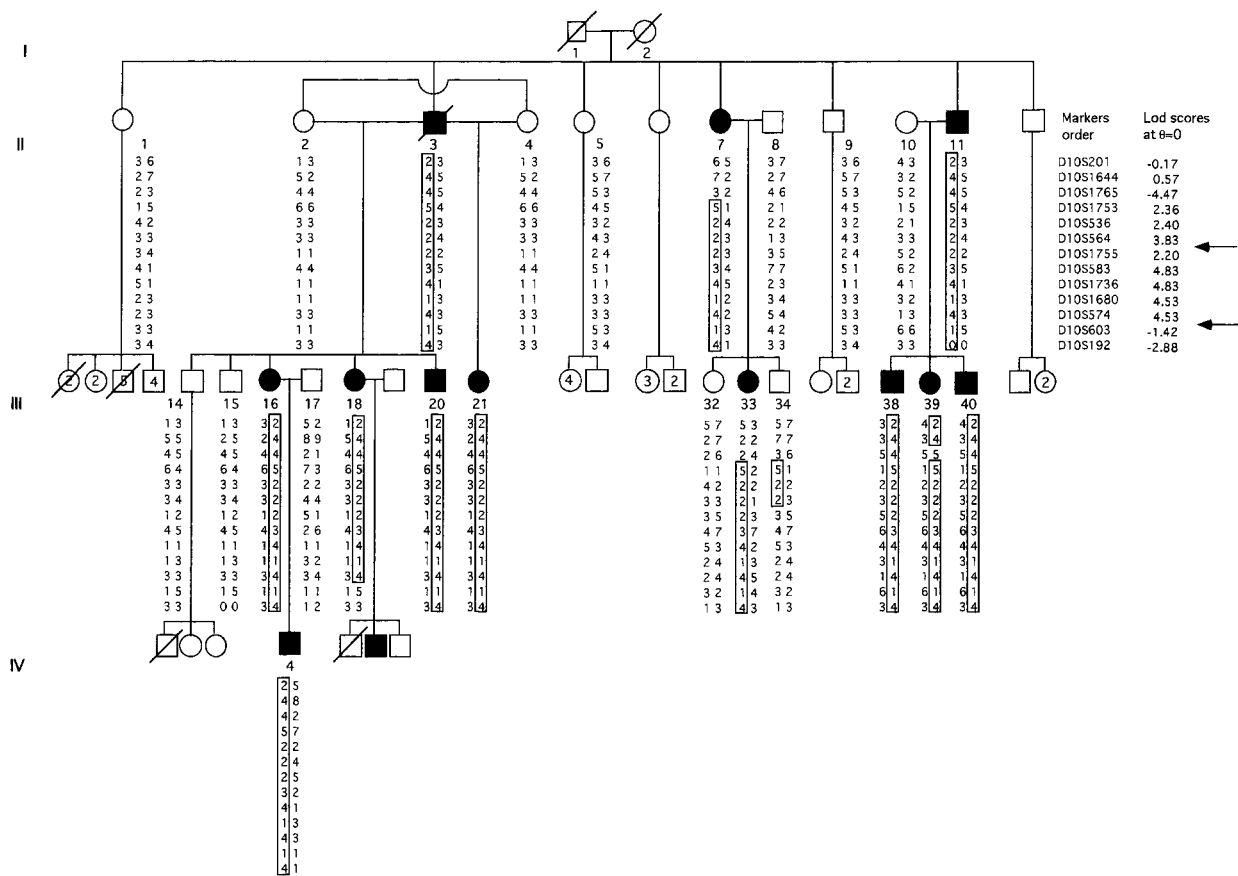


Figure 1 The pedigree of the family with haplotype reconstruction for informative markers on 10q23.3-q24.2. The “at-risk” haplotype is boxed. Arrows indicate the boundaries of the critical interval identified. The LOD score values at $\theta = 0$ for the different markers are reported.

(70%–80%) display autosomal dominant inheritance, with autosomal recessive inheritance being responsible for most of the remaining cases (Reid 1997).

Three autosomal dominant and two recessive forms of pure spastic paraplegia have already been mapped to the chromosomal regions 2p24-p21 (MIM 182601), 14q12-q21 (MIM 182600), 15q11.2-q12 (MIM 600363), 8p11-q13 (MIM 270800), and 16q24.3 (MIM 602783) (Hazan et al. 1993, 1994; Hentati et al. 1994a, 1994b; Fink et al. 1995; De Michele et al. 1998). Spastic paraplegia can be complicated by the presence of additional neurologic or nonneurologic features. In particular, optic nerve involvement, pigmentary retinopathy, extrapyramidal signs, distal amyotrophy, dementia, ataxia, skin lesions, oligophrenia, neuropathy, deafness, and cone-shaped epiphyses have been reported to be associated with spastic paraplegia. The complicated forms of spastic paraplegia consist of a large number of rare conditions and have already been reviewed by Bundy (1992) and Harding (1993).

Recently, Slavotinek et al. (1996) reported a pedigree with recurrence of congenital cataracts, motor system

disorder, short stature, learning difficulties, and skeletal abnormalities (MIM 601162). The spectrum of phenotypic manifestations segregating in the pedigree we collected is reminiscent of those segregating in the smaller pedigree reported by Slavotinek et al. (1996), suggesting the possibility of a new syndrome.

A simulated linkage analysis of the whole pedigree here reported yielded a maximum LOD score of 3.2 at recombination fraction (θ) = .01 and of 3.02 at $\theta = .05$ under an affected-only model, and of 6.22 and 5.81, respectively, under a complete penetrance model. Since the family is highly informative, DNA samples and lymphoblastoid cell lines were collected from 24 (12 affected and 12 unaffected) members of this pedigree, to perform genomewide mapping.

Subjects and Methods

Clinical Report

The spectrum of phenotypic manifestations segregating in the collected pedigree probably represents a new,

rare, and complicated form of spastic paraparesis. Table 1 summarizes the clinical features of the affected family members.

Ocular abnormalities occur with complete penetrance. All of the affected individuals presented with bilateral cataracts, with the exception of patient III-21, who presented with myopia and a chorioretinal dystrophy. An ophthalmologic evaluation of patient III-40 disclosed lens opacities in the zonular area, without anomalies of the anterior/posterior segment. Furthermore, all subjects presented with persistent vomiting, and in two of them, gastroesophageal reflux was diagnosed. The presence of a hiatus hernia was ascertained by an esophageal endoscopy in subjects II-11, III-38, III-39, and III-40.

Spastic paraparesis shows incomplete penetrance and/or variable expressivity. Pes cavus and the Babinski sign, along with different degrees of muscle wasting localized in the hands and forelegs, are present in some subjects. Electrophysiologic studies confirmed involvement of the

central motor pathways and revealed a peripheral neuropathy that mainly involved the motor axons. In particular, somatosensory and central motor-evoked potentials were abnormal in subjects III-16, III-18, and III-21, indicating involvement of the central motor and sensory pathways. An electromyogram in the same subjects revealed a neurogenic pattern, although the nerve conduction velocities were normal, suggesting an axonal motor neuropathy. Brainstem-evoked potentials showed delayed bilateral I-III latency in subjects III-16 and III-18, whereas these potentials were normal in patient III-21. Magnetic resonance imaging showed spinal cord atrophy in patient III-18. With regard to the age at onset, spastic paraparesis appeared in the first and in the third decade of life in different members of the family, with some indications of anticipation. For example, patient II-3 presented with difficulties during ambulation only in later adulthood. The daughter, patient III-16, manifested muscle weakness and difficulties in ambulation

Table 1

Clinical Features of the Affected Individuals from the Family

Patient	Bilateral Cataract	Persistent Vomiting	Hiatus Hernia	Abnormal Gait	Brisk Reflexes	Hypertone	Distal Muscle Wasting	Muscle Weakness	Pes Cavus	Babinski Sign	Other
II-3	+	+		+	+	LL			+		
II-7	+	+		+	+	LL					
II-11	+	+	+		+	LL	LL				GER
III-16	+	+		Developed during pregnancy	+	+	UL	+	+	+	
III-18	+	+		Developed during pregnancy	+	+	+	+	+	+	
III-20	+	+		+	+	LL	+		+	+	
III-21	Chorioretinal dystrophy with myopia	+		+	+		+	+	+	+	
III-33	+	+			+	+					
III-38	+	+	+		+	+	LL				
III-39	+	+	+		+	+	LL				
III-40	Zonular cataract	+	+		+						GI, GER
IV-4	+	+		+	+				+		GI, IVD

NOTE.—A plus sign (+) indicates presence of characteristic; LL = lower limbs; UL = upper limbs; GER = gastroesophageal reflux; GI = growth impairment; and IVD = interventricular defect.

during pregnancy, at age 25 years. At present, she is aged 35 years and has a severe impairment of ambulation. Her son, patient IV-4, has shown gait disturbances and the presence of pes cavus at the age of 4 years. Finally, growth impairment was ascertained in patients III-40 (height and weight both below 3d percentile) and IV-4 (height and weight both at the 25th percentile).

Large-Scale Mapping

We performed large-scale genetic mapping, using a DNA sequencer apparatus (ABI 373A) and the ABI PRISM Linkage Mapping Set (Perkin-Elmer). This set comprises 360 markers that define a 10-cM-resolution human map, with an average heterozygosity of 0.81. The markers are organized into 28 panels. Each panel contains 7–16 fluorescent dye-labeled primer pairs that generate PCR products, which can be pooled and detected in a single gel lane. PCR conditions were the same as those specified in the manufacturer’s instructions. PCR products were pooled, combined in a tube with a size standard, and loaded onto the gel in the automated sequencer ABI 373A. We performed DNA fragment sizing analysis using GENESCAN, whereas we used GENOTYPER to perform semiautomatic “allele-calling.”

Linkage Analysis

Classic two-point LOD score analysis was done in this pedigree under the assumption of autosomal dominant inheritance, with 90% penetrance of the segregating trait and an estimated disease-allele frequency of .001. All of the individuals showing at least bilateral cataracts and persistent vomiting were included as “affected” in the linkage analysis. We used the MLINK program included in the LINKAGE package (Lathrop et al. 1984) to perform linkage analysis.

Haplotype Reconstruction

Haplotype analysis was performed, to better characterize the possible meiotic recombinants and to define the critical region of the disease gene. Seven microsatellites (D10S1644, D10S1765, D10S1739, D10S1753, D10S536, D10S564, and D10S1755 [Généthon]) known to map between D10S201 and D10S583, the two markers present in the ABI-PRISM Linkage Mapping Set, and nine microsatellites (D10S1736, D10S1680, D10S574, D10S1758, D10S577, D10S1709, D10S1726, D10S198, and D10S603 [Généthon]), which span the interval between D10S583 and D10S192 in the ABI-PRISM Linkage Mapping Set, were synthesized by an Oligo 1000 M DNA Synthetizer (Beckmann). All markers, with the exception of D10S564 and D10S574, were synthesized by labeling the forward primers with 6-FAM or TET fluorescent amidites and were purified with OPC

columns (ABI, Perkin-Elmer), according to the manufacturer’s conditions. PCR was performed under standard conditions, and amplification products were loaded onto an automated sequencer ABI 373A to define allele size, by use of GENESCAN. The dinucleotide repeats D10S564 and D10S574 were amplified under standard conditions, electrophoresed in an 8% polyacrilamide/6 M urea gel, and revealed by silver staining (Budowle et al. 1991).

Results

Large-Scale Mapping

To map the disease gene, we used the 360 fluorescent markers in the ABI PRISM Linkage Mapping panels spanning the entire genome to type the 24 family members. First, we studied those chromosomes in which candidate regions containing genes responsible for different forms of congenital cataracts and spastic paraparesis had been identified. Two-point LOD score linkage analysis was performed on this pedigree, under the assumption of autosomal dominant inheritance of the segregating trait.

A LOD score of 4.83 at $\theta = .0$ was obtained for marker D10S583 (table 2). Thus, the gene responsible for the disease was mapped to the long arm of chromosome 10 on band q23.3-q24.2. Since D10S201 and D10S192, the two markers flanking D10S583 in the ABI

Table 2

LOD Score Values of the Markers Present in the ABI PRISM Linkage Mapping Set Spanning Chromosome 10

MARKER	LOD SCORE AT $\theta =$						
	.0	.01	.05	.1	.2	.3	.4
D10S249	-3.75	-.79	-.1	.15	.27	.21	.1
D10S591	-4.49	-4.14	-2.89	-1.93	-.83	-.29	-.06
D10S189	-2.56	-2.12	-1.01	-.56	-.22	-.10	-.04
D10S547	-3.90	-3.74	-2.31	-1.37	-.50	-.12	.02
D10S191	-4.46	-3.34	-1.82	-1.09	-.39	-.07	.03
D10S548	-4.21	-2.94	-1.51	-.88	-.32	-.07	.02
D10S197	-7.87	-4.38	-2.14	-1.15	-.29	.03	.08
D10S208	-1.23	-1.16	-.91	-.64	-.25	-.04	.04
D10S220	-3.47	-3.14	-1.32	-.48	.16	.27	.16
D10S561	.00	.00	.00	.00	.00	.00	.00
D10S537	-5.17	-1.22	.59	1.13	1.26	.93	.39
D10S201	-.17	.81	1.87	2.08	1.86	1.30	.56
D10S583	4.83	4.75	4.42	3.99	3.06	2.02	.86
D10S192	-2.88	1.04	1.55	1.61	1.37	.95	.41
D10S597	-3.66	-1.84	-1.03	-.63	-.26	-.10	-.03
D10S190	-3.85	-3.06	-1.05	-.23	.32	.34	.11
D10S587	-2.16	-.21	.39	.55	.51	.29	.05
D10S217	-4.99	-4.51	-2.67	-1.59	-.60	-.22	-.09
D10S212	-8.57	-4.62	-2.52	-1.60	-.72	-.30	-.10

NOTE.—All of these markers were used to type the 24 available family members.

PRISM Linkage Mapping Set, showed recombination events in some family members, additional markers were used for haplotype analysis in this region, to better characterize the possible meiotic recombinants and to define the critical region for the disease gene.

Haplotype Analysis

All family members were typed for seven microsatellites (D10S1644, D10S1765, D10S1739, D10S1753, D10S536, D10S564, and D10S1755), mapping between markers D10S201 and D10S583, and for nine microsatellites (D10S1736, D10S1680, D10S574, D10S1758, D10S577, D10S1709, D10S1726, D10S198, and D10S603), mapping between D10S583 and D10S192. Markers D10S1739, D10S1758, D10S577, D10S1709, D10S1726, and D10S198 were determined to be not informative and were excluded from haplotype reconstruction (fig. 1).

A recombination event in patient II-7 positioned the gene telomeric to D10S1765. Her affected daughter, patient III-33, inherited the same at-risk haplotype, whereas the unaffected son, subject III-34, received only part of this at-risk haplotype, from D10S1753 to D10S564. This additional recombination event allowed us to define the centromeric boundary of the critical region as between markers D10S564 and D10S1755. Furthermore, a recombination event in patient III-18 refined the distal limit of the critical interval to between markers D10S574 and D10S603. Thus, the haplotype reconstruction reduced the critical region to a 12-cM interval, flanked by markers D10S564 and D10S603.

Discussion

The present study reports the genetic mapping of a new rare spastic paraparesis, segregating in a large, three-generation family. The affected members show bilateral cataracts, gastroesophageal reflux with persistent vomiting, and spastic paraparesis with amyotrophy. From a clinical point of view, the spectrum of symptoms present in this family is reminiscent of that in a previous disorder, reported elsewhere by Slavotinek et al. (1996). In particular, the spastic paraparesis and the bilateral cataract represent the major characteristics of this new syndrome, although some other minor features are present in the affected individuals of both pedigrees. These features include persistent vomiting associated with hiatus hernia; weakness and wasting of the muscles; presence of associated motor polyneuropathy with axonal degeneration, onset of the symptoms, in some women, during pregnancy; as well as presence of anticipation. To our knowledge, this association represents a new rare form of complicated spastic paraparesis (Bundey 1992; Harding 1993). Since anticipation of symptoms, caused

by an abnormal expansion of trinucleotide repeats (Abbott and Chambers 1994; Neri et al. 1996), is a characteristic of single-gene disorders, a similar pathogenetic mechanism could also be supposed for this syndrome. The expansion of trinucleotide repeats normally causes neurodegenerative disorders. Besides, an autosomal dominant pure spastic paraplegia, already mapped to 2p21-24, has recently been shown, by a repeat expansion-detection experiment (Schalling et al. 1993), to be caused by a CAG-repeat expansion (Nielsen et al. 1997).

Using genomewide screening, we mapped this complicated form of spastic paraparesis to the long arm of chromosome 10 on band q23.3-q24.2. The gene responsible is located in an interval spanning ~12 cM of genomic DNA, between markers D10S564 and D10S603.

This interval is physically covered by the YAC contig WC10.7, available at the Whitehead Institute/MIT website. Furthermore, an integrated physical and genetic map, spanning chromosome band 10q24 (Gray et al. 1997), allows us to better characterize this critical interval. On the basis of this map, we estimated the size of the interval between markers D10S564 and D10S603 to be ~6-7 Mb. This integrated physical and genetic map contains 10 known gene loci and 11 additional expressed sequences (Gray et al. 1997). Seven of the 10 genes, as well as 8 of the 11 expressed sequence tags (ESTs), map inside of the D10S564/D10S603 interval. Some of these could represent, on the basis of their location, function, and expression, candidate genes. Furthermore, a search of the Human Genome Map database (Schuler et al. 1996), for expressed sequences in the genomic region between markers D10S564 and D10S603, results in ≥ 119 ESTs that are included within this interval, representing additional potential candidate genes. Different neurologic disorders, as well as other diseases, already have been mapped to this region (fig. 2). The critical intervals of some of these disorders overlap, for a large portion, the region defined in the present study.

A corneal dystrophy, the Thiel-Behnke type (MIM 602082; Behnke and Thiel 1965), has been mapped to a 12-cM region, between markers D10S677 and D10S1671 (Yee et al. 1997), overlapping ~6 cM of the critical interval here reported. Furthermore, a gene for partial epilepsy (MIM 600512) has been assigned to 10q24, located in a 10-cM interval between markers D10S185 and D10S566 (Ottman et al. 1995). This region overlaps, for ~7 cM, the critical interval defined in the present study. Since families with recurrence of spastic paraparesis and epilepsy are reported (Gigli et al. 1993), it would be interesting to test whether they represent a new contiguous-gene syndrome.

The Hermansky-Pudlak syndrome (HPS; MIM 203300) has also been mapped to this region, in a 14-cM interval that contains the markers D10S198 and

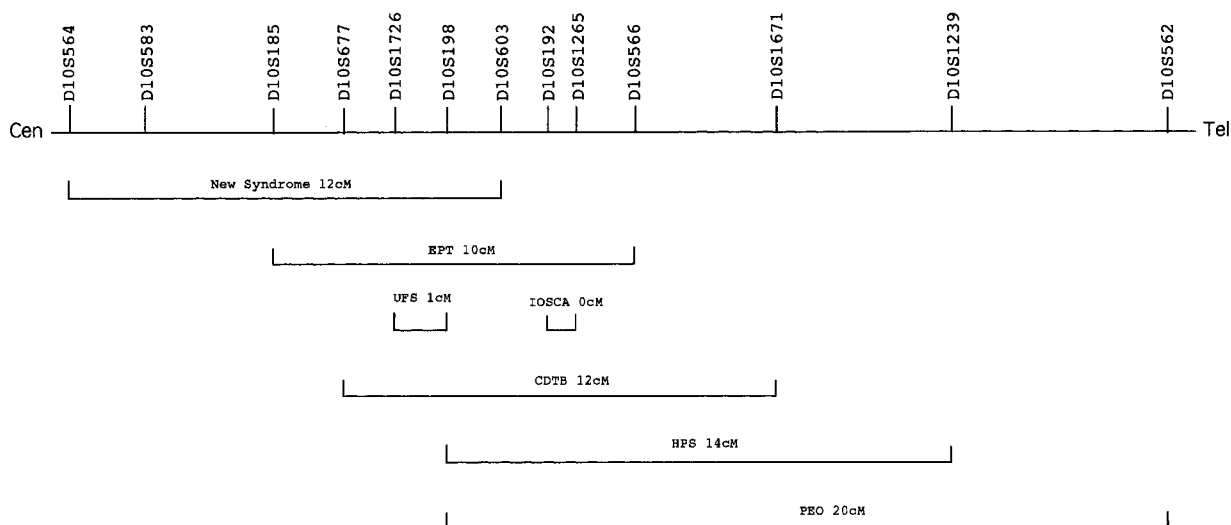


Figure 2 Schematic representation of the chromosomal region 10q23.3-q24.2, to which the syndrome described in the present study has been assigned. The overlapping of the critical interval with the regions to which other disorders have been mapped is reported. Cen = centromere; Tel = telomere; IOSCA = infantile-onset spinocerebellar ataxia; EPT = partial epilepsy; UFS = urofacial syndrome; and CDTB = corneal dystrophy, Thiel-Behnke type.

D10S1239 (Wildenberg et al. 1995). By positional cloning, the HPS gene has been identified (Oh et al. 1996), and recently mutation in the homologous murine *Hps* gene has been identified, in the "pale ear" mouse (Feng et al. 1997), mapping to murine chromosome 19. These results establish a murine region of interest, to identify additional mutant mice as animal models for the new syndrome here described.

By homozygosity mapping, the urofacial syndrome or "Ochoa syndrome" (MIM 236730; Elejalde 1979) has been assigned to a 1-cM interval, containing markers D10S1726/D10S198 (Wang et al. 1997) and overlapping the telomeric side of the critical region defined in the present study. Furthermore, an infantile-onset form of spinocerebellar ataxia (MIM 271245) with sensory neuropathy has been assigned, by homozygosity mapping, to the 10q23.3-q24.1 locus (Nikali et al. 1995). This locus, designated "SCA8," has been restricted to a region between two adjacent microsatellites, D10S192 and D10S1265 (Nikali et al. 1997). This neurologic disorder maps telomeric to the region defined in the new syndrome, described in the present paper, but the two critical intervals are closely located.

Finally, an interesting disorder has been mapped in close proximity to the syndrome reported in the present study. This disorder (MIM 157640) shows progressive external ophthalmoplegia (PEO), mitochondrial myopathy, and other abnormalities, such as progressive proximal muscle weakness and bilateral cataracts (Zeviani et al. 1989, 1990; Cormier et al. 1991; Suomalainen et al. 1992). This disorder, inherited as an autosomal dom-

inant trait, is associated with multiple different deletions of mtDNA, suggesting the presence of a nuclear-encoded factor responsible for mitochondrial deletions (Zeviani et al. 1989; Cormier et al. 1991), and has been mapped to chromosome 10 in a 20-cM region between D10S198 and D10S562 (Suomalainen et al. 1995), which is close to the critical interval identified in the present study. The presence of genetic heterogeneity in PEO syndrome suggests that another nuclear gene, or genes, is involved in the pathogenesis of this disorder. There may be other examples of human pathologic disorders caused by mutations involved in the "cross-talk" between the nuclear and the mtDNA. Pure and complicated forms of hereditary spastic paraplegia have been demonstrated to be caused by mutations in a nuclear gene coding for a mitochondrial ATPase (Casari et al. 1998), suggesting the presence of an impairment of mitochondrial functions in this class of progressive neurodegenerative disorders.

We report here the genetic mapping of a new rare autosomal dominant spastic paraparesis, which probably represents the disorder already investigated by Slavotinek et al. (1996). Haplotype reconstruction in this second pedigree would be important, to confirm that the disorder represents a new homogeneous syndrome and to possibly reduce the critical interval. This syndrome is localized in 10q23.3-q24.1, a chromosomal region containing different genes, and one to which several neurologic disorders have been mapped. The search for the disease gene through the candidate-gene approach could add clues to the understanding, at a functional level, of the molecular defects causing important types of path-

ologic entities, such as congenital cataract and spastic paraparesis.

Acknowledgments

The Telethon grant E.440 is gratefully acknowledged. This work was supported by the Italian Ministry of Health. We thank Dr. G. Casari and the Telethon Institute of Genetics and Medicine for providing fluorescent markers.

Electronic- Database Information

Accession numbers and urls for data in this article are as follows:

Généthon, <http://www.genethon.fr/> (for markers used)
 Human Genome Map, <http://www.ncbi.nlm.nih.gov/Science96/> (for expressed sequences)
 Online Mendelian Inheritance in Man (OMIM), <http://www.ncbi.nlm.nih.gov/Omim/> (for congenital cataracts [MIM 115665, 116600, 116200, 123660, 116800, 115660, 600881, 601547, 601202, 601885], spastic paraplegia [MIM 182601, 182600, 600363, 270800, 602783, 601162], corneal dystrophy [MIM 602082], partial epilepsy [MIM 600512], Hermansky-Pudlak syndrome [MIM 203300], Ochoa syndrome [MIM 236730], SCA8 [MIM 271245] and PEO syndrome [MIM 157640])
 Whitehead Institute/MIT, <http://www.genome.wi.mit.edu/> (for YAC contig information)

References

- Abbott C, Chambers D (1994) Analysis of CAG trinucleotide repeats from mouse cDNA sequences. *Ann Hum Genet* 58: 87-94
- Armitage MM, Kivlin JD, Ferrell RE (1995) A progressive early onset cataract gene maps to human chromosome 17q24. *Nat Genet* 9:37-40
- Behnke H, Thiel HJ (1965) Über die hereditäre Epitheldystrophie der Hornhaut (Typ Meesman-Wilke) in Schleswig-Holstein. *Klin Mbl Augenheilk* 147:662-672
- Berry V, Ionides ACW, Moore AT, Plant C, Bhattacharya SS, Shiels A (1996) A locus for autosomal dominant anterior polar cataract on chromosome 17p. *Hum Mol Genet* 5: 415-419
- Brakenhoff RH, Henskens HAM, van Rossum MWPC, Lubsen NH, Schoenmakers JGG (1994) Activation of the γ E-crystallin pseudogene in the human hereditary Coppock-like cataract. *Hum Mol Genet* 3:279-283
- Budowle B, Chakraborty R, Giusti AM, Eisenberg AJ, Allen RC (1991) Analysis of the VNTR Locus DIS80 by the PCR followed by high resolution PAGE. *Am J Hum Genet* 48: 137-144
- Bunday S (ed) (1992) *Genetics and neurology*. Edinburgh: Churchill Livingstone
- Casari G, De Fusco M, Ciarmatori S, Zeviani M, Mora M, Fernandez P, De Michele G, et al (1998) Spastic paraplegia and OXPHOS impairment caused by mutations in paraplegin, a nuclear-encoded mitochondrial metalloprotease. *Cell* 93:973-983
- Cormier V, Rotig A, Tardieu M, Colonna M, Saudubray J-M, Munnich A (1991) Autosomal dominant deletions of the mitochondrial genome in a case of progressive encephalomyopathy. *Am J Hum Genet* 48:643-648
- De Michele G, De Fusco M, Cavalcanti F, Filla A, Marconi R, Volpe G, Monticelli A, et al (1998) A new locus for autosomal recessive hereditary spastic paraplegia maps to chromosome 16q24.3. *Am J Hum Genet* 63:135-139
- Eiberg H, Lund AM, Warburg M, Rosenberg T (1995) Assignment of congenital cataract Volkmann type (CCV) to chromosome 1p36. *Hum Genet* 96:33-38
- Eiberg H, Marner E, Rosenberg T, Mohr J (1988) Marner's cataract assigned to chromosome 16: linkage to haptoglobin. *Clin Genet* 34:272-275
- Elejalde BR (1979) Genetic and diagnostic considerations in three families with abnormalities of facial expression and congenital urinary obstruction: "the Ochoa syndrome." *Am J Med Genet* 3:97-108
- Feng GH, Bailin T, Oh J, Spritz RA (1997) Mouse pale ear (ep) is homologous to human Hermansky-Pudlak syndrome and contains a rare "AT-AC" intron. *Hum Mol Genet* 6: 793-797
- Fink JK, Wu CB, Jones SM, Sharp GB, Lange BM, Lesicki A, Reinglass T, et al (1995) Autosomal dominant familial spastic paraplegia: tight linkage to chromosome 15q. *Am J Hum Genet* 56:188-192
- Gigli GL, Diomedei M, Bernardi G, Placidi F, Marciani MG, Calia E, Maschio MCE, et al (1993) Spastic paraplegia, epilepsy and mental retardation in several members of a family: a novel genetic disorder. *Am J Med Genet* 45:711-716
- Gray IC, Fallowfield J, Ford S, Nobile C, Volpi EV, Spurr NK (1997) An integrated physical and genetic map spanning chromosome band 10q24. *Genomics* 43:85-88
- Harding AE (1993) Hereditary spastic paraplegias. *Semin Neurol* 13:333-336
- Hazan J, Fontaine B, Bruyn RPM, Lamy C, van Deutekom JCT, Rime CS, Dürr A, et al (1994) Linkage of a new locus for autosomal dominant familial spastic paraplegia to chromosome 2p21-p24. *Hum Mol Genet* 3:1569-1573
- Hazan J, Lamy C, Melki J, Munnich A, de Recondo J, Weissenbach J (1993) Autosomal dominant familial spastic paraplegia is genetically heterogeneous and one locus maps to chromosome 14q. *Nat Genet* 5:163-167
- Hejtmancik JF (1998) The genetics of cataract: our vision becomes clearer. *Am J Hum Genet* 62:520-525
- Hentati A, Pericak-Vance MA, Hung WY, Belal S, Laing N, Boustany RM, Hentati F, et al (1994a) Linkage of "pure" autosomal recessive familial spastic paraplegia to chromosome 8 markers and evidence of genetic locus heterogeneity. *Hum Mol Genet* 3:1263-1267
- Hentati A, Pericak-Vance MA, Lennon F, Wasserman B, Hentati F, Juneja T, Angrist MH, et al (1994b) Linkage of a locus for autosomal dominant familial spastic paraplegia to chromosome 2p markers. *Hum Mol Genet* 3:1867-1871
- Ionides ACW, Berry V, Mackay DS, Moore AT, Bhattacharya SS, Shiels A (1997) A locus for autosomal dominant posterior polar cataract on chromosome 1p. *Hum Mol Genet* 6:47-51

- Kramer P, Yount J, Mitchell T, LaMorticella D, Carrero-Valenzuela R, Lovrien E, Maumenee I, et al (1996) A second locus for cerulean cataract maps to the β -crystallin region on chromosome 22. *Genomics* 35:539–542
- Lathrop GM, Lalouel JM, Julier C, Ott J (1984) Strategies for multilocus linkage analysis in humans. *Proc Natl Acad Sci USA* 81:3443–3446
- Mackay D, Ionides A, Berry V, Moore A, Bhattacharya S, Shiels A (1997) A new locus for dominant “zonular pulverulent” cataract, on chromosome 13. *Am J Hum Genet* 60:1474–1478
- Maumenee IH (1979) Classification of hereditary cataracts in children by linkage analysis. *Ophthalmology* 86:1554–1558
- Merin S (1991) Inherited cataracts. In: Merin S (ed) *Inherited eye disease: diagnosis and clinical management*. Marcel Dekker, New York, pp 86–120
- Néri C, Albanèse V, Lebre A-S, Holbert S, Saada C, Bouguerlet L, Meier-Ewert S, et al (1996) Survey of CAG/CTG repeats in human cDNAs representing new genes: candidates for inherited neurological disorders. *Hum Mol Genet* 5: 1001–1009
- Nielsen JE, Koefoed P, Abell K, Hasholt L, Eiberg H, Fenger K, Niebuhr E, et al (1997) CAG repeat expansion in autosomal dominant pure spastic paraplegia linked to chromosome 2p21-p24. *Hum Mol Genet* 6:1811–1816
- Nikali K, Isosomppi J, Lonnqvist T, Mao J, Suomalainen A, Peltonen L (1997) Toward cloning of a novel ataxia gene: refined assignment and physical map of the IOSCA locus (SCA8) on 10q24. *Genomics* 39:185–191
- Nikali K, Suomalainen A, Terwilliger J, Koskinen T, Weissenbach J, Peltonen L (1995) Random search for shared chromosomal regions in four affected individuals: the assignment of a new hereditary ataxia locus. *Am J Hum Genet* 56: 1088–1095
- Oh J, Bailin T, Fukai K, Feng GH, Ho L, Mao J, Frenk E, et al (1996) Positional cloning of a gene for Hermansky-Pudlak syndrome, a disorder of cytoplasmic organelles. *Nat Genet* 14:300–306
- Ottman R, Risch N, Hauser WA, Pedley TA, Lee JH, Barker-Cummings C, Lustenberger A, et al (1995) Localization of a gene for partial epilepsy to chromosome 10q. *Nat Genet* 10:56–60
- Padma T, Ayyagari R, Murty JS, Basti S, Fletcher T, Rao GN, Kaiser-Kupfer M, et al (1995) Autosomal dominant zonular cataract with sutural opacities localized to chromosome 17q11-12. *Am J Hum Genet* 57:840–845
- Reid E (1997) Pure hereditary spastic paraplegia. *J Med Genet* 34:499–503
- Renwick JH, Lawler SD (1963) Probable linkage between a congenital cataract locus and the duffy blood group locus. *Ann Hum Genet* 27:67–84
- Schalling M, Hudson TJ, Buetow KH, Housman DE (1993) Direct detection of novel expanded trinucleotide repeats in the human genome. *Nat Genet* 4:135–139
- Schuler GD, Boguski MS, Stewart EA, Stein LD, Gyapay G, Rice K, White RE, et al (1996) A gene map of the human genome. *Science* 274:540–546
- Slavotinek AM, Pike M, Mills K, Hurst JA (1996) Cataracts, motor system disorder, short stature, learning difficulties, and skeletal abnormalities: a new syndrome? *Am J Med Genet* 62:42–47
- Suomalainen A, Kaukonen J, Amati P, Timonen R, Haltia M, Weissenbach J, Zeviani M, et al (1995) An autosomal locus predisposing to deletions of mitochondrial DNA. *Nat Genet* 9:146–151
- Suomalainen A, Majander A, Haltia M, Somer H, Lonnqvist J, Savontaus M-L, Peltonen L (1992) Multiple deletions of mitochondrial DNA in several tissues of a patient with severe retarded depression and familial progressive external ophthalmoplegia. *J Clin Invest* 90:61–66
- Wang C-Y, Hawkins-Lee B, Ochoa B, Walker RD, She J-X (1997) Homozygosity and linkage-disequilibrium mapping of the urofacial (Ochoa) syndrome gene to a 1-cM interval on chromosome 10q23-q24. *Am J Hum Genet* 60: 1461–1467
- Wildenberg SC, Oetting WS, Almodovar C, Krumwiede M, White JG, King RA (1995) A gene causing Hermansky-Pudlak syndrome in a Puerto Rican population maps to chromosome 10q2. *Am J Hum Genet* 57:755–765
- Yee RW, Sullivan LS, Lai HT, Stock EL, Lu Y, Khan MN, Blanton SH, et al (1997) Linkage mapping of Thiel-Behnke corneal dystrophy (CDB2) to chromosome 10q23-24. *Genomics* 46:152–154
- Zeviani M, Bresolin N, Gellera C, Bordoni A, Pannacci M, Amati P, Moggio M, et al (1990) Nucleus-driven multiple large-scale deletions of the human mitochondrial genome: a new autosomal dominant disease. *Am J Hum Genet* 47: 904–914
- Zeviani M, Servidei S, Gellera C, Bertini E, Di Mauro S, Di Donato S (1989) An autosomal dominant disorder with multiple deletions of mitochondrial DNA starting at the D-loop region. *Nature* 339:309–311