

Technical aspects of enteral nutrition

M Keymling

Abstract

Advances in technical aspects of enteral feeding such as the manufacture of tubes from polyurethane or silicone have helped promote the science of enteral nutrition. Nasoenteral tubes have few complications, apart from a high unwanted extubation rate and some reluctance from patients because of cosmetic unacceptability. Needle jejunostomy has low morbidity but can only be placed at laparotomy. Percutaneous gastrostomy (in all its different guises) has been established as a low risk procedure and is the access route of choice for longterm enteral feeding, in particular for cancer, geriatric, and neurological patients.

(Gut 1994; supplement 1: S77-S80)

The use of the enteral route of access for artificial nutrition dates back to the 16th century. It was not until the late 1960s, however, with the advent of sophisticated delivery systems and effective enteral diets that its routine use in clinical medical practice became accepted. Progress continued throughout the past two decades with developments such as enteral tube materials like polyurethane and silicone suitable for longer term placement,¹ and commercially produced complete diet formulations as effective as parental formulations.²⁻⁶

Appropriate diet delivery systems are required for a number of reasons including: (1) inability to swallow because of disease (for example - head and neck, oesophageal tumours; neurological - multiple sclerosis, stroke); (2) palatability of commercially produced enteral diets often precludes oral administration; (3) volume of feed (sometimes up to 2.5 l/24 h) may be difficult for some patients (for example the elderly) to consume).

The different access routes to the gastrointestinal tract are considered in this study.

Nasoenteral tubes

Nasoenteral tube feeding is widely accepted as a very simple and safe method of diet delivery. A number of techniques have been used to ensure accurate placement of the tube and maintenance of position once placed. Manegold⁷ described the role of endoscopy. One particularly novel technique was the development of an enteral tube with an inflatable balloon at the distal tip. Inflation of the balloon theoretically permitted the gastric pressure waves and peristalsis to convey the tip of the tube through the pylorus and then through the duodenum. Once placed the balloon was further inflated and broke away

from the distal tube, at which point it deflated and continued its passage through the gastrointestinal tract to be expelled through the rectum. Another design of tube included an 'olive', which sat intranasally, supposedly preventing accidental tube extubation. Accidental tube extubation remains the commonest complication of nasoenteral tube feeding. Cosmetic dissatisfaction and delay in the resolution of deglutition disorders after a stroke have also been described (Table I).⁸ In rare cases fatal misplacement of tubes occurs (for example into the lung, through the oesophagus, or into the brain).⁹⁻¹¹ The decision on the placement of the distal end of the nasoenteral tube is a clinical one, and it may be placed in the stomach, duodenum or jejunum. *x* Ray should be used to record correct positioning after insertion and to identify other complications such as tube knotting.¹²

Some additional points should be made, which include firstly that in elderly or confused patients frequent tube extubation interrupts treatment and prevents nutritional goals being met. Secondly, in patients with disordered swallowing the situation can be worsened by the presence of a nasoenteral tube. Finally, placement of tubes in patients with a tumour in the upper gastrointestinal tract or pharynx can be difficult.

Needle jejunostomy

Delany described the placement of a fine bore feeding tube with a peel away catheter into the jejunum. It is a simple procedure appropriate for longer term feeding. The technique creates a submucosal tunnel for the catheter about 10 cm in length, which minimises the risk of displacement or intraperitoneal leakage of diet. Removal does not require further laparotomy. Mortality is about 2%.¹³ General anaesthesia is required, however, and with adequate alternative techniques available the needle jejunostomy is probably only indicated if concurrent surgery is taking place and the patient is, or is in danger, of becoming malnourished. Typical patients include those about to have extensive tumour resection or those after multiple trauma.

TABLE I Complications of nasoenteric feeding tubes

<i>Major</i>	
Oesophageal perforation	
Oesophageal bleeding	
Oesophageal strictures	
Tube misplacement	
Pulmonary aspiration of diet	
<i>Minor</i>	
Cosmetic	
Delay in resolution of deglutition disorders after stroke	
Frequent accidental extubation	
Spontaneous rugration of the tip of the tube	

Medizinische Klinik,
Kreiskrankenhaus,
Bad Hersfeld,
Germany
M Keymling

Correspondence to:
Priv-Doz Dr M Keymling,
Medizinische Klinik,
Kreiskrankenhaus, Seilerweg
29, D 6430 Bad Hersfeld,
Germany.

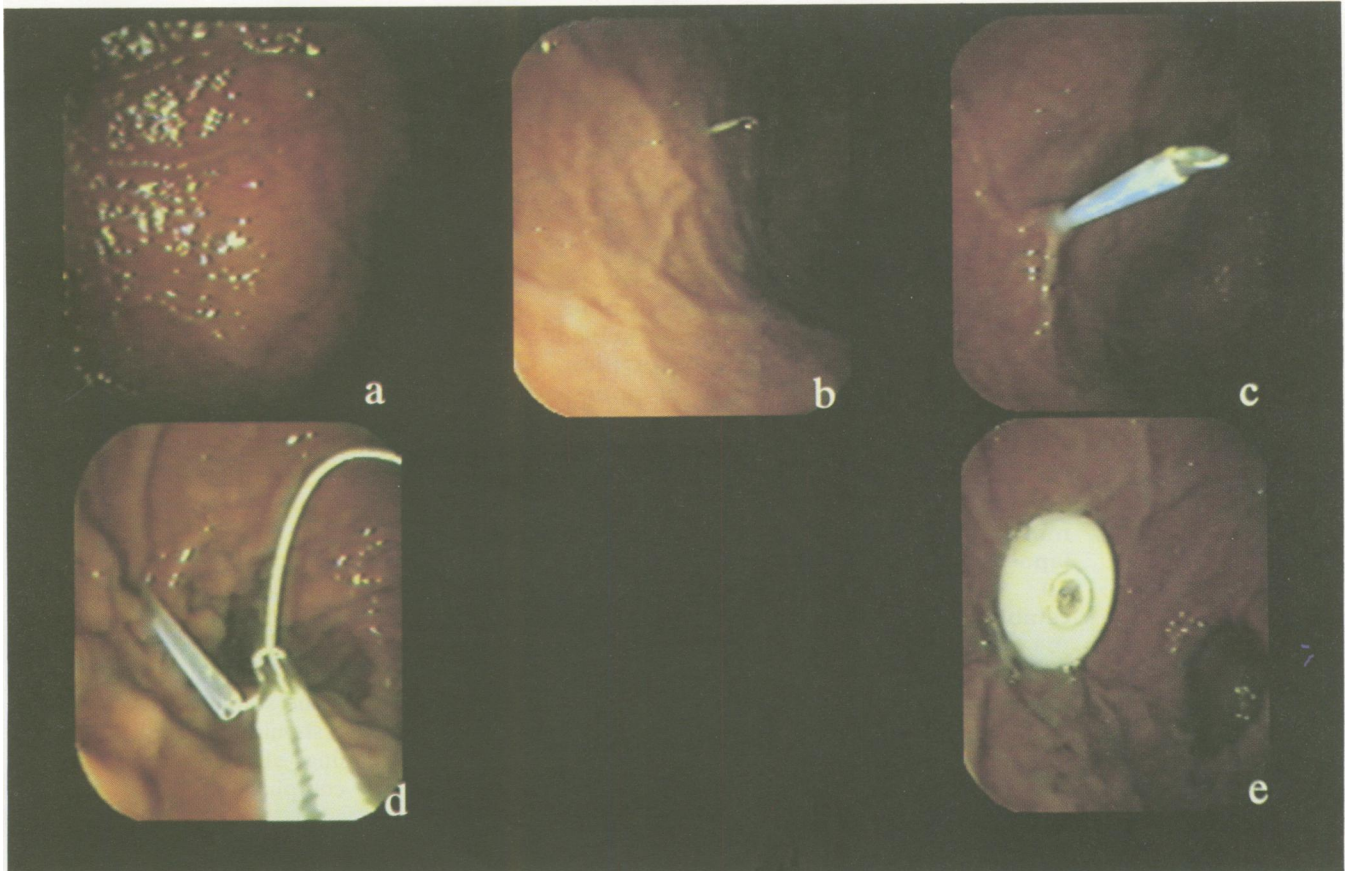


Figure 1: The 'pull through' technique of inserting percutaneous endoscopic gastrostomy feeding tubes.

Percutaneous endoscopic gastrostomy

In 1980 a new technique of gastrostomy tube insertion was developed that was done under endoscopic control and local anaesthesia.¹⁴ The simplicity and low morbidity and mortality mean that this technique is the best method for access in the patient requiring longer term enteral feeding.^{15 16}

TECHNIQUES

The 'pull through' technique is described. The supine patient is given an endoscopy and the stomach distended with air. The tip of the palpating finger may be seen through the abdominal wall (Fig 1a) and a cannula for local anaesthesia is inserted through the wall into the stomach, under direct vision of the endoscopist (Fig 1b). A puncture cannula is pushed from outside into the stomach (Fig 1c) serving as a guide for the thread, which is introduced from outside and grabbed by the endoscope forceps (Fig 1d) and pulled up the oesophagus and out of the mouth. This thread is now fixed to a preformed gastrostomy tube with a circular buffer, and the thread is pulled back through the abdominal wall pulling the gastrostomy tube until it abuts the gastric mucosa (Fig 1e). A fixation device is then attached to prevent movement.

Sacks and Vine¹⁷ modified the technique by replacing the thread with a guidewire over which the gastrostomy tube was pushed. The apparent slight advantages of this pull through technique are probably clinically irrelevant.¹⁸

A completely different system (the direct stab approach) was described by Russell.¹⁹

Still under endoscopic control, the gastrostomy tube is inserted externally through the abdominal wall. Unfortunately this technique gives rise to the 'tent roof' phenomenon particularly in larger subjects. In these cases the cannula is not long enough to penetrate the gastric mucosa externally but merely pushes it down so that the endoscopic appearance is of a 'tent roof' (Fig 2).

A number of different retainer systems are used including balloons, buttons or spirals.^{19 20} The spiral retainer system is open to criticism on grounds of safety²¹ possibly because of its length and rigidity.

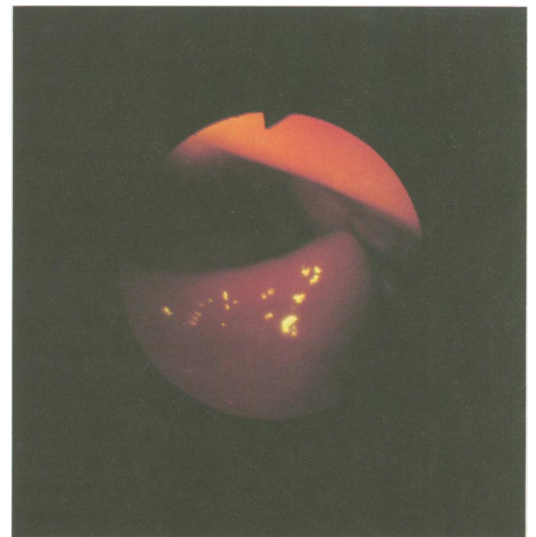

Figure 2: 'Tent roof' phenomenon that can occur during the direct stab approach of inserting gastrostomy tubes externally through the abdominal wall.

TABLE II *Contraindications to non-surgical gastrostomy feeding tube placement*

Coagulopathies
Missed diaphanoscopy
Peritonitis
Ileus
No informed consent
Anorexia nervosa

Fluoroscopic gastrostomy

The use of fluoroscopic techniques to place gastrostomy tubes has been described in recent years and is a low morbidity procedure. For this technique the stomach is inflated by instillation of air (down a nasogastric tube placed for the purpose) so that it can be localised by x ray. Endoscopy is not required, which may permit placement in certain patients in whom endoscopy is either impossible or contraindicated (for example some oropharyngeal tumours). Reported death rates for this technique are about 0.8%, with a minor complication rate of about 5%. There are certain disadvantages. The technique cannot be used for access to the jejunum, and if the 'tent roof' phenomenon described earlier develops then the procedure cannot be done.

Whenever possible the stomach should be assessed before any gastrostomy tube insertion because an undiagnosed abnormality such as peptic ulcer or carcinoma may coincidentally be present.⁸ There are certain contraindications to any non-surgical gastrostomy placement (Table II). The inability to auscultate or visualise the stomach occurs in about 1% of cases and is generally caused by peritoneal carcinomatosis or previous surgery. Fully informed consent of the patient or their guardian is of course mandatory to highlight that in many cases this procedure is palliative and will not affect the eventual outcome of the underlying disease. Anorexia nervosa is considered an absolute contraindication to gastrostomy placement because such patients often manipulate their enteral feeding regimens.

Table III compares the different feeding techniques described. Nasoenteral tube placement requires the least experience, while, of the interventional techniques, endoscopic gastrostomy seems to be the best procedure.

Complications of gastrostomy

If gastrostomy is performed carefully according to predefined protocols technical complications such as early displacement (common for nasoenteral tubes) are rare. Care protocols monitored by nutrition support teams minimise complications such as tube blockage from coagulated diet.

Clinically minor complications occur quite often, and local infection (around the stoma

site) is most common and may be present from 3 to 15% of cases,¹⁵ depending on the medical centre. Difference between centres are difficult to explain, but may relate to inconsistencies in the definition of infection and differences in techniques of prophylaxis. Differences in gastrostomy technique used probably have no influence on subsequent infection rates. Preliminary results from our unit, investigating the relation between bacterial colonisation of the pharynx and gastrostomy puncture site immediately after 'pull through' of the gastrostomy show differences in bacterial populations. Our puncture site infection rate is only 3% and suggests that the 'pull through' technique may be undertaken with low infection rates. Our experience confirms that careful management and care with daily change of dressing of the puncture site is the best way of reducing local infection rates. If infection develops it may be treated by local wound care – the need for tube removal is rare.

About 10% of patients develop local pain at the puncture site after tube insertion, which may be treated with simple analgesia. Occasionally this pain may cause diagnostic uncertainty if pneumoperitoneum is present after gastrostomy tube insertion, leading to unnecessary laparotomy after tube insertion.

Major complications are rare. The overall minor complication rate for gastrostomies is about 9%, with a major complication rate of 3% and a death rate of 0.8%.^{15 16 22 23} We have had no deaths in a series of 600 tube insertions. Other procedure specific complications such as major haemorrhage, fistula, and necrotising fasciitis are rare, but must be considered.²⁴

Clinical application

The low morbidity and mortality of endoscopic gastrostomy placement has allowed it to become a popular route of access for enteral nutrition in three key patient groups – oncology, geriatric, and neurological patients.

ONCOLOGY PATIENTS

Cachexia occurs in 40% of cancer patients.²⁵⁻²⁷ The causes are as yet not fully known, but in many cases diet supplementation alone will not reverse the cachexia. Increasingly enteral (and sometime parenteral) nutrition support is appropriate. The introduction of endoscopic gastrostomy has permitted the widespread use of ambulatory enteral feeding in this group – a development welcomed by both clinicians and patients.

In our patients with unresectable cancer, two main indications for the introduction of enteral feeding are apparent. Firstly, those with weight loss (>5 kg in four weeks), and secondly those with intestinal malignant structure giving rise to intermittent subacute obstruction, which is aggravated by the ingestion of solid food. For these patients continual infusion of liquid enteral diet can be of benefit in reducing symptoms.

Tube feeding is a well proved way of treating weight loss in patients with advanced

TABLE III *Summary of techniques of feeding tube placement*

	x Ray	Laparotomy	Endoscopy	General Anaesthesia
Nasoenteric tube	+	-	+	-
Needle jejunostomy	-	-	-	+
Fluoroscopic gastrostomy	+	-	-	-
Endoscopic gastrostomy	-	-	+	-

--No; +=Yes.

cancer.^{28, 29} Our patients show a mean weight gain of 2.9 kg (range -2.8 to +13 kg). Despite this encouraging weight gain, metabolic parameters seem unchanged.

For those with proximal malignant strictures the distal end of the enteral tube should be placed (when possible) distal to the stricture. This may require endoscopic or fluoroscopic manipulation. In some cases dilation of the stricture might be appropriate. In recent years the use of intestinal self expanding mesh graft stents have been advocated. Gastrostomy or jejunostomy can then be performed. Recently we described the introduction of a self expanding stent through a gastrostomy tube to be placed in a malignant duodenal stricture. A fine bore feeding tube was then passed through the gastrostomy and stent into the distal non-obstructed part of the duodenum. This combination treatment permitted the patient to orally ingest a soft diet supplemented by tube feeding.³⁰

The time spent in hospital after endoscopic gastrostomy feeding tube placement is short, and in our unit tube placement in some patients is carried out as a day case. The main benefit of gastrostomy feeding in cancer patients is a better quality of life,³¹ as a result of reversal of weight loss and respite from abdominal pain. The added bonus is that the patient may be treated at home.

GERIATRIC AND NEUROLOGICAL PATIENTS

Strokes are common in subjects over 60.³² As the mean survival of Western societies increases, larger numbers of patients present with nutrition problems associated with deglutition disorders after stroke. Many of the neurological deficits after stroke will recover, but may take many weeks or months, during which time nutritional state needs to be maintained to avert the development of complications such as bedsores. Thus a simple and effective means of delivering nutrition may be required. Nasoenteral tubes may adversely affect recovery of swallowing function,³³ and thus gastrostomy feeding is the best technique for this patient group. In our own stroke patients 20% will return to normal swallowing after an average of three months.

- 1 Orr G, Wade J, Bothe A, Blackburn GL. Alternatives to total parenteral nutrition in the critically ill patient. *Crit Care Med* 1980; 8: 29-34.
- 2 Allardyce DB, Groves AC. A comparison of nutritional gains resulting from intravenous and enteral feeding. *Surg Gynecol Obstet*, 1984; 139: 179-84.
- 3 Yeung CK, Smith RC, Hill GL. Effect of an elemental diet on body composition. *Gastroenterology* 1979; 77: 652-7.

- 4 Heymsfield SB, Bethel RA, Ansley JD, Nixon DW, Rudman D. Enteral hyperalimentation: an alternative to central venous hyperalimentation. *Ann Intern Med* 1979; 90: 63-71.
- 5 Chrysomilides SA, Kaminsky MV. Home enteral and parenteral nutritional support: a comparison. *Am J Clin Nutr* 1981; 34: 2271-5.
- 6 Dölp R, Grünert A, Böhm A. Enterale oder parenterale Ernährungstherapie Eine vergleichende klinische Studie. *Infusionstherapie* 1983; 10: 286-90.
- 7 Manegold BC, Mechtersheimer U, Jung M. Applikationsformen zur enteralen Sondenernährung. ein Überblick. *medwelt* 1989; 38: 26-8.
- 8 Yeung EY, Ho CS. Percutaneous radiologic gastrostomy. *Clin Gastroenterol* 1992; 6: 297-317.
- 9 Frenstad JD, Martin SH. Lethal complication from insertion of nasogastric tube after severe basilar skull fracture. *J Trauma* 1978; 18: 820-2.
- 10 Ghahremani GG, Gould RJ. Nasoenteric feeding tubes: radiographic detection of complications. *Dig Dis Sci* 1986; 31: 574-85.
- 11 James RH. An unusual complication of passing a narrow bore nasogastric tube. *Anesthesia* 1978; 33: 76.
- 12 Rabast U. Lokalisation von Ernährungssonden. *Dtsch Med Wochenschr* 1985; 110: 1074-6.
- 13 Page CP. Needle catheter jejunostomy. *Contemporary Surgery* 1981; 19: 29-47.
- 14 Gauderer WL, Ponsky JL, Izant RJ. Gastrostomy without laparotomy: a percutaneous endoscopic technique. *J Pediatr Surg* 1980; 15: 872-5.
- 15 Larson DE, Burton DD, Schroeder KW, DiMagno EP. Percutaneous endoscopic gastrostomy. Indications, success, complications and mortality in 314 consecutive cases. *Gastroenterology* 1987; 93: 48-52.
- 16 Ponsky JL, Gauderer MWL, Stellato TA, Aszodi A. Percutaneous approaches to enteral alimentation. *Am J Surg* 1985; 149: 102-5.
- 17 Sacks BA, Vine HS, Plestrant AM, Ellison HP, Shropshire D, Lowe R. A nonoperative technique for establishment of a gastrostomy in the dog. *Invest Radio* 1983; 18: 485-7.
- 18 Hogan RB, DeMarco DC, Hamilton JK, Walker CO, Polter DE. Percutaneous endoscopic gastrostomy - to push or pull. *Gastrointest Endosc* 1986; 32: 253-8.
- 19 Russell TR, Brotman M, Norris F. Percutaneous gastrostomy. *Am J Surg* 1984; 148: 132-7.
- 20 Vestweber KH, Troidl H, Sommer H. Perkutane Endoskopische Gastrostomie. *Dtsch Med Wochenschr* 1984; 109: 1203-4.
- 21 Fruehmorgen P, Hardegg G, Heller T. Sondendislokation nach perkutaner, endoskopisch kontrollierter Gastrostomie Ein Fallbericht. *Z Gastroenterol* 1991; 29: 655-8.
- 22 Foutch PG, Woods CA, Talbert GA, Sanowski RA. A critical analysis of the Sacks-Vine gastrostomy tube: a review of 120 consecutive procedures. *Am J Gastroenterol* 1988; 83: 812-5.
- 23 Miller RE, Castelmain B, Lacqua FJ, Kotler DP. Percutaneous endoscopic gastrostomy: results in 316 patients and review of literature. *Surg Endos* 1989; 3: 186-90.
- 24 Greif JM, Ragland JJ, Oschsner MG. Fatal necrotizing fasciitis complicating percutaneous endoscopic gastrostomy. *Gastrointest Endosc* 1986; 32: 292-4.
- 25 Lundvick J. Nutritional screening of the oncological patient. *Nutritional Support Services* 1983; 3: 21-3.
- 26 Theologides A. Cancer cachexia. *Cancer* 1979; 43: 2065-9.
- 27 DeWys WD. Anorexia as a general effect of cancer. *Cancer* 1979; 43: 2013-9.
- 28 Lübke HJ, Weithofer G, Keymling M, Bloch R. Supportive Ernährungstherapie bei Patienten mit metastasierenden Tumoren des Gastrointestinaltraktes. *Tumor Diagnostik Therapie* 1982; 3: 259-68.
- 29 Keymling M. Die perkutane endoskopisch kontrollierte Gastrostomie in der intermistischen Onkologie. *Medwelt* 1987; 38: 37-9.
- 30 Keymling M, Knyrim K, Wagner J, Vakil M. Percutaneous stent implantation in malignant duodenal obstruction. *Gastrointest Endosc* 1993; 39: 439-41.
- 31 Schmitz JM, Seiter A, Czischke C, Grünert A, Ahnefeld FW. Möglichkeiten und Grenzen der parenteralen Ernährung bei onkologischen Patienten. *Aktuelle Onkologie* 1986; 35: 209-22.
- 32 Lindner O. Differential-Therapie bei der Multimorbidität in der Geriatrie. *Acta Gerontologica* 1974; 4: 115-22.
- 33 Selley WG. Swallowing difficulties in stroke patients: a new treatment. *Age ageing* 1985; 14: 361-5.