

Arterial oxygen saturation during upper gastrointestinal endoscopy: the effects of a midazolam/pethidine combination

A W Murray, C G Morran, G N C Kenny, J R Anderson

Abstract

This study was performed to assess the severity and duration of hypoxia during and after prolonged upper gastrointestinal endoscopy. Twenty patients were studied using a non-invasive pulse oximeter. Significant reductions in oxygen saturation were noted during endoscopy and remained below the pre-examination level during the one hour period after the examination. This study indicates that pulse oximetry is a useful monitor for detection of hypoxia during and after endoscopy.

Flexible fiberoptic endoscopy of the upper gastrointestinal tract is frequently performed and has a low morbidity and mortality. Hypoxic episodes have been noted, however, in association with endoscopy and electrocardiographical changes associated with the episodes have been reported especially in patients suffering from ischaemic heart disease.¹⁻⁷

More complex and prolonged procedures such as endoscopic retrograde cholangiopancreatography (ERCP) with or without sphincterotomy, and laser therapy to oesophageal and gastric lesions are carried out on increasingly elderly patients who are deemed poor risks for general anaesthetic. As these examinations cause the patient much greater discomfort than diagnostic endoscopy, larger doses of sedative and analgesic drugs may be administered.

Mild degrees of hypoxia can be tolerated in young fit patients without obvious sequelae. In the elderly, and in those patients with pre-existing cardiovascular or cerebrovascular disease, a reduction in oxygen supply is likely to exacerbate symptoms. If hypoxaemia is severe or protracted, cardiac arrhythmias and ischaemic changes may progress to myocardial infarction or cardiac arrest. Borderline ischaemic regions of brain are at high risk of infarction during hypoxic episodes. Reversible damage to the brain caused by hypoxia may become manifest after endoscopy when recovery from sedation may appear to be greatly prolonged.

Ambient lighting is often reduced during endoscopy to improve the quality of observation by the operator and detection of cyanosis in these circumstances becomes increasingly difficult. In addition, endoscopy is frequently performed with only one member of medical staff present. As the operator's attention is concentrated on the procedure, deterioration in the patient's condition may only be recognised when a critical event occurs.

The present study was designed to examine

the changes in arterial oxyhaemoglobin saturation during, and up to one hour following prolonged endoscopic procedures.

Methods

PATIENTS

Written informed consent for the study was obtained from 20 patients. Demographic data are shown in Table I. Underlying medical and surgical diseases and the procedures undertaken are detailed in Tables II and III.

Arterial oxyhaemoglobin saturation (SaO₂) was monitored continuously using an Ohmeda Biox 3700 pulse oximeter. Output from the pulse oximeter was connected to an Atari 1040 ST computer via an analogue to digital converter and the results saved to magnetic disk at one minute intervals. The computer program was designed to reduce the time period between storage to 15 seconds if the oxygen saturation decreased 5% or more below the baseline observation measured before the administration of any sedative drugs. Measurements continued for the duration of the examination and for one hour into the recovery phase.

Lignocaine was applied to the patients'

TABLE I Demographic data

	Age (yr)	Weight (kg)
Mean	62.45	64.55
Range	26-85	32-106
(SEM)	3.35	4.43
	Male	Female
Sex	14	6

TABLE II Pre-existing disease in 20 patients undergoing endoscopy

Condition	n
Ischaemic heart disease	5
Cerebrovascular disease	3
Valvular heart disease	1
Hepatic or pancreatic disease	4
Respiratory disease	4

TABLE III Endoscopic procedures

Procedure	n
Endoscopic retrograde cholangiopancreatography	9
Endoscopy with laser therapy	7
Upper GI endoscopy	4
Duration of examination	time (min)
Mean	20.7
(SEM)	2.47
Range	4-43

University Department of Anaesthesia, Royal Infirmary, Glasgow
A W Murray
C G Morran
G N C Kenny

University Department of Surgery, Royal Infirmary, Glasgow
C G Morran
J R Anderson

Correspondence to:
Dr A W Murray, Department of Anaesthesia, Newcastle General Hospital, Westgate Road, Newcastle upon Tyne NE4 6BE.

Accepted for publication
23 May 1989

pharynx using 10 doses of 10 mg from a metered spray. Sedative and analgesic drugs were administered intravenously into a fast running infusion by the operator. In accordance with the normal practice for these procedures in our unit, patients were given intravenous pethidine 50 mg if they were aged under 70 years, and pethidine 25 mg if they were older. The sedation was then completed with midazolam, titrated in 2.5 mg increments until the patients' speech became slurred. The mean dose of midazolam was 7.77 mg (SEM 0.59) and the individual doses ranged from 2.5 mg to 15 mg. When the operator was satisfied with the level of sedation, the endoscope was introduced.

All patients were examined in the left lateral position and breathed room air. Arterial saturation was recorded:

During the procedure

(i) At baseline, before administration of sedative drugs; (ii) at the maximum reduction of saturation during endoscopy; (iii) at the end of endoscopy as the endoscope was withdrawn.

During recovery

(i) At the beginning of the recovery phase, after transfer to the recovery area; (ii) at the point of maximum desaturation during recovery; (iii) at one hour from the end of endoscopy.

The time period during which oxygen saturation dropped below baseline, and time spent 5% or more below baseline were noted.

Results

DURING ENDOSCOPY

Mean duration of the endoscopy was 20.7 minutes and ranged from four to 43 minutes. The mean baseline saturation measured was below the lower limit for a normal population. This probably reflects the poor cardiorespiratory state of these patients. After administration of sedatives and introduction of the endoscope,

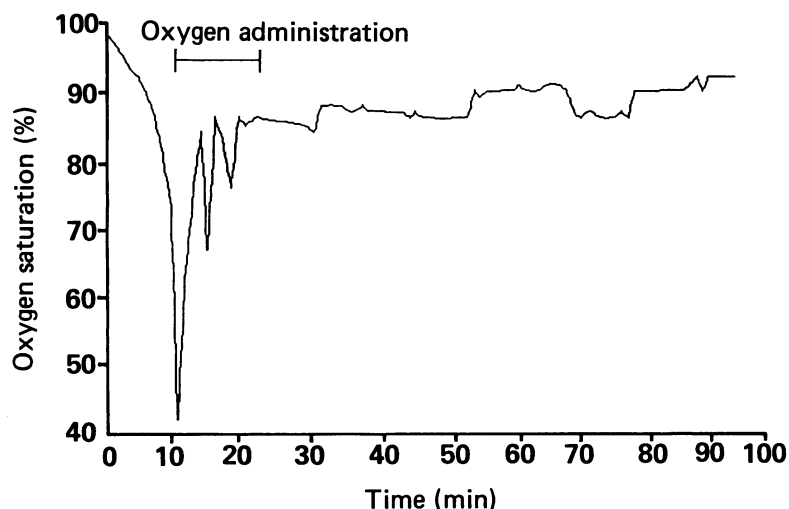


Figure: Oxygen saturations for one patient. This patient had a short respiratory arrest requiring manual ventilation for approximately three minutes. Oxygen was then administered by nasal cannulae for the remainder of the examination at a rate of 2 l/min. SaO₂ of 42% is approximately equivalent to an arterial PO₂ of 20 mmHg.

TABLE IV SaO₂ at measurement points during the study

Event	Saturation (Mean)	(SEM)
<i>(a) During endoscopy</i>		
Baseline	94.4	2.54
Minimum saturation	82.9*†	12.48
End of examination	91.6*	3.64
*p<0.01 compared with baseline		
†p<0.01 compared with end of procedure		
<i>(b) During recovery</i>		
Start of recovery	91.9*	3.28
Minimum saturation	90.1*	3.58
End of recovery	93.9	2.45
*p<0.05 compared with end of recovery (Student's paired t test).		

reductions in oxyhaemoglobin saturation were noted in all patients (Table IVa). Four patients developed a SaO₂ of 80% or below. Of these four patients, two became apnoeic and required ventilatory support for a short time. Supplementary oxygen was given through nasal cannulae until SaO₂ was above 90%.

There were significant differences in saturation between baseline and the lowest value recorded during endoscopy (p<0.01) and also between the baseline and the value measured at the end of endoscopy (p<0.05). The difference between the end of the examination and the maximum desaturation was also significant (p<0.01).

DURING RECOVERY

Arterial oxygen saturation improved significantly from the beginning to the end of the recovery period (p<0.05, Table IVb). The lowest SaO₂ during the recovery phase was greater than the lowest SaO₂ recorded during endoscopy, but was significantly below the baseline level and the value obtained at the end of recovery. The maximum desaturation recorded during the recovery period was not significantly different from the start of recovery. There was no significant difference between saturations at baseline and the end of one hour recovery: however, at this point, 11 patients had still not recovered to their baseline levels.

The mean duration spent with oxyhaemoglobin saturation below baseline was 73.5 minutes (range 6–103 min) and time spent 5% or more below baseline was 9.1 minutes (range 1–33 min).

Discussion

Pulse oximetry has shown that desaturation can occur rapidly and can be profound (Figure). The present study has confirmed that hypoxaemia is precipitated by administration of sedative drugs and insertion of an endoscope into the upper gastrointestinal tract. Four patients developed arterial saturations below 80% which is approximately equivalent to an arterial PO₂ of 40 mmHg (5.32 kPa). The average minimum SaO₂ during endoscopy was 82.9% which corresponds to an arterial PO₂ of approximately 46 mmHg (6.12 kPa). The maximum drop in any individual patient was to 42%. We have also shown the persistence of hypoxaemia beyond the end of the procedure. The mean minimum SaO₂ during the recovery phase was 90.1% which corresponds to a PO₂ of 65 mmHg (8.64 kPa),

but one patient had a minimum saturation of 84% or 56 mmHg (7.45 kPa). Some patients remained below their baseline measurements more than one hour later. The problem of hypoxia therefore extends beyond the period of endoscopic examination and vigilance must be maintained during this time.

Clinical observation for physical signs of hypoxaemia are subjective, non-specific and unreliable.⁸ Observation of cyanosis and respiratory pattern can be made more difficult when ambient lighting is reduced to facilitate endoscopy.

Many previous studies of oxygenation during upper gastrointestinal endoscopy have relied on intermittent sampling of arterial blood.^{1-3,5} Analysis may take several minutes, require the services of a technician and important information may be missed in the periods between sampling. It is also impractical to consider arterial sampling for routine monitoring of patients undergoing endoscopy. Ear oximetry has also been used effectively to measure oxygen saturation, however, these instruments tend to be large and expensive. Pulse oximetry has been shown to be reliable and to provide an accurate measurement of haemoglobin oxygen saturation in critically ill patients over a wide range of arterial saturations.⁹

Sedation is used to facilitate endoscopy and render it more acceptable to the patient. Benzodiazepines are used commonly, sometimes in combination with an analgesic to achieve a state of tranquillity, amnesia, and cooperation. Zsigmond and his coworkers showed that intravenous diazepam given to healthy volunteers caused minimal changes in arterial PO_2 ,¹⁰ but the hypoxaemia became significant when the benzodiazepine was combined with an opioid analgesic. This effect was noted to be more marked when the studies were performed in groups of patients suffering from chronic obstructive pulmonary disease.¹¹

Intravenous midazolam has replaced diazepam in many units because of the potential advantages of shorter half life with rapid recovery, and lack of venous irritation and phlebitis. It has been shown that midazolam produces a slightly greater, but not statistically different, reduction in oxygen saturation than an equipotent dose of diazepam.¹² A recent study has confirmed that marked drops in oxygen saturation occur after the administration of midazolam and that these appeared to be related to reductions in respiratory rate and respiratory excursion.¹³ Further reductions in saturations were seen after the introduction of the endoscope which provoked gagging and coughing. The lowest mean oxygen saturation was 89% which is much higher when compared with the 82.9% in the present study. This difference between the studies is probably caused by the effect of pethidine.

Electrocardiographical changes have been observed concurrently with hypoxaemic episodes during endoscopic examination. They have been mainly premature ventricular beats and, in one case, slowing of ventricular response in a patient with atrial fibrillation.¹ These changes all reverted to pre-examination levels within one hour of the end of endoscopy.

Introduction of an endoscope has been shown to induce similar significant reductions in oxygen tension whether benzodiazepines are given or withheld.^{2,3} It was thought that partial obstruction of respiration after introduction of an endoscope, aspiration of gastric contents, ventilation perfusion inequality secondary to changes in autonomic tone or a combination of several of these factors contributed to this effect. A study by Lavies has shown that a greater reduction in oxygen saturation can be caused by an inexperienced endoscopist.⁴

More marked reductions in saturation were noted during endoscopy when the sedative action of the benzodiazepine was augmented with pethidine. Rozen and his colleagues have shown that the degree of hypoxaemia can be reduced with the use of short acting opioid drugs or the use of a narrow diameter paediatric endoscope.⁵ Furthermore, the combination of short acting opioid and narrow diameter endoscope was found to minimise the drop of arterial oxygen saturation during the examination.

Almost all previous studies of oxygenation during upper gastrointestinal endoscopy have shown that hypoxia occurs. A recent study has shown that hypoxia can be minimised by the administration of nasal oxygen during the procedure and recommend that supplementary oxygen be given to all elderly patients and particularly those with cardiovascular disease.¹⁴ Because non-invasive monitoring of oxygenation is now readily available and relatively inexpensive, it would appear mandatory to apply this technique when high risk patients are subjected to profound sedation and prolonged endoscopic examination. In the absence of pulse oximetry, we would vigorously endorse the view of Bell and his coworkers in recommending the administration of oxygen to these patients.¹⁴

Arterial saturation does not always continue to improve immediately after endoscopy and may decrease further when the patient is returned to the recovery area. It is important, therefore, to continue monitoring of oxygenation and oxygen therapy until the patient has recovered adequately.

We would like to thank the nursing staff of the endoscopy suite and recovery area of the Royal Infirmary for their cooperation and help.

- 1 Rostykus PS, McDonald GB, Albert RK. Upper intestinal endoscopy induces hypoxaemia in patients with obstructive pulmonary disease. *Gastroenterology* 1980; 78: 488-91.
- 2 Whorwell PJ, Smith CL, Foster KJ. Arterial blood gas tensions during upper gastro-intestinal endoscopy. *Gut* 1976; 17: 797-800.
- 3 Pecora AA, Chiesa JC, Alloy AM, Santoro J, Lazarus B. The effect of upper gastro-intestinal endoscopy on arterial oxygen tension in smokers and non-smokers with and without premedication. *Gastrointest Endosc.* 1984; 30: 284-8.
- 4 Lavies NG, Creasy T, Harris K, Hanning CD. Arterial oxygen saturation during upper gastrointestinal endoscopy: influence of sedation and operator experience. *Am J Gastroenterol* 1988; 83: 618-22.
- 5 Rozen P, Fireman Z, Gilat T. Arterial oxygen tension changes in elderly patients undergoing upper gastro-intestinal endoscopy II. Influence of the narcotic premedication and endoscope diameter. *Scand J Gastroenterol* 1981; 16: 299-303.
- 6 Rozen P, Fireman Z, Gilat T. The causes of hypoxaemia in elderly patients during endoscopy. *Gastrointest Endosc* 1982; 28: 243-6.
- 7 Jones G. Oxygen saturation during upper gastrointestinal endoscopy. *Br J Anaesth* 1986; 58: 807.

- 8 Neil SG, Lam AM, Turnbull KW, Tremper KK. Monitoring of oxygen. *Can J Anaesth* 1987; 34: 56-63.
- 9 Mihm FG, Halperin BD. Noninvasive detection of profound arterial desaturations using a pulse oximeter device. *Anesthesiology* 1985; 62: 85-7.
- 10 Zsigmond EK, Flynn K, Martinez OA. Diazepam and meperidine on arterial blood gases in healthy volunteers. *J Clin Pharmacol* 1974; 14: 377-81.
- 11 Zsigmond EK, Shively JG, Flynn K. Diazepam and meperidine on arterial blood gases in patients with chronic obstructive pulmonary disease. *J Clin Pharmacol* 1975; 15: 464-9.
- 12 Bell GD, Morden A, Coady T, Lee J, Logan RFA. A comparison of diazepam and midazolam as endoscopy premedication assessing changes in ventilation and oxygen saturation. *Br J Clin Pharmacol* 1988; 26: 595-600.
- 13 Bell GD, Reeve PA, Moshiri M, et al. Intravenous midazolam: a study of the degree of oxygen desaturation occurring during upper gastrointestinal endoscopy. *Br J Clin Pharmacol* 1987; 23: 703-8.
- 14 Bell GD, Bown S, Morden A, Coady T, Logan RFA. Prevention of hypoxaemia during upper-gastrointestinal endoscopy by means of oxygen via nasal cannulae. *Lancet* 1987; i: 1022-4.