

## Case report

# Silicone in the liver: possible late effects

J HUNT, M J G FARTHING, L R I BAKER, P R CROCKER,  
AND D A LEVISON

*From the Departments of Gastroenterology, Nephrology and Histopathology, St Bartholomew's Hospital, London*

**SUMMARY** We describe two renal transplant recipients who presented with clinical and biochemical abnormalities of liver function in whom liver scarring and silicone particles were identified in the liver by light microscopy. The presence of silicon in the particles was confirmed by x-ray energy dispersive spectroscopy. In one patient liver abnormalities were first noted more than two years after haemodialysis was discontinued and in a second patient abnormalities were still present more than four years after successful kidney transplantation. No other specific cause for the chronic liver abnormalities was determined and we consider that these may be related to the presence of silicone degradation products in the liver. Other patients haemodialysed using a siliconised peristaltic blood pump insert system may also be at risk of developing similar late complications.

Deposition of particles of silicone (an organosilicon oxide polymer) in the liver of haemodialysis patients was first described in the early 1980s.<sup>1-4</sup> The silicone was liberated from siliconised peristaltic blood pump inserts. After this discovery, pump inserts were gradually changed to polyvinyl chloride (PVC). There have not been any reports of late sequelae of silicone deposition. We report two cases with liver damage associated with the presence of silicone in the liver (confirmed by x-ray energy dispersive spectroscopy), one patient presenting some years after exposure to silicone through haemodialysis, and the other with persisting abnormalities of liver function four years after renal transplantation.

### Case histories

#### PATIENT 1

A Caucasian man with a solitary right pelvic kidney developed end stage renal failure in March 1977. He was treated with haemodialysis using cupraphane

membranes with a siliconised rubber insert in the peristaltic roller pump. A live related donor transplant was done in October 1977 and he was immunosuppressed with azathioprine and prednisolone. Several rejection episodes ensued which were treated with methylprednisolone. In 1980 azathioprine was discontinued and cyclophosphamide substituted because of epistaxes, bruising, anaemia and thrombocytopenia (Hb 7.0 g/dl, WBC 4.2, platelets 41 000). Graft function was satisfactory until January 1982 when the patient suffered an episode of pneumonia, during which immunosuppressive medication was stopped and an acute rejection episode developed. This was treated with intravenous steroids but he subsequently required haemodialysis in March 1982. At this time he was found to have splenomegaly, ascites and dilated anterior abdominal wall veins. Antibodies to hepatitis B virus (HBV) and cytomegalovirus (CMV) were not detected and auto-antibody screen was negative.

Biochemical tests of liver function had been abnormal from May 1980 (Alk phos 16 KA units; normal range (NR) 14-13; SGPT 48 IU/l; NR 0-14; SGPT 20 IU/l, NR 0-20; bilirubin 44 µmol/l, NR 13-18), and remained so until August 1982 at the

Address for correspondence: Dr M J G Farthing, Dept of Gastroenterology, St Bartholomew's Hospital, West Smithfield, London EC1A 7BE.

Accepted for publication 11 August 1988.

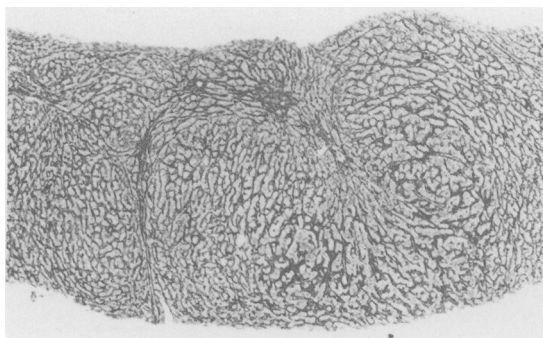


Fig. 1 Patient 1: liver biopsy showing tendency to nodule formation, a coarse irregular reticulin pattern (scarring) and paucity of central veins. Reticulin  $\times 40$ .

time of liver biopsy (bilirubin 12  $\mu\text{mol/l}$ ; SGOT 32 IU/l; Alk phos 124 IU/l; albumin 32 g/l). Oesophagogastrosocopy showed oesophageal varices.

Liver biopsy in August 1982 showed the appearance of a chronic active hepatitis with fibrosis partly dividing the parenchyma into nodules (Fig. 1). Granular refractile material was noted in macrophages in portal tracts, in Kupffer cells and in parenchymal giant cells (Fig. 2). This material could only be seen easily with the substage (condenser) diaphragm of the microscope closed. It did not take up routine stains and was shown by *x*-ray energy dispersive spectroscopy to consist almost entirely of silicon (see below).

Thus by 1982 the patient had chronic liver disease with portal hypertension. During the past five years he remained generally well but continued to have abnormal biochemical tests of liver function, chronic ascites and several variceal bleeds requiring intermit-

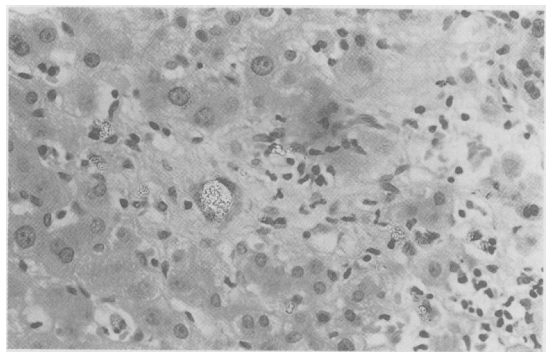


Fig. 2 Patient 1: liver biopsy showing refractile silicone particles (largest clump in giant cell left of centre) and scattered lymphocytes in a parenchymal scar. H and E  $\times 400$  with substage condenser closed.

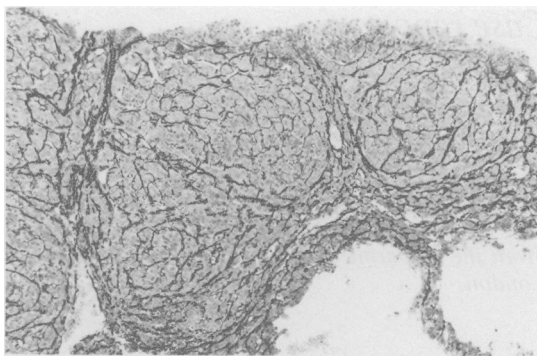


Fig. 3 Patient 2: liver biopsy showing an area of nodule formation and scarring. Reticulin  $\times 100$ .

tent endoscopic sclerotherapy. In March 1988 he presented with episodes of lethargy and confusion and was clearly suffering from hepatic encephalopathy. This was considered to be due primarily to portosystemic shunting as hepatocellular function remained remarkably good (serum albumin 30 g/l; prothrombin ratio 1.3).

#### PATIENT 2

A 29 year old man was found to have systemic hypertension. Investigations revealed chronic renal failure with reduced creatinine clearance (25 ml/min). Intravenous urogram showed calyceal irregularity consistent with bilateral reflux nephropathy. Hypertension was variously treated with clonidine 50  $\mu\text{g}$  three times daily, frusemide 40 mg once daily,  $\alpha$ -methyl dopa 250 mg twice daily and Cyclopentiazide K two tablets once daily. During this period he remained well but his renal function continued to

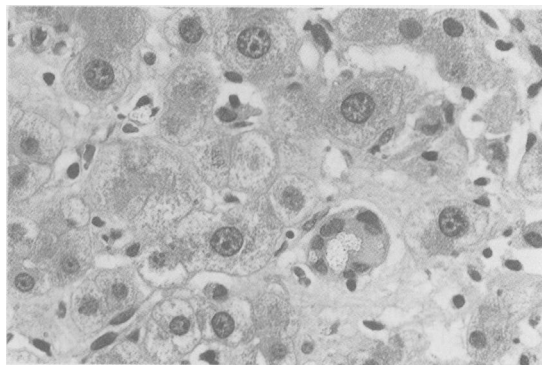


Fig. 4 Patient 2: liver biopsy showing silicone particles in a giant cell (below and right of centre) and a Kupffer cell above and left of centre. H and E  $\times 630$  with substage condenser closed.

deteriorate and in August 1978 he was started on haemodialysis, using a system identical to that used for patient 1. He underwent parathyroidectomy and forearm implantation of parathyroid tissue in 1981.

In February 1984 he received a cadaver renal transplant and was immunosuppressed with azathioprine and prednisolone. Seven days after grafting he developed an acute rejection episode which was treated with intravenous steroids. At the time of surgery and for the month thereafter his liver function tests remained normal. In April 1984, however, he developed a pyrexia, splenomegaly and hepatomegaly. Alkaline phosphatase and SGOT were raised (385 IU/l and 180 IU/l, respectively) and serum albumin was reduced at 28 g/l. Blood cultures were negative as was the initial viral antibody screen. Nine days after admission serum cytomegalovirus (CMV) IgG titre increased eightfold, and the presence of specific anti-CMV IgM was also detected. CMV was isolated from the urine. His clinical condition improved during the following month, as did the liver function tests with marked reduction in the SGOT (52 IU/l although alkaline phosphatase (379 IU/l) and serum albumin (29 g/l) were unchanged. Immunosuppressive drugs were continued throughout and hypertension was controlled with a thiazide diuretic in combination with atenolol. Liver function tests, however, never returned to normal and in September 1986 both alkaline phosphatase (180 IU/l) and SGOT (92 IU/l) remained raised. Examination at that time revealed hepatosplenomegaly. No antibodies to nuclei, smooth muscle and mitochondria were detected. Markers for hepatitis B virus infection and hepatitis A virus serology were negative. Cytomegalovirus titres continued to be positive at 1:1024. Abdominal ultrasound showed a normal liver and biliary tract, but an enlarged spleen measuring 21 cm in length.

A needle biopsy of liver at this time showed virtually no inflammation, but fine scarring partly dividing the parenchyma into nodules (Fig. 3) and similar refractile material to that seen in patient 1 in macrophages in portal tracts, Kupffer cells, macrophages and giant cells in the parenchyma (Fig. 4). The refractile material was again analysed by *x*-ray energy dispersive spectroscopy and shown to be silicon (see below). Immunoperoxidase stains using known CMV positive human serum as antibody, and *in situ* DNA hybridisation failed to show any evidence of CMV infection in the biopsy material.

#### MICROANALYTICAL TECHNIQUES AND RESULTS

Haematoxylin and eosin stained paraffin sections containing refractile material were carefully photographed. The coverslip was then removed in xylene and the section was coated with carbon in a Nanotech

CC2 carbon coater. As silicon is present in glass, the sections were transferred from glass slides to perspex slides (negative on *x*-ray energy dispersive spectroscopy) as described previously.<sup>5</sup> Sections were examined in a JEOL 35 CF scanning electron microscope fitted with a backscattered electron detector, a Kevex Unispec System 7000 *x*-ray energy dispersive spectroscopy analytical unit, and a Dapple Microplus data processor.

The photographed area was located in the secondary electron image and the granular material visualised in the backscattered electron image which identifies particles of different atomic weight to the background material. The particles were then analysed by *x*-ray energy spectroscopy at 25 kv for period of 100 seconds. All such particles in both cases gave strong readings for silicon only. The organic elements with which silicon is combined in silicone are not detected by our apparatus.

#### Discussion

Abnormalities of liver function in patients with chronic renal failure are not uncommon.<sup>1</sup> Drugs, alcohol, iron overload and infective agents (particularly the hepatitis viruses) are all well established causes of liver damage in patients with chronic renal failure, but there remains a group in whom the cause of liver damage is obscure. It was in this group of patients that refractile particles of silicone derived material were first noted in liver biopsies.<sup>1-4</sup> Abnormalities of liver structure and function were ascribed to this material.<sup>3</sup> As a result of this observation, the use of silicone (an organosilicon oxide polymer which increases the flexibility of PVC tubing) in the peristaltic blood pump insert was abandoned in new pumps. We understand, however, that silicone pump inserts may still be used in some centres.

The longterm sequelae of the presence of silicon particles in the liver are still not known. Silicon particles are likely to stay in the liver for a long time as they are not degraded by lysosomal enzymes.

Definite physical changes do occur in all types of implanted silicone rubber as a result of aging.<sup>6</sup> It is of interest, and perhaps some importance, that one of our patients developed liver abnormalities several years after stopping haemodialysis; this is compatible with an effect of particulate silicone. It has been shown that silicone prostheses do sometimes decay and that the degradation products can set up an inflammatory reaction.<sup>7\*</sup> These silicone particle degradation products may therefore be responsible for the late onset of liver disease. Other possible causes of chronic liver damage have been excluded as far as is possible in both our cases. Serological

markers for HAV and HBV were both negative although we cannot exclude the possibility that they have non-A, non-B hepatitis. Although patient 2 clearly had acute CMV hepatitis we were unable to find any evidence of chronic CMV infection either morphologically, immunohistochemically or with the application of *in situ* hybridisation techniques. Yet both patients have clinical, histological and biochemical evidence of persistent, relatively non-progressive chronic liver damage associated with the presence of silicone particles in the liver. Patient 1 raises an interesting possibility that the primary effect of silicone is to cause hepatic fibrosis with portal hypertension, perhaps like schistosomiasis, with relatively little hepatocellular damage. Providing variceal bleeding can be controlled, management is fairly straightforward until portosystemic shunting supervenes with resulting encephalopathic episodes.

This study confirms that silicone particles persist in the liver for some years. Patient 2 for example, was biopsied in 1986 and had not been dialysed with silicone containing apparatus since 1984. As it is suspected that silicone degradation products can evoke an inflammatory reaction,<sup>7</sup> perhaps all patients who were/are dialysed with silicone containing system are at longterm risk of liver damage. Silicone will only be recognised in biopsies if pathologists think of the possibility of its presence and then close their substage (condenser) diaphragms, as the material is virtually invisible with the microscope set up for normal use.

MJGF is a Wellcome Trust Senior Lecturer, and gratefully acknowledges financial support by the Wellcome Trust. We thank Joanne Fitzgerald and Gillian Taylor for excellent photographic and secretarial assistance respectively, and Mr Colin Aldridge for expert technical advise on haemodialysis pump inserts.

#### References

- 1 Leong AS, Disney APS, Grove DW. Refractile particles in liver of haemodialysis patients. *Lancet* 1981; i: 889-90.
- 2 Bonmer J, Ritz E, Waldherr R, Gastner M. Silicone cell inclusions causing multi-organ foreign body reaction in dialysed patients. *Lancet* 1981; i: 1314.
- 3 Leong AS. Silicone - a possible iatrogenic cause of hepatic dysfunction in haemodialysis patients. *Pathology* 1983; 15: 193-5.
- 4 Leong AS, Disney APS, Grove DW. Spallation and migration of silicone from blood pump tubing in patients with haemodialysis. *N Engl J Med* 1982; 306: 135-40.
- 5 Crocker PR, Toulson E, Levison DA. Particles in paraffin sections demonstrated in the Backscattered Electron Image (BEI). *Micron* 1982; 13: 437-46.
- 6 Roggendorf E. The biostability of silicone rubbers, a polyamide and a polyester. *J Biomed Mater Res* 1976; 10: 123-43.
- 7 Christie AJ, Weinberger KA, Deitrich M. Silicone lymphadenopathy and synovitis: complications of silicone elastomer finger joint prosthesis. *JAMA* 1977; 237: 1463-4.
- 8 St C Symmers W. Silicone mastitis in 'topless' waitresses and some other varieties of foreign-body mastitis. *Br Med J* 1968; 3: 19-22.