

## ALIMENTARY TRACT

## Spontaneous intramural rupture of the oesophagus

C Steadman, P Kerlin, F Crimmins, J Bell, D Robinson, L Dorrington, A McIntyre

## Abstract

The clinical, endoscopic, and radiological features of seven patients with an uncommon oesophageal injury characterised by long lacerations of the oesophageal mucosa with haematoma formation but without perforation are reported. The injuries were not related to forceful vomiting or any other definable cause but were similar to those previously described as intramural oesophageal rupture. Upper gastrointestinal endoscopy undertaken to identify the cause of haematemesis in six patients proved safe and useful. When dysphagia and odynophagia occurred early in the clinical course to alert the clinician to possible oesophageal injury, radiological contrast studies were used to exclude perforation. One patient in this study had oesophageal cavernocapillary haemangiomas which may have caused intramural oesophageal bleeding and submucosal dissection but in the remainder the aetiology of intramural oesophageal rupture remains uncertain. Conservative management was successful in all patients.

Oesophageal injury is high in the differential diagnosis of patients who have chest pain and haematemesis after forceful vomiting, oesophageal instrumentation, or ingestion of a foreign body. If chest pain precedes the onset of haematemesis, however, and there is no history of a potential cause, oesophageal injury may be dif-

ficult to diagnose. This diagnostic difficulty may be increased when chest pain of oesophageal origin mimics that of myocardial infarction or aortic dissection. We report the clinical features of seven patients who had chest or epigastric pain and subsequently haematemesis caused by an unusual type of oesophageal injury that occurred without any definable causes.

The oesophageal injury in these patients was characterised by long lacerations of the oesophageal mucosa with bruising and haematoma formation but without perforation. These lesions had similar features to a group previously classified as intramural oesophageal rupture.<sup>1,2</sup> As there was no reason to suspect oesophageal perforation and because haematemesis was the most important early management problem, upper gastrointestinal endoscopy was used to make the final diagnosis in all patients in this study. The use of endoscopy was not complicated by any morbidity resulting from the procedures.

## Methods

The seven patients studied were seen by the authors at four southern Queensland hospitals between 1984 and 1988. Patients were included if they had a major oesophageal injury diagnosed in the absence of an oesophageal perforation, oesophageal instrumentation, or an ingested foreign body. Those with a diagnosis of Mallory-Weiss tear were excluded. The clinical features of each patient's diagnosis, management, and outcome were determined retrospectively from clinical, radiological, and procedural records. Patients were also contacted and asked about residual symptoms after the acute injury had resolved.

## Results

## CLINICAL PRESENTATION

All seven patients were women with a mean age of 65.3 years (range 51-76 years). The symptoms of these patients before and at the time of presentation are shown in Table I. Except in one patient who had an episode of haematemesis eight days before presentation, the complaints that preceded oesophageal injury gave no warning that the injury might occur.

At presentation five of the patients gave a history of severe central chest pain which they could not relate to ingestion of a meal or alcohol, strenuous exercise, or any other potential cause.

Department of  
Gastroenterology,  
Princess Alexandra  
Hospital, Queensland,  
Australia  
C Steadman  
P Kerlin  
A McIntyre  
L Dorrington

Department of  
Gastroenterology,  
Mater Misericordiae  
Hospital, Queensland,  
Australia  
J Bell  
F Crimmins

Correspondence to:  
Dr P Kerlin, Princess  
Alexandra Hospital, Ipswich  
Road, Brisbane, Queensland,  
Australia, 4102

Accepted for publication  
5 October 1989

TABLE I Clinical features of patients with spontaneous intramural oesophageal rupture

Patient	Antecedent symptoms	Acute symptoms	Oesophageal radiology	Endoscopy
1	Dyspepsia	Central chest pain (4-5 h)	Left lateral mid to distal tear, intramural dissection	Luminal blood clot, superficial tear mid to distal oesophagus, extensive bruising
2	Episodic chest pain	Central chest pain (30 min)	Nil	Long oesophageal intramural haematoma
3	Chest pain once (brief)	Central chest pain (1 h)	Nil	Gaping oesophageal tear 30-39 cm*
4	Heartburn/dyspepsia	Epigastric pain and haematemesis	Nil	Oesophageal tear 18-30 cm* Hiatus hernia 30-40 cm*
5	Haematemesis	Odynophagia, dysphagia (8 days)	Normal in 2 studies	Oesophageal tear 20-40 cm* with a granulating base
6	Heartburn/dyspepsia	Central chest pain (2 h)	Nil	Oesophageal tear 30-36 cm*, blood clot, oesophagitis above hiatus hernia 38 cm*
7	Sensation of 'lump' in throat	Central chest pain (1.5 h)	Oesophageal dilation above haematoma	Oesophageal tear 20-40 cm* with large intramural haematoma

\* Distance from the incisors at endoscopy.

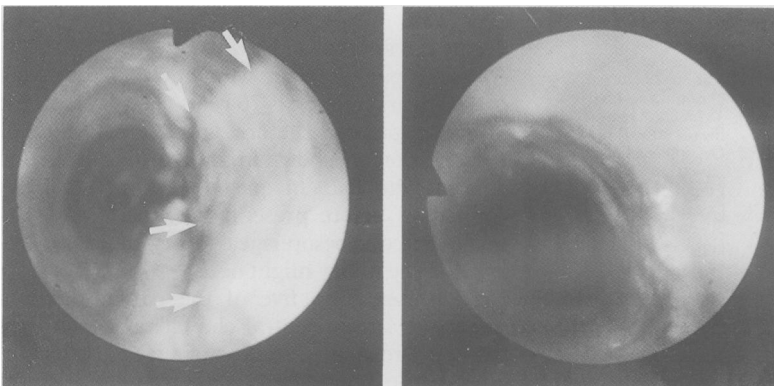
In particular, none of these five could relate the onset of pain to vomiting. No history of using medications such as doxycycline, aspirin, or anticoagulants which could have caused mucosal injury or haemorrhage was recorded. The histories were judged to be reliable as none of these patients were alcoholics or confused. Most of the patients thought they were having a 'heart attack'. In the remaining two patients, including one with epigastric pain, the relation between vomiting (including haematemesis) and pain was uncertain.

Initially, cardiovascular emergencies such as myocardial infarction and aortic dissection seemed to be the most likely diagnoses in the patients with chest pain but physical examinations, electrocardiograms, and chest x rays were normal. Haematemesis occurred later, 30 minutes to five hours after the onset of pain. Because of the disparity between the onset of chest pain and the later onset of haematemesis and because there was no history of vomiting or any other potential cause of oesophageal injury, it was not apparent early in the clinical course of these patients that the chest pain and bleeding shared a common oesophageal origin. In the patient with epigastric pain and haematemesis, a gastroduodenal lesion seemed to be more likely. All six of these acutely ill patients went on to develop odynophagia and dysphagia between 1.5 and five hours after the onset of other symptoms. In the other patient, who presented eight days after an episode of haematemesis, the presence of odynophagia and dysphagia clearly indicated an oesophageal lesion.

#### INVESTIGATIONS – ENDOSCOPY

Investigation of the cause of haematemesis was the highest clinical priority after the initial patient assessments did not show any evidence of cardiovascular disease. Upper gastrointestinal endoscopy was the first investigation for haematemesis used in all six acutely ill patients. In the patient who had the most rapid onset of dysphagia (1.5 hours) an attempt at endoscopic examination of the oesophagus failed due to blood welling up into the posterior pharynx. Barium contrast x rays of the oesophagus were taken before a second endoscopy was used to make the final diagnosis. The patient who presented late (eight days) and with dysphagia had endoscopy performed after barium studies.

*Figure 1: Endoscopic photographs of the oesophagus (patient 5, Table I) showing, (left) intramural rupture (arrows) and (right) resolution. Long mucosal lacerations and intramural haematomas in the mid-oesophagus are the characteristic features of intramural oesophageal rupture.*

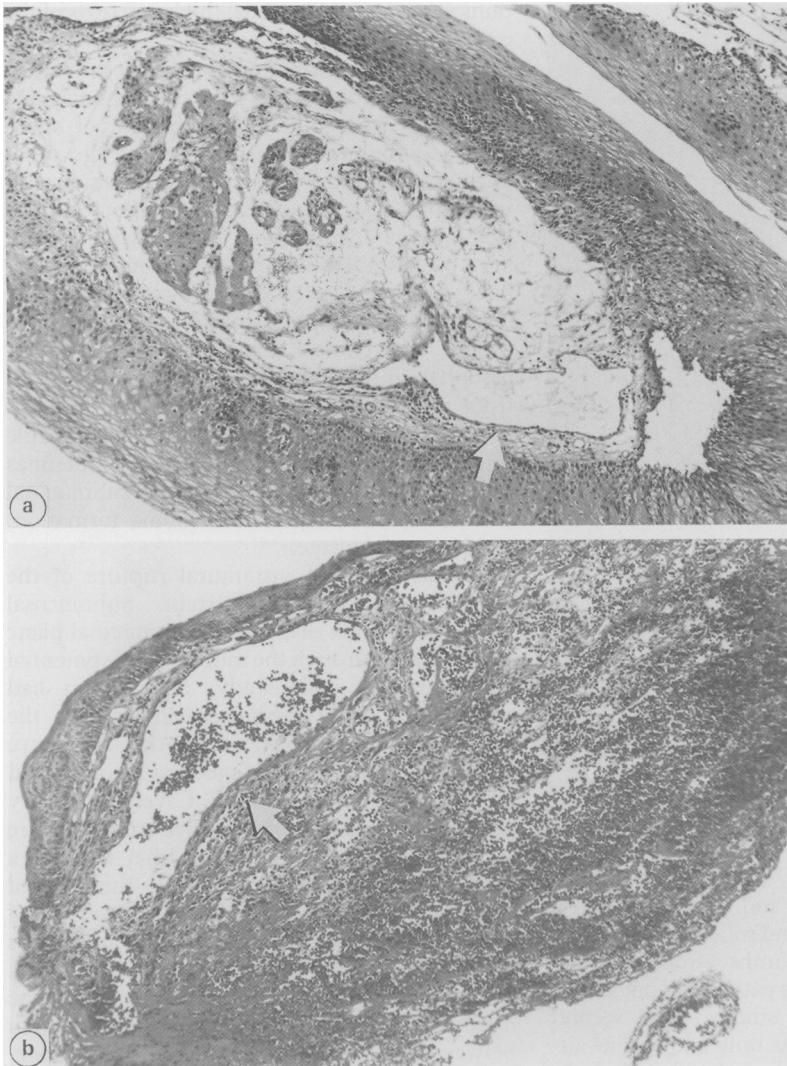


The principal findings at endoscopy (Table I) were (1) high localisation of lesions away from the gastro-oesophageal junction, (2) striking length of mural disruption of the oesophagus (from the cricopharyngeal region to the distal oesophagus in four patients) with obvious mucosal laceration (Fig 1), and (3) prominence of mural bruising and haematoma formation complicated by various degrees of narrowing of the oesophageal lumen. These findings allowed the endoscopists to distinguish the lesions from Mallory-Weiss tears. Although clotted blood obscured the base of the tear in some patients, no transmural rupture (perforation) was detected. No patient had complications as a result of the endoscopic examination, and insufflation of air into the oesophagus did not cause subcutaneous emphysema or the appearance of mediastinal gas on subsequent chest x rays. Biopsy specimens were taken from around the site of injury in one patient where the mucosal disruption could not be distinguished from a malignancy by the endoscopist. The specimens showed extensive cavernocapillary haemangiomas of the lamina propria and submucosa with obvious haemorrhage present (Fig 2). Specimens from the area of oesophageal injury and macroscopically unaffected mucosa showed the histological abnormality.

#### INVESTIGATIONS – RADIOLOGY

Chest x rays were normal in all patients. Three patients had radiological contrast studies of the oesophagus. In the patient in whom an initial attempt at endoscopy was unsuccessful, a barium swallow showed dilatation of the oesophageal lumen above a mass that was causing anteroposterior compression and rightward displacement of the oesophagus at the level of the aortic arch (Fig 3). The mass seemed to be a mediastinal tumour or aneurysm of the aortic arch but a second endoscopy showed that the mass effect was due to a large intramural haematoma of the oesophagus rather than an extrinsic lesion.

In the second patient, who was later shown to have cavernocapillary haemangiomas of the oesophageal mucosa and submucosa, a Gastrografin (meglumine diatrizoate) swallow was done after endoscopy to exclude the possibility of oesophageal perforation. These x rays showed an extensive left-sided anterolateral oesophageal tear from 3 cm above the gastro-oesophageal junction up to the level of the left main bronchus; in addition, there was intramural spread of contrast caused by intramural dissection of the oesophagus (Fig 4). The third patient who had contrast studies was the patient who presented late, eight days after an episode of haematemesis. A barium study had been done within 24 hours of the haematemesis but was interpreted as being normal and consequently the patient was not referred for hospital care until dysphagia and odynophagia had persisted for over a week. A second barium study at the time of presentation was also interpreted as normal but endoscopy showed a long healing laceration of the oesophageal mucosa.

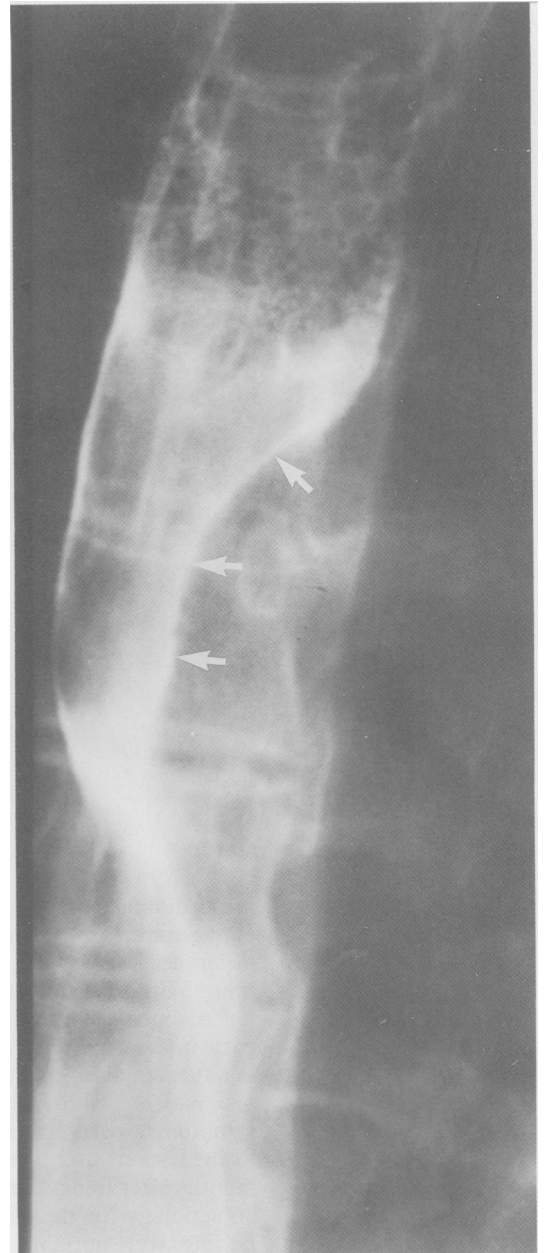


**Figure 2:** (a) Oesophageal mucosa (patient 1, Table I); large (arrow) and small thin walled vascular channels are immediately below the squamous epithelium at a site remote from the tear. Thicker walled vessels are present in the centre of the field in relation to muscularis mucosa. (Haematoxylin and eosin x 480: final magnification.)  
 (b) Oesophageal tissue (patient 1, Table I) with extensive disruptive submucosal haemorrhage which is closely related to the abnormal ectatic vascular channels (arrow). (Haematoxylin and eosin x 480: final magnification).

#### MANAGEMENT AND OUTCOME

Three patients with chest pain at presentation were treated with sublingual glyceryl trinitrate without any response. Two of these and one other were given morphine intravenously until pain was controlled. All six acutely ill patients had all oral intake ceased and were given intravenous fluids but as none were either haemodynamically compromised or had haemoglobin concentrations less than 11 g/dl, none were transfused. After the diagnoses were made all patients were treated conservatively. The early clinical course was characterised by moderate central chest and epigastric discomfort, odynophagia and dysphagia. Five patients had an intermittent fever and a blood leucocytosis but only two received antibiotic treatment (cefotaxim; penicillin/gentamicin/metronidazole). The fevers resolved in all cases over two to nine days (mean (SE) 5.8 (1.4)). Histamine H<sub>2</sub> antagonist drugs were administered empirically in six patients as prophylaxis against worsening of the injury by gastro-oesophageal reflux.

When symptomatic recovery and resolution of fever had occurred normal diets were gradually

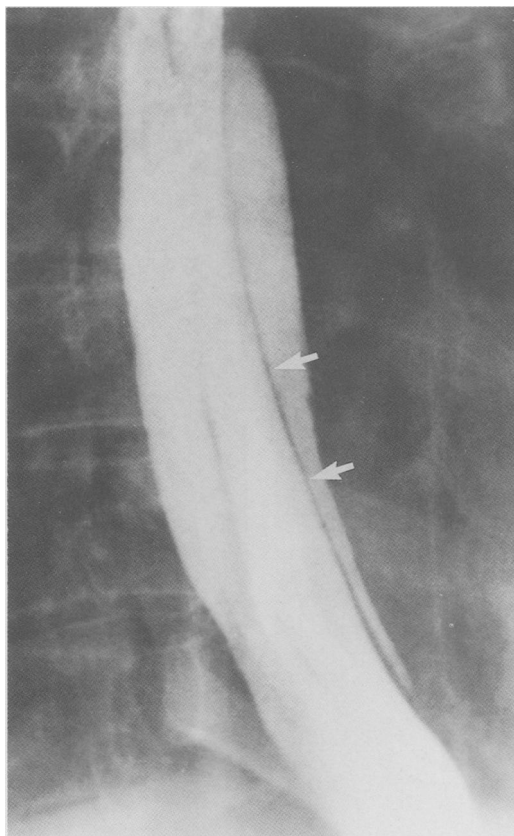


**Figure 3:** Barium swallow (patient 7, Table I) showing dilatation of the proximal oesophagus above a long narrowing of the lumen from the aortic arch distally. The stenosis was produced by a long left-sided intramural oesophageal haematoma (arrows) shown at endoscopy.

resumed but the patient with the very large intramural oesophageal haematoma (initially thought to be a mediastinal tumour – see radiology) had total parenteral nutrition for 10 days. The six acutely ill patients who had been admitted to hospital were discharged after four to 19 days (mean (SE) 10.7 (2.1)). Complete healing of the lesions, as judged by endoscopic examination in five patients, occurred between 14 and 44 days (mean (SE) 31.4 (5.7)) but these times may have reflected the arbitrary timing of examinations rather than true healing periods. The oesophageal tears typically developed a thin surface exudate then progressively healed but areas of submucosal haematoma tended to ulcerate before resolving.

At the last follow up interview (two months to 2.5 years after the injury), two patients had persistent dysphagia. One of these had a noticeably abnormal barium swallow that showed

Figure 4: Gastrografin swallow (patient 1, Table I) showing a narrow line of mucosa (arrows) separating the main column of contrast in the oesophageal lumen from the collection of contrast in the oesophageal wall. This appearance was due to intramural dissection of the oesophagus.



incoordinate contractions and slow passage (up to five minutes) of liquid and solid contrast in the lower oesophagus 4-5 months after the acute injury. Unfortunately, this patient did not attend for oesophageal motility studies. The second patient had mild dysphagia only and was awaiting further assessment at another hospital. In one patient, who had complete resolution of symptoms, oesophageal manometry was performed soon after the lesion had healed (1.5 months after injury) in an attempt to determine an aetiology for the lesion but the manometric findings were normal.

### Discussion

Intramural rupture of the oesophagus is the third distinct pattern of oesophageal injury after the Mallory-Weiss tear<sup>3</sup> and so-called spontaneous rupture of the oesophagus or Boerhaave's syndrome,<sup>4</sup> both of which occur after vomiting (Table II). Extensive idiopathic disruption of the oesophageal wall without perforation was first observed in radiological studies which showed superficial extraluminal spread of barium, what seemed to be a double oesophageal lumen, and bulging mucosal irregularities. These observa-

tions were caused by partial thickness tears of the oesophageal wall, submucosal dissection, and submucosal haematomas respectively.<sup>5-7</sup> Oesophageal apoplexy was the name then coined to describe the sudden development of spontaneous submucosal haematomas of the oesophagus which had some features in common with intramural oesophageal rupture.<sup>8</sup> Direct surgical descriptions of intramural oesophageal rupture have been limited because conservative management has been successful. However, the only documented oesophagectomy specimen<sup>7</sup> confirmed the clinical diagnosis of intramural oesophageal dissection that seemed to originate from a mucosal laceration. Operative findings in other patients have included appreciable thickening of the oesophageal wall sometimes associated with a clear plane of submucosal dissection, oesophageal haematoma formation, and mucosal damage.<sup>2,9-12</sup>

The aetiology of intramural rupture of the oesophagus remains uncertain. Submucosal haemorrhage that dissects the submucosal plane and ruptures through the mucosa is one potential mechanism. In this study, one patient had caverno-capillary haemangiomas of the lamina propria and submucosa that may have potentially caused the submucosal bleeding and dissection that was observed. Caverno-capillary haemangiomas is a descriptive term for a rare and poorly documented lesion that features a noticeable increase in thick and thin walled vascular channels in the lamina propria and submucosa. The histological appearance is analogous to that of arteriovenous malformation and ecstatic vascular channels may attenuate the overlying mucosa. There was a close relation between the channels and disruptive haemorrhage, although the abnormality also affected areas of the oesophagus that were macroscopically normal. Extensive sudden intramural haematoma formation has also been documented in patients who have thrombocytopenia<sup>11,13</sup> or haemophilia<sup>14</sup> and in patients treated with anti-coagulants or haemodialysis.<sup>2,15-18</sup> Haemorrhagic dissection of the submucosa has previously been shown in patients without a coagulopathy.<sup>2,19</sup>

Vomiting has also been associated with intramural rupture of the oesophagus.<sup>7,10,19-21</sup> The assertion that this lesion is simply an intermediate injury between the Mallory-Weiss tear and oesophageal perforation, however, is not supported by the lack of vomiting in many patients or the anatomical changes seen with this injury. In this study, the patients were elderly women who seemed to be reliable historians, and not alcoholics who might have forgotten episodes of forceful vomiting. We observed long and extensive lesions but haematomas associated with Mallory-Weiss tears are small and mostly located in the region of the tear.<sup>22</sup> In Boerhaave's syndrome and in experimental lesions produced in cadavers by increasing intraoesophageal pressure,<sup>23-26</sup> perforations are most frequently localised to the distal left lateral oesophagus.

An abnormal swallowing mechanism may be another aetiology, as some patients have had the onset of pain during drinking<sup>8,27</sup> and eating<sup>2,9,11,20,27</sup> but in many patients, as we have found, there is no indication of the cause.<sup>2,11,27-29</sup>

TABLE II Classification and outcome of acute oesophageal injury

	Mallory-Weiss tear	Boerhaave's syndrome	Intramural rupture
Aetiology	Forceful vomiting	Forceful vomiting	?
Presentation	Haematemesis	Chest pain	Chest pain
Later symptoms	—	Sepsis	Haematemesis
Depth of lesion	Mucosal	Transmural	Dysphagia, odynophagia
Length of lesion	Short, distal	Short, distal	Intramural
Management	Conservative	Surgery	Long
Prognosis	Good	High mortality	Conservative
			Good

Diagnosis of intramural rupture of the oesophagus can be made safely using upper gastrointestinal endoscopy but if symptoms such as dysphagia or odynophagia are present to give some warning that an oesophageal injury has occurred, then radiological contrast studies should be done first to exclude perforation. As observed in this study, such warning is commonly absent. Others have also found endoscopy to be safe in the diagnosis of this lesion.<sup>30</sup> Contrast studies can be expected to correlate well with endoscopic observations<sup>2, 8-10, 20</sup> but the choice of radiological contrast agent remains a subject of debate.<sup>31</sup> These studies have led to terms such as the 'double-barrelled' oesophagus<sup>7</sup> and the 'mucosal stripe' sign<sup>32</sup> which describe the appearances produced by intramural dissection. Computer tomography of the thorax has also been useful in diagnosing this injury<sup>33, 34</sup> and may facilitate early diagnosis of other mediastinal mass lesions included in the differential diagnosis of intramural haematoma of the oesophagus.

Intramural rupture of the oesophagus has a good prognosis and is best managed conservatively.<sup>35, 36</sup> Oral intake can be judiciously commenced with fluids when fever has resolved and odynophagia and dysphagia are improving. We have observed resolution of fever regardless of antibiotic treatment and at present the role of antibiotics remains uncertain when a low grade fever is the only clinical indication for their use. Treatment given to minimise gastrooesophageal reflux is also of uncertain benefit but in view of the extensive luminal exposure of the submucosa and sometimes the oesophageal muscle layers, the oesophagus is likely to be more vulnerable than normal to damage by acid and pepsin. Thoracotomy and mediastinal drainage offer no therapeutic advantage<sup>2, 9-12</sup> and oesophagectomy has resulted in death.<sup>7</sup>

The authors thank Drs J Sampson, J Harper, K Hourigan, P Walsh, and M Neely for access to clinical and radiological data used in this study.

- 1 Marks IN, Keet AD. Intramural rupture of the oesophagus. *Br Med J* 1968; 3: 536-7.
- 2 Kerr WF. Spontaneous intramural rupture and intramural haematoma of the oesophagus. *Thorax* 1980; 35: 890-7.
- 3 Weiss S, Mallory GK. Lesions of the cardiac orifice of the stomach produced by vomiting. *JAMA* 1932; 98: 1353-5.
- 4 Bradley SL, Pairolo PC, Payne S, Gracey DR. Spontaneous rupture of the oesophagus. *Arch Surg* 1981; 116: 755-8.
- 5 Williams B. Oesophageal laceration following remote trauma. *Br J Radiol* 1957; 30: 666-8.
- 6 Benjamin B, Hanks TJ. Submucosal dissection of the oesophagus due to haemorrhage. A new radiographic finding. *J Laryngol Otol* 1965; 79: 1032-8.
- 7 Thompson NW, Ernst CB, Fry WJ. The spectrum of emetogenic injury to the oesophagus and stomach. *Am J Surg* 1967; 113: 13-26.
- 8 Talley NA, Nicks R. Spontaneous submucosal haematoma of the oesophagus: 'oesophageal apoplexy'. *Med J Aust* 1969; 2: 146-50.
- 9 Borrie J, Sheat J. Spontaneous intramural oesophageal perforation. *Thorax* 1970; 25: 294-300.
- 10 Kelley DL, Neugebauer MK, Fosberg RG. Spontaneous intramural oesophageal perforation. *J Thorac Cardiovasc Surg* 1972; 63: 504-8.
- 11 Shay SS, Berendson RA, Johnson LF. Oesophageal haematoma. Four new cases, a review and a proposed etiology. *Dig Dis Sci* 1981; 26: 1019-24.
- 12 Biagi G, Capelli G, Propersi L, Grossi A. Spontaneous intramural haematoma of the oesophagus. *Thorax* 1983; 38: 394-5.
- 13 Ashman FC, Hill MC, Saba GP, Diaconis JN. Oesophageal haematoma associated with thrombocytopenia. *Gastrointest Radiol* 1978; 3: 115-8.
- 14 Oldenburger D, Gundlach WJ. Intramural oesophageal haematoma in a haemophiliac. *JAMA* 1977; 237: 800.
- 15 Arefi D, Horney JT, Eaton SB, Shulman M, Whaley W, Galambos JT. Spontaneous intramural haematoma of the oesophagus. *Gastrointest Endosc* 1978; 24: 172-4.
- 16 Snyder N, Patterson M, Hughes WS. Oesophageal haematoma. *South Med J* 1973; 66: 1079-80.
- 17 Andress M. Submucosal haematoma of the oesophagus due to anticoagulant therapy. *Acta Radiol Diagn* 1971; 11: 216-9.
- 18 Smart RF, Stone AR. Intramural oesophageal haematoma complicating anticoagulant therapy. *NZ Med J* 1978; 87: 176-7.
- 19 Joffe N, Millan VG. Postemetic dissecting intramural haematoma of the oesophagus. *Radiology* 1970; 95: 379-80.
- 20 Smith G, Gillanders LA, Brunnen PL, Teo HS. Oesophageal apoplexy. *Lancet* 1974; i: 390-2.
- 21 McMyn JK. Spontaneous intramural oesophageal perforation. *Aust Radiol* 1977; 21: 234-40.
- 22 Watts HD. Postemetic haematomas. A variant of the Mallory-Weiss syndrome. *Am J Surg* 1976; 132: 320-1.
- 23 Abbott OA, Mansour KA, Logan WD, Hatcher CR, Symbas PN. Atraumatic so-called 'spontaneous' rupture of the oesophagus. *J Thorac Cardiovasc Surg* 1970; 59: 67-83.
- 24 Mackler SA. Spontaneous rupture of the oesophagus. An experimental and clinical study. *Surg Gynecol Obstet* 1952; 95: 345-56.
- 25 Brackney EL, Campbell GS, Thal AP, Wangenstein OH. Spontaneous perforation of the oesophagus; experimental study. *Proc Soc Exp Biol* 1955; 88: 307-10.
- 26 Kinsella TJ, Morse RW, Hertzog AJ. Spontaneous rupture of the oesophagus. *J Thorac Surg* 1948; 17: 613-31.
- 27 Spiller RC, Catto JV, Kane SF. Spontaneous dissecting intramural haematoma of the oesophagus: a rare cause of haematemesis and dysphagia. *Endoscopy* 1981; 13: 128-30.
- 28 Morrill GN, Walbaum PR. Spontaneous dissection of the oesophagus. *Thorax* 1980; 35: 898-900.
- 29 Girdwood AH, Silber W, Kottler RE, Alexander MG, Marks IN. Intramural rupture of the oesophagus. *S Afr Med J* 1981; 60: 695-8.
- 30 Ou Tim L, Segal I, Mirwis J. Intramural haematoma of the oesophagus. The role of endoscopy. *S Afr Med J* 1982; 61: 798-900.
- 31 James AE, Montali RJ, Chaffee V, Strecker EP, Vessal K. Barium or gastrografin: which contrast media for diagnosis of oesophageal tears? *Gastroenterology* 1975; 68: 1103-13.
- 32 Lowman RM, Goldman R, Stern H. The roentgen aspects of intramural dissection of the oesophagus. *Radiology* 1969; 93: 1329-31.
- 33 Demos TC, Okrent DH, Studlo JD, Flisak ME. Spontaneous oesophageal haematoma diagnosed by computed tomography. *J Comput Assist Tomogr* 1986; 10: 133-5.
- 34 Schweiger F, Depew WT. Spontaneous intramural oesophageal haematoma. Diagnosis by C.T. scanning. *J Clin Gastroenterol* 1987; 9: 546-8.
- 35 Barone JE, Robilotti JG, Comer JV. Conservative treatment of spontaneous intramural perforation (or intramural haematoma) of the oesophagus. *Am J Gastroenterol* 1980; 74: 165-7.
- 36 Yeoh NT, McNicholas T, Rothwell-Jackson RL, Goldstraw P. Intramural rupture and intramural haematoma of the oesophagus. *Br J Surg* 1985; 72: 958-60.