

Pancreaticobiliary ductal union

S P Misra, M Dwivedi

Abstract

The main pancreatic duct and the common bile duct open into the second part of the duodenum alone or after joining as a common channel. A common channel of >15 mm (an anomalous pancreaticobiliary duct) is associated with congenital cystic dilatation of the common bile duct and carcinoma of the gall bladder. Even a long common channel (≥ 8 mm) is associated with a higher frequency of carcinoma of the gall bladder. Gall stones smaller than the common channel and a long common channel predispose to gall stone induced acute pancreatitis. Separate openings for the two ductal systems predisposes to development of gall stones and alcohol induced chronic pancreatitis. The role of ductal union has also been investigated in primary sclerosing cholangitis and biliary atresia.

The anatomy of the distal ends of the common bile duct and the main pancreatic duct has received attention because of its importance in pancreaticobiliary diseases (Table I). The two ducts open in the duodenum either separately or via a common channel. In the pre-endoscope era, a common channel was noted in 20-90% of the general population at necropsy and in 7-50% by cholangiography.¹ In a later study a common channel was found in 74% of specimens, 7% of which had interposed septum and 19% separate openings for the two ducts.² Another necropsy study noted separate ducts (separate openings plus one opening without a common channel) in 16.9% subjects while 83.1% had a common channel.³ Our own data, based on a retrospective analysis of 259 selected endoscopic retrograde cholangiopancreatograms (ERCPs), in which the pancreaticobiliary ductal union could be clearly seen, showed a common channel in 63%.⁴

The length of the common channel in normal people ranges from 1-12 mm, with a mean of about 4.5 mm^{4,5} (Table II). Jona *et al*⁷ noted that the length of the common channel was <5 mm in normal people. A common channel of 4 mm in infants and 6 mm in adults was considered abnormal.⁸ In Di Magno's series 25% of patients had a well defined ampulla, 31% had a common

TABLE II Length of the common channel in normal subjects in various series

Authors	Mean (mm)	Range (mm)
Misra <i>et al</i> ⁴	4.7	1.6-18.4
Kimura <i>et al</i> ⁵	4.6	2-10
Dowdy <i>et al</i> ⁶	4.4	1-12

channel of <3 mm, and 18% had a common channel of >3 mm. The mean length was not mentioned.² In a necropsy study of 35 infants, Miyano *et al*⁹ noted that the average length of the common channel was 1.3 mm.

Kimura *et al*,⁵ using cineradiography during ERCP, have shown contractile motility of the ductal wall extending well beyond the common channel, towards the liver. The mean (SD) length of the contractile segment was 20.5 (4.6) mm (range 14-31 mm).

Anomalous pancreaticobiliary ductal union (APBD)

In APBD the connection between the common bile duct and the main pancreatic duct is located outside the duodenal wall and is therefore not under the influence of the sphincter of Boyden (Table III).¹¹ The frequency of APBD varies from 1.5-3.2%.^{4,5,10-15} The highest incidence of 3.2% was reported by Kimura *et al*⁵ and Unozawa *et al*.¹¹ If it appears that the pancreatic duct is joining the common bile duct it is denoted as P-B type and if the common bile duct appears to join the main pancreatic duct it is denoted as B-P type (Fig 1).

Kimura *et al*⁵ have shown that the contractile segment of the common channel, in APBD, ended well below the common channel. The mean (SD) length of the contractile segment was 14.8 (4.6) mm (range 11-22 mm) in subjects with APBD compared to 20.5 (4.6) mm (range 14-31 mm) in those without APBD. The difference between the two groups was significant ($p < 0.001$).

MECHANISM OF APBD

It may be that APBD is a result of uneven proliferation of bile duct epithelium during fetal life.¹⁷ The union of the common bile duct and the main pancreatic duct is located lateral to the duodenum up to the eighth week of gestation and then it shifts medially to lie finally within the

TABLE I Diseases associated with disorders of the pancreaticobiliary ductal union

<i>Anomalous pancreaticobiliary ductal union:</i>
Congenital cystic dilatation
Carcinoma of the gall bladder
<i>Long common channel:</i>
Carcinoma of the gall bladder
Gall stone induced acute pancreatitis
<i>Separate openings of the common bile duct and the main pancreatic duct:</i>
Gall stones
Alcohol induced chronic pancreatitis

TABLE III Definition of anomalous pancreaticobiliary ductal union used by various workers

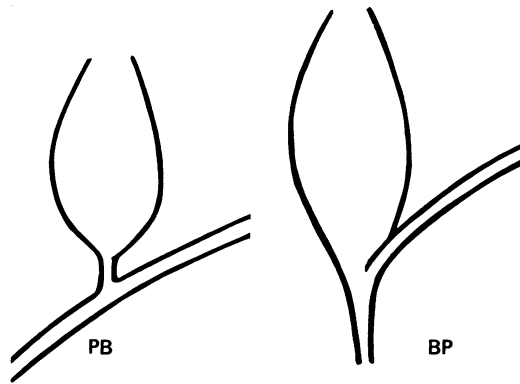
Common channel >15 mm ^{4,5,10-14}
Common channel >20 mm or ducts joining perpendicular to each other, or both ¹⁵
Common channel >15 mm plus amylase activity in bile >10 000 IU ¹³
Common channel >6 mm outside duodenum ¹⁶

Gastroenterology Unit,
Postgraduate
Department of Medicine,
MLN Medical College,
Allahabad-211001, India
S P Misra
M Dwivedi

Correspondence to:
Dr S P Misra.

Accepted for publication
30 October 1989

Figure 1: Two types of union. In the BP type the common bile duct appears to join the main pancreatic duct, while in the PB type the main pancreatic duct appears to join the common bile duct.



duodenal wall. Failure of this movement could result in APBD.¹⁸

APBD and congenital cystic dilatation of the common bile duct

In 1906 Arnolds noted an association between APBD and congenital dilatation of the common bile duct.¹⁹ Since then many workers have reported this association.^{5 7 10 14-17 20-27} The incidence of this association in various studies is shown in Table IV.

Ono *et al*¹⁶ found APBD in 15 (68%) of 22 patients with congenital cystic dilatation, while Sameshima *et al*²⁶ found APBD in 47.5% of patients with congenital cystic dilatation. In two other studies APBD was noted in 33%²⁴ and 100%⁷ of patients with congenital cystic dilatation.

TYPE OF UNION

Kimura¹⁰ and Komi *et al*²⁴ noted that B-P type of union is usually associated with congenital cystic dilatation, while another study from Japan noted the P-B union in nine of 15 (60%) cases.¹⁶ In a recent series 28 (56%) of 50 cases were of the P-B type and 22 (44%) of the B-P type.⁵ Arima and Akita noted the B-P type in 66% and P-B type in 34% of patients.²⁵

MECHANISM OF CONGENITAL CYSTIC DILATATION

The exact cause of congenital cystic dilatation is not known. Babbitt *et al*²⁰ proposed that because of the abnormally long common channel maldevelopment of the sphincter of Oddi occurs, which results in a reversed pressure gradient between the common bile duct and the main pancreatic duct. This leads to regurgitation of the pancreatic juice into the common bile duct and repeated attacks of cholangitis. This results in thickening of the common bile duct wall, stenosis, and finally dilatation. Komi showed that bile from patients with dilatation contained

amylase,²² but he failed to produce localised dilatation by regurgitating pancreatic juice experimentally into the common bile duct.²⁴ Cylindrical dilatation of varying degrees has been produced by injecting pancreatic juice through the bile duct in mongrel dogs.²⁷

Oguchi *et al*²⁷ found epithelial hyperplasia with round cell infiltration and thickening of the wall with fibrosis in all of their patients with cystic dilatation (n=40). They divided their patients into two groups. One group presented with abdominal pain; 86.4% showed predominant epithelial hyperplasia and round cell infiltration (glandular type). The amylase activity in bile was increased. The other group presented with obstructive jaundice; 73.7% of these patients showed predominant thickening of the wall with fibrosis (fibrotic type). Amylase activity, in bile of these patients, was significantly less than in the other group. 14 of 31 patients with cystic dilatation had glandular type while the other 17 had fibrotic type but all nine patients with cylindrical cystic dilatation had glandular type. In their animal model, where a pancreatico-cholecystostomy was done, they observed only cylindrical dilatation. They concluded that cylindrical congenital cystic dilatation may be accounted for by an APBD union, with resultant reflux of pancreatic juice into the common bile duct. But for cystic dilatation both an APBD union and an obstructive element in the lower part of the cyst play a part.

APBD and carcinoma of the gall bladder

Several Japanese workers have reported an association between APBD and carcinoma of the gall bladder.^{11 13-15 28-35} Kato *et al*¹⁵ reported that four of nine (44.4%) patients with APBD had carcinoma of the gall bladder. Only four of 291 (1.3%) patients without APBD had carcinoma of the gall bladder.

Kimura *et al*⁵ noted APBD in 16.7% of patients with carcinoma of the gall bladder compared to only 2.8% of patients with other hepatobiliary and pancreatic diseases. They also found that of the 65 cases of APBD, carcinoma of the gall bladder was present in 24.6% compared to 1.9% in those without APBD. Of these 65 patients with APBD, 50 had congenital cystic dilatation of the common bile duct. Of the remaining 15 (who did not have congenital cystic dilatation), 11 (73.3%) had gall bladder cancer compared to only five (10%) of the 50 patients. Ours is the only group, outside Japan, to find an association between APBD and carcinoma of the gall bladder.⁴

The prevalence of carcinoma of the gall bladder in APBD varies from 57% to 77% in Japanese series.^{5 9 12 13 28-30} Two of four (50%) patients in our series had carcinoma of the gall bladder⁴ (Fig 2b and c).

Patients with APBD develop carcinoma of the gall bladder earlier than those without APBD. The median age was lower by about a decade in those with APBD.¹⁴ In another report from Japan the mean (SD) age of patients with carcinoma of the gall bladder associated with APBD was 49.8 (9.8) years compared to 61.7

TABLE IV Incidence of congenital cystic dilatation of the common bile duct in patients with anomalous pancreaticobiliary ductal union

Author	Incidence (%)
Kimura <i>et al</i> ⁵	77
Kato <i>et al</i> ¹⁵	33
Yamauchi <i>et al</i> ¹⁴	75
Sameshima <i>et al</i> ²⁶	82.8

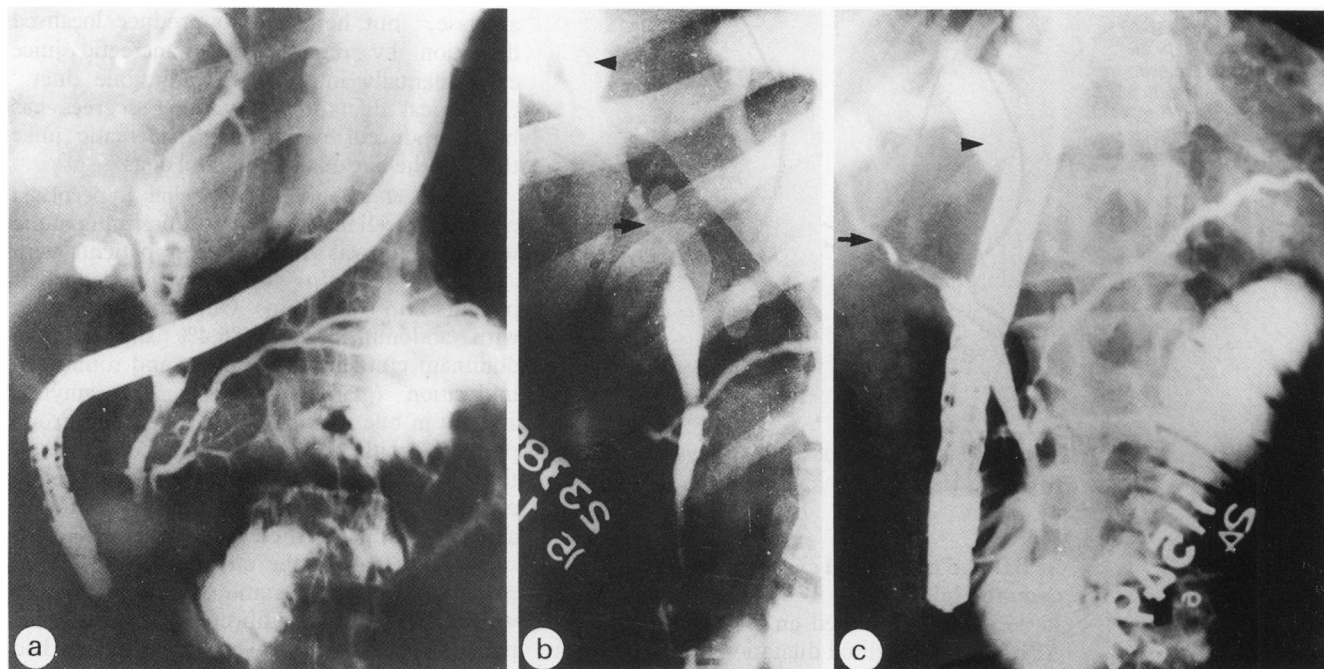


Figure 2: (a) Separate openings of the common bile duct and the main pancreatic duct in a patient with choledocholithiasis. (b) Anomalous pancreaticobiliary ductal union in a patient with carcinoma of the gall bladder. The common hepatic duct shows narrowing (arrow) with dilatation of proximal ducts (arrow head). (c) Endoscopic retrograde cholangiopancreatogram of a patient with carcinoma of the gall bladder and a long common channel. The common bile duct is narrowed (arrow) with dilatation of the intrahepatic biliary radicles (arrow head).

(10.3) years for those without APBD ($p < 0.05$).⁵

TYPE OF UNION IN CARCINOMA OF THE GALL BLADDER ASSOCIATED WITH APBD

In a review of all 47 reported cases of carcinoma of the gall bladder associated with APBD, Yamauchi *et al*¹⁴ observed that in 39 of 42 (92.9%) cases the union was of the P-B type. In the remaining five patients the type of union was not mentioned. In another study 13 of 42 (31%) patients with a P-B union had carcinoma of the gall bladder compared to only three of 23 (13%) with a B-P union.⁵

MECHANISM OF GALL BLADDER CARCINOMA IN APBD

A review of all 47 reported cases of carcinoma of the gall bladder associated with APBD up to 1985 showed that gall stones were present in only 17.5% of patients¹⁴ compared to 74% found by Piehler and Crichlow in patients with gall bladder cancer³⁶ and 57% in a Japanese study.³⁷ Kimura *et al*⁵ found gall stones in only 12.5% of patients with APBD associated carcinoma of the gall bladder compared to 66.9% in those with carcinoma of the gall bladder without APBD. Gall stones are probably not an important aetiological factor in patients with carcinoma of the gall bladder with APBD.

It has been postulated that in APBD pancreatic juice refluxes freely into the biliary tree, leading to chronic inflammation and metaplasia.^{5,14} When pancreatic juice is mixed with bile, lysolecithin and phospholipase A2 are produced, which may also be irritants.¹⁴ The gall bladder acts as a reservoir in patients with APBD without congenital cystic dilatation and thus carcinoma of the gall bladder occurs more frequently in such patients. In patients with

congenital cystic dilatation irritation occurs in the cyst rather than in the gall bladder, and it is well known that there is a high incidence of carcinomatous change.³⁸⁻⁴³ The amylase content in bile was high in 10 of 11 such patients.¹⁴ The highest activity recorded was 567 000 IU by Kinoshita *et al*.¹³ Sphincteric action stopped short of pancreaticobiliary ductal union in patients with APBD and thus the normal control mechanism preventing regurgitation of pancreatic juice into the biliary tree is absent in these patients.⁵ In an experimental study on mongrel dogs, development of mucosal and intestinal metaplasia was observed in the gall bladder after the creation of a cholecystopancreatic communication.³⁵ Thus APBD is a predisposing factor for carcinoma of the gall bladder and may be a premalignant condition, especially in patients without congenital cystic dilatation of the common bile duct. One worker even goes as far as to recommend prophylactic cholecystectomy in these patients.¹⁴

Long common channel

We have defined a long common channel as a common channel of ≥ 8 mm.⁴ In our study 12 (5%) of 259 ERCPs examined showed a long common channel. Eight (67%) of these patients had carcinoma of the gall bladder (Fig 2c), one patient had gall stones, and three were in the control group. The prevalence of a long common channel in the control group was three (3%) of 102 and one (1%) of 95 patients with gall stone disease compared to eight (38%) of 21 with carcinoma of the gall bladder. If only those with a common channel were considered, three (5%) of 64 control subjects, one (3.5%) of 28 patients with gall stone disease, and eight (57%) of 14 patients with carcinoma had a long common channel. The mechanism of carcinoma of the gall

bladder may be the same as that for APBD associated carcinoma.

Pancreaticobiliary ductal union in gall stone disease

In a retrospective analysis a total of 95 patients with gall stone disease of whom 59 patients had stones seen at ERCP, either in the common bile duct or the gall bladder, and 36 patients who had undergone cholecystectomy in the past for gall stone disease were evaluated by ERCP for post-cholecystectomy symptoms.⁴ Sixty seven of 95 (70%) had separate openings of the common bile duct and the main pancreatic duct (Fig 2a). When compared to the control group (separate opening for the two ducts in 37%) this difference was highly significant ($p < 0.001$), but the mean (SD) length of the common channel in gall stone disease (4.6 (2.6) mm) was similar to that in the control group (4.7 (2.5) mm).

MECHANISM

Two hypotheses might explain the higher incidence of gall stone disease in those who have separate openings for the two ducts. Firstly, the sphincteric mechanism at the distal end of the common bile duct may behave differently in these patients, leading to prolonged stasis of bile in the common bile duct and gall bladder, thus causing stone formation. Sphincterotomy inhibits gall stone formation in prairie dogs,⁴⁴ and this effect is reversed by giving atropine.⁴⁵ The alternative hypothesis is that a common channel may prevent gall stone formation because of reflux of pancreatic juice in the common bile duct where the glyco and proteolytic properties of the pancreatic juice dissolve the mucin nidus of gall stones, which is found at the core of most cholesterol gallstones.⁴⁶⁻⁴⁸ An in vitro study has shown that trypsin enhances the dissolution of gall stones.⁴⁹ Furthermore, studies from Japan have shown a much lower incidence of gall stones in patients with carcinoma of the gall bladder and APBD compared to those without APBD.^{5,14} Amylase levels in the bile of patients with carcinoma of the gall bladder with APBD were also high in 10 of 11 patients.¹⁴

Pancreaticobiliary ductal union in acute gall stone pancreatitis

Opie⁵⁰ noted impacted gall stones at the ampulla of Vater in a patient with pancreatitis, and it was suggested that reflux of bile into the pancreatic duct causes pancreatitis in patients with cholelithiasis.⁵¹ This led to the common channel theory.⁵² Since then many workers have shown that common bile duct stones are involved in the pathogenesis of gall stone pancreatitis⁵³⁻⁶² and are found in 20-30% of patients with gall stone pancreatitis at necropsy.^{53,55,59,60} When surgery was performed early, stones were found causing ampullary obstruction in 63-72% of patients.^{55,61} Stones can be recovered from the stools of most patients with gall stone pancreatitis.^{55,57,63}

A common pancreaticobiliary channel occurs in 67-80% of patients with gall stone pancreatitis.^{57,58,64-66} Jones *et al*⁶⁶ noted a common

pancreaticobiliary channel in 67% of 37 patients with gall stone pancreatitis compared to 32% of 109 patients with other biliary tract diseases.

Most of the stones found in patients with gall stone pancreatitis are small.⁶⁶⁻⁶⁸ Even microliths (stones <3 mm) have been implicated in the pathogenesis.⁶⁹

Jones *et al*⁶⁶ correlated the size of the gall stone to the length of the common channel. The length of the common channel was greater than the diameter of the smallest stone in nine of 27 (33%) patients with gall stone pancreatitis compared to 13 of 109 (12%) with other biliary tract disease. Thus, a common channel occurs more frequently in patients with gall stone pancreatitis, and the size of the stone and the common channel have important implications in the pathogenesis of gall stone induced acute pancreatitis.

Pancreaticobiliary angle (angle of reflux)

Even the width of the pancreatic duct and the angle at which the common bile duct and the main pancreatic duct meet are important in the pathogenesis of gall stone pancreatitis. In a study of 53 patients who had had attacks of acute gall stone pancreatitis and 561 patients without such a history (controls), it was noted that pancreatic duct reflux occurred in 33 (62.5%) patients with a previous history of acute gall stone pancreatitis compared to only 82 (14.6%) of the controls. Among all patients with pancreatic reflux, those with a past history of acute gall stone pancreatitis had wider cystic, common bile, and pancreatic ducts and the angle of reflux was greater (mean (SD) 40 (12)°) compared to those with no history of acute gall stone pancreatitis (angle of reflux 21 (15)°). The length of the common channel was greater in patients with a history of gall stone pancreatitis compared to controls (8 mm *v* 4 mm). Furthermore, 72% of patients had a common channel of 5 mm or more compared to only 20% in the control group. Apart from the frequency of pancreatic duct reflux, similar results were found in another study.⁷¹

Pancreaticobiliary ductal union in chronic pancreatitis

Yatto and Siegel⁷² reported separate openings of the common bile duct and the main pancreatic duct in 24 (86%) of 28 patients with alcoholic pancreatitis compared to only six (20%) of 30 alcoholics without chronic pancreatitis. The difference was significant ($p < 0.001$). We evaluated ERCP films of 49 patients with chronic pancreatitis: 18 (37%) had alcoholic pancreatitis and 31 (63%) had non-alcoholic pancreatitis. Thirteen (72%) of the 18 patients with alcoholic pancreatitis had separate openings for the two ducts, and 14 (45%) of 31 patients with non-alcoholic pancreatitis had separate openings. The difference between the two groups just failed to reach statistical significance. When compared to our earlier study in a control population⁴ separate openings in alcoholic pancreatitis patients were much more common (72% *v* 37%). If the entire series of 49 patients is considered, separate openings were noted in 27

(55%), which, when compared to the control group, was significantly higher. The length of the common channel was, however, similar (4.5 (1.2) v 4.7 (2.5) mm) (unpublished observations).

Mechanism of chronic pancreatitis

Di Magno *et al*² observed that separate openings for the common bile duct and the main pancreatic duct were associated with hyperplasia of the pancreatic ductular epithelium. This might lead to obstructed flow of pancreatic secretions. An association between pancreatic ductular epithelial changes, obstruction of pancreatic secretion, and chronic pancreatitis has been observed.⁷³ Chronic alcohol intake results in hyperplasia of the pancreatic ductular epithelium and increased secretion of pancreatic juice.⁷⁴ It may be that separate openings for the two ducts lead to hyperplasia of the pancreatic ductular epithelium which is enhanced by chronic alcohol intake, resulting in obstruction of the flow of pancreatic juice and later precipitation of protein plugs and chronic pancreatitis. Protein plugs form in the initial stages in most patients with chronic pancreatitis.⁷⁵

APBD and abnormal pancreatograms

Kato *et al*¹⁵ in a study of nine cases of APBD noted abnormality of the pancreatogram in eight (77.8%). An abnormal pancreatogram was found in only 24 (36.9%) of 65 patients with some type of biliary disease without APBD. There is no mention of an abnormal pancreatogram in most series of APBD. In our study⁴ we found no abnormality of the pancreatogram in our four patients with APBD.⁴

Pancreaticobiliary ductal union in primary sclerosing cholangitis

Muller *et al*⁷⁶ studied the role of pancreaticobiliary ductal union in primary sclerosing cholangitis. In 20 of the 46 patients, in whom the pancreaticobiliary ductal union could be clearly seen, anomalous union was noted in only two (10%) cases. Fourteen (70%) patients had a common channel of 1 or 2 mm, three patients had a common channel of 3 to 10 mm, and one patient had separate openings for the two ducts. Pancreatic duct abnormalities were found in half of these patients. It was concluded that the variations in the pancreaticobiliary ductal union were rare in patients with primary sclerosing cholangitis.

Pancreaticobiliary ductal union in other diseases

Abnormally long pancreaticobiliary ductal union was found in two (12%) of 17 children with infantile hepatitis, three (5%) of 57 with biliary atresia, and one patient with chronic pancreatitis.²⁵

In another study of 28 cases with biliary atresia, the junction of the common bile duct and the main pancreatic duct was situated below the propria muscularis of the duodenum in 17

(60.7%). The common channel was longer (>6 mm) in these patients than in the control subjects. The angle at which the two ducts joined was less acute than in the control subjects. The common channel in patients with choledochal cyst was longer than in patients with biliary atresia. An APBD was noted in all patients with choledochal cyst compared to 60% of patients with biliary atresia.⁹

Two cases of anomalous drainage of the common bile duct into the fourth portion of the duodenum have been described.⁸ Both were in young children who had recurrent attacks of abdominal pain and vomiting and, on investigation, hyperbilirubinaemia and hyperamylasemia. The common channels measured 1.0 and 2.7 cm.

- Hansson K. Experimental and clinical studies in aetiological role of bile reflux in acute pancreatitis. *Acta Chir Scand* 1967; 375 (suppl): 1-102.
- Di Magno EP, Shorter RG, Taylor WG, Go LW. Relationship between pancreaticobiliary ductal anatomy and pancreatic ductal and parenchymal histology. *Cancer* 1982; 49: 361-8.
- Suda K, Miyano T, Konuma I, Matsumoto M. An abnormal pancreatico-cholecho ductal junction in cases of biliary tract carcinoma. *Cancer* 1983; 52: 2086-8.
- Misra SP, Gulati P, Thorat VK, Vij JC, Anand BS. Pancreaticobiliary ductal union in biliary diseases. An endoscopic retrograde cholangiopancreatographic study. *Gastroenterology* 1989; 96: 907-12.
- Kimura K, Ohto M, Saisho H, *et al*. Association of gall bladder carcinoma and anomalous pancreaticobiliary duct union. *Gastroenterology* 1985; 89: 1258-65.
- Dowdy GS, Waldron GW, Brown WG. Surgical anatomy of the pancreaticobiliary ductal system. *Arch Surg* 1962; 84: 229-46.
- Jona JZ, Babbitt DP, Starshak RJ, La Porta AJ, Glicklich M, Cohen RD. Anatomic observations and etiologic and surgical considerations in choledochal cyst. *J Paediatr Surg* 1979; 14: 315-20.
- Doty J, Hassal E, Fonkalsrud EW. Anomalous drainage of the common bile duct into the fourth portion of the duodenum. *Arch Surg* 1985; 120: 1077-9.
- Miyano T, Suruga K, Suda K. Abnormal choledochopancreatic ductal junction related to the etiology of infantile obstructive jaundice. *J Paediatr Surg* 1979; 14: 16-26.
- Kimura K. Studies in 28 cases of congenital cystic dilatation of the common bile duct in adults. Roentgenological features and a union between the choledochus and the main pancreatic duct. *Jpn J Gastroenterol* 1976; 73: 61-74 (in Japanese with English abstract).
- Unozawa T, Kimura K, Ohto M, *et al*. Clinical study on relationship between anomalous pancreaticobiliary ductal union and carcinoma of the gall bladder. *Jpn J Gastroenterol* 1985; 82: 473-82 (in Japanese with English abstract).
- Kato T, Koyama K. Anomalous choledochopancreatic junction and its pathology. *J Clin Surg* 1986; 28: 34-43 (in Japanese).
- Kinoshita H, Nagata E, Hirohashi K, Sakai K, Yasutsugu Y. Carcinoma of the gall bladder with an anomalous connection between the choledochus and the pancreatic duct. *Cancer* 1984; 54: 762-9.
- Yamauchi S, Koga A, Matsumoto S, Tanaka M, Nakayama F. Anomalous junction of pancreaticobiliary duct without congenital choledochal cyst. A possible risk factor for gall bladder carcinoma. *Am J Gastroenterol* 1987; 82: 20-4.
- Kato O, Hattori K, Suzuki T, Tachino F, Yuasa T. Clinical significance of anomalous pancreaticobiliary union. *Gastrointest Endosc* 1983; 29: 94-8.
- Ono J, Sakoda K, Akita H. Surgical aspect of cystic dilatation of the bile duct. *Ann Surg* 1982; 195: 203-8.
- Yotsuyanagi S. Contributions to aetiology and pathology of idiopathic cystic dilatation of the common bile duct with report of three cases. New aetiological theory. *Gann* 1935; 30: 601-53.
- Wong KC, Lister J. Human fetal development of hepatopancreatic duct junction - a possible explanation of congenital dilatation of the biliary tract. *J Paediatr Surg* 1981; 16: 139-45.
- Arnolds. Eine menseskopfgrossen Retentionszyste des Choledochus. *Dtsch Med Wochenschr* 1906; 32: 1804.
- Babbitt DP, Starshak RJ, Clemett AR. Choledochal cyst: a concept of etiology. *Am J Roentgenol* 1973; 119: 57-62.
- Oi I, Doki F, Takemoto T. Analysis of anomalous connection between the pancreatic and biliary ducts. *Jpn J Gastroenterol* 1974; 71: 191.
- Komi N. Anomalous arrangement of pancreaticobiliary ducts. *Shuzutsu* 1975; 29: 73-83 (in Japanese).
- Kimura K, Ohto M, Ono T, *et al*. Congenital cystic dilatation of the common bile duct - relationship to anomalous pancreaticobiliary ductal union. *Am J Roentgenol* 1977; 928: 571-7.
- Komi N, Kashiwagi Y, Ikeda N. The etiology of congenital dilatation of the biliary duct. *Jpn J Paediatr Surg* 1977; 9: 1101-9 (in Japanese).

- 25 Arima E, Akita H. Congenital biliary tract dilatation and anomalous junction of the pancreaticobiliary system. *J Paediatr Surg* 1979; 14: 9-15.
- 26 Sameshima Y, Uchimura M, Muto Y, Maeda J, Tsuchiyama H. Coexistent carcinoma in congenital dilatation of the bile duct and anomalous arrangement of the pancreaticobiliary duct. *Cancer* 1987; 60: 1883-90.
- 27 Oguchi Y, Okada A, Nakamura T, et al. Histopathologic studies of congenital dilatation of the bile duct as related to an anomalous junction of the pancreaticobiliary ductal system. Clinical and experimental studies. *Surgery* 1988; 103: 168-73.
- 28 Sameshima Y, Uchimura M, Muto Y, et al. A case of anomalous arrangement of pancreatico-biliary duct with papillary adenocarcinoma and papillary adenoma of the gall bladder. *Jpn J Gastroenterol* 1978; 756: 909-15.
- 29 Konishi T, Nagakawa T, Jinno M, et al. Four cases of anomalous arrangement of pancreaticobiliary duct associated with gall bladder cancer. *Biliary Tract and Pancreas* 1981; 2: 435-41 (in Japanese).
- 30 Hanyu F, Ohashi M, Ohi T. Clinical aspects of biliary duct carcinoma associated with anomalous arrangement between the choledochus and the pancreatic duct. *Biliary Tract and Pancreas* 1981; 2: 1637-50 (in Japanese).
- 31 Kinoshita H, Osada E, Chimata Y, et al. Carcinoma of the gall bladder with anomalous arrangement between the choledochus and the pancreatic duct. Report of 7 cases and review of literature. *Biliary Tract and Pancreas* 1981; 2: 1701-9 (in Japanese).
- 32 Uchimura M, Muto Y, Waki S, et al. Association of carcinoma with congenital dilatation of the bile duct. *Biliary Tract and Pancreas* 1982; 3: 333-42 (in Japanese).
- 33 Sugihara J, Sekita M, Saito Y, et al. Anomalous arrangement of pancreaticobiliary duct and cancer. *Biliary Tract and Pancreas* 1982; 3: 487-95 (in Japanese).
- 34 Mihara O, Murahisa T, Tsugama M, et al. A case of early carcinoma of the gall bladder with anomalous arrangement between the choledochus and the pancreatic duct without choledochal cyst dilatation. *Biliary Tract and Pancreas* 1984; 5: 617-21 (in Japanese).
- 35 Nagata E, Sakai K, Kinoshita H, et al. The relation between carcinoma of the gall bladder and anomalous connection between the choledochus and the pancreatic duct. *Ann Surg* 1985; 202: 182-90.
- 36 Piehler JM, Crichlow RW. Primary carcinoma of the gall bladder. *Surg Gynecol Obstet* 1978; 147: 929-42.
- 37 Yokayama I, Tashiro S, Kanno T, et al. Current problems on surgical treatment of primary carcinoma of the gall bladder in Japan. *Nippon Shokakigeka Gakkai Zasshi* 1980; 13: 1362-8.
- 38 Alonso-Lej F, Rever WB, Pessagno DJ. Congenital choledochal cyst, with a report of two and an analysis of 94 cases. *Int Abstr Surg* 1959; 108: 1-30.
- 39 Tsuchiya R, Harada N, Ito T, et al. Malignant tumors in choledochal cysts. *Ann Surg* 1977; 186: 22-8.
- 40 Bloustein PA. Association of carcinoma with congenital cystic conditions of the liver and bile ducts. *Am J Gastroenterol* 1977; 67: 40-6.
- 41 Todani T, Kobuchi KM, Watanabe Y, et al. Carcinoma arising in the wall of congenital bile duct cyst. *Cancer* 1979; 44: 1134-41.
- 42 Chaudhary PK, Chaudhari B, Schuler JJ, Nyhus L. Carcinoma associated with congenital cystic dilatation of bile ducts. *Arch Surg* 1982; 117: 1349-51.
- 43 Voyles CR, Smadja C, Shands WC, et al. Carcinoma in choledochal cysts. *Arch Surg* 1983; 118: 968-8.
- 44 Hulton SW, Sievert CE Jr, Vennes JA, Dunane WC. The effect of sphincterectomy on gallstone formation in prairie dog. *Gastroenterology* 1981; 81: 663-71.
- 45 Hulton SW, Sievert CE Jr, Vennes JA, Duane WD. Inhibition of gallstone formation by sphincterectomy in the prairie dog. Reversal by atropine. *Gastroenterology* 1982; 82: 1308-13.
- 46 Womack N, Zeppa R, Irvin G. The anatomy of gallstones. *Ann Surg* 1963; 157: 670-86.
- 47 Maki T, Matsushiro T, Susuki N, Nakamura N. Role of sulphated glycoprotein in gall stone formation. *Surg Gynecol Obstet* 1974; 132: 846-54.
- 48 Lee SP, La Mont JT, Carey MC. Role of gall bladder mucus hypersecretion in the evolution of cholesterol gall stones. *J Clin Invest* 1981; 67: 1712-23.
- 49 Leuschner J, Baumgattel H. Gallstone dissolution in the biliary tract. In vitro investigations in inhibiting factors and special dissolution agents. *Am J Gastroenterol* 1982; 77: 222-6.
- 50 Opie EL. The relation of cholelithiasis to disease of the pancreas and to fat necrosis. *Bull Johns Hopkins Hosp* 1901; 12: 119-21.
- 51 Halstead WS. Retrojection of bile into the pancreas, a cause of acute haemorrhagic pancreatitis. *Bull Johns Hopkins Hosp* 1901; 12: 179-81.
- 52 Opie EL. The etiology of acute haemorrhagic pancreatitis. *Bull Johns Hopkins Hosp* 1901; 12: 182.
- 53 Calen F, Frey C. Re-evaluation of the treatment of pancreatitis associated with biliary tract disease. *Ann Surg* 1964; 160: 723-6.
- 54 Dixon JA, Hillam JD. Surgical treatment of biliary tract disease associated with acute pancreatitis. *Am J Surg* 1970; 120: 371-5.
- 55 Acosta JM, Ledesma CL. Gallstone migration as a cause of acute pancreatitis. *N Engl J Med* 1974; 290: 484-7.
- 56 Imrie W, Whyte AS. A prospective study of acute pancreatitis. *Br J Surg* 1975; 62: 490-4.
- 57 Kelly TR. Gallstone pancreatitis. Pathophysiology. *Surgery* 1976; 80: 488-92.
- 58 Freunh H, Pfeffermann R, Dinst AL, Rabinovici N. Exploration of biliary system in acute and recurrent pancreatitis. *Arch Surg* 1976; 111: 1106-7.
- 59 Ong BB, Lam KH, Lam SK, et al. Acute pancreatitis in Hong-Kong. *Br J Surg* 1979; 66: 398-403.
- 60 Ranson JHC. The timing of surgery in acute pancreatitis. *Ann Surg* 1979; 189: 654-63.
- 61 Kelly TR. Gallstone pancreatitis. The timing of surgery. *Surgery* 1980; 88: 345-50.
- 62 Kelly TR. Gallstone pancreatitis. The second time around. *Surgery* 1982; 92: 571-5.
- 63 Acosta JM, Rossi R, Ledesma CL. The usefulness of stool screening for diagnosing cholelithiasis in acute pancreatitis. A description of the technique. *Am J Dig Dis* 1977; 22: 168-72.
- 64 Bergqvist A, Selainger SI. Pancreatic reflux in operative cholangiography in relation to pre and post operative pancreatic affection. *Acta Chir Scand* 1957; 114: 191-6.
- 65 Thyrston OG. Pathogenesis of gallstone pancreatitis. *Am J Surg* 1975; 129: 301-3.
- 66 Jones BA, Salsberg BB, Bohnen JMA, Mehta MH. Common pancreaticobiliary channels and their relationship to gall stone size in gallstone pancreatitis. *Ann Surg* 1987; 205: 123-5.
- 67 McMohan MJ, Playforth MJL. The relationship between gall stone and cystic duct anatomy in acute pancreatitis. *Br J Surg* 1978; 65: 361.
- 68 Frey CF. Gallstone pancreatitis. *Surg Clin North Am* 1981; 61: 923-38.
- 69 Houssin D, Casaing D, Lemioine J, Bismuth H. Microlithiasis of the gall bladder. *Surg Gynecol Obstet* 1983; 157: 20-4.
- 70 Armstrong CP, Taylor TV. Pancreatic duct reflux and acute gallstone pancreatitis. *Ann Surg* 1986; 204: 59-64.
- 71 Yveyneaux JP. [Letter]. *Ann Surg* 1987; 205: 594-6.
- 72 Yatro RP, Siegel JH. The role of pancreaticobiliary duct anatomy in the etiology of alcoholic pancreatitis. *J Clin Gastroenterol* 1984; 6: 419-23.
- 73 Volkhoff G, Stolle M, Beeker V. Epithelial dysplasia in chronic pancreatitis. *Virchows Arch (Pathol Anat)* 1982; 392: 331-49.
- 74 Dreiling DA, Greenstein AJ, Bortalo O. The hypersecretory states of the pancreas. Implications in the pathophysiology of peptic ulcer diathesis. *Am J Gastroenterol* 1973; 59: 505-11.
- 75 Sarles H. Etiopathogenesis and definition of chronic pancreatitis. *Dig Dis Sci* 1986; 31 (suppl): 91S-107S.
- 76 Muller EL, Miyamoto T, Pitt HA, Longmire WP. Anatomy of the choledochopancreatic duct junction in primary sclerosing cholangitis. *Surgery* 1985; 97: 21-6.