

Can transcutaneous recordings detect gastric electrical abnormalities?

B O Familoni, K L Bowes, Y J Kingma, K R Cote

Abstract

The ability of transcutaneous recordings of gastric electrical activity to detect gastric electrical abnormalities was determined by simultaneous measurements of gastric electrical activity with surgically implanted serosal electrodes and cutaneous electrodes in six patients undergoing abdominal operations. Transient abnormalities in gastric electrical activity were seen in five of the six patients during the postoperative period. Recognition of normal gastric electrical activity by visual analysis was possible 67% of the time and with computer analysis 95% of the time. Ninety four per cent of abnormalities in frequency were detected by visual analysis and 93.7% by computer analysis. Abnormalities involving a loss of coupling, however, were not recognised by transcutaneous recordings. Transcutaneous recordings of gastric electrical activity assessed by computer analysis can usually recognise normal gastric electrical activity and tachygastria. Current techniques, however, are unable to detect abnormalities in electrical coupling.

Human gastric electrical activity consists of recurrent regular depolarisations (slow waves) at 2.5 to 4 cycles per minute, and intermittent high frequency oscillations (spikes) that appear only in association with contractions. Slow waves begin high on the greater curvature and pass aborally towards the lesser curvature, accelerating as the pylorus is approached. As spikes can only occur during a portion of the slow wave cycle, slow waves are the ultimate determinant of the frequency and direction of propagation of contractions.

Slow waves are best recorded in vivo by surgically implanted electrodes. They have also been recorded by percutaneous and transmucosal techniques.¹⁻⁴ The latter techniques are, however, noisy and recognition of gastric slow waves is possible during part of the recording time only. In some patients, successful recordings are not obtainable. Spikes are generally not seen on transcutaneous recordings.

In spite of the recording difficulties, abnormalities in gastric slow wave activity have been described using these techniques in patients with unexplained nausea and vomiting,⁵⁻⁷ anorexia nervosa,⁸ gastroparesis,⁹⁻¹¹ pregnancy related nausea,¹² and motion sickness.¹³⁻¹⁵ Although comparing groups of patients with the same technique, as in these studies, lends credence to the existence of an abnormality in a particular group, the accuracy of transcutaneous electrogastrograms in diagnosing an abnormality in a single patient has not been determined.

This study was undertaken to determine the ability of transcutaneous electrical recordings to recognise various types of gastric slow wave abnormality. Implanted electrodes were used as our 'gold standard'. The postoperative period afforded the opportunity to study both normal and abnormal states of gastric slow waves. Abnormalities in these after surgery have been described using serosal electrodes.¹⁶⁻¹⁸ To exploit fully the potential of transcutaneous recordings, both visual analysis and extensive filtering and analysis on a digital computer were performed.

Methods

ELECTROGASTROGRAPHIC METHODS

Transcutaneous and serosal recordings of gastric slow waves were made simultaneously on six patients undergoing laparotomy for fundoplication, cholecystectomy, or bowel resection. The study had been approved by the ethics committee of the University of Alberta Hospitals in October 1986 and informed written consent was obtained from each subject before the procedure.

Three pairs of stainless steel wire electrodes 0.254 mm in diameter were implanted subserosally into the anterior surface of the antral wall, between 1.5 cm and 10.5 cm from the pylorus. The Teflon coated connecting wires were brought out through a 1 inch Penrose drain via a separate stab wound. Four ordinary Hewlett Packard electrocardiography electrodes (type 14445C) were placed on the skin in the epigastric region to form two pairs of bipolar recording electrodes. Each pair was aligned with the antral axis as previously described¹⁹ or as close to it as the surgical wounds permitted.

The implanted electrodes were connected to a Beckman dynograph recorder with a low cut off frequency of 0.017 Hz (1 cycle/minute) and a high cut off frequency of 30 Hz (1800 cycles/minute). The cutaneous electrodes were connected to the dynograph at a low cut off frequency of 0.017 Hz (1 cycle/minute) and a high cut off frequency of 0.08 Hz (4.8 cycles/minute). The cut off frequency of 0.08 Hz was necessary to ensure rejection of electrocardiographic artefacts from the transcutaneous recording. The slope of this first order filter, however, was quite gentle (6 dB/octave). The attenuation at the cut off frequency (4.8 cpm) was -3 dB (or a factor of 0.71), and the attenuation of a signal at 9.6 cpm was still only -6 dB (or a factor of 0.5).

The signals at the dynograph amplifier outputs were sampled at a rate of 2 Hz and stored on an IBM pc AT computer via a Lab Master 200009 12 bit, 8 channel A to D converter.

Departments of Surgery and Electrical Engineering, University of Alberta, Edmonton, Alberta, Canada
B O Familoni
K L Bowes
Y J Kingma
K R Cote

Correspondence to:
Dr Kenneth L Bowes,
Department of Surgery,
MacKenzie Health Sciences
Centre, Edmonton, Alberta,
Canada T6G 2B7.

Accepted for publication
26 March 1990

Recording was started in the recovery room and continued for up to 120 hours.

ANALYSIS OF RECORDINGS

All channels were subjected to both visual and computer analysis. The recorded signals were visually inspected for regularity in the slow wave period, frequency, and presence of abnormalities. The transcutaneous recording was inspected blind – that is, without reference to the serosal recordings. The percentage of time during which the recorded signal was normal and the number and type of abnormalities recorded were determined. These were then compared with a similar individual analysis of the serosal recordings to determine the correlation and accuracy of the transcutaneous method.

We defined normal gastric slow waves in accordance with several previous reports of gastric slow waves in healthy people – that is, regular activity with a fundamental frequency

between 2.0 and 4.5 cycles/minute.^{1 3 4 19 20} Both coupled (phaselocked) and uncoupled abnormalities were observed. The coupled abnormalities included tachygastric, irregular slow waves, and electrical 'shutdown'. Tachygastric was defined as stable slow wave with a frequency higher than 4.5 cpm.^{2 5 6 10 12} Irregular slow waves were characterised by variations of 10–60% in the period of successive cycles of the slow waves. An electrical 'shutdown' was assumed to occur when no slow waves were seen in any channel for 40 seconds or more (corresponding to a maximum slow wave frequency of less than 1.5 cpm). Two types of uncoupled (not phaselocked) gastric slow waves were seen. In the first type the different sites had different frequencies and the signals were irregular. In the second type the same frequency was evident at different sites, but the signals were not coupled.

Computer analysis consisted of sequential power spectrum analysis over successive 128 second 50% overlapping intervals and cross

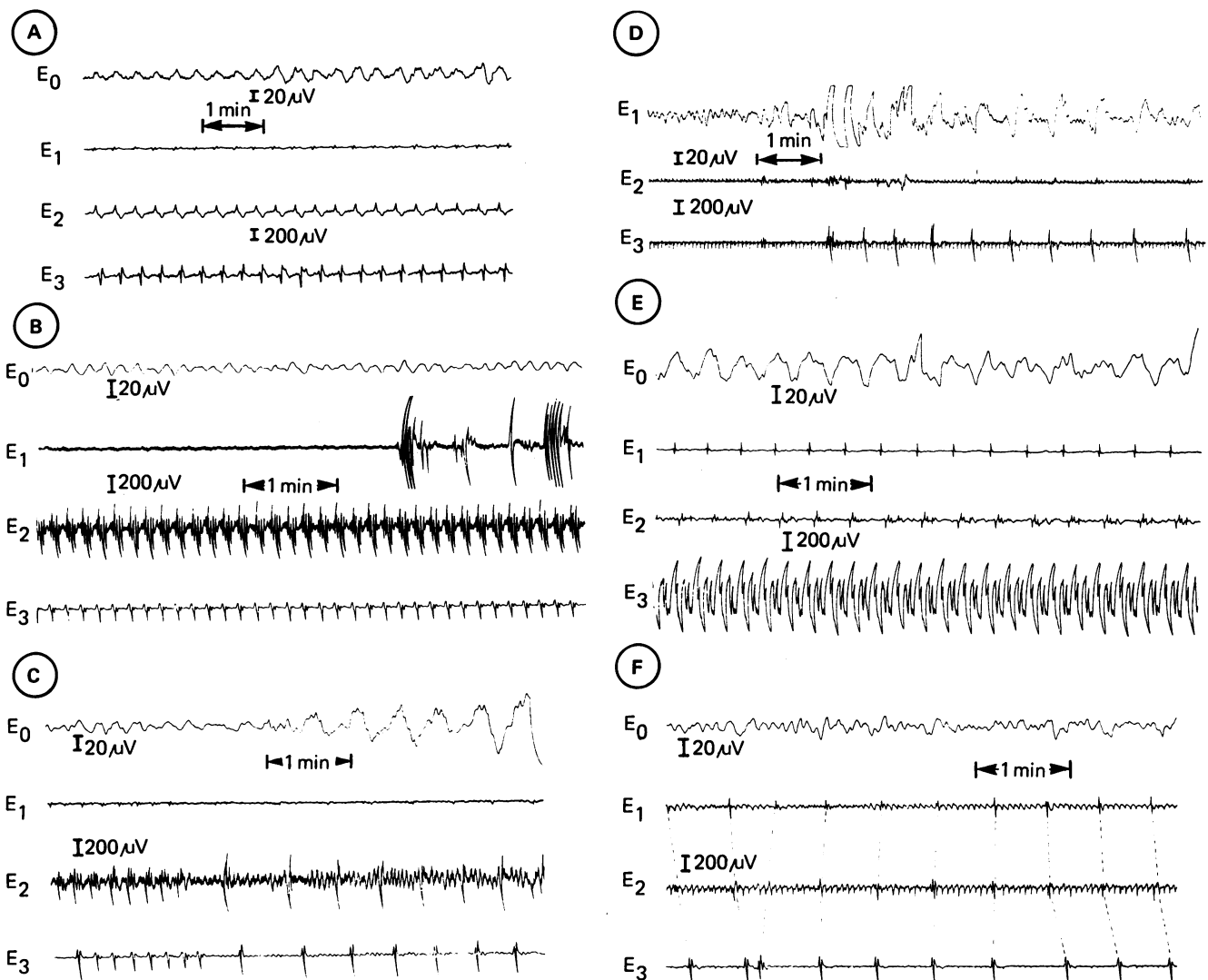


Figure 1: Gastric electrical activity recorded simultaneously by cutaneous (E_0) and serosal (E_1 – E_3) electrodes.

(A) Normal gastric slow waves (GSW) (2.8 cpm) recorded by both cutaneous and serosal electrodes.

(B) Tachygastric (6 cpm) evident in both serosal and cutaneous records. E_1 has become loosely implanted and displays low signal to noise ratio.

(C) Irregular, but coupled, GSW evident in both serosal and cutaneous records.

(D) GSW 'shutdown' marked by absence of discernible signal in serosal and cutaneous electrodes followed by return of slow waves in cutaneous and one serosal electrode. The third serosal electrode in this patient had previously broken off.

(E) Uncoupled regular GSW with different frequencies in different parts of the stomach (E_1 , E_2 2.9 cpm, E_3 4.2 cpm). The cutaneous electrode ignores the frequency of E_3 but accurately reflects E_1 and E_2 .

(F) Uncoupled and irregular GSW. The broken lines in the serosal recording link successive slow waves in adjacent channels. The variable pattern of these lines indicates uncoupling. The cutaneous electrode's signal does not accurately reflect the actual gastric events.

correlation. Fast Fourier transform with a Hamming window were calculated for the 256 samples in each time frame to determine the signal frequencies. Power spectrum analysis breaks down a signal, permitting determination of frequencies of any rhythmical activities even if the signal is corrupted by random noise;²¹ a difference in the fundamental frequencies of any two signals indicates that they are not phase locked. Cross correlation determines which frequencies, if any, are common to two given signals. This method was employed to determine whether the slow wave was coupled or not.²⁰

Periods of nursing care or patient movement as marked on the recording paper by the nursing staff were excluded from the analysis. The implanted electrodes were removed with the drain when the latter was no longer needed 72 to 120 hours after its insertion.

Results

SEROSAL RECORDINGS

Serosal electrodes gave excellent recordings of gastric slow waves. Out of a total recording duration of 491.9 hours, 7.3 hours were unusable because of motion artefacts from nursing care. Data analysis was restricted to the remaining 484.6 hours of recording.

Normal slow wave was recorded for most of the recording time (76.84%). In the recovery

TABLE I Gastric slow wave (GSW) abnormalities recorded at (A) serosal electrodes, (B) cutaneous electrodes, and (C) those recorded simultaneously at both sites

	No of episodes	Duration (min) (mean (SD))	Total (hrs)
(A) Serosal electrodes			
Tachygastria	131	45.9 (74.3)	100.22
Irregular GSW	11	7 (2.6)	1.28
Electrical shutdown	5	3.5 (2.6)	0.29
Uncoupled I	4	217.3 (92.4)	14.49
Uncoupled II	5	5.2 (2.7)	0.43
Total	156		116.71
(B) Cutaneous electrodes			
Tachygastria	127	47 (74.9)	99.48
Irregular GSW	12	7.3 (2.3)	1.46
Electrical shutdown	3	3.6 (2.7)	0.18
Uncoupled I	0	0 (0)	0.00
Uncoupled II	0	0 (0)	0.00
Total	142		101.12
(C) Abnormalities recorded simultaneously by both methods			
Tachygastria	122	46.3 (74.6)	94.14
Irregular GSW	9	7.1 (2.2)	1.07
Electrical shutdown	3	3.6 (2.7)	0.18
Uncoupled I	0	0 (0)	0.00
Uncoupled II	0	0 (0)	0.00
Total	134		95.39

TABLE II Accuracy of transcutaneous recordings in diagnoses of normal and abnormal gastric slow wave (GSW) (visual analyses)

Gastric slow wave activity (Serosal electrodes) (hrs)	Cutaneous electrical recording (%)					
	Normal	Undecipherable	Tachygastria	Irregular GSW	Electrical shutdown	Uncoupled
(A) Visual analyses						
Normal	369.05	67.01	31.02	1.96	0.01	0
Tachygastria	100.4	0	9.11	90.89	0	0
Irregular GSW	1.4	0.71	35.71	1.43	62.86	0
Electrical shutdown	0.3	0	26.67	13.33	0	66.67
Uncoupled I	15.1	35.1	43.71	20.53	0.66	0
Uncoupled II	0.4	0	97.5	2.5	0	0
(B) Computer analyses						
Normal	367.88	95.44	3.85	0.71	0	0
Tachygastria	100.22	0	5.82	93.93	0.25	0
Irregular GSW	1.29	0.78	15.5	0.73	82.95	0
Electrical shutdown	0.29	0	27.59	10.34	0	62.07
Uncoupled I	14.25	22.46	57.54	18.95	1.05	0
Uncoupled II	0.43	0	97.67	2.33	0	0

room (0 to 1 hour postoperatively), the slow waves in all six patients remained regular, with a mean (SD) frequency 2.91 (0.48) cpm (0.049 (0.008) Hz) (Fig 1A).

Slow wave abnormalities were seen in five patients shortly after the recovery room period; the abnormalities lasted up to 10.75 (4.61) hours postoperatively in four, and persisted until the implanted electrodes were removed (120 hours) in the fifth. We had suspected from intraluminal and transcutaneous measurements before the operation that this fifth patient had gastric electrical abnormalities.

One hundred and fifty six separate episodes of slow wave abnormalities were recorded from the serosa (Table I). Coupled (tachygastria, irregular slow wave, electrical 'shutdown') and uncoupled abnormalities were observed. Tachygastria was the commonest abnormality detected in both the transcutaneous and gastric recordings (Fig 1B). Eleven episodes of irregular slow waves lasting an average of seven minutes were recorded (Fig 1C). Electrical 'shutdown' was recorded five times by the serosal electrodes with an average duration of 3.5 (2.6) minutes (Fig 1D).

Nine episodes of uncoupled activity were recorded. In four there were different frequencies at separate sites (Figs 1E and F).

CUTANEOUS RECORDINGS

Cutaneous recordings reflected actual gastric electrical events poorly (Table II). Normal slow waves were recognised by cutaneous electrodes only 67% of the time. Surprisingly, tachygastria was recognised more often (91% of the time). Irregular electrical activity and electrical 'shutdown' pauses were often not recognised; they were recognised at the cutaneous recording only 63% and 67% of the time respectively. Uncoupled gastric electrical events were not recognised in any cutaneous recording. During uncoupling cutaneous electrodes did not accurately reflect gastric slow wave (Fig 1E and F).

Computer analysis dramatically improved the ability of transcutaneous recordings to detect coupled gastric events (Table II). For instance, normal slow waves were recognised 95% of the recording time. Irregular slow waves and electrical 'shutdown' were not diagnosed with greater precision, however, and uncoupling was again not recognised. Detection of irregular slow

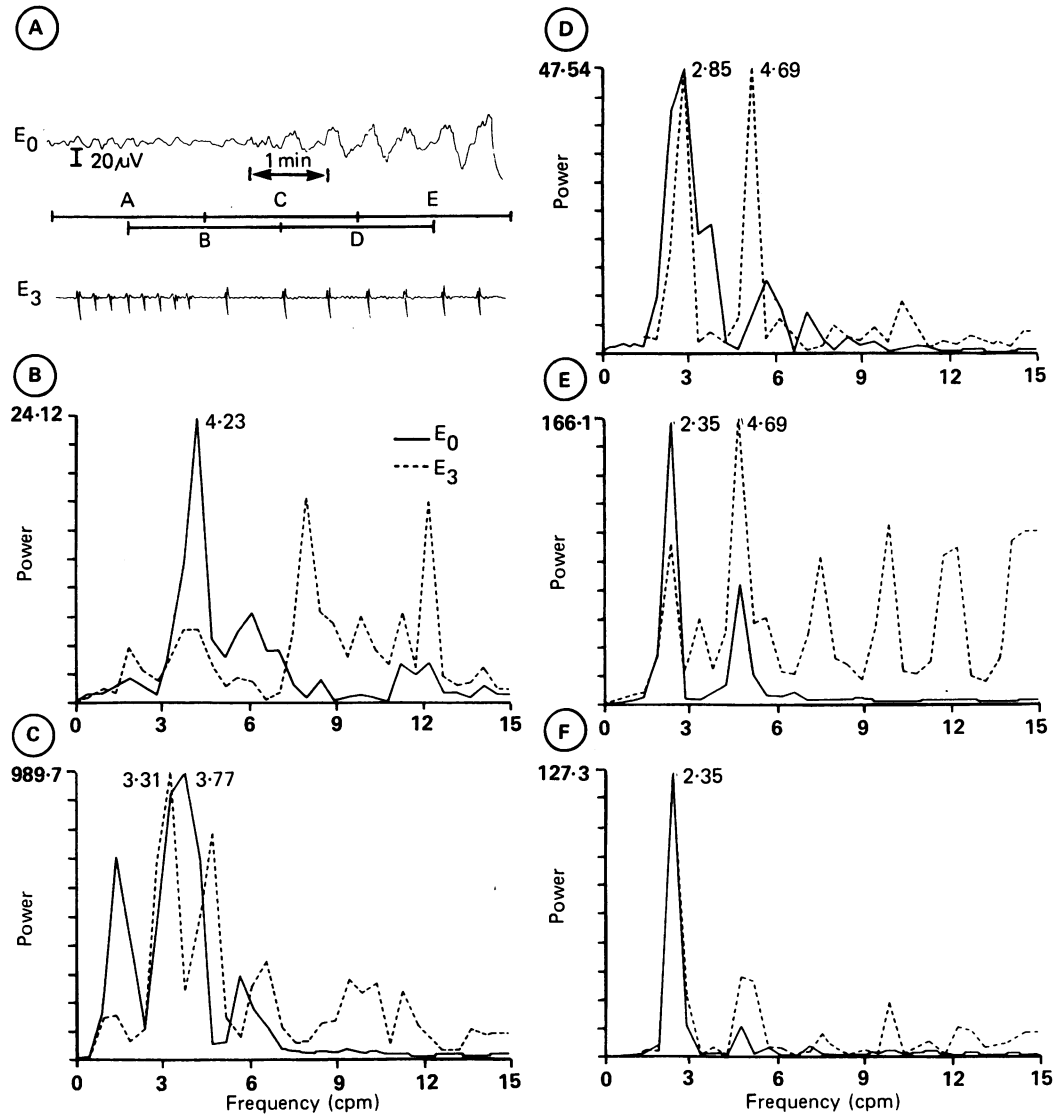


Figure 2: (A) Cutaneous (E_0) and serosal (E_3) recordings of gastric slow wave (GSW) during a period of shifting frequencies. Sequential frequency power spectra of 128 second overlapping intervals (A, B, C, D, E) of E_0 and E_3 were obtained and are illustrated in 2A-F. The amplitude scales are arbitrary. The major peaks are labelled with their frequencies. (B) E_0 and E_3 have the fundamental frequency of 4.23 cpm in common. The term fundamental is the repetition frequency of a signal. When this periodic signal is highly non-sinusoidal in shape the harmonic content increases - that is, integrar multiples or overtones of the fundamental frequency are seen.²⁵ Note that the harmonics of E_3 are prominent and the fundamental is small. (C) E_0 and E_3 deviate from the common frequency in B. The wide peak of E_0 at 3.77 cpm indicates shifting frequencies. (D) E_0 and E_3 are both settling to a lower common frequency. (E and F) E_0 and E_3 have a sharp fundamental peak in common at 2.35 cpm.

waves by power spectrum analysis was contingent on the observer detecting particular trends in sequential frames of the power spectra and was therefore quite subjective. For example, the variations in frequency of the irregular slow waves (Fig 2) resulted in an unstable frequency

pattern in the power spectra analysis as shown in Figure 2B to F. At the height of the transition, two distinct slow wave frequencies that were not harmonically related (2.85 and 4.69 cpm) were seen (Fig 2D).

When the transcutaneous signal was normal,

TABLE III Gastric slow waves (GSW) during various patterns of transcutaneous recordings

Cutaneous recording (hrs)	Gastric electrical activity (%)					
	Normal	Tachygastric	Irregular GSW	Electrical shutdown	Uncoupled I	Uncoupled II
<i>(A) Visual analyses</i>						
Normal	251.04	94.8	3	0.6	0	2.1
Uncipherable	127.81	88.2	7.4	0.2	0.1	4.1
Tachygastric	103.96	13	81.5	0.3	0.02	4.9
Irregular GSW	0.97	4.12	2.06	71.13	0	22.68
Electrical shutdown	0.17	0	23.53	0	70.59	0
Uncoupled	0	0	0	0	0	11.76
<i>(B) Computer analyses</i>						
Normal	341.06	97.34	1.55	0.02	0	1.08
Uncipherable	39.2	76.52	6.89	1.73	0.05	14.29
Tachygastric	103.62	5.4	88.88	0.21	0	5.31
Irregular GSW	0.63	26.98	1.59	47.62	0	17.46
Electrical shutdown	0.26	3.85	11.54	0	65.38	0
Uncoupled	0	0	0	0	0	19.23

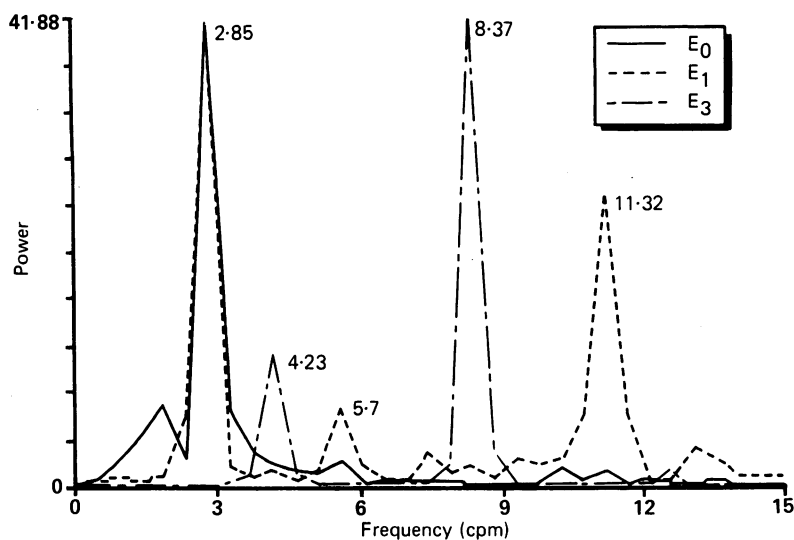


Figure 3: Frequency power spectra of uncoupled regular electrical activity (Fig 1A). The cutaneous recording E_0 duplicated E_1 , but ignored E_3 . E_0 (cutaneous) and E_1 (serosal) exhibit the same strong fundamental frequency at 2.85 cpm. E_1 also contains several harmonics of this frequency. Serosal electrode E_3 however does not contain a component at 2.85 cpm, but instead it has peaks at 4.23 cpm.

the actual slow waves were usually normal also (94.8%: Table III). Unfortunately, a large portion of transcutaneous recordings were undecipherable. The transcutaneous recording of tachygastric less accurately reflected the true gastric event (80%). Transcutaneous recordings of irregular slow waves and electrical 'shutdown' were even less precise. No noticeable improvement occurred in the detection of these abnormalities after computer analysis.

Discussion

The concept of cutaneous electrodes diagnosing abnormalities in gastric electrical activity has great appeal. Electrocardiograms are obtained using similar techniques and there is little question of their great value in the diagnosis of cardiac disease. The electrogastragram, however, differs significantly from the electrocardiogram. The amplitude of the signal is extremely low (average 0.05 mV on the electrogastragram v 1.6 mV for the R wave on the electrocardiogram). This necessitates a considerably increased gain and therefore an appreciable increase in artefact. Part of this artefact is caused by the motion of respiration or movement of the gut wall and part is probably from superimposition of signals arising in multiple sites in the small bowel and colon. Unlike the heart, only a minority of the signals recordable (slow waves) are associated with contractions.

Definite abnormalities in gastric electrical activity have been described in only a few conditions and usually with non-implanted electrodes. In all such recordings, a good recording may not be obtained for much of the time. The abnormalities described are usually present for a portion of the recording time only and the incidence of noisy unanalysable records is high. It is possible that some of the abnormalities described are recording artefacts. Some recording artefacts may be secondary to the abnormal state and not the cause of it - for example, heaving before vomiting or gastric dilatation or displacement from any cause.

Cutaneous recording can recognise 67% of normal gastric slow waves, 90% of tachygastric, 62% of irregularities in gastric electrical activity, and 67% of electrical 'shutdown'. If computer analysis is used these figures alter to 95%, 93%, 82%, and 62% respectively.

When cutaneous electrodes indicate a normal record they are accurate 95% of the time. A cutaneous recording of tachygastric is confirmed 82% of the time. Irregularities in slow waves and electrical 'shutdown' are accurate reflections of the true situation in 71 and 70% of the time. These figures are altered by computer analysis to 97%, 89%, 47%, and 65%.

Cutaneous records, however, cannot pick up uncoupling (Fig 3). Homogeneous linear conducting models of the human torso²¹⁻²³ suggest that this is probably because electrogastragrams represent the summation of all activity and reflect the major mass of tissue. If most of the stomach is normally coupled, a regular record at a normal or fast frequency is obtained (Fig 1E) and a very significant underlying gastric disorder could be missed.

Computer analysis is obviously of considerable value in interpreting gastric electrical activity recordings. Without it 26% of records are undecipherable, whereas with it only 8% cannot be deciphered. With computer analysis, transcutaneous gastric electrical activity is in certain instances of definite value. If a normal recording is obtained it is highly likely that the patient's gastric slow wave activity is normal. Similarly, tachygastric will be an accurate reflection of the situation in the stomach in nine out of 10 subjects. The commonest abnormality reported in patients with gastric electrical abnormalities is, in fact, tachygastric.^{5-8, 10} It might be asked whether tachygastric is of much functional importance. Although a frequency of 6 per minute indicates a change in the state of the gastric oscillators, it is not established that contractions occurring at a frequency of 6 per minute are less efficient than those occurring at 3 per minute.

The important abnormalities in gastric slow wave activity are probably those involving an oral spread or a loss of coupling of the electrical slow waves. As gastric slow wave determines the frequency and direction of propagation of contractions, these abnormalities could have a profound effect on gastric contractions and emptying. If the gastric oscillators were coupled in an oral direction, contractions could only move in that direction resulting in delayed emptying and possibly vomiting. A loss of coupling in the antrum would produce incoordinated contractions and retard gastric emptying considerably. Unfortunately, this study indicates that neither of these abnormalities can be accurately assessed with transcutaneous recordings. The practical value of the test is, therefore, severely limited. Future endeavours should focus on techniques for improving non-invasive recordings of gastric electrical activity before too much reliance is placed on recordings made using current techniques.

We offer a final note of caution. Often a record is noisy. It is tempting to interpret apparent irregularities in transcutaneous recording to be a

true reflection of real gastric electrical activity. Such interpretations could be dangerous, particularly if they led to therapeutic interventions.

This work was supported in part by grant MA-5946 from the Medical Research Council of Canada.

- 1 Hamilton JW, Bellahsene BE, Reichelder M, Webster JG, Bass P. Human electrogastragrams: comparison of surface and mucosal recordings. *Dig Dis Sci* 1986; 31: 33-9.
- 2 Abell TL, Malagelada J-R. Glucagon evoked gastric dysrhythmias in humans shown by an improved electrogastrographic technique. *Gastroenterology* 1985; 88: 1932-40.
- 3 Bellahsene BE, Hamilton JW, Webster JG, Bass P, Reichelder M. An improved method for recording and analyzing the electrical activity of the human stomach. *IEEE Trans Biomed Eng* 1985; 32: 911-5.
- 4 Familoni BO, Kingma YJ, Bowes KL. A study of transcutaneous and intraluminal measurements of gastric electrical activity in humans. *Med Biol Eng Comput* 1987; 25: 397-402.
- 5 Geldof H, Van Der Schee EJ, Van Blankenstein M, Grashuis JL. Electrogastrographic study of gastric myoelectrical activity in patients with unexplained nausea and vomiting. *Gut* 1986; 27: 799-808.
- 6 You CH, Chey WY. Study of electromechanical activity of the stomach in humans and in dogs with particular attention to tachygastric. *Gastroenterology* 1980; 86: 1460-8.
- 7 You CH, Lee KY, Chey WY, Mengur R. Electrogastrographic study of patients with unexplained nausea, bloating and vomiting. *Gastroenterology* 1980; 79: 311-4.
- 8 Abell TL, Malagelada J, Lucas AR, et al. Gastric electromechanical and neurohormonal function in anorexia nervosa. *Gastroenterology* 1987; 93: 958-65.
- 9 Abell TL, Camilleri M, Malagelada J-R. High prevalence of gastric electrical dysrhythmias in diabetic gastroparesis. *Gastroenterology* 1985; 88: 1299.
- 10 Pfister CJ, Hamilton JW, Nagel N, Bass P, Webster JG, Tompkins WJ. Use of spectral analysis in the detection of frequency differences in the electrogastragrams of normal and diabetic subjects. *IEEE Trans Biomed Eng* 1988; 35: 935-41.
- 11 Telander RL, Morgan KG, Kreulen DL, Schmalz PF, Kelly KA, Szurszewski JK. Human gastric atony with tachygastric and gastric retention. *Gastroenterology* 1978; 75: 497-501.
- 12 Koch KL, Creasey GW, Dwey A, Vasey M, Stern RM. Gastric dysrhythmia and nausea of pregnancy [Abstract]. *Dig Dis Sci* 1987; 32: 909.
- 13 Stern RM, Koch KL, Liebowitz HW, Lindblad IM, Shupert CL, Stewart WR. Tachygastric and motion sickness. *Aviat Space Environ Med* 1985; 56: 1074-7.
- 14 Stern RM, Koch KL, Stewart WR, Lindblad IM. Spectral analysis of tachygastric recorded during motion sickness. *Gastroenterology* 1987; 92: 92-7.
- 15 Rague BW, Oman CM. Use of a microcomputer system for running spectral analysis of EGG's to predict the onset of motion sickness. *Proc IEEE 9th Annual Conf of Eng in Med and Biol Society*, 1987: 87-90.
- 16 Nelsen TS, Kohatsu S. Clinical electrogastrography and its relationship to gastric surgery. *Am J Surg* 1968; 116: 215-22.
- 17 Sarna SK, Bowes KL, Daniel EE. Post-operative gastric electrical control activity in man. In: Daniel EE, ed. *Gastrointestinal motility*. Vancouver: Mitchell Press, 1974: 73-83.
- 18 McIntyre JA, Deitel M, Baida M, Jalil S. The human electrogastragram at operation: a preliminary report. *Can J Surg* 1969; 12: 275-84.
- 19 Mirrizi N, Scafoglieri U. Optimal direction of the electrogastrographic signal in man. *Med Biol Eng Comput* 1983; 21: 385-9.
- 20 Familoni BO, Kingma YJ, Bowes KL. Noninvasive assessment of human gastric motor function. *IEEE Trans Biomed Eng* 1987; 34: 30-6.
- 21 Ramirez W. *The FFT fundamentals and concepts*. New York: Prentice-Hall, 1985.
- 22 Code CF, Szurszewski JH, Kelly KA, Smith IB. A concept of control of gastrointestinal motility. *Handbook of physiology: alimentary canal, Section 6*. Vol. 5. Washington DC: American Physiological Society.
- 23 Plonsey R. *Bioelectric phenomena*. New York: McGraw-Hill, 1979: 202-9.
- 24 Kingma YJ, Durdle NG, Bowes KL, Kocylowski M, Szmids J. Size of electrical oscillating regions in the canine colon. In: Christensen J, ed. *Gastrointestinal motility*. New York: Raven Press, 1980: 425-31.
- 25 Kingma YJ. *Spectral analysis of gastrointestinal electrical signals*. Automedica, 1987: 237-48.