

Small bowel morphology in British Indian and Afro-Caribbean subjects: evidence of tropical enteropathy

G M Wood, J C Gearty, B T Cooper

Abstract

Distal duodenal biopsy specimens taken from 30 white, 35 Indian, and 20 Afro-Caribbean residents of West Birmingham during routine endoscopy for dyspepsia, were assessed by dissecting microscopy and morphometry. Finger-shaped villi were significantly less frequent in the Indian and Afro-Caribbean subjects than in the white subjects when assessed by dissecting microscopy ($p < 0.005$), and both immigrant groups had decreased mucosal thickness ($p < 0.01$), villous height ($p < 0.001$), villous: crypt ratios ($p < 0.01$) and enterocyte height ($p < 0.05$) compared with the white group. In the Indian subjects, villous height and villous: crypt ratios correlated significantly with the time since the last visit to the Indian subcontinent ($p < 0.005$). Serum alkaline phosphatase values were significantly higher in the Indian subjects compared with the whites ($p < 0.02$), and serum globulins were increased in both the Afro-Caribbean and Indian subjects ($p < 0.01$). There were no correlations between morphometric indices and body habitus or biochemical or haematological indices and the long term effect of the morphological changes is not clear.

Small bowel morphology of inhabitants of tropical countries differs from that of white Europeans and North Americans; blunted villi and increased inflammatory cell infiltrates are common even in asymptomatic people.¹⁻⁸ It is unclear whether this tropical enteropathy is genetic or environmental in origin, and effects of migration to temperate lands on villous architecture have not been properly documented. Visitors from temperate countries, however, may develop these changes in villous architecture while resident in the tropics^{9,10} and regression of these abnormalities on return is described.¹¹

The aims of this study were to compare the morphological appearance of distal duodenal biopsy specimens from British residents of different ethnic origin and correlate morphology with length of domicile in this country.

Methods

SUBJECTS

Distal duodenal biopsy specimens were obtained, with informed consent, from 35 Indian (from the Indian subcontinent), 30 white, and 20 Afro-Caribbean residents of West Birmingham undergoing routine outpatient diagnostic endoscopy for dyspeptic symptoms. Weights and heights were recorded and the body mass

TABLE I Clinical details of ethnic groups

	White subjects (n=30)	Indians (n=35)	Afro-Caribbeans (n=20)
Age: Mean (SD)	37.5 (14)	36.5 (13.1)	43.1 (15.3)
(Range)	(15-67)	(15-64)	(17-66)
Male:female	16:14	16:19	11:9
Years in UK: Median	-	20	26*
(Range)	-	(2-32)	(14-34)
Years since last home: Median	-	3	15.1**
(Range)	-	(0.25-20)	(0.33-34)
Height (m): Median	1.673	1.623***	1.664†
(Range)	(1.51-1.84)	(1.435-1.78)	(1.55-1.83)
Weight (kg): Median	66.3	61.5	70.3†
(Range)	(44-104)	(35.5-85)	(49.5-101.5)
Body mass index:			
Median	23.7	24.3	26.3
(Range)	(16.1-32.3)	(15-32.5)	(19.2-35.3)

*Indians v Afro-Caribbeans, $p < 0.01$; **Indians v Afro-Caribbeans, $p < 0.001$; ***White v Indians, $p < 0.05$. †Indians v Afro-Caribbeans, $p < 0.05$. There were no other significant differences between the groups.

index (weight (kg)/height² (m)) was calculated. Blood samples were taken for routine haematological and biochemical tests.

The subjects' country of origin and the total time they had been resident in the United Kingdom were noted as well as the date of the last visit to their native country.

Clinical details are shown in Table I; there were no significant differences between the groups with regard to age and body mass index, although the Indian subjects were of smaller stature than the white subjects ($p < 0.05$), and were smaller and weighed less than the Afro-Caribbean subjects ($p < 0.05$).

The Indian subjects had been resident in Birmingham for a significantly shorter time than the Afro-Caribbeans ($p < 0.01$) and had revisited their native country more recently ($p < 0.001$).

Two mucosal biopsy specimens were taken from beyond the distal end of the second part of the duodenum using the Olympus GIF-1T10 endoscope and large Olympus biopsy forceps (FB-13K). The specimens were washed in 0.9% saline and carefully orientated on monofilament nylon mesh (Schuco International Ltd, London) with the villous surface uppermost. Orientation was checked using dissecting microscopy and biopsy specimens were graded according to the following scheme: grade I, finger-shaped villi; grade II, finger and leaf-shaped villi; grade III, leaf-shaped villi; grade IV, leaf-shaped villi and ridges; grade V, ridges or convolutions, or both. The mounted specimens were fixed in formol saline, embedded in paraffin wax, and 3 μ sections were cut and stained with haematoxylin and eosin. Stained sections were identified by a code number and morphometric assessment was carried out blind by one observer. Intraepithelial lymphocytes were counted for at least 500 enterocytes on sections where central, basal enterocyte nuclei were present using a 100 \times

Gastroenterology Unit
and Department of
Pathology, Dudley Road
Hospital, Birmingham

G M Wood
J C Gearty
B T Cooper

Correspondence to:
Dr B T Cooper,
Gastroenterology Unit,
Dudley Road Hospital,
Birmingham B18 7QH.

Accepted for publication
9 April 1990

oil immersion lens and results expressed as intraepithelial lymphocytes/100 enterocytes.¹² Further morphometric assessment was carried out using a Leitz projecting microscope. Stained sections were projected onto a board at fixed magnification and the projected image was calibrated using a stage micrometer slide; measurements were made to the nearest mm. Enterocyte heights were estimated by measuring at least 20 cells randomly chosen throughout the section; selected cells had oval, basal nuclei and were located in the middle third of villi.¹³ Mean enterocyte heights (μ) were calculated. Mucosal thickness was estimated by measuring from the muscularis mucosae to the tips of at least 10 consecutive villi, and villous height was derived by subtraction of mean crypt depth (derived in a similar manner) from mean mucosal thickness. Villous:crypt and mucosal:crypt ratios were calculated.¹⁴ Surface area:volume ratios were derived by projecting images of stained sections onto a 15 line hexagonal pattern at constant magnification and random orientation. The ratio of the number of times the lines cut the mucosal surface ('c') to the number of times and end points of the lines fell on the lamina propria ('h') is an index of surface area:volume and the mean number of hits ('h') is an index of mucosal volume.¹⁵

Apart from ages of the subjects, which were normally distributed and analysed by the Student's *t* test, data were analysed by the Mann-Whitney U and χ^2 tests and Spearman rank correlation coefficient.

This study was approved by the Ethical Committee of West Birmingham Health Authority.

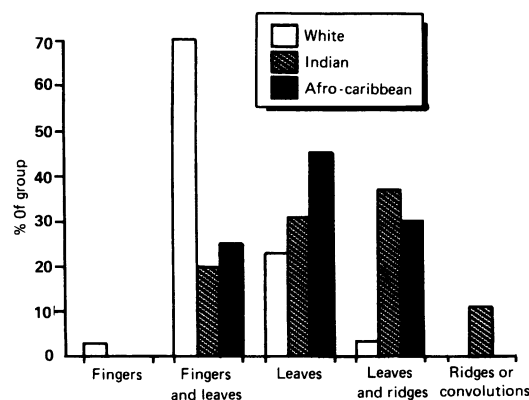
Results

DISSECTING MICROSCOPY

Results of dissecting microscopic assessment of villous morphology are shown in the Figure. Subtotal villous atrophy was not seen in any biopsy specimen. Digitate villi were present in 22 (73%) of the white subjects and were significantly less frequent in Indian (seven of 35, $p < 0.001$) and Afro-Caribbean (five of 20, $p < 0.005$) subjects. In the latter groups, leaves and ridges predominated.

MORPHOMETRY

Table II shows the results of objective morpho-



Appearances at dissecting microscopy of distal duodenal biopsy specimens from 30 white, 35 Indian, and 20 Afro-Caribbean subjects.

Specimens were grouped into the following grades - I: finger-shaped villi; II: finger and leaf-shaped villi; III: leaf-shaped villi; IV: leaf-shaped villi and ridges; V: ridges or convolutions, or both.

TABLE II Morphometric indices (median (range)) of duodenal biopsy specimens from White, Indian, and Afro-Caribbean subjects

Index	White subjects (n=30)	Indians (n=35)	Afro-Caribbeans (n=20)
Mucosal thickness (m)	584 (439-768)	531*** (401-628)	491† (327-718)
Crypt depth (m)	185 (123-249)	185 (127-282)	186 (135-274)
Villous height (m)	386 (287-529)	349*** (194-442)	302†† (138-581)
Villous:crypt ratio	2.21 (1.15-3.74)	1.97*** (0.79-3.1)	1.75†† (0.62-4.24)
Villous:mucosal ratio	0.69 (0.54-0.79)	0.64 (0.44-0.75)	0.64 (0.38-0.81)
Enterocyte height (m)	30.2 (25.1-35.1)	28.3** (22.4-34.2)	27.2* (22.4-35)
IEL count (/100 enterocytes)	15.2 (5.9-26.6)	18.4* (7.9-36.5)	13.9 (7.9-39.1)
Surface area: volume ratio	51.8 (31.5-93.1)	51 (22.2-87.7)	51.7 (34.6-77.4)
Mucosal volume	11.6 (7-14.7)	11.3 (7-17.2)	10.2 (6.7-15.5)

Immigrants v white subjects: * $p < 0.05$; ** $p < 0.02$; *** $p < 0.01$; † $p < 0.002$; †† $p < 0.001$.

IEL=intraepithelial lymphocyte.

metric assessment of mucosal biopsy specimens. In comparison with white subjects, Indians had significantly decreased mucosal thickness ($p < 0.01$), shorter villi ($p < 0.001$), lower villous: crypt and villous:mucosal ratios ($p < 0.01$), and lower enterocyte heights ($p < 0.02$). Intraepithelial lymphocyte counts were significantly higher in the Indian subjects ($p < 0.05$). There were no differences in crypt depth, surface to volume ratios, or mucosal volume.

Similar results were seen in Afro-Caribbean subjects, who had lower mucosal thickness ($p < 0.002$), villous heights ($p < 0.001$), villous:crypt ($p < 0.001$) and villous:mucosal ratios ($p < 0.02$), and lower enterocyte heights ($p < 0.05$) than white subjects but intraepithelial lymphocyte counts were similar. The only significant difference between the Indian and Afro-Caribbean subjects was a higher intraepithelial lymphocyte count in the Indian group ($p < 0.01$).

In the Indian subjects, there were no significant correlations between morphometric measurements and time of domicile in Britain. Villous heights and villous:crypt and villous:mucosal ratios, however, showed significant correlations with time since the last visit to the Indian subcontinent ($p < 0.005$). Thus lower values were seen in those who had more recently visited India. There were no significant correla-

TABLE III Differences in biochemical and haematological values (median (range)) between white, Indian, and Afro-Caribbean subjects

	White subjects (n=30)	Indians (n=35)	Afro-Caribbeans (n=20)
Mean corpuscular haemoglobin (pg)	29.5 (21.3-34.5)	28.5* (20.7-31.1)	29.5 (26.2-34.1)
Serum vitamin B ₁₂ (ng/ml)	339 (130-640)	287 (104-1129)	588** (307-1032)
Iron deficient	4/29	10/33	2/17
Serum globulins (g/l)	28 (23-25)	31*** (26-37)	31* (26-39)
Serum orosomucoids (g/l)	0.73 (0.26-1.14)	0.62* (0.32-1.32)	0.57 (0.43-1.0)
Serum alkaline phosphatase (IU/l)	66 (3-196)	73†† (30-154)	79 (46-174)

*White subjects v Indians, $p < 0.05$; **Afro-Caribbeans v white subjects and Indians, $p < 0.001$; ***Indians v white subjects, $p < 0.001$. †Afro-Caribbeans v white subjects, $p < 0.01$; ††Indians v white subjects, $p < 0.02$.

tions for the Afro-Caribbean subjects with either length of domicile in Britain or time since last visit home.

Differences in biochemical and haematological values between the three groups are shown in Table III. Serum globulin ($p < 0.001$) and alkaline phosphatase values ($p < 0.02$) were higher in the Indian than in the white subjects, and mean corpuscular haemoglobin and serum orosomuroid values were lower ($p < 0.05$). Serum vitamin B₁₂ concentrations were significantly higher in the Afro-Caribbean group compared with both the white and Indian subjects ($p < 0.001$), and serum globulins were raised compared with the white subjects ($p < 0.01$). There was no significant difference between the groups with respect to haemoglobin, mean cell volume, serum folate, albumin, calcium, and phosphate. No significant differences could be detected between Indian subjects with villous: crypt ratios < 2 ($n = 18$) and those with ratios > 2 ($n = 17$) with respect to body habitus or biochemical or haematological variables.

Discussion

Asymptomatic inhabitants of tropical countries have different small bowel morphology to those living in temperate lands – leaf villi and ridges are more common and digitate villi are unusual on dissecting microscopy and histologically, villi are broader and more stunted, often with an increased inflammatory cell infiltrate.¹⁻⁸ These changes are sometimes associated with evidence of mild malabsorption, usually of xylose^{1 2 4 5 11 16} and with changes in small intestinal passive permeability.¹⁷ Such minor abnormalities in small bowel morphology have been described in asymptomatic Thais,¹⁴ Vietnamese,¹⁸ black Africans,^{7 8 19 20} Indians,^{5 21} Pakistanis,^{2 3} Mexicans,²² Haitians, and Puerto Ricans.⁶

The relation between these minor small bowel abnormalities (tropical enteropathy) and similar but more noticeable abnormalities in symptomatic subjects (tropical sprue) is controversial and the conditions may represent different aspects of the same disease process²³ or may be different disorders.⁵ The cause of the minor abnormalities in healthy subjects is also unclear. Jejunal biopsy specimens from stillborn fetuses in the tropics have digitate villi, but in infancy leaves and ridges predominate.²⁴ This implies that these changes are environmental rather than genetic. Environmental factors that could be responsible are nutrition,²² diet,²⁵ parasites, viral and bacterial infections,^{5 9 19 20} and socioeconomic status.^{9 20 26} Direct evidence for an environmental cause is provided by studies of American expatriates living in tropical countries in whom decreased xylose and vitamin B₁₂ absorption and minor abnormalities on dissecting microscopy of small bowel biopsy specimens were found.^{9 27} These abnormalities returned to normal in almost all cases after repatriation to the United States.^{11 27} The changes did not seem to be related to the type of food eaten – for example, spiced food – and it was suggested that they were due to recurrent gastrointestinal infections.

In the only two studies of small bowel mucosa of immigrants from tropical countries resident in

a temperate climate, some immigrants to the United States had evidence of jejunal morphological abnormalities and xylose malabsorption which were less noticeable the longer they had lived in the United States.^{28 29}

This is the first study to investigate immigrants to Britain from tropical countries and has used biopsy specimens from the distal duodenum where morphometric parameters are similar to those of the jejunum, although there is a tendency for villi to be shorter and villous: crypt ratios lower.¹⁴ We have shown that Indian and Afro-Caribbean subjects living in England had shorter villi and enterocytes than white subjects. The similar surface area: volume ratios in the groups may be explained by the lower mucosal thickness in the non-white subjects.

Although we did not study asymptomatic patients, we think our study reflects the 'normal' small bowel morphology of immigrant subjects, as no subject had diarrhoea or the clinical features of small bowel disease. The observation that total length of residence in the United Kingdom of the Indian subjects did not correlate with changes in villous architecture but that length of time since their last visit to India did, implies that an environmental rather than a genetic factor may cause the changes in villous morphology. The morphological abnormalities decreased with time spent in the temperate climate which suggests that an environmental factor such as spiced food is not responsible. The increased intraepithelial lymphocyte count and raised serum globulin values suggest that these changes may be related to intestinal infections, perhaps reacquired during visits to India.

The relation between the time since the last visit home and villous architecture was not seen in the Afro-Caribbeans, who had lived longer in Birmingham than the Indian subjects. Few had recently visited the West Indies, which suggests the possibility of genetic factors. In contrast to India, little is known about small bowel histology in normal residents of the English-speaking West Indies, although tropical enteropathy and tropical sprue occur in Puerto Rico, Haiti, and the Dominican Republic.^{6 29 30 31}

We have been unable to find any relation between villous abnormalities and anthropometric, haematological, or biochemical measurements in the immigrant subjects, although few were studied within the first six months after a visit to a tropical country when such abnormalities may have been apparent. Lack of similar correlations, however, has been noted in the tropics.² The differences in serum globulin between immigrants and the indigenous population is probably not surprising as it is known that residents of tropical countries have hyperglobulinaemia, which may be one of the consequences of alterations in passive small intestinal permeability associated with tropical enteropathy.¹⁷ The other minor differences between the groups are unexplained.

Clinicians should be aware of these minor changes in small bowel morphology in immigrants, should not necessarily assume that they are abnormal, and would be unwise to ascribe symptoms to them. The long term effects of this tropical enteropathy are uncertain, how-

ever, and consequences for nutritional status or ill effects from possible associated changes in intestinal permeability cannot be excluded.

We thank Sister A Huggins and the staff of the Endoscopy Department at Dudley Road Hospital, Birmingham for expert assistance.

- 1 Sprinz H, Sribhibhadh R, Gangarosa GJ, Benyajati C, Kundel D, Halstead S. Biopsies of small bowel of Thai people with special reference to recovery from Asiatic cholera and to intestinal malabsorption syndrome. *Am J Clin Pathol* 1962; **38**: 43-51.
- 2 Lindenbaum J, Jamial Alam AKM, Kent TH. Subclinical small intestinal disease in East Pakistan. *Br Med J* 1966; **2**: 1616-9.
- 3 Russell PK, Aziz MA, Ahmed N, Kent TH, Gangarosa EJ. Enteritis and gastritis in young asymptomatic Pakistani men. *Am J Dig Dis* 1966; **11**: 296.
- 4 Troncale FJ, Keusch GT, Miller LH, Olsson RA, Buchanan RD. Normal absorption in Thai subjects with non-specific jejunal abnormalities. *Br Med J* 1967; **4**: 578-80.
- 5 Baker SJ, Mathan VI. Tropical enteropathy and tropical sprue. *Am J Clin Nutr* 1972; **25**: 1047-55.
- 6 Schenk EA, Klipstein FA, Tomasini JT. Morphologic characteristics of jejunal biopsies from asymptomatic Haitians and Puerto Ricans. *Am J Clin Nutr* 1972; **25**: 1080-3.
- 7 Banwell JG, Hutt MSR, Tunnicliffe R. Observations on jejunal biopsy in Ugandan Africans. *East Afr Med J* 1964; **41**: 46-54.
- 8 Cook GC, Kajubi SK, Lee FD. Jejunal morphology of the Africans in Uganda. *J Pathol* 1969; **98**: 157-69.
- 9 Lindenbaum J, Kent TH, Sprinz H. Malabsorption and jejunitis in American Peace Corps volunteers in Pakistan. *Ann Intern Med* 1966; **65**: 1201-9.
- 10 Klipstein FA. Tropical sprue in travellers and expatriates living abroad. *Gastroenterology* 1981; **80**: 590-600.
- 11 Lindenbaum J, Gerson CD, Kent TH. Recovery of small-intestinal structure and function after residence in the tropics. I. Studies in Peace Corps Volunteers. *Ann Intern Med* 1971; **74**: 218-22.
- 12 Ferguson A, Murray D. Quantitation of intraepithelial lymphocytes in human jejunum. *Gut* 1971; **12**: 988-94.
- 13 Stewart JS, Pollock DJ, Hoffbrand AV, Mollin DL, Booth CC. A study of proximal and distal intestinal structure and absorptive function in idiopathic steatorrhea. *Q J Med* 1967; **36**: 425-44.
- 14 Scott BB, Losowsky MS. Patchiness and duodenal-jejunal variation of the mucosal abnormality in coeliac disease and dermatitis herpetiformis. *Gut* 1976; **17**: 984-92.
- 15 Dunnill MS, Whitehead R. A method for the quantitation of small intestinal biopsy specimens. *J Clin Pathol* 1972; **25**: 243-6.
- 16 Cook GC. Impairment of D-xylose absorption in Zambian patients with systemic intestinal infections. *Am J Clin Nutr* 1972; **25**: 490-3.
- 17 Ukabam SO, Homeida MMA, Cooper BT. Small intestinal permeability in normal Sudanese subjects: evidence of tropical enteropathy. *Trans R Soc Trop Med Hyg* 1986; **80**: 204-7.
- 18 Colwell EJ, Welsh JD, Legters LJ, Proctor RF. Jejunal morphological characteristic in South Vietnamese residents. *JAMA* 1968; **206**: 2273-6.
- 19 Falaiye JM. Present status of subclinical intestinal malabsorption in the tropics. *Br Med J* 1971; **4**: 454-8.
- 20 Thomas G, Clain DJ, Wicks ACB. Tropical enteropathy in Rhodesia. *Gut* 1976; **17**: 888-94.
- 21 Jeejeebhoy KN, Desai HG, Noronha JM, Antia FP, Parekh DV. Idiopathic tropical diarrhoea with or without steatorrhea (tropical malabsorption syndrome). *Gastroenterology* 1966; **51**: 333-44.
- 22 Garcia S. Malabsorption and malnutrition in Mexico. *Am J Clin Nutr* 1968; **21**: 1066-76.
- 23 Klipstein FA. Tropical sprue - an iceberg disease? *Ann Intern Med* 1967; **66**: 622-3.
- 24 Chako CJG, Paulson KA, Mathan VI, Baker SJ. The villus architecture of the small intestine in the tropics: a necropsy study. *J Pathol* 1969; **98**: 146-51.
- 25 Owen RL, Brandberg LL. Jejunal morphologic consequences of a vegetarian diet. *Gastroenterology* 1977; **72**: 111.
- 26 Bennett MK, Sachdev GK, Jewell DP, Anand BS. Jejunal mucosal morphology in healthy north Indian subjects. *J Clin Pathol* 1985; **38**: 368-71.
- 27 Sheehy TW, Legters LJ, Wallace DK. Tropical jejunitis in Americans serving in Vietnam. *Am J Clin Nutr* 1968; **21**: 1013-22.
- 28 Klipstein FA, Falaiye JM. Tropical sprue in expatriates from the tropics living in the continental United States. *Medicine* 1969; **48**: 475-91.
- 29 Gerson CD, Kent TH, Saha J, Siddiqi N, Lindenbaum J. Recovery of small-intestinal structure and function after residence in the tropics. II. Studies in Indians and Pakistanis living in New York City. *Ann Intern Med* 1971; **75**: 41-8.
- 30 Klipstein FA, Samloff MI, Schenk EA. Tropical sprue in Haiti. *Ann Intern Med* 1966; **64**: 575-94.
- 31 Klipstein FA, Beauchamp I, Corcino JJ, et al. Nutritional status and intestinal function among rural populations of the West Indies. II. Barrio Nuevo, Puerto Rico. *Gastroenterology* 1972; **63**: 758-67.
- 32 Klipstein FA, Rubio C, Montas S, Tomasini JT, Castillo RG. Nutritional status and intestinal function among rural populations of the West Indies. III. Barrio Cabreto, Dominican Republic. *Am J Clin Nutr* 1973; **26**: 87-94.