

CASE REPORTS

Increase in γ/δ T cell receptor bearing lymphocytes in normal small bowel mucosa in latent coeliac disease

M Mäki, Kati Holm, P Collin, E Savilahti

Abstract

A jejunal biopsy specimen from an asymptomatic 35 year old man was studied because of a low serum titre of reticulin antibody and the finding of coeliac disease in his son. In this specimen villous structure was quite normal as was the total number of intraepithelial lymphocytes, but the number of γ/δ T cell receptor bearing lymphocytes was 10 times higher than the mean in control subjects. Two years later a further biopsy specimen was obtained because of clinical symptoms and an increased titre of reticulin antibody. This specimen showed villous atrophy with crypt hyperplasia and increased infiltration of intraepithelial lymphocytes compatible with coeliac disease. A control biopsy specimen taken during gluten free diet showed normalisation of the villous architecture. Latent coeliac disease may be characterised by an increase in γ/δ positive cells similar to that seen in established coeliac disease.

Latent gluten sensitive enteropathy has been described in patients with dermatitis herpetiformis, in whom small bowel mucosal deterioration was shown to occur after adding extra gluten to the diet.¹⁻³ Gluten loading may cause jejunal mucosal changes compatible with coeliac disease in healthy individuals too.^{2,4} Latent coeliac disease was recently described in four patients in whom a first biopsy showing normal small intestinal mucosa was succeeded by specimens showing overt coeliac disease after a further 2.6 to 9 years on a diet containing gluten.⁵

The recognition of latent coeliac disease may be important because of the association with malignancies in both overt⁶ and latent forms of the disease.⁷ Gut humoral immunity may provide a diagnostic index of latent coeliac disease,⁸ and increased intraepithelial lymphocyte counts in normal jejunal mucosal specimens together with HLA-DR3 status may also identify those with a genetically determined predisposition to the disease.⁹

An interesting method of detecting latent coeliac disease is to identify specific markers in the small intestinal mucosa. Intestinal γ/δ T cell receptor bearing lymphocytes have been shown to be increased in patients with active coeliac disease¹⁰⁻¹² compared with normal subjects.^{10,12-15} It has also been recently shown that γ/δ T cell receptor bearing lymphocytes are constantly increased in coeliac disease, regardless of dietary

treatment and jejunal morphology.¹⁶ This finding is the only permanent abnormality described thus far in the jejunal mucosa of patients with coeliac disease.

In this study we show for the first time a greatly increased number of γ/δ T cell receptor bearing cells in normal bowel mucosa in a patient later shown to have coeliac disease.

Methods

Routine small bowel biopsy was performed with an adult Watson biopsy capsule and the specimens were studied under light microscopy. Part of the initial biopsy specimen was freshly embedded in optimal temperature cutting compound (Tissue-Tec, Miles Inc) and stored at -70°C for later use.

γ/δ T cell receptor bearing intraepithelial lymphocytes were recognised in $5\ \mu$ cryostat tissue sections by the monoclonal antibody TCRdelta1 (Tcell Sciences Inc, Cambridge, MA) and a three layer peroxidase staining method.¹⁶ The α/β T cell receptor molecules were detected by the betaF1 antibody (Tcell Sciences Inc, Cambridge, MA) and CD3 antigens by Leu4 monoclonal antibody (Beckton-Dickinson, Mountain View, CA).

Altogether, 13 jejunal specimens from patients with a mean age of 38 years (range 17-57 years) and with histologically proved normal small bowel mucosal architecture served as controls for the immunohistochemical studies. In addition, 13 jejunal specimens from patients with a mean age of 34 years (range 15-52 years) and with newly diagnosed coeliac disease were studied.

Case report and results

Jejunal biopsy was undertaken when the patient was 35 years old because his son was found to have coeliac disease and because he was homozygous for HLA DR3 and had a low titre (1:10) of IgA class serum reticulin antibodies.⁵ He had always eaten a normal diet containing gluten. He had experienced no abdominal symptoms but had had epilepsy diagnosed earlier and had infrequent seizures.

The initial biopsy specimen excluded coeliac disease. It showed completely normal villous architecture (Figure (top)) with villus/crypt ratio of 3.72 and an intraepithelial lymphocyte count of 18/100 epithelial cells.

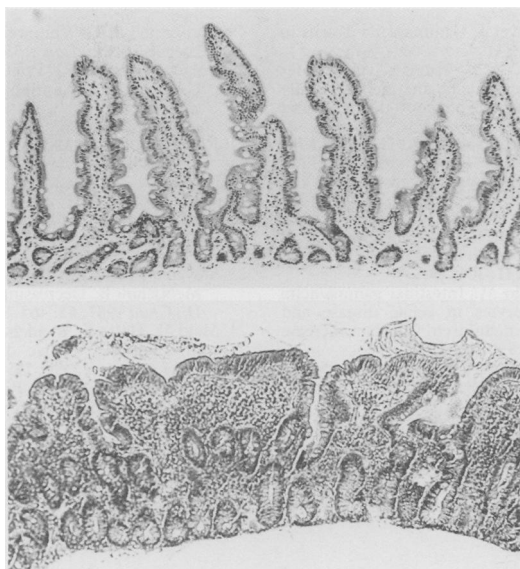
At the age of 37 years his epilepsy worsened and he experienced more frequently convulsions.

Department of Clinical Sciences, University of Tampere, Tampere, Finland
M Mäki
Kati Holm,
P Collin

Children's Hospital, University of Helsinki, Helsinki, Finland
E Savilahti

Correspondence to:
Dr Markku, Mäki,
Department of Clinical Sciences, University of Tampere, SF-33520 Tampere, Finland.

Accepted for publication
16 December 1990



Top, initial jejunal biopsy specimen taken from a 35 year old man on a diet containing gluten since early childhood. Normal appearance of the mucosal architecture is seen (original magnification $\times 100$). Bottom, a second biopsy specimen taken at the age of 37 years showed clear deterioration of the mucosa. (original magnification $\times 100$).

His serum reticulín antibody titre had increased (1:50) and a second biopsy was therefore performed. Histologically, the mucosa showed clear deterioration with villous atrophy and crypt hyperplasia. The Figure (bottom) shows the mucosal deterioration. The intraepithelial lymphocyte count was now 56/100 epithelial cells and the villus height/crypt depth ratio was 1.30. The patient was prescribed a gluten free diet, and a control biopsy taken six months later showed a return to normal of the villous architecture with a villus height/crypt depth ratio of 4.60 and an intraepithelial lymphocyte count that was still high at 32/100 epithelial cells.

The initial normal biopsy specimen was studied again by immunohistochemical methods. The results are shown in the Table. Specific staining showed increased CD3 cells in the epithelium. The density of γ/δ T cell receptor bearing cells in the jejunal epithelium was 10 times higher than control values but near the range observed in patients with coeliac disease and subtotal villous atrophy.

Discussion

It is generally accepted that a normal small bowel biopsy specimen, taken for the first time when the patient is eating a normal diet containing

Numbers of intraepithelial lymphocytes (cells/mm) expressing surface antigen CD3 and T cell receptor α/β or γ/δ in normal small bowel biopsy specimen of a patient with latent coeliac disease, control subjects, and coeliac disease patients with subtotal villous atrophy

Surface antigen	Patient (No)	Control (n=13) (Median (range))	Coeliac disease (n=13) (Median (range))
CD3	81	47 (16-88)	131 (83-187)
α/β	49	39 (7-67)	95 (37-109)
γ/δ	31	2.0 (0-8.5)	45 (33-89)

gluten, rules out a diagnosis of coeliac disease once and for all. There are exceptions in the published reports, however, that indicate that this is probably not the whole truth.^{4 5 7 17-22} We have described one more patient with latent coeliac disease and have shown that the initial unequivocally normal small bowel mucosa expressed numerous γ/δ T cell receptor bearing lymphocytes, which is a very typical sign of coeliac disease¹⁰⁻¹² in contrast to normal small bowel mucosa.^{10 12-15} The normalised mucosa of coeliac patients on gluten free diet, however, show a similar increase.¹⁶

Late developing mucosal atrophy in coeliac disease may be much more common than previously assumed. Recent reports indicate that coeliac disease in children is becoming more rare.²³ Even if typical forms of coeliac disease had disappeared from study cohorts, however, we have, by following up cohorts, shown that the disease does exist and occurs late in these.²⁴ We find it difficult to accept that adolescents and adults diagnosed at older ages with mild or no abdominal symptoms²⁴⁻²⁶ have had villous atrophy for years; we believe that the villous atrophy has developed late, perhaps because of environmental triggering factors such as viral infections or an increase in gluten intake. In these patients a mucosal biopsy specimen taken before symptoms are evident would show normal villous architecture even if they had eaten normal amounts of gluten since early childhood. Detection of considerably increased numbers of intraepithelial γ/δ T cell receptor bearing lymphocytes in these 'normal' small bowel mucosal specimens could thus identify those with latent coeliac disease. It remains to be seen, however, whether this phenomenon in the intestine is specific for coeliac disease.

This study was supported by the Emil Aaltonen Foundation, the Sigrid Juselius Foundation, and by the Academy of Finland (Dr Markku Mäki, Researcher).

- Weinstein WM. Latent celiac sprue. *Gastroenterology* 1974; **66**: 489-93.
- Ferguson A, Blackwell JN, Barnetson RS. Effects of additional dietary gluten on the small-intestinal mucosa of volunteers and of patients with dermatitis herpetiformis. *Scand J Gastroenterol* 1987; **22**: 543-9.
- Chorzelski TP, Rosinska D, Beutner EH, Sulej J, Kumar V. Aggressive gluten challenge of dermatitis herpetiformis cases converts them from seronegative to seropositive for IgA-class endomysial antibodies. *J Am Acad Dermatol* 1988; **18**: 672-8.
- Doherty M, Barry RE. Gluten-induced mucosal changes in subjects without overt small-bowel disease. *Lancet* 1981; **i**: 517-20.
- Mäki M, Holm K, Koskimies S, Hällström O, Visakorpi JK. Normal small bowel biopsy followed by coeliac disease. *Arch Dis Child* 1990; **65**: 1137-41.
- Holmes GKT, Prior P, Lane MR, Pope D, Allan RN. Malignancy in coeliac disease - effect of a gluten free diet. *Gut* 1989; **30**: 333-8.
- Freeman HJ, Chiu BG. Multifocal small bowel lymphoma and latent celiac sprue. *Gastroenterology* 1986; **90**: 1992-7.
- O'Mahony S, Vestey JP, Ferguson A. Similarities in intestinal humoral immunity in dermatitis herpetiformis without enteropathy and in coeliac disease. *Lancet* 1990; **335**: 1487-90.
- Marsh MN, Bjarnason I, Shaw J, Ellis A, Baker R, Peters TJ. Studies of intestinal lymphoid tissue. XIV - HLA status, mucosal morphology, permeability and epithelial lymphocyte populations in first degree relatives of patients with coeliac disease. *Gut* 1990; **31**: 32-3.
- Spencer J, Isaacson PG, Diss TC, MacDonald TT. Expression of disulfide-linked and nondisulfide-linked forms of the T cell receptor - gamma/delta heterodimer in human intestinal intraepithelial lymphocytes. *Eur J Immunol* 1989; **19**: 1335-8.
- Halstensen TS, Scott H, Brandtzaeg T. Intraepithelial T cells of TcRgamma/delta+CD8- and Vdelta1/Jdelta1+ phenotypes are increased in coeliac disease. *Scand J Immunol* 1989; **30**: 665-72.

- 12 Viney J, MacDonald TT, Spencer J. Gamma/delta T cells in gut epithelium. *Gut* 1990; 31: 841-4.
- 13 Groh V, Porcell S, Fabbi M, *et al.* Human lymphocytes bearing T cell receptor gamma/delta are phenotypically diverse and evenly distributed throughout the lymphoid system. *J Exp Med* 1989; 169: 1277-94.
- 14 Brandtzaeg P, Bosnes V, Halstensen TS, Scott H, Sollid LM, Valnes KN. T lymphocytes in human gut epithelium preferentially express the alpha/beta antigen receptor and are often CD45/UCHL1-positive. *Scand J Immunol* 1989; 30: 123-8.
- 15 Bucy RP, Chen C-LH, Cooper MD. Tissue localization and CD8 accessory molecule expression of T gamma/delta cells in humans. *J Immunol* 1989; 141: 3045-9.
- 16 Savilahti E, Arato A, Verkasalo M. Intestinal gamma/delta receptor bearing T lymphocytes in celiac disease and inflammatory bowel diseases in children. Constant increase in celiac disease. *Pediatr Res* 1990; 28: 579-81.
- 17 Kamath KR, Dorney SFA. In discordance for coeliac disease in monozygotic twins permanent? *Pediatr Res* 1983; 17: 422.
- 18 Salazar de Sousa J, Ramos de Almeida JM, Monteiro MW, Magalhaes-Ramalho P. Late onset coeliac disease in the monozygotic twin of a coeliac child. *Acta Paediatr Scand* 1987; 76: 172-4.
- 19 McConnell RB, Whitewell F. Small-intestinal histology in coeliac disease. *Lancet* 1975; ii: 418.
- 20 Polanco I, Larrauri J, Prieto G, Guerrero J, Pena AS, Varquez C. Severe villous atrophy appearing at different ages in two coeliac siblings with identical HLA haplotypes. *Acta Paediatr Belg* 1980; 33: 276.
- 21 Rolles CJ, Kyaw-Myint TB, Wai-Kee Sin, Andersom CM. The familial incidence of asymptomatic coeliac disease. In: McConnell RB, ed. *The genetics of coeliac disease*. Lancaster: MTP Press, 1981: 235-43.
- 22 Egan Mitchell B, Fottrell PF, McNicholl B. Early or pre-coeliac mucosa: development of gluten enteropathy. *Gut* 1981; 22: 65-9.
- 23 Stevens FM, Egan-Mitchell B, Cryan E, McCarthy CF, McNicholl B. Decreasing incidence of coeliac disease. *Arch Dis Child* 1987; 62: 465-8.
- 24 Mäki M, Holm K. Incidence and prevalence of coeliac disease in Tampere. Coeliac disease is not disappearing. *Acta Paediatr Scand* 1990; 79: 980-2.
- 25 Logan RFA, Tucker G, Rifkind EA, Heading RC, Ferguson A. Changes in clinical features of coeliac disease in adults in Edinburgh and the Lothians 1960-79. *BMJ* 1983; 286: 95-7.
- 26 Collin P, Hällström O, Mäki M, Viander M, Keyriläinen O. Atypical coeliac disease found with serological screening. *Scand J Gastroenterol* 1990; 25: 245-50.