

## PAPERS

## Epidermal growth factor in the oesophagus

J Jankowski, G Coghill, B Tregaskis, D Hopwood, K G Wormsley

### Abstract

**Epidermal growth factor (EGF) has been implicated in mitogenesis and oncogenesis in the gastrointestinal tract. To determine the role of EGF in oesophageal disease, its quantity and distribution in the oesophageal mucosa of control subjects and patients with oesophageal disease were studied. Oesophageal biopsy specimens, taken 20–40 cm from the incisors in 72 patients, were graded histologically and adjacent specimens were taken for immunohistochemical analysis of the distribution of EGF. In patients with Barrett's columnar lined oesophagus, specimens were also taken from the gastric cardia for comparison. Twenty two biopsy specimens showed oesophagitis, 20 Barrett's mucosa, and 30 were histologically normal. EGF was found in the capillary endothelium of the normal oesophageal papillae and basal mucosa. Significantly more EGF positive papillae were found in the normal mucosa (81%) than in the inflamed mucosa (42%) ( $p < 0.001$ ). The 20 patients with Barrett's mucosa showed abnormal expression of EGF in 25% of the isthmus and superficial epithelial cells. This study has shown that EGF is found only in the endothelial cells of the capillaries of the normal oesophageal mucosa and that the peptide is detectable significantly less frequently than normal in the inflamed oesophageal mucosa. EGF is also abnormally present, in large quantities, in the cytoplasm of the epithelial cells of Barrett's mucosa compared with gastric mucosa.**

(Gut 1992; 33: 1448–1453)

Epidermal growth factor (EGF) is a single chain polypeptide that is secreted by submandibular glands,<sup>1,2</sup> Brunner's glands in the duodenum,<sup>1,2</sup> Paneth cells of the small intestine,<sup>3</sup> and other exocrine glands, including the pancreas.<sup>4</sup> EGF is also found in 'a novel cell lineage containing neutral mucin' in the stomach and intestine adjacent to ulceration of the mucosa<sup>5</sup> and in many gastrointestinal tumours.<sup>6–8</sup> EGF is found in many body fluids, including saliva.<sup>2,3,9</sup> Circulating concentrations are low, but high concentrations are found within platelet granules.<sup>2,3,10,11</sup> By binding to the EGF receptor,<sup>12</sup> EGF exerts protean actions, including effects on wound healing,<sup>4,13,14</sup> cellular proliferation,<sup>12,13</sup> differentiation,<sup>15,16</sup> and oncogenesis<sup>5,17–19</sup> in the gastrointestinal tract. EGF has been reported to increase epithelial proliferation throughout the gastrointestinal tract<sup>20–25</sup> and also in other squamous epithelia including the skin.<sup>26</sup>

Whether there is a deficiency of secreted salivary EGF in patients with uncomplicated reflux oesophagitis is unknown, because reports have been contradictory.<sup>27,28</sup> In any case, the luminal route of action of EGF for maintaining oesophageal mucosal integrity seems unlikely since the oesophageal proliferative cells are situated in the basal layer.<sup>29,30</sup>

This study aimed to define the route whereby EGF gains access to the oesophageal epithelium, by immunohistochemical determination of the EGF distribution in biopsy specimens from healthy and diseased oesophageal mucosa, to determine whether it plays any role in the pathogenesis of oesophagitis.

### PATIENTS AND METHODS

Twenty eight women and 24 men (mean age 48 years (range 20–77)) who attended an endoscopy clinic were studied, as were a further 20 patients (eight women and 12 men) (median age 67 years (range 42–81) who had proven Barrett's mucosa. All patients gave informed consent. None were taking non-steroidal anti-inflammatory drugs: 26 were taking ranitidine 150 mg twice daily.

An oesophageal biopsy specimen was taken 20–40 cm from the incisors for histological examination. An immediately adjacent specimen was snap frozen in the endoscopy suite. Patients with Barrett's mucosa had three specimens taken from the area of columnar lined oesophagus and a fourth from the gastric cardia for comparison. Cryostat sections (6  $\mu$ m) were cut and EGF distribution was studied immunohistochemically. Monoclonal antibody (IgG) to EGF type 1 was supplied by Oncogene Science (Manhasset, NY, USA). This monoclonal antibody shows no cross reactivity with transforming growth factor alpha.<sup>31,32</sup> The avidin-biotin complex method followed by DAB visualisation were used to show the EGF-antibody complex.<sup>33</sup>

Negative control slides comprised normal oesophageal mucosa which had been treated with either avidin-biotin or EGF monoclonal antibody alone. In addition, we used absorbance experiments, incubating sections with purified EGF (BM, UK) at 10  $\mu$ g/ml. Sections of salivary glands containing EGF were used as positive controls.

Some sections were also stained immunohistochemically with polyclonal antibody to blood group factor H (Becton-Dickenson, UK). Blood group factor H has been reported to bind preferentially to endothelial cells as well as intestinal mucins and other glycoproteins.<sup>34</sup>

One of the authors (i) assessed the biopsy

Departments of Medicine and Pathology, University of Dundee, Dundee

J Jankowski  
G Coghill  
B Tregaskis  
D Hopwood  
K G Wormsley

Correspondence to:  
Dr J Jankowski,  
Histopathology Unit, Imperial  
Cancer Research Fund,  
Lincoln's Inn Field, London  
WC2A 3PX.

Accepted for publication  
29 March 1992

specimens and graded them according to the severity of histological inflammation (Jarvis criteria)<sup>35</sup> and (ii) classified Barrett's mucosa according to the type of metaplasia<sup>36</sup> – intestinal, junctional, or fundic. Sections of metaplastic mucosa that had a homogeneous pattern (>90% mucosal surface) were selected. Dysplasia of the Barrett's mucosa was classified according to Riddell.<sup>37</sup> Two observers independently assessed the EGF staining of the biopsy specimens without information about the histological status.

The percentage of positively stained papillae containing EGF endothelium in each biopsy specimen was calculated as a percentage of the total number of papillae.

The positive EGF staining of Barrett's mucosal biopsy specimens was graded according to a criteria that we have developed.<sup>8</sup> Five randomly viewed areas of at least 400, to a maximum of 1000, consecutive nucleated epithelial cells in well orientated sections were independently assessed by two observers. The sections were considered positive only if the number of epithelial cells which had at least 1+ staining was >10% of the total epithelial cells. The intensity of staining was graded as 0–3 (0 – no staining; 1+ – weakly positive; 2+ – moderately positive (cytoplasm positive but unstained cytoplasm also visible); and 3+ – strongly positive (entire cytoplasm densely stained)). The grade considered to be 3+ was stained as densely as simultaneously stained (control) submandibular tissue. In some sections with non-homogeneous staining, intensity per section was calculated. For example, if 500 cells were counted in one section and the number of cells of each intensity was as follows; 0=20, 1=150, 2=230, 3=100, the mean count was calculated as follows:  $(0 \times 20) + (1 \times 150) + (2 \times 230) + (3 \times 100) = 910/500$  and the mean intensity in the section was rounded up to '2'.

Sections of Barrett's mucosa were also stained to show neutral and acid mucous substances by the Alcian blue/diastase periodic acid Schiff method.

#### STATISTICS

The distribution of the data was Gaussian for normal and inflamed squamous oesophagitis and therefore analysis of variance was used to calculate the significance of intergroup distribution compared with intragroup variation to 95% confidence intervals. Because the distribution of the data from the Barrett's mucosa was not Gaussian the Kruskal-Wallis test was used to assess the variation between EGF expression in normal cardiac mucosa, Barrett's intestinal mucosa, and Barrett's junctional/cardiac mucosa. In addition, the Wilcoxon rank test was used to assess specifically the difference in EGF expression between Barrett's intestinal mucosa and Barrett's junctional/cardiac mucosa as well as between Barrett's mucosa with dysplasia and Barrett's mucosa without dysplasia.

#### Results

Thirty patients, 16 women and 14 men (median age 52 years) were subsequently shown to have

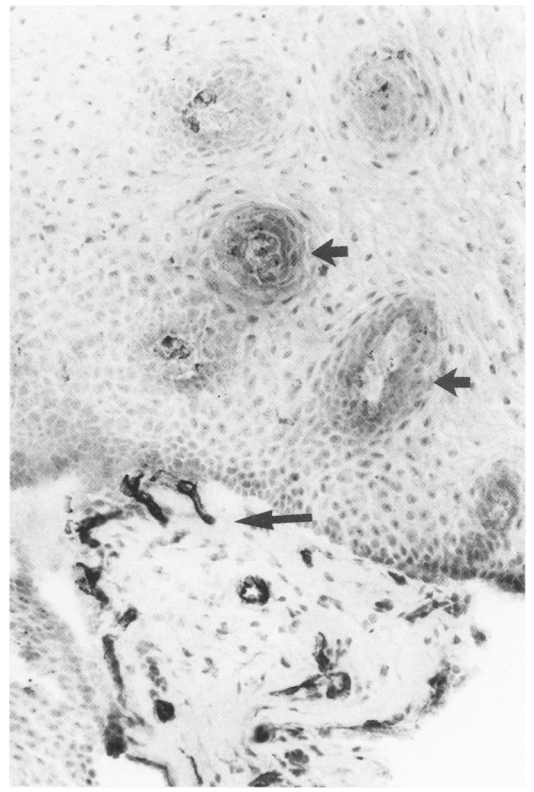


Figure 1: Photomicrograph of normal oesophageal mucosa cut in cross section and stained immunohistochemically with EGF (original magnification  $\times 100$ ). (The dark staining papillae contain EGF containing endothelium (arrowed).)

both normal endoscopic and histological findings. Twenty two patients (12 women and 10 men) (median age 42 years) were subsequently shown to have oesophageal inflammation endoscopically and histologically.

Twenty biopsy specimens had previously been noted to show Barrett's mucosa.

Some sections incubated with EGF monoclonal antibody and EGF peptide showed minimal staining in the cytoplasm but this was less than grade 1 in our grading system and therefore did not interfere with our quantitation.

The cells in the squamous mucosa of the oesophagus that showed positive staining for EGF were confined to the capillary endothelial cells immediately adjacent to the basal cells of the papillae (Fig 1). The staining pattern was cytoplasmic in nature. There was no discernable staining of the mucosa in the control slides treated with either EGF or avidin-biotin complex alone. The glandular and ductal cells of the salivary glands stained strongly for EGF.

Serial sections in 10 patients stained for the presence of blood group factor H (Fig 2A) showed that the staining pattern detected all endothelium whereas (Fig 2B) not all blood vessels stained positively with EGF, only those in the lamina propria. When the sections were stained with elastase red and yellow (a marker of elastic fibres in the smooth muscle of vascular tissue) none of the EGF positive vessels were stained (not shown).

In sections from normal oesophageal mucosa, almost all the endothelium in the papillae stain positively for EGF (Fig 3A). On the other hand, sections from inflamed oesophageal mucosa contain little EGF in the capillary endothelium

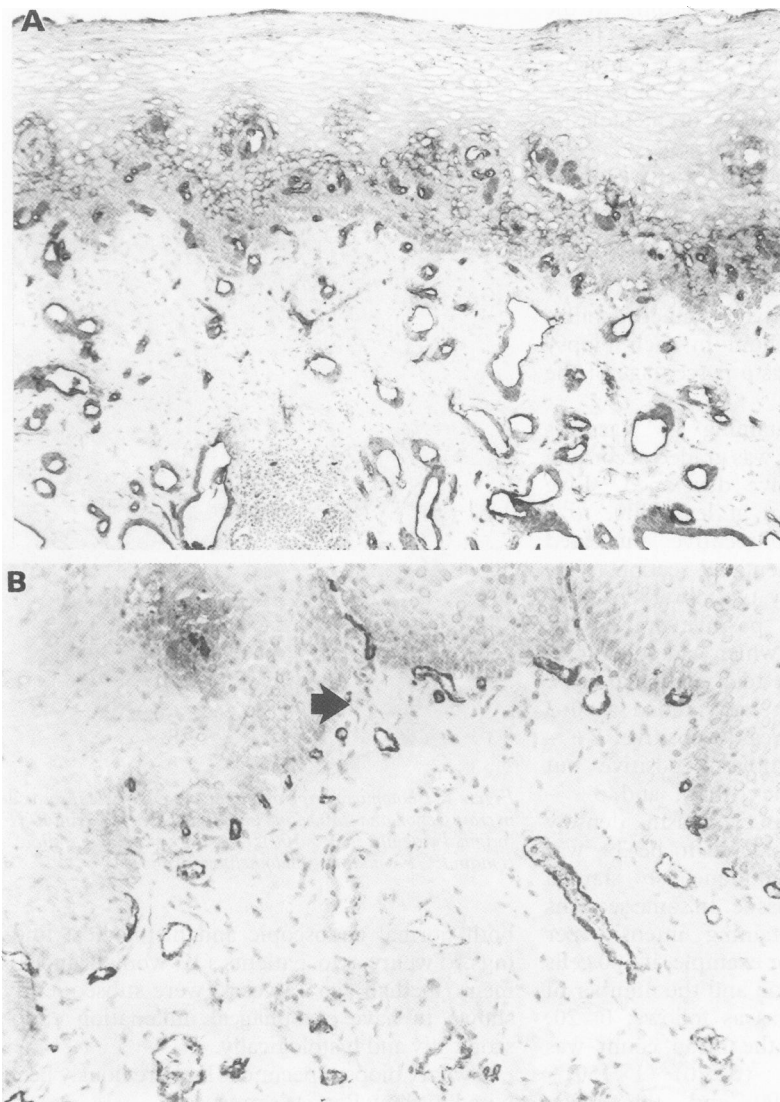


Figure 2: Both sections (A and B) are from sequential sections from the same biopsy specimen taken from a normal oesophagus. (A) Staining with blood group factor H (original magnification  $\times 40$ ). (All capillaries stained positively.) (B) Staining with EGF (original magnification  $\times 100$ ). (Capillaries in the basal lamina are usually positively stained (arrowed).)

resulting in few EGF positive papillae. Consequently, the proportion of papillae with EGF positive capillaries was significantly decreased in inflamed oesophageal mucosa (42.5%) compared with normal oesophageal mucosa (82.5%) ( $p < 0.001$ ) (Fig 4).

The 30 patients with normal endoscopic and histological findings had biopsy specimens taken at different levels of the oesophagus. Eleven patients had specimens taken at 20 cm, nine patients at 30 cm, and 10 at 40 cm. There was no significant difference in EGF staining of mucosa obtained from different levels of the oesophagus (Fig 5).

Periodic acid Schiff staining showed that most Barrett's mucosa and all the gastric mucosa contained neutral mucin (red colouration in cytoplasm) while some areas, especially those composed of intestinal mucosa, contained acid mucin (blue colouration in cytoplasm) or glands with both acid and neutral mucin (purple colouration in the cytoplasm). On histological examination, five of the subjects with Barrett's mucosa had moderate or high grade dysplasia,

while the other 15 had no dysplasia. Although the areas that stained positively for EGF corresponded well with the acid mucin or mixed mucin glands in intestinal-type mucosa, in the other types of Barrett's epithelium EGF stained strongly positive in an average of 25% (range 12–34%) of the superficial epithelial cells of the mucosa, irrespective of PAS staining (Fig 3B). Not all the glandular tissue in any section was positively stained, showing that the expression of EGF in Barrett's epithelium is not uniform. The staining of the epithelial cells is cytoplasmic, involving the basolateral and, to a lesser extent, the apical surfaces of the cells and EGF can also be seen in the mucus derived from the glandular ducts in many cases (Fig 3C). Although EGF was expressed to a greater degree in intestinal and fundic/junctional Barrett's mucosa than in gastric mucosa ( $p < 0.01$ ), there was no difference between the metaplastic types of Barrett's mucosa or the degree of dysplasia ( $p = 0.5$ ) (Fig 6).

There was no difference between EGF expression in patients with uncomplicated reflux oesophagitis receiving treatment with ranitidine and those without therapy (median values 2 and 2, respectively) ( $p = 0.8$ ).

#### Discussion

There have been no previous reports of the occurrence or distribution of EGF in the healthy and inflamed squamous oesophagus, although we have described the occurrence of EGF in Barrett's mucosa.<sup>8</sup> We have shown that the EGF antibody used in this study binds reliably to EGF peptide as reported by other workers. This study has shown that EGF can be found in the endothelial cells immediately adjacent to basal cell layers of the normal oesophagus, including those forming papillae. This is in keeping with previous studies that have found EGF in the vascular endothelium immediately adjacent to basal cells in bile ducts,<sup>38</sup> glomeruli,<sup>39</sup> and human oral mucosa.<sup>40</sup> In normal oesophageal mucosa the distribution of EGF does not alter from proximal to distal oesophagus.

It is interesting to note that not all vascular endothelium stains with EGF. It seems that EGF is confined to the capillaries and is not found in the submucosal venules and arterioles.

This study has also shown there are significantly fewer EGF-positively staining endothelial cells in inflamed than in normal oesophageal mucosa, although the distribution of the EGF is similar in inflamed and normal mucosa. EGF is also found in the superficial epithelial cells in Barrett's oesophagus, a distribution which is quite different to that in the squamous mucosa.

The origin of the EGF found in the oesophageal endothelial cells has not been defined. It is possible that EGF is not produced in the oesophagus but is transported to the oesophageal mucosa by the blood stream, being released from the platelets and then transported into capillary endothelium.<sup>10,11</sup> It has been shown previously that EGF exerts greater trophic action when administered intravenously than via the luminal route.<sup>41</sup> Perhaps EGF is stored in the endothelial cells of the normal mucosa and when inflamma-



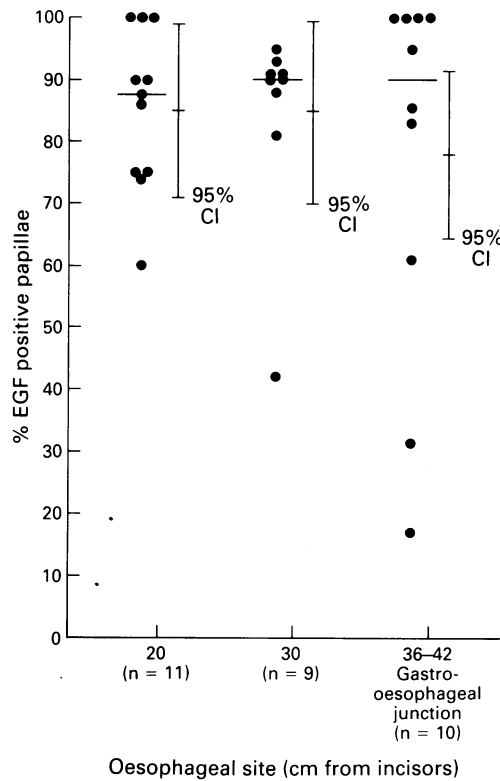


Figure 5: Distribution of epidermal growth factor (EGF) immunohistochemistry at three different oesophageal sites (EGF was not differentially expressed at different sites from the normal proximal to distal oesophagus.) Means and 95% confidence intervals (CI) given.

plasia. In this context, it has been reported that over-expression of EGF in gastric mucosa is, by itself, unlikely to cause transformation without the simultaneous overproduction of the EGF receptor.<sup>48-50</sup>

Some areas of intestinal type Barrett's mucosa contained predominantly acid mucin whereas all other forms of Barrett's mucosa contained neutral mucin (normal type of mucin in gastric mucosa). Wright *et al* have described EGF secreting lineages containing neutral mucin arising beside ulcerated intestinal mucosa.<sup>5</sup> We found no difference, however, between the expression of EGF in Barrett's mucosa contain-

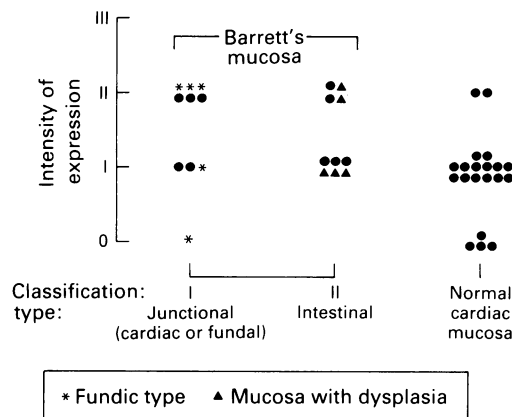


Figure 6: Expression of epidermal growth factor (EGF) in three different types of Barrett's epithelia. (EGF was not differentially expressed in the three types of Barrett's metaplasia.)

ing neutral mucin and that containing acid mucin (data not shown).

In conclusion, this study has shown EGF or EGF-like peptide in the capillaries of the oesophagus and in the glandular tissue of Barrett's mucosa, and confirms previous reports.<sup>8,40</sup> Decreased amounts of EGF are found in the mucosa of the inflamed oesophagus, indicating that EGF may also play a role in the development or healing of oesophagitis.

- Bradshaw RR, Cavanaugh KP. Isolation and characterisation of growth factors - epidermal growth factor. In: Sporn M, Roberts A, eds. *Peptide growth factors and their receptors I*. Berlin: Springer-Verlag, 1990: 210-450.
- Carpenter G, Wahl MI. The epidermal growth factor family. In: Sporn MB, Roberts AN, eds. *Peptide growth factors and their receptors II*. London: Springer-Verlag, 1990: 430-570.
- Cartilage SA, Elder JB. Transforming growth factor alpha and epidermal growth factor levels in normal human gastrointestinal mucosa. *Br J Cancer* 1989; **60**: 675-60.
- Konturek SJ, Bielanski W, Konturek SJ, Bogdal J, Olesksy J. Distribution and release of epidermal growth factor in man. *Gut* 1989; **30**: 1194-200.
- Wright NA, Pike C, Elia G. Induction of a novel epidermal growth factor-secreting cell lineage by mucosal ulceration in human gastrointestinal stem cells. *Nature* 1990; **343**: 82-5.
- Yoshida K, Kyo E, Tetsuhiro T, Sano T, Niimoto M, Tahara E. Expression of epidermal growth factor, transforming growth factor alpha and their receptor genes in human gastric carcinomas; implication for autocrine growth. *Jpn J Cancer Res* 1990; **81**: 43-51.
- Tahara E. Growth factors and oncogenes in human gastrointestinal carcinomas. *J Cancer Res Clin Oncol* 1990; **116**: 121-31.
- Jankowski J, McMenemin R, Hopwood D, Penston J, Wormsley KG. Abnormal expression of growth regulatory peptides in Barrett's mucosa. *Clin Sci* 1991; **81**: 663-8.
- Kelly SM, Hunter JO. Epidermal growth factor stimulates synthesis and secretion of mucus glycoproteins in human gastric mucosa. *Clin Sci* 1990; **79**: 425-7.
- Laurence DJR, Gusterson BA. The epidermal growth factor. *Tumor Biol* 1990; **11**: 229-61.
- Oka Y, Orth DN. Human plasma epidermal growth factor/beta urogastrone is associated with blood platelets. *J Clin Invest* 1983; **72**: 249-59.
- Carpenter G, Cohen S. Epidermal growth factor; a mini-review. *J Biol Chem* 1990; **265**: 7709-12.
- Mahida YR, Jones PDE, Daneshmend TK, Hawkey CJ. Peptide regulatory factors in the gut. In: Pounder RE, ed. *Recent advances in gastroenterology*. Edinburgh: Churchill Livingstone, 1990: 200-45.
- Wright NA, Poulosom R, Stamp GWH, Hall PA, Jaffrey RE, Longcroft JM, *et al*. Epidermal growth factor (EGF/URO) induces expression of regulatory peptides in damaged human gastrointestinal tissues. *J Pathol* 1990; **162**: 279-84.
- Tsujikawa T, Bamba T, Hosoda S. The trophic effect of epidermal growth factor on morphological changes and polyamine metabolism in the small intestine of rats. *Gastroenterol Jpn* 1990; **25**: 328-34.
- Reiss M, Sartorelli A. Regulation of growth and differentiation of human keratinocytes by type B transforming growth factor and epidermal growth factor. *Cancer Res* 1987; **47**: 6705-9.
- Chernoff EA, Robertson S. Epidermal growth factor and the onset of epithelial epidermal wound healing. *Tissue Cell* 1990; **22**: 123-35.
- Cutry AF, Kinniburgh AJ, Krabak MJ, Hui Sek-Wen, Wenner CE. Induction of c-fos and c-myc proto-oncogene expression by epidermal growth factor and transforming growth factor alpha is calcium independent. *J Biol Chem* 1989; **264**: 19700-5.
- Mukaida H, Yamamoto T, Hirai T, Toi M, Nakamura T, Yamashita Y, *et al*. Expression of human epidermal growth factor and its receptor in esophageal cancer. *Jpn J Surg* 1990; **29**: 275-82.
- Onda M, Tokunaga A, Nishi K, Yoshiyuki T, Shimizu Y, Kiyama T, *et al*. The correlation of epidermal growth factor with invasion and metastasis in human gastric cancer. *Jpn J Surg* 1990; **20**: 269-74.
- Nakagawa S, Yoshida S, Hirao Y, Kasuga S, Fuwa T. Biological effects of biosynthetic human EGF on the growth of mammalian cells in vitro. *Differentiation* 1985; **29**: 284-8.
- Majumdar AP, Arlow FL. Aging: altered responsiveness of gastric mucosa to epidermal growth factor. *Am J Physiol* 1989; **257**: 554-60.
- Kunizaki C, Sugiyama M, Tsuchiya S. Epidermal growth factor inhibits cysteamine-induced duodenal ulcers in rats. *Scand J Gastroenterol* 1989; **162** (suppl): 218-21.
- Konturek SJ, Dembinski A, Warzecha Z, Brzozowski T, Gregory H. Role of epidermal growth factor in healing of chronic gastroduodenal ulcers in rats. *Gastroenterology* 1988; **94**: 1300-7.
- Goodlad RA, Wright NA. Modulation of cell turnover and mucosal growth. In: Garner A, Whittle BJR, eds. *Advances in drug therapy of gastrointestinal ulceration*. London: John Wiley, 1989: 81-98.
- O'Keefe EJ, Chiu ML. Stimulation of thymidine incorpora-

- tion in keratinocytes by insulin, epidermal growth factor, and placental extract: comparison with cell number to assess growth. *J Invest Dermatol* 1988; **90**: 2-8.
- 27 Maccini DM, Veit BC. Salivary epidermal growth factor in patients with and without acid peptic disease. *Gastroenterology* 1990; **85**: 1102-4.
- 28 Kingsnorth AN, Smith P, Richards RC. Parotid salivary epidermal growth factor levels in human reflux oesophagitis and peptic ulcer disease. *Gastroenterology* 1989; **96**: A257.
- 29 Jankowski J, Austin W, Howat K, Coghill G, Murphy S, Hopwood D, *et al.* Proliferation in the oesophagus; an index of chronological age. *Eur J Gastroenterol Hepatol* 1991; **3**: 675-8.
- 30 Livstone E, Sheahan D, Behar J. Studies of esophageal cell proliferation in patients with reflux esophagitis. *Gastroenterology* 1977; **73**: 1315-9.
- 31 Starkey RH, Orth DN. Radioimmunoassay of human epidermal growth factor (urogastrone). *J Clin Endocrinol Metab* 1987; **45**: 1144-53.
- 32 Winkler ME, O'Connor L, Winget M, Fendley B. Epidermal growth factor and transforming growth factor alpha bind differently to the epidermal growth factor receptor. *Biochemistry* 1989; **28**: 6373-78.
- 33 Coghill G, Swanson-Beck J, Gibbs JH, Fawkes RS. The avidin-biotin technique in immunocytochemical staining. In: Grange JM, Fox A, Morgan NL, eds. *Immunological techniques in microbiology*. Edinburgh: Society for applied bacteriology, technical series. 1987; **24**: 87-110.
- 34 Filipe MI. The histochemistry of intestinal mucins. Changes in disease. In: Whitehead R, ed. *Gastrointestinal and oesophageal pathology*. Edinburgh: Churchill Livingstone, 1989: 65-91.
- 35 Jarvis LR, Dent J, Whitehead R. Morphometric assessment of reflux oesophagitis in fiberoptic biopsy specimens. *J Clin Pathol* 1985; **36**: 44-8.
- 36 Hamilton SR. Adenocarcinoma in Barrett's oesophagus. In: Whitehead R, ed. *Gastrointestinal and oesophageal pathology*. Edinburgh: Churchill Livingstone, 1989: 390-412.
- 37 Riddell RH, Golman H, Ransohoff DF, Appelman HD, Fenoglio CM, Haggitt RC, *et al.* Dysplasia in inflammatory bowel disease: standardized classification with provisional clinical applications. *Hum Pathol* 1983; **14**: 931-68.
- 38 Ishii M, Vroman B, LaRusso NF. Morphologic demonstration of receptor-mediated endocytosis of epidermal growth factor by isolated bile duct epithelial cells. *Gastroenterology* 1990; **98**: 1284-91.
- 39 Yoshioka K, Takemura T, Murakami K, Akano N, Matsubara K, Aya N, *et al.* Identification and localisation of epidermal growth factor and its receptor in the human glomerulus. *Lab Invest* 1990; **63**: 189-96.
- 40 Shirasuna K, Hayashido Y, Sugiyama M, Yoshioka H, Matsuya T. Immunohistochemical localisation of epidermal growth factor (EGF) and EGF receptor in human oral mucosa and its malignancy. *Virchows Arch [A]* 1991; **418**: 349-53.
- 41 Goodlad RA, Wilson TGJ, Lenton W, Gregory H, McCullagh KG, Wright NA. Proliferative effects of urogastrone-EGF on the intestinal epithelium. *Gut* 1987; **28** (suppl 1): 37-43.
- 42 Lee DC, Han VKM. Expression of growth factors and their receptors in development. In: Sporn MB, Roberts AB, eds. *Peptide growth factors and their receptors II*. London: Springer-Verlag, 1990: 330-60.
- 43 Ozawa S, Ueda M, Ando N, Osahiko A, Shimizu N. High incidence of EGF receptor hyperproduction in esophageal squamous-cell carcinomas. *Int J Cancer* 1987; **39**: 33-7.
- 44 Jankowski J, Murphy S, Coghill G, Grant A, Hopwood D, Wormsley KG. Expression of epidermal growth factor receptors in oesophageal mucosa. *Gut* 1992; **33**: 439-43.
- 45 Reid BJ, Haggitt RC, Rubin CE, Rabinovitch PS. Barrett's esophagus: correlation between flow cytometry and histology in detection of patients at risk for adenocarcinoma. *Gastroenterology* 1987; **93**: 1-11.
- 46 Konturek SJ, Dembinski A, Warzecha Z, Bielanski W, Brzozowski T, Drozdzowicz D. Epidermal growth factor (EGF) in the gastroprotective and ulcer healing actions of colloidal bismuth subcitrate (De-Nol) in rats. *Gut* 1986; **29**: 894-902.
- 47 Gysin B, Muller RK, Otten U, Fischli AE. Epidermal growth factor content of submandibular glands is increased in rats with experimentally induced gastric lesions. *Scand J Gastroenterol* 1988; **23**: 665-71.
- 48 Tahara E. Growth factors and oncogenes in human gastrointestinal carcinomas. *J Cancer Res Clin Oncol* 1990; **116**: 121-31.
- 49 Yoshida K, Kyo E, Tsujino T, Sano T, Niimoto M, Tahara E. Expression of epidermal growth factor, transforming growth factor alpha and their receptor genes in human gastric carcinomas; implication for autocrine growth. *Jpn J Cancer Res* 1990; **81**: 43-51.
- 50 Jankowski J, Hopwood D, Wormsley KG. Expression of EGF, TGF alpha and their receptors in the upper alimentary tract. *Dig Dis* (in press).