

## PAPERS

## Changes in the intragastric distribution of *Helicobacter pylori* during treatment with omeprazole

R P H Logan, M M Walker, J J Misiewicz, P A Gummett, Q N Karim, J H Baron

### Abstract

Omeprazole is a powerful inhibitor of gastric acid and may suppress *Helicobacter pylori* by effecting the pKa of *H pylori* urease, by altering the pattern of infection, or by promoting overgrowth of other bacteria. At routine endoscopy *H pylori* was detected by histology and culture before and after four weeks' treatment with omeprazole, 40 mg each morning. A <sup>13</sup>C-urea breath test was also done at t=0, 2, 4, and 6 weeks. Thirty nine patients with duodenal ulcer (n=25) or reflux oesophagitis (n=14) were studied, of whom 29 of 39 had *H pylori* infection. During omeprazole treatment, <sup>13</sup>C-urea breath test values fell significantly – mean (SEM) values before treatment and at four weeks were 23.0 (2.1) and 15.5 (2.7) per mil respectively, p<0.001. Before treatment *H pylori* was seen in 28 of 29 antral, 29 of 29 corpus, and 28 of 29 fundic biopsy specimens. After four weeks of omeprazole treatment, the histological density of *H pylori* in the antrum and corpus was reduced (p<0.001), while that in the fundus was increased. The migration of *H pylori* from the antrum to the fundus was associated with a corresponding decrease in the activity of antral gastritis. *H pylori* was not seen in antral biopsy specimens from 12 of 29 patients whose median excess  $\delta^{13}\text{CO}_2$  excretion fell from 23.0 to 9.9 per mil. In the body mucosa, 26 of 29 specimens were still positive for *H pylori* and there was no significant change in the gastritis type. Two weeks after finishing treatment, the mean (SEM) excess  $\delta^{13}\text{CO}_2$  excretion returned to levels before treatment. Omeprazole decreases antral *H pylori* colonisation but increases that in the fundus. The changes in the intragastric distribution of the organism are associated with concomitant changes in the activity of gastritis and are matched by a progressive fall in the excretion of  $\delta^{13}\text{CO}_2$ .

(Gut 1995; 36: 12-16)

Keywords: *Helicobacter pylori*, intragastric distribution, omeprazole, <sup>13</sup>C-urea breath test.

*Helicobacter pylori* causes non-autoimmune gastritis<sup>1</sup> and is an important factor in the aetiology of recurrent duodenal ulcer disease.<sup>2,3</sup> *H pylori* colonises only gastric type epithelium. Its powerful urease activity is probably essential for colonisation and the base produced by urease may protect the organism from gastric acid.<sup>4,5</sup> Omeprazole inhibits H<sup>+</sup>/K<sup>+</sup> ATPase, and 40 mg can suppress over 80% of gastric acid secretion.<sup>6</sup> Initial reports of the effect of omeprazole on *H pylori* were inconclusive.<sup>7,8</sup> Although eradication has been claimed in some reports,<sup>8-10</sup> *H pylori* status was assessed prematurely and on antral biopsy specimens alone. More recent reports using either the <sup>13</sup>C or <sup>14</sup>C-urea breath test suggest that omeprazole partly suppresses, but does not eradicate *H pylori*.<sup>11,12</sup> This prospective study examines the effect of omeprazole on the distribution and persistence of *H pylori* within the stomach using the <sup>13</sup>C-urea breath test and antral, corpus, and fundic histology.

### Methods

Patients attending for routine diagnostic gastroscopy and likely to need omeprazole were invited to take part in, and give written consent to this study, which was approved by the Parkside Ethical Committee. Patients with previous gastric surgery, known bleeding diathesis, taking oral anticoagulants, or who had been treated with bismuth compounds, omeprazole, or antibiotics known to be active against *H pylori* within the previous two months, were excluded. To determine *H pylori* status biopsy specimens were taken from the antrum (within 2 cm of the pylorus, two for histology and two for microbiology), corpus (half way along greater curvature, two for histology), and fundus (two for histology).

After each examination the endoscopes were disinfected by an automatic washing machine (Olympus EW20)<sup>13</sup> and the biopsy forceps were sterilised by autoclaving.

A <sup>13</sup>C-urea breath test<sup>14</sup> was performed within 24 hours of the initial endoscopy before starting treatment with omeprazole 40 mg each morning for four weeks in all patients in whom it was clinically indicated.

Parkside Helicobacter Study Group, Central Middlesex and St Mary's Hospitals, London

R P H Logan  
M M Walker  
J J Misiewicz  
P A Gummett  
Q N Karim  
J H Baron

Correspondence to:  
Dr R P H Logan, Division of Gastroenterology, Department of Therapeutics, University Hospital, Nottingham NG7 2UH.

Accepted for publication 29 April 1994

Grade of acute gastritis and grade of *Helicobacter pylori* colonisation in patients before and after treatment with omeprazole 40 mg in the morning

	Antrum				Body				Fundus			
	0	1	2	3	0	1	2	3	0	1	2	3
<i>Grade of acute gastritis</i>												
Before treatment (no)	6	4	14	4	11	2	14	1	11	8	2	1
After treatment (no)	14	3	10	1	7	3	18	0	7	6	9	3
(p)		<0.05								<0.05		
<i>Grade of H pylori colonisation</i>												
Before treatment (no)	1	6	11	11	0	12	11	5	1	19	1	0
After treatment (no)	12	9	5	1	5	11	8	4	3	15	4	5
(p)		<0.001										

## FOLLOW UP

The  $^{13}\text{C}$ -urea breath test was repeated in the *H pylori* positive patients after two weeks' treatment with omeprazole. A second endoscopy and a third breath test were completed after a further two weeks' therapy, and a fourth breath test was done two weeks after finishing omeprazole. If this breath test was negative, it was repeated two weeks later to document possible eradication at one month after finishing the drug.

Patients without *H pylori* were also studied to examine the possibility that overgrowth of other urease producing bacteria might yield a false positive breath test and to act as negative controls.

DETERMINATION OF *H PYLORI* STATUS

The presence of *H pylori* was determined by  $^{13}\text{C}$ -urea breath test, culture of two antral biopsy specimens on selective and unselective media in microaerobic conditions for up to 10 days, and by histological examination of two specimens from the gastric antrum, corpus, and fundus. Patients were classified as *H pylori* positive by a positive breath test (excess  $\delta^{13}\text{CO}_2 > 5$  per mil) together with either positive antral culture or positive histology from any site.

Clearance of *H pylori* was defined as a negative breath test (excess  $\delta^{13}\text{CO}_2 < 5$  per mil) at the end of treatment, and eradication as a negative breath test one month after the end of treatment.<sup>14</sup>

 $^{13}\text{C}$ -UREA BREATH TEST

Semiquantitative assessments of the severity of *H pylori* infection were made with the  $^{13}\text{C}$ -urea breath test (European standard protocol).<sup>14</sup> Briefly, a baseline sample of expired breath was obtained before drinking a fatty liquid test meal designed to delay gastric emptying. After 10 minutes,  $^{13}\text{C}$ -urea (100 mg (99% pure, Cambridge Isotopes, Boston, USA) in 50 ml of tap water) was swallowed and distributed within the stomach by turning the patient to the left and right decubitus position. Two litre serial breath samples were collected every five minutes into a large reservoir collecting bag, from which a single 20 ml sample (pooled sample) was taken at the end of the test and analysed by mass spectrometry (BSIA, Brentford, London). The results were expressed as excess  $\delta^{13}\text{CO}_2$  excretion per mil by subtracting the baseline from the pooled sample.

## HISTOLOGY

Biopsy specimens were processed routinely, embedded in paraffin wax, and stained (haematoxylin and eosin, and Gimenez method) for *H pylori*. In each patient the histologist examined two biopsy specimens at three levels (six sections) from the gastric antrum, body, and fundus and assessed the overall grade (0–3) according to the Sydney system of the activity (numbers of neutrophils) and chronicity (number of lymphocytes) of the gastritis.<sup>15</sup> For illustrative purposes the means of the overall grades for the three sites of all patients were then calculated. All histological assessments were made by the same experienced histopathologist (MMW), who was unaware of the other results, or of the patient's treatment. Ten biopsy specimens were selected at random for replicate histological examination, in order to assess observer variation.

## STATISTICAL ANALYSIS

The Wilcoxon rank sum test and Spearman's rank correlation coefficient were used for statistical analysis of the histological data; the paired Student's *t* test was used for  $^{13}\text{C}$ -urea breath test results.

## Results

Thirty nine patients (24 men, median age 48 years, range 16–72 years) with moderate to severe reflux oesophagitis ( $n=14$ ) or duodenal ulcer unhealed by  $\text{H}_2$  antagonists ( $n=25$ ) entered the study. In 29 of 39 patients *H pylori* was detected by a positive  $^{13}\text{C}$ -urea breath test (mean excess  $\delta^{13}\text{CO}_2$  excretion = 23.0 per mil), which was confirmed by either positive antral culture ( $n=26$ ), or positive antral biopsy, or both ( $n=28$ ). In all patients *H pylori* was also present in the corpus biopsy specimens and in 28 of 29 it was present in fundic specimens.

In 10 patients with reflux oesophagitis there was no evidence of *H pylori* infection on  $^{13}\text{C}$ -urea breath test (mean (SEM) excess  $\delta^{13}\text{CO}_2$  excretion = 1.9 (0.24) per mil), antral culture, or on antral, corpus, and fundic histology.

*H PYLORI* POSITIVE PATIENTS

## Histology

Before starting omeprazole *H pylori* was found in all the biopsy specimens, except those from two patients. One patient had no antral *H pylori* (but mild chronic antral gastritis and *H pylori* in the corpus and fundus). Another patient had no fundic *H pylori* (but mild chronic fundal gastritis and *H pylori* in the corpus and antrum). The mean density scores for *H pylori* in the antrum, body, and fundus were 2.1, 1.75, and 1.04 respectively. The presence of *H pylori* was often associated with active (presence of neutrophils) antral (26 of 29) or corpus gastritis (18 of 28). There were features of chronic inflammation in all the

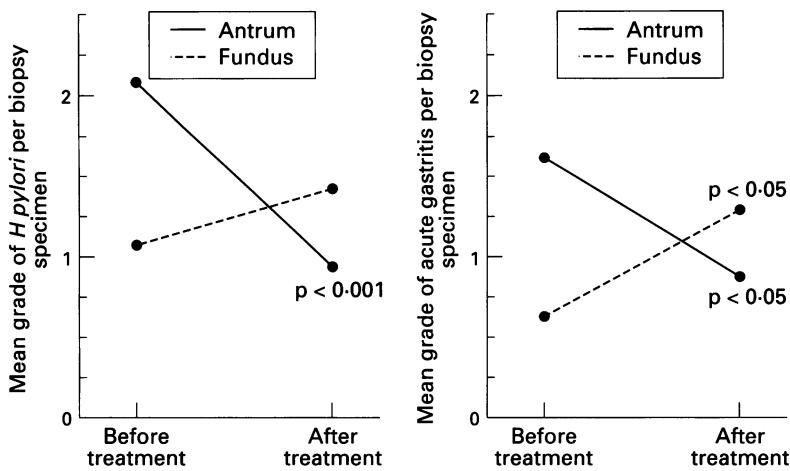


Figure 1: Changes in antral and fundal *Helicobacter pylori* colonisation and severity of acute antral and fundal gastritis before and after omeprazole, 40 mg mane for four weeks.

remaining, *H. pylori* positive antral, corpus, and fundal specimens.

After four weeks' treatment with omeprazole, *H. pylori* could no longer be detected in the antral specimen of 12 patients. Moreover, in three of these, *H. pylori* could no longer be detected in the corpus specimens, but all three still had organisms in the fundus. In the patients who were *H. pylori* positive before starting treatment, the mean density score of antral *H. pylori* was significantly lower after four weeks' omeprazole (0.90 *v* 2.1 before treatment,  $p < 0.001$ , Fig 1) with a similar, but not significant, trend in the corpus (1.75 *v* 1.3,  $p > 0.05$ ). In contrast, there was a small increase in the density of fundal *H. pylori* (from 1.0 to 1.4,  $p > 0.05$ ). These changes in the distribution of *H. pylori* were associated with a decreased mean grade of active antral gastritis (from 1.6 to 0.9,  $p < 0.05$ ) and an increased mean grade of active fundal gastritis (from 0.6 to 1.3,  $p < 0.05$ , Fig 1). The decreased density of antral and corpus *H. pylori* in biopsy specimens correlated with a decreased excess  $\delta^{13}\text{CO}_2$  excretion measured by the urea breath test (rank Spearman correlation,  $r = 0.45$ ,  $p < 0.05$ ). There was no change in the grade of chronic gastritis in the antrum, corpus, or fundus after omeprazole treatment. In one patient, unusual morphological forms of bacteria, not typical of *H. pylori*, were detected after four weeks' omeprazole treatment.

Replicate histological examination assessments of gastritis and *H. pylori* were the same ( $n = 5$ ), or varied by no more than one grade ( $n = 5$ ).

#### <sup>13</sup>C-urea breath test

The excess  $\delta^{13}\text{CO}_2$  excretion fell progressively in *H. pylori* positive patients ( $n = 29$ ) after treatment with omeprazole 40 mg daily. The mean (SEM) excess  $\delta^{13}\text{CO}_2$  excretion fell from 23.0 (2.1) per mil before starting omeprazole to 17.2 (2.1) after two weeks' treatment ( $p < 0.05$ , compared with before treatment), and to 15.5 (2.7) per mil after four weeks ( $p < 0.25$ , compared with two weeks) (Fig 2). The fall in  $\delta^{13}\text{CO}_2$  at four weeks was closely correlated with the decrease in the semiquantitative

histological assessments of *H. pylori* ( $r = 0.6$ ,  $p < 0.001$ ). In four patients the excess  $\delta^{13}\text{CO}_2$  excretion fell to  $< 5$  per mil after four weeks, but in all four the breath test was positive two weeks after finishing omeprazole. In the 12 patients with an antrum histologically cleared of *H. pylori*, the fall in excess  $\delta^{13}\text{CO}_2$  excretion was more pronounced than in the remainder: the (mean (SEM) excess  $\delta^{13}\text{CO}_2$  excretion fell from 23.0 (2.1) to 9.9 (4.2) per mil,  $p < 0.001$  from mean value before treatment), compared with 18.3 (3.3) per mil in those without antral clearance of *H. pylori*.

Two weeks after finishing treatment the excess  $\delta^{13}\text{CO}_2$  excretion returned to values before treatment (mean excess  $\delta^{13}\text{CO}_2$  excretion = 23.0 (3.8) per mil,  $p > 0.5$  *v* value before treatment, Fig 2).

#### *H. PYLORI* NEGATIVE PATIENTS

In the *H. pylori* negative patients there was no significant change in the excess  $\delta^{13}\text{CO}_2$  excretion after two weeks' treatment with omeprazole (mean excess  $\delta^{13}\text{CO}_2 = 2.4$  (0.37) per mil *v* 1.9 (0.24) per mil before treatment,  $p > 0.25$ ).

#### Discussion

Omeprazole, given in a dose of 40 mg daily for four weeks, significantly decreased histological evidence of *H. pylori* in the antral mucosa and the corpus, and significantly reduced the activity of antral gastritis. In the fundic mucosa, however, *H. pylori* increased as did the activity of fundic gastritis; but overall the <sup>13</sup>C-urea breath test results decreased progressively with treatment. The breath test became transiently negative in only four of 29 patients but *H. pylori* was not eradicated by omeprazole in any patient.

These results confirm previous reports

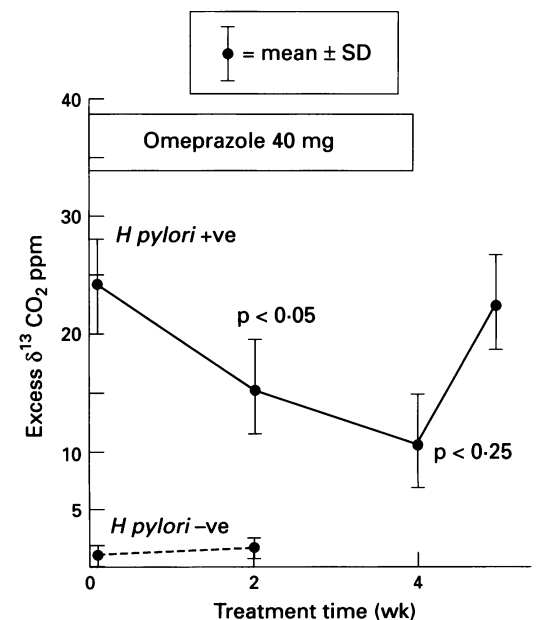


Figure 2: <sup>13</sup>C-urea breath test results (mean (SD)) in patients who were positive and negative for *Helicobacter pylori* before, during, and after two and four weeks' omeprazole 40 mg daily.

that omeprazole suppresses *H pylori* infection.<sup>11 12 17-19</sup> In a small study using the <sup>14</sup>C-urea breath test, Bell *et al*<sup>12</sup> cleared the organism in half the patients given omeprazole 40 mg for four weeks, while a dose of 20 mg cleared *H pylori* in only one quarter. No biopsy assessments of *H pylori* infection were made in this study. After four weeks' treatment with omeprazole 20 mg, Daw *et al*<sup>16</sup> reported 50% clearance from the antrum using culture as the criterion (the associated gastritis improved in 54% of patients), but over half the patients who had been negative on culture at the end of treatment had *H pylori* in the gastric pits visible on transmission electron microscopy. Similarly, 40% clearance of antral *H pylori* was reported after only two weeks of omeprazole 20 mg, but histology was used to assess the *H pylori* status.<sup>18</sup> Similar results were also reported in a large study dealing with duodenal ulcer patients after four weeks of either ranitidine 150 mg bd or omeprazole 10 or 20 mg daily: in patients receiving omeprazole 20 mg daily, antral *H pylori* was cleared in 68% of cases, with a concurrent improvement in the activity of the gastritis.<sup>19</sup> These changes were not dose related.

The highest (72%) clearance of antral *H pylori* was reported by Vigneri *et al* after four weeks' omeprazole 40 mg per day.<sup>20</sup> Thus, clearance of antral *H pylori* based on biopsy findings occurs in 40% to 80% of patients after either two or four weeks' treatment. This effect does not seem to be dose-related, although two retrospective studies have suggested that prolonged treatment might produce higher clearance rates.<sup>17</sup> Only our study and that of Vigneri *et al* have documented the increase and shift of *H pylori* to the fundic mucosa with increased colonisation of this area.

The pathogenic effects of *H pylori* may depend on the pattern of colonisation, but factors that determine the distribution of the organism within the stomach are unknown. *H pylori* is most often isolated from the gastric antrum, but loss of normal gastric type epithelium (for example, with gastric antral atrophy or intestinal metaplasia) or the loss of the adherent layer of mucus because of bile reflux is associated with lower levels of antral colonisation. Data from this study suggest that the distribution of *H pylori* can be changed by omeprazole, so far the only agent shown to influence the distribution of *H pylori* within the stomach.

One possible explanation for the suppression of *H pylori* by omeprazole is bacterial overgrowth. In this study neither mucosal biopsy specimens nor gastric juice were assessed microbiologically for bacterial overgrowth because of the inherent problems of accurately reproducing the in vivo microenvironment in vitro. Preliminary data suggest, however, that bacterial overgrowth does not correlate with the suppression of *H pylori*.<sup>21</sup> A possible explanation for this observation is that *H pylori* and other bacteria do not share the same habitat: *H pylori* is generally found beneath the mucus layer or in the gastric pits, while other bacteria colonise the gastric lumen and surface

mucus. In addition, loss of antral *H pylori* in patients with atrophic antral gastritis (but in whom *H pylori* persists in the corpus) is seldom associated with bacterial overgrowth (J Wyatt, personal communication).

Omeprazole and lansoprazole are potent inhibitors of *H pylori* in vitro, with minimum inhibitory concentrations that compare favourably with bismuth salts.<sup>22-24</sup> After the preliminary results of our study had been reported, Bugnoli *et al* discovered that omeprazole was a powerful inhibitor of *H pylori* urease. Although these data may seem to explain our findings, mutant urease negative *H pylori* and *H mustelae* were also inhibited by omeprazole. In addition inhibition of urease is an ineffective treatment for *H mustelae*,<sup>25</sup> which suggests that omeprazole's urease inhibition alone does not account for our findings.

Although omeprazole heals duodenal ulcers more rapidly than H<sub>2</sub> antagonists do,<sup>19</sup> the incidence of recurrence in the absence of maintenance treatment is similar.<sup>26</sup> Duodenal ulcer healing rates are related to the extent of acid suppression.<sup>27</sup> It has also been shown that duodenal ulcer healing rates may increase when H<sub>2</sub> antagonists are combined with anti-*H pylori* treatment.<sup>28</sup> It is possible, therefore, that more rapid duodenal ulcer healing with omeprazole may depend on suppression of *H pylori* as well as greater inhibition of gastric acid. Because omeprazole does not eradicate *H pylori*, the incidence of duodenal ulcer recurrence after initial healing with omeprazole is similar to those recorded with other antisecretory agents.<sup>26</sup>

We have shown that during treatment with omeprazole, *H pylori* may be suppressed sometimes simulating clearance of the antrum and corpus, or both, but with relapse of *H pylori* after the end of treatment. This effect of omeprazole considerably impairs the sensitivity of antral biopsy tissue for detecting *H pylori* in patients who are taking this drug. The practical consequences of this observation are that if breath tests are not available biopsies should also be taken from the corpus and fundus in order to determine if *H pylori* is still present in the stomach. In addition for patients unable to temporarily stop treatment with omeprazole, a negative breath test result should be interpreted with caution.

How omeprazole suppresses *H pylori* is not clear. We hypothesise that our findings may be due to *H pylori*'s chemotaxis for H<sup>+</sup>, however, further studies of the relationship between H<sup>+</sup>, *H pylori*, and the role of urease are needed.

The authors thank the endoscopy staff at the Central Middlesex and St Mary's Hospitals for help with this study. Dr R Logan was supported by a grant from Glaxo Group Research.

An abstract of this study was presented at the European Digestive Diseases Week in Amsterdam in September 1991.

- 1 Rauws EA, Langenberg W, Houthoff HJ, Zanen HC, Tytgat GNJ. Campylobacter pyloridis-associated chronic active antral gastritis. A prospective study of its prevalence and the effects of antibacterial and antiulcer treatment. *Gastroenterology* 1988; **94**: 33-40.
- 2 Rauws EAJ, Tytgat GNJ. Cure of duodenal ulcer with eradication of *Helicobacter pylori*. *Lancet* 1990; **335**: 1233-5.
- 3 Axon AR. Duodenal ulcer: the villain unmasked? *BMJ* 1991; **302**: 919-21.

- 4 Eaton KA, Brooks CL, Morgan DR, Krakowka S. Essential role of urease in pathogenesis of gastritis induced by *Helicobacter pylori* in gnotobiotic piglets. *Infect Immun* 1991; **59**: 2470-5.
- 5 Mobley HLT, Hausinger RP. Microbial ureases: significance, regulation and molecular characterisation. *Microbiol Rev* 1989; **53**: 85-108.
- 6 Maton PN. Omeprazole. *N Engl J Med* 1991; **324**: 965-75.
- 7 Mainguet P, Delmee M, Debongnie J-C. Omeprazole, *Campylobacter pylori* and duodenal ulcer. *Lancet* 1989; **ii**: 389-90.
- 8 Ghelani AM, Hale S, Coleman H, Radziwonik H, Robertson C, Atkinson M. Lack of in vitro activity of omeprazole against *Campylobacter pylori*. *J Clin Pathol* 1990; **43**: 171-2.
- 9 Biasco G, Miglioli M, Barbara L, Corinaldesi R, Di Febo G. Omeprazole, *Helicobacter pylori*, gastritis and duodenal ulcer. *Lancet* 1989; **ii**: 1403.
- 10 Tessaro P, Di Mario M, Rugge M, Baffa R, Pasqualetti P, Vio A, *et al.* Efficacy of omeprazole in eradicating *Helicobacter pylori* from the gastric mucosa. *Eur J Gastroenterol Hepatol* 1990; **2** (1): S117-8.
- 11 Sharp J, Logan RPH, Walker MM, Gummett PA, Misiewicz JJ, Baron JH. Effect of omeprazole on *Helicobacter pylori*. *Gut* 1991; **32**: A565.
- 12 Weil J, Bell DG, Powell K, Morden A, Harrison G, Gants PW, *et al.* Omeprazole and *Helicobacter pylori*: temporary suppression rather than true eradication. *Alimentary Pharmacology and Therapy* 1991; **5**: 309-13.
- 13 Weller IVD, Williams CB, Jeffries DJ, Leicester RJ, Gazzard BG, Axon ATR, *et al.* Cleaning and disinfection of equipment for gastrointestinal flexible endoscopy: interim recommendations of a Working Party of the British Society of Gastroenterology. *Gut* 1988; **29**: 1134-51.
- 14 Logan RPH, Dill S, Bauer FE, Walker MM, Hirschl AM, Gummett PA, *et al.* The European <sup>13</sup>C-urea breath test for the detection of *Helicobacter pylori*. *European Journal of Gastroenterology and Hepatology* 1991; **3**: 915-21.
- 15 Misiewicz JJ. The Sydney system: a new classification of gastritis. *J Gastroenterol Hepatol* 1991; **6**: 207-52.
- 16 Daw MA, Deegan P, O'Morain C. The effect of omeprazole on *Helicobacter pylori* and associated gastritis. *Alimentary Pharmacology and Therapy* 1991; **5**: 435-39.
- 17 Stolte M, Bethke B. Elimination of *Helicobacter pylori* under treatment with omeprazole. *Z Gastroenterol (Verh)* 1990; **28**: 271-4.
- 18 Arachimandritis C, Tjivras M, Davaris P, Fertakis A. Effect of omeprazole of *H pylori* after 2 weeks of treatment. *Italian Journal of Gastroenterology* 1991; **23**: 357-8.
- 19 Hui WM, Lam SK, Ho J, Lai CL, Lok ASF, Ng MMT, *et al.* Effect of omeprazole on duodenal ulcer-associated antral gastritis and *Helicobacter pylori*. *Dig Dis Sci* 1991; **36**: 577-82.
- 20 Vigneri S, Termini R, Scialabba A, Pisciotta G, Di Mario F. Omeprazole therapy modifies the gastric localisation of *Helicobacter pylori*. *Am J Gastroenterol* 1991; **86**: 1276.
- 21 Fraser R, Thorens J, Froelich F, Gonvers JJ, Bille J, Blum A, *et al.* Relationship between *Helicobacter pylori* infection and gastric and duodenal bacterial overgrowth. *Gastroenterology* 1993; **104**: A81.
- 22 Iwahi T, Satoh H, Nakao M, Iwasaki T, Yamazaki T, Kubo K, *et al.* Lansoprazole, a novel benzimidazole proton pump inhibitor, and its related compounds have selective activity against *Helicobacter pylori*. *Antimicrobial Agents and Chemotherapy* 1991; **35**: 490-6.
- 23 Bugnoli M, Bayeli PF, Rappuoli R, Pennatini C, Figura N, Crabtree JE. Inhibition of *Helicobacter pylori* urease by omeprazole. *European Journal of Gastroenterology Hepatology* 1993; **5**: 683-5.
- 24 Nagata K, Satoh H, Iwahi T, Shimoyama T, Tamura T. Potent inhibitory action of the gastric proton pump inhibitor lansoprazole against urease activity of *Helicobacter pylori*: unique action selective for *H pylori* cells. *Antimicrobial Agents and Chemotherapy* 1993; **37**: 769-74.
- 25 McColm AA, Bagshaw JA, O'Malley CFO. Development of a <sup>14</sup>C-urea breath test in ferrets colonised with *Helicobacter mustelae*: effects of treatment with bismuth, antibiotics and urease inhibitors. *Gut* 1993; **34**: 181-6.
- 26 Schiller KFR, Axon ATR, Carr-Locke DL, Cockell R, Donovan IA, Edmonstone WM, *et al.* Duodenal ulcer recurrence after healing with omeprazole or cimetidine treatment: a multicentre study in the UK. *Gut* 1989; **30**: A1490.
- 27 Hunt RH, Howden CW, Jones DB, Burget DW, Kerr GD. The correlation between acid suppression and peptic ulcer healing. *Scan J Gastroenterol* 1986; **21** (suppl 125): 22-9.
- 28 Graham DY, Ginger M, Lew PA-C, Evans DG, Evans DJ, Klein PD, *et al.* Effect of triple therapy (antibiotics plus bismuth) on duodenal ulcer healing. *Ann Intern Med* 1991; **115**: 266-9.