

Chronology of p53 protein accumulation in gastric carcinogenesis

M E Craanen, P Blok, W Dekker, G J A Offerhaus, G N J Tytgat

Abstract

p53 Protein accumulation in early gastric carcinoma was studied in relation to the histological type (Lauren classification) and the type of growth pattern, including the chronology of p53 protein accumulation during carcinogenesis. Forty five, paraffin embedded gastrectomy specimens from early carcinomas were examined for the presence of chronic atrophic gastritis, subtypes of intestinal metaplasia, and dysplasia. The Lauren type and the type of growth pattern were reassessed for all early carcinomas. p53 Protein accumulation was examined using the monoclonal antibody DO-7. Complete absence of p53 protein accumulation was observed in normal gastric mucosa, chronic atrophic gastritis, and intestinal metaplasia, irrespective of subtype. In gastric dysplasia (one mild, two moderate, and one severe), only severe dysplasia was p53 positive. Intestinal type (n=20) and diffuse type early gastric carcinomas (n=25) were p53 positive in 70% and 52% of cases, respectively. Both tumour types differed significantly in the percentage of p53 positive tumour cells per tumour ($p < 0.01$) and in staining intensity ($p < 0.05$). No significant difference in p53 protein accumulation was found between early carcinomas with different types of growth pattern. It is concluded that p53 protein accumulation – usually reflecting missense p53 gene mutation – seems to be a late event in gastric carcinogenesis. Moreover, it is suggested that missense p53 gene mutation occurs in a final pathway common to both intestinal and diffuse type of early gastric carcinoma. Finally, the types of growth pattern do not seem to differ in p53 protein accumulation.

(Gut 1995; 36: 848-852)

Keywords: p53 protein accumulation, early gastric cancer, Lauren classification, growth pattern.

According to Lauren, gastric carcinoma can be divided into two main histological types – intestinal and diffuse type carcinoma.¹ These two types not only differ morphologically, they have different clinical and epidemiological characteristics too.^{2,3} Moreover, the pathogenesis of both types is considered to be different. Intestinal type gastric carcinoma is thought to be the end result of a multistep process leading from normal gastric mucosa via chronic active gastritis to chronic gastritis with

variable degrees of atrophy, intestinal metaplasia, dysplasia, and ultimately to carcinoma. The diffuse type is thought to arise from the normal gastric mucosa, with no precursor lesion identified yet.^{4,5} Recent studies on the association of *Helicobacter pylori* and gastric carcinoma suggest, however, that *H pylori* induced gastritis may be a predisposing factor for both intestinal and diffuse types of gastric cancer.⁶⁻⁹

In colonic carcinogenesis, an accumulation of genetic changes have been described, with the progression from normal colonic mucosa via various (polypoid) precursor lesions to carcinoma.¹⁰ In contrast, the genetic changes at the various stages of gastric carcinogenesis remain to be explained. Research on the genetic basis of (gastrointestinal) malignancies has focused attention on the role of, among others, the p53 tumour suppressor gene in tumour development. To date there are very few reports on p53 protein accumulation – usually reflecting missense p53 gene mutation – in premalignant gastric lesions. Moreover, whereas several studies have reported mutations of the p53 gene in human gastric carcinoma and its lymph node metastases,¹¹⁻¹³ early gastric carcinomas were not included. Finally, although the prognosis of surgically treated early gastric cancer is generally excellent,¹⁴ its metastatic potential and postoperative five year survival rate appear to be correlated with the type of growth pattern.¹⁵ Interestingly, nuclear p53 protein accumulation in gastric carcinoma has also been shown to correlate with a higher propensity for lymph node metastasis and to correlate with an unfavourable clinical outcome independent of tumour stage as measured by early relapse and death.¹⁶⁻¹⁸

In view of the above, we not only examined the chronology of p53 protein accumulation in gastric carcinogenesis, but also investigated p53 protein accumulation in relation to Lauren type and growth pattern of the early cancers.

Methods

TISSUES

Forty five gastrectomy specimens from patients with early gastric cancer were retrieved from the files. The tissues had been fixed in 10% formalin and processed to paraffin wax by routine methods. Chronic atrophic gastritis was diagnosed using the criteria of the Sydney classification.^{19,20} Whenever intestinal metaplasia was present in the mucosa, 5 μ m sections were cut and stained with Alcian blue pH 2.5/periodic acid Schiff (AB pH 2.5/PAS) and high-iron-diamine/Alcian blue for subtyping of intestinal

Departments of
Gastroenterology and
Pathology, Academic
Medical Center,
Amsterdam, The
Netherlands
M E Craanen
G J A Offerhaus
G N J Tytgat

Department of
Medical Oncology, The
Netherlands Cancer
Institute, Amsterdam,
The Netherlands
M E Craanen

Department of
Pathology, Westeinde
Ziekenhuis, The
Hague, The
Netherlands
P Blok

Department of
Internal Medicine,
Kennemer Gasthuis
locatie EG, Haarlem,
The Netherlands
W Dekker

Correspondence to:
Dr M E Craanen,
Department of Medical
Oncology, The Netherlands
Cancer Institute,
Plesmanlaan 121, 1066CX
Amsterdam, The
Netherlands.

Accepted for publication
26 September 1994

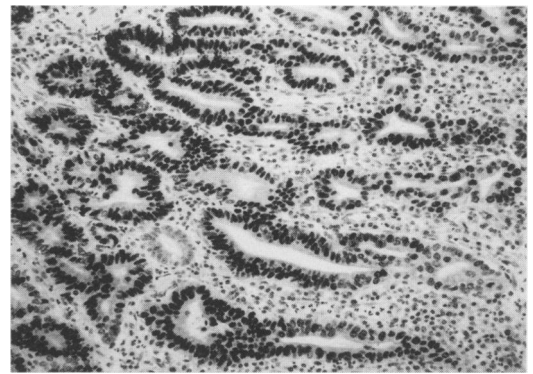
metaplasia according to Filipe.²¹ Dysplasia was scored according to the criteria of the World Health Organization.²² Early gastric cancer was defined according to the Japanese Society of Gastrointestinal Endoscopy.²³ The tumour histology according to Lauren, and the type of growth pattern according to Kodama *et al.*¹⁵ were reassessed using the original paraffin embedded, haematoxylin and eosin stained sections. In rare cases of disagreement, consensus was reached after discussion.

IMMUNOHISTOCHEMISTRY

To assess p53 protein accumulation, the commercially available monoclonal antibody DO-7 (DAKO, Glostrup, Denmark) was used in combination with the avidin-biotin-peroxidase method, as described by Hsu *et al.*²⁴ DO-7, which can be used on (archival) paraffin embedded material, is a mouse monoclonal antibody raised against recombinant human wild type p53 protein expressed in *Escherichia coli* and recognises both wild type and mutant type p53 protein. The exact binding site of DO-7 is unknown, but is probably between amino acids 35–45 in the N-terminus of the p53 protein (DAKO data sheet).

Briefly, 4 μ sections were cut and dewaxed in xylene. After rehydration through alcohol, the sections were immersed in 0.3% hydrogen peroxidase in methanol for 30 minutes to block endogenous peroxidase activity. After washing with phosphate buffered saline (PBS), sections were treated with 10% normal goat serum to reduce non-specific antibody binding. All steps were carried out at room temperature. To improve p53 immunoreactivity, sections were treated with an antigen retrieval solution (10 mM citric acid monohydrate pH 6.0), heated in a microwave. After washing with PBS, DO-7 was applied for one hour. After further washing with PBS, sections were incubated with a biotinylated rabbit anti-mouse second-stage antibody (DAKO). After further washing with PBS, peroxidase-conjugated streptavidin was applied. Peroxidase activity was demonstrated by adding diaminobenzidine as a chromogen. The sections were counterstained with haematoxylin. Negative control sections were processed without the primary antibody. Positive control sections were processed from a breast adenocarcinoma, previously shown to express high levels of p53 protein.

The proportion of tumour cells with nuclear p53 protein accumulation was arbitrarily divided into five groups: 0%, <10%, 10–30%, 30–60%, and \geq 60% of the total tumour cell population per section. Four sections from each tumour were scored. A tumour was scored as p53 positive when at least 10% of the tumour cells showed nuclear p53 protein accumulation. In p53 positive tumours, the intensity of nuclear p53 immunostaining was graded as (1) weak but definitely visible and (2) strong and clearly visible. Ultimately, for each p53 positive early gastric cancer, a product score of % p53 positive cells \times staining intensity was calculated as follows:



High grade dysplasia with most cells showing strong nuclear p53 immunostaining (original magnification \times 10).

10–30%=1, 30–60%=2, \geq 60%=3, weak=1 and strong=2.

In cases of normal gastric mucosa, chronic active gastritis, intestinal metaplasia subtypes, and dysplasia, the same scoring criteria which was used in cases of early gastric cancer, were applied. Scoring was performed independently by two of the authors (MC/PB). In rare cases of disagreement, consensus was reached after discussion.

STATISTICS

The χ^2 test was used for statistical analysis, unless stated otherwise. A p value <0.05 was considered significant.

Results

HISTOLOGY

Normal gastric mucosa was observed in all gastrectomy specimens. Chronic active gastritis was present in 35 gastrectomy specimens. Since intestinal metaplasia was present multifocally, totals of 271 foci of type I intestinal metaplasia, 189 foci of type II intestinal metaplasia, and 53 foci of type III intestinal metaplasia were identified. Four areas of gastric dysplasia were found in the mucosa adjacent to the tumours and were graded as; mild (n=1), moderate (n=2), and severe (n=1). There were 20 intestinal type early gastric cancers and 25 diffuse type early gastric cancers.

GROWTH PATTERN

Twenty seven early cancers (60%) were confined to the mucosa and 18 (40%) extended into the submucosa. According to growth pattern, there were 24 small mucosal type early gastric cancers (all limited to the mucosa), five superficial spreading type early gastric cancers (three mucosal, two submucosal), and 16 penetrating (Pen) type early gastric cancer (four Pen A type, 12 Pen B type).

p53 IMMUNOREACTIVITY

Without using the described antigen unmasking method, none of the sections, irrespective of the histological diagnosis, stained positively with DO-7 (data not shown). After pretreatment, the following results were obtained.

TABLE I Prevalence of nuclear p53 protein accumulation in early gastric carcinomas (EGC) and precancerous lesions

	p53 Positive (%)	p53 Negative (%)
Intestinal type EGC (n=20)	70*	30
Diffuse type EGC (n=25)	52*	48
Dysplasia:		
Mild (n=1)	0	100
Moderate (n=2)	0	100
Severe (n=1)	100	0
Intestinal metaplasia foci:		
Type I (n=271)	0	100
Type II (n=189)	0	100
Type III (n=53)	0	100
Chronic active gastritis (n=35)	0	100
Normal mucosa (n=45)	0	100

*Not significant.

Note: a lesion was scored as p53 positive in case at least 10% of the cells showed nuclear p53 protein accumulation.

Complete absence of nuclear p53 protein accumulation (0% of p53 positive cells) was observed in normal gastric mucosa, chronic active gastritis, and all foci of intestinal metaplasia, irrespective of subtype. In cases of dysplasia, nuclear p53 protein accumulation was only found in the one area of severe dysplasia (Figure). Nuclear p53 protein accumulation was shown in 60% of early gastric cancers. When divided into histological type, 14 of 20 (70%) intestinal type and 13 of 25 (52%) diffuse type early gastric cancers were p53 positive (Table I).

The staining characteristics of both tumour types were significantly different (Table IIA and B). In 11 of 14 p53 positive intestinal type tumours and in three of 13 p53 positive diffuse type tumours ($p < 0.01$), most of the tumour cells ($\geq 60\%$) showed nuclear p53 protein accumulation. Moreover, (the same) 11 p53 positive intestinal type early gastric cancers showed strong immunostaining, whereas only four of the p53 positive diffuse type early gastric cancer (all with $\geq 30\%$ p53 positive cells) showed a similar staining intensity ($p < 0.05$). The median product score (% p53 positive cells \times staining intensity) was 6 for intestinal type and 1 for diffuse type early gastric cancer (Wilcoxon rank test: $p < 0.005$). The tumour adjacent to the severe (p53 positive) dysplastic area, was a p53 positive intestinal type early gastric cancer (product score=6). The tumours adjacent to the

mild/moderate (p53 negative) dysplastic areas were all p53 positive (two diffuse type with product scores of 2 and 1, respectively; one intestinal type with a product score of 6).

Finally, no significant difference in p53 protein accumulation was found between the various types of growth pattern (Table III).

Discussion

Despite mounting evidence that immunohistochemical detection of p53 protein accumulation is not always synonymous with the presence of missense p53 gene mutation,²⁵⁻²⁹ p53 protein accumulation has been shown to be strongly associated with missense mutations in a highly conserved region (exons 5-8) of the p53 gene.³⁰⁻³² Whereas wild type p53 protein has a very short half life, the mutant proteins have an extended half life and as a result can be readily detected by immunohistochemical analysis. To date, only three immunohistochemical studies have been published on premalignant gastric lesions and p53 protein accumulation.³³⁻³⁵ Chronic active gastritis and intestinal metaplasia were uniformly reported to be negative for p53 protein accumulation, although the exact number of scored intestinal metaplasia foci was not stated. Moreover, no division into the various intestinal metaplasia subtypes was made. Presumably, only subtype III, and not subtypes I and II, should be considered as a marker of premalignant change in the stomach.³⁶⁻³⁸ Our results clearly show that p53 protein accumulation does not occur in chronic active gastritis and the various intestinal metaplasia subtypes. This finding does not necessarily deny the premalignant potential of chronic active gastritis and intestinal metaplasia (type III in particular), but rather suggests that p53 protein accumulation occurs beyond the stage of chronic active gastritis and intestinal metaplasia formation. In our study, p53 protein accumulation was found only in severe gastric dysplasia. Although the very small number of areas of gastric dysplasia precludes firm conclusions, our data seem to be in line with the results of the former three studies.³³⁻³⁵ They not only reported p53 protein accumulation in gastric dysplasia, but also that the frequency of p53 positivity increased with the severity of dysplasia. Similar findings have been reported in dysplastic Barrett's epithelium.³⁹

Comparison of different immunohistochemical studies is fraught with pitfalls and difficulties. Differences in tissue fixation, antibodies used or different scoring criteria, or

TABLE II Characteristics of p53 immunoreactivity in early gastric carcinomas (EGC) and precancerous lesions

	A: Cells with nuclear p53 protein accumulation (%)				
	0	<10	10-30	30-60	≥ 60
Intestinal type EGC (n=20)	4	2	3	0	11
Diffuse type EGC (n=25)	5	7	9	1	3
Dysplasia (n=4)	3			1	
Intestinal metaplasia foci:					
Type I (n=271)	271				
Type II (n=189)	189				
Type III (n=53)	53				
Chronic active gastritis (n=35)	35				
Normal mucosa (n=45)	45				
	B: Intensity of nuclear p53 immunoreactivity in p53+ve lesions				
	Weak	Strong			
Intestinal type EGC (n=14)	3	11			
Diffuse type EGC (n=13)	9	4			
Dysplasia (n=1)	0	1			

TABLE III Prevalence of p53 protein accumulation in early gastric carcinomas according to type of growth pattern

Growth pattern	No	p53 Positive (%)
Small mucosal:		
Mucosa limited	24	50
Submucosa involved	0	
Superficial spreading:		
Mucosa limited	3	33.3
Submucosa involved	2	100
Penetrating type:		
Type A	4	50
Type B	12	83.3

both, for example, may lead to biased conclusions. We used monoclonal antibody DO-7, whereas other investigators used either polyclonal antibody CM-1^{33 34} or monoclonal antibody Pab 1801.³⁵ All three antibodies recognise both wild type and mutant type p53 protein, despite differences in the epitopes recognised.⁴⁰⁻⁴² DO-7, however, has been reported to be superior to both CM-1 or Pab 1801 on formalin fixed, paraffin embedded tissues in detecting missense p53 gene mutations, especially when combined with target unmasking fluid.⁴³ Our data therefore suggest that missense p53 gene mutation is a late event in gastric carcinogenesis. In contrast, the only study to date which has used p53 gene mutational analysis (single strand conformation polymorphism with direct DNA sequencing) as an adjunct to immunohistochemistry has suggested that p53 gene mutation is an early pathogenic event in gastric carcinogenesis. Missense mutations, however, were found only from dysplasia onwards. Moreover, the mutations found in three of eight cases of intestinal metaplasia did not change the amino acid sequence of the p53 protein, thereby leaving the p53 protein in its wild type form. Finally, it was not stated whether or not the intron 5 mutation in intestinal metaplasia affected the splice site acceptor region. Its conclusion, therefore, that p53 gene mutation is an early instead of a late pathogenic event in gastric carcinogenesis seems unlikely.⁴⁴ Apparently, p53 is not involved in the (early) progression from metaplastic to dysplastic epithelium, but is involved in the malignant transformation from dysplasia onwards.

According to our criteria, 60% of early gastric cancers were p53 positive, and similar percentages have been reported in both early and advanced carcinomas.^{16 33} No significant difference was found in the proportion of p53 positive tumours between intestinal and diffuse type early gastric cancers. This finding does not necessarily preclude the possibility of a different pathogenesis of both tumour types but could merely reflect the occurrence of missense p53 gene mutations during a final common pathway of genetic alterations.

Whether or not both tumour types differ in the occurrence of nonsense p53 gene mutations remains unanswered in our study. Immunohistochemistry can not generally detect these mutations since they lead to stop codon formation and premature termination of translation. Interestingly, significant differences in immunostaining characteristics were observed between both types of early gastric cancer, best exemplified by the median product score of the % p53 positive cells \times staining intensity. Of course, it is tempting to speculate that intestinal and diffuse type early gastric cancers differ in their p53 mutational spectrum or in the expression of viral or cellular proteins that interact with p53. Furthermore, differences in the expression levels of the p53 gene in both tumour types, in cell cycle kinetics, and finally in the p53 protein degradation pathway might be considered. However, one should also cautiously include the possibility that microwave pretreatment has

influenced results, since this technique may lower the immunohistochemical detection threshold of the p53 protein⁴⁵ and may influence immunostaining results appreciably, as has been shown by Lambkin *et al.*⁴⁶ As a result, it cannot entirely be ruled out that in some cases, especially in those with weak nuclear staining intensity, stabilised inactivated wild type p53 protein is being detected instead of mutant forms. Ideally, therefore, one should combine microwave pretreatment with the use of an antibody that specifically recognises mutant forms, as has been reported for Pab 240,⁴⁷ but unfortunately this antibody can not be applied to formalin fixed, paraffin embedded tissues.^{42 43}

It has been reported that p53 protein accumulation in gastric carcinoma is correlated with a higher propensity for lymph node metastasis and with an unfavourable clinical outcome independent of tumour stage, as measured by early relapse and death.¹⁶⁻¹⁸ Moreover, recent findings on the role of p53 in the apoptotic response of cells to genotoxic stimuli such as radiation and anticancer agents⁴⁸⁻⁵⁰ lend further support to the concept that p53 positive tumours may constitute a distinct group of gastric carcinomas with a higher malignant potential than p53 negative gastric carcinomas. Since, in cases of early gastric cancer, the type of growth pattern may also strongly influence malignant potential and clinical outcome, we examined whether growth patterns and p53 protein accumulation are correlated. Whereas the pen A type, in contrast to the other growth types, has been reported to have a high propensity for blood vessel invasion and lymph node metastasis and to have the worst prognosis after surgery due to early postoperative hepatic metastasis,¹⁴ we found no significant difference in p53 protein accumulation between the various growth types.

In conclusion, p53 protein accumulation – usually reflecting missense p53 gene mutation – should be considered as a late event in gastric carcinogenesis. Moreover, we suggest that missense p53 gene mutation occurs in a final pathway of genetic alterations common to both intestinal and diffuse type early gastric cancer. Finally, it seems that mechanisms other than p53 protein accumulation underlie the reported differences in biological behaviour of early gastric carcinomas with different types of growth pattern.

- 1 Lauren P. The two histological main types of gastric carcinoma: diffuse and so-called intestinal-type carcinoma. *Acta Pathologica et Microbiologica Scandinavica* 1965; 64: 31-49.
- 2 Davessar K, Pezzulo JC, Kessimian N, Hale JH, Jauregui HO. Gastric adenocarcinoma: Prognostic significance of several pathologic parameters and histologic classification. *Hum Pathol* 1990; 21: 325-32.
- 3 Munoz N, Correa P, Cuello C, Duque E. Histologic types of gastric carcinoma in high- and low-risk areas. *Int J Cancer* 1968; 3: 809-18.
- 4 Correa P. Precursors of gastric and esophageal cancer. *Cancer* 1982; 50: 2554-65.
- 5 Correa P. A human model of gastric carcinogenesis. *Cancer Res* 1988; 48: 1319-26.
- 6 Sipponen P, Kosunen TU, Valle J, Riihela M, Seppala K. Helicobacter pylori infection and chronic gastritis in gastric cancer. *J Clin Pathol* 1992; 45: 319-23.
- 7 Craanen ME, Blok P, Dekker W, Tytgat GNJ. Helicobacter pylori and early gastric cancer. *Gut* 1994; 35: 1370-2.
- 8 Parsonnet J, Friedman GD, Vandersteen JP, Chang Y, Vogelstein JH, Orentreich N, Sibley RK. Helicobacter

- pylori infection and the risk of gastric carcinoma. *N Engl J Med* 1991; 325: 1127-31.
- 9 Nomura A, Stemmermann GN, Chyou P-H, Kato I, Perez-Perez GI, Blaser MJ. Helicobacter pylori infection and gastric carcinoma among Japanese Americans. *N Engl J Med* 1991; 325: 1132-6.
 - 10 Vogelstein B, Fearon ER, Hamilton SR, Kern SE, Preisinger AC, Leppert M, et al. Genetic alterations during colorectal tumor development. *N Engl J Med* 1989; 319: 525-32.
 - 11 Imazeki F, Omata M, Nose H, Ohto M, Isono K. p53 Gene mutations in gastric and esophageal cancers. *Gastroenterology* 1992; 103: 892-6.
 - 12 Tamura G, Kihana T, Nomura K, Terada M, Sugimura T, Hirohashi S. Detection of frequent p53 gene mutations in primary gastric cancer by cell sorting and polymerase chain reaction single-strand conformation polymorphism analysis. *Cancer Res* 1991; 51: 3056-8.
 - 13 Yamada Y, Yoshida T, Hayashi K, Sekiya T, Yokota J, Hirohashi S, et al. p53 Gene mutations in gastric cancer metastases and in gastric cancer cell lines derived from metastases. *Cancer Res* 1991; 51: 5800-5.
 - 14 Craanen ME, Dekker W, Ferwerda J, Blok P, Tytgat GNJ. Early gastric cancer: a clinicopathologic study. *J Clin Gastroenterol* 1991; 13: 274-83.
 - 15 Kodama Y, Inokuchi K, Soejima K, Matsusaka T, Okamura T. Growth patterns and prognosis in early gastric carcinoma. *Cancer* 1983; 51: 320-6.
 - 16 Martin HM, Filipe MI, Morris RW, Lane DL, Silvestre F. p53 Expression and prognosis in gastric carcinoma. *Int J Cancer* 1992; 50: 859-62.
 - 17 Kakeji Y, Korenaga D, Tsujitani S, Baba H, Anai H, Maehara Y, Sugimachi K. Gastric cancer with p53 overexpression has high potential for metastasising to lymph nodes. *Br J Cancer* 1993; 67: 589-93.
 - 18 Starzynska T, Bromley M, Ghosh A, Stern PL. Prognostic significance of p53 overexpression in gastric and colorectal carcinoma. *Br J Cancer* 1992; 66: 558-62.
 - 19 Misiewicz JJ. The Sydney system: A new classification of gastritis. Introduction. *J Gastroenterol Hepatol* 1991; 6: 207-8.
 - 20 Price AB. The Sydney system: Histological division. *J Gastroenterol Hepatol* 1991; 6: 209-22.
 - 21 Filipe MI. Histochemistry of intestinal mucins. In: Whitehead R, ed. *Gastrointestinal and oesophageal pathology*. 1st ed. Edinburgh/London/Melbourne/New York: Churchill Livingstone, 1989: 71.
 - 22 Watanabe H, Jass JR, Sobin LH, eds. *WHO international histological classification of tumours. The histological typing of oesophageal and gastric tumors*. Berlin/Heidelberg/New York/Paris/Tokyo: Springer Verlag, 1990
 - 23 Murakami T. Pathomorphological diagnosis. Definition and gross classification of early gastric cancer. In: Murakami T, ed. *Early gastric cancer*. Gann monograph on cancer research. Vol 11. Tokyo: University of Tokyo Press, 1971: 53-5.
 - 24 Hsu SM, Raine L, Fanger H. The use of the avidin-biotin-peroxidase complex (ABC) in immunoperoxidase techniques: a comparison between ABC and unlabeled antibody procedures. *J Histochem Cytochem* 1985; 19: 577-80.
 - 25 Wynford-Thomas D. p53 in tumour pathology: can we trust immunohistochemistry? *J Pathol* 1992; 166: 329-30.
 - 26 Hall PA, Lane DP. p53 In tumour pathology: can we trust immunohistochemistry? - revisited. *J Pathol* 1994; 172: 1-4.
 - 27 Battifora H. p53 Immunohistochemistry: A word of caution. *Hum Pathol* 1994; 25: 435-6.
 - 28 Unger C, Kress S, Buchmann A, Schwarz M. Irradiation-induced micronuclei from mouse hepatoma cells accumulate high levels of the tumor suppressor protein p53. *Cancer Res* 1994; 54: 3651-5.
 - 29 Chowdary DR, Dermody JJ, Jha KK, Ozer HL. Accumulation of p53 in a mutant cell line defective in the ubiquitin pathway. *Mol Cell Biol* 1994; 14: 1997-2003.
 - 30 Davidoff AM, Humphrey PA, Iglehart JD, Marks JR. Genetic basis for p53 overexpression in human breast cancer. *Proc Natl Acad Sci USA* 1991; 88: 5006-10.
 - 31 Marks JR, Davidoff AM, Kerns BJ, Humphrey PA, Pence JC, Dodge RK, et al. Overexpression and mutation of p53 in epithelial ovarian cancer. *Cancer Res* 1991; 51: 2979-84.
 - 32 Iggo R, Gatter K, Bartek J, Lane D, Harris AL. Increased expression of mutant forms of p53 oncogene in primary lung cancer. *Lancet* 1990; 335: 675-9.
 - 33 Rugge M, Shiao YH, Correa P, Baffa R, Dimario F. Immunohistochemical evidence of p53 overexpression in gastric epithelial dysplasia. *Cancer Epidemiology - Biomarkers and Prevention* 1992; 1: 551-4.
 - 34 Joypaul BV, Newman EL, Hopwood D, Grant A, Qureshi S, Lane DP, Cuschieri A. Expression of p53 protein in normal, dysplastic, and malignant gastric mucosa: an immunohistochemical study. *J Pathol* 1993; 170: 279-83.
 - 35 Lauwers GY, Wahl SJ, Melamed J, Rojascorona RR. p53 Expression in precancerous gastric lesions - an immunohistochemical study of Pab 1801 monoclonal antibody on adenomatous and hyperplastic gastric polyps. *Am J Gastroenterol* 1993; 88: 1916-9.
 - 36 Jass JR, Filipe MI. Sulphomucins and precancerous lesions of the human stomach. *Histopathology* 1980; 4: 271-9.
 - 37 Rokkas T, Filipe MI, Sladen GE. Detection of an increased incidence of early gastric cancer in patients with intestinal metaplasia type III who are closely followed up. *Gut* 1991; 32: 1110-3.
 - 38 Craanen ME, Blok P, Dekker W, Ferwerda J, Tytgat GNJ. Early gastric cancer and intestinal metaplasia. *Eur J Gastroenterol Hepatol* 1991; 3: 935-40.
 - 39 Younes M, Lebovitz RM, Lechago LV, Lechago J. p53 Protein accumulation in Barrett's metaplasia, dysplasia and carcinoma: A follow-up study. *Gastroenterology* 1993; 105: 1637-42.
 - 40 Banks L, Matlashewski G, Crawford L. Isolation of human p53 specific monoclonal antibodies and their use in the studies of human p53 expression. *Eur J Biochem* 1986; 159: 529-34.
 - 41 Midgley CA, Fisher CJ, Bártek J, Vojtesek B, Lane D, Barnes DM. Analysis of p53 expression in human tumours: an antibody raised against human p53 expressed in Escherichia coli. *J Cell Sci* 1992; 101: 183-9.
 - 42 Vojtesek B, Bártek J, Midgley CA, Lane DP. An immunohistochemical analysis of the human nuclear phosphoprotein p53. *J Immunol Methods* 1992; 151: 237-44.
 - 43 Bass IO, Mulder JWR, Offerhaus GJA, Vogelstein B, Hamilton SR. An evaluation of six antibodies for immunohistochemistry of mutant p53 gene product in archival colorectal neoplasms. *J Pathol* 1994; 172: 5-12.
 - 44 Shiao Y-H, Rugge M, Correa P, Lehmann HP, Scheer WD. p53 Alteration in gastric precancerous lesions. *Am J Pathol* 1994; 144: 511-7.
 - 45 McKee PH, Hobbs C, Hall PA. Antigen retrieval by microwave irradiation lowers immunohistological detection thresholds. *Histopathology* 1993; 23: 377-9.
 - 46 Lambkin HA, Mothersill CM, Kelehan P. Variations in immunohistochemical detection of p53 protein overexpression in cervical carcinomas with different antibodies and methods of detection. *J Pathol* 1994; 172: 13-8.
 - 47 Gannon JV, Greaves R, Iggo R, Lane DP. Activating mutations in p53 produce a common conformational effect. A monoclonal antibody specific for the mutant form. *EMBO J* 1990; 9: 1595-602.
 - 48 Lowe SW, Schmitt EM, Smith SW, Osborne BA, Jacks T. p53 Is required for radiation induced apoptosis in mouse thymocytes. *Nature* 1993; 362: 847-9.
 - 49 Clarke AR, Purdie CA, Harrison DJ, Morris RG, Bird CC, Hooper ML, Wyllie AH. Thymocyte apoptosis induced by p53 dependent and independent pathways. *Nature* 1993; 362: 849-52.
 - 50 Lowe SW, Ruley HE, Jacks T, Housman DE. p53-Dependent apoptosis modulates the cytotoxicity of anti-cancer agents. *Cell* 1993; 74: 957-67.