

# Biochemical and morphological changes that characterise recovery from necrotising biliary pancreatitis in the opossum

M Rünzi, A Saluja, A Kaiser, D Gerdes, A Sengupta, M L Steer

## Abstract

**The events that characterise recovery from severe biliary pancreatitis have not been defined. This study used a reversible model of necrotising pancreatitis, induced by obstructing the opossum common bile pancreatic duct (CBPD), to evaluate this phenomenon. The CBPD of opossums was obstructed with a balloon tipped catheter for five days and then decompressed by removal of the catheter. Recovery was evaluated 0-90 days after relief of obstruction. Serum bilirubin and amylase values rapidly declined, reaching control values 7-14 days after removal of the obstructing catheter. Pancreatic protein and amylase values were transiently increased shortly after relief of obstruction but returned to control values 21 days after decompression. Pancreatic ornithine decarboxylase activity and incorporation of [<sup>3</sup>H]-thymidine into DNA were transiently increased 14 days after duct decompression suggesting that regeneration occurs at approximately that time. Foci of pancreatic necrosis involved roughly 40% of the gland at the time of decompression but these foci gradually disappeared and the gland resembled that of control animals 60 days after decompression. Evidence of fibrosis or collagen deposition in the pancreas was not noted at any time. These studies show that recovery after necrotising biliary pancreatitis occurs comparatively rapidly and the restitution ad integrum occurs. Recovery from necrotising acute pancreatitis in this model is not associated with the development of chronic pancreatitis.**

(Gut 1995; 37: 427-433)

Keywords: biliary pancreatitis, opossum.

The events that characterise structural recovery of the pancreas after a severe attack of necrotising pancreatitis have not been clearly defined. Restitutio ad integrum is believed by many to occur in humans.<sup>1</sup> On the other hand, some recent reports have suggested that severe necrotising acute pancreatitis in humans may be followed by fibrosis and evolve into chronic pancreatitis.<sup>2-4</sup> This so called necrosis-fibrosis hypothesis, however, remains controversial. Detailed morphological studies characterising recovery from acute necrotising pancreatitis in

humans have not been possible because, for the most part, specimens of pancreatic tissue from patients recovering from pancreatitis have not been available. Animal studies have been of limited value as, for the most part, the methods of inducing pancreatitis result in only mild glandular injury (duct ligation or secretagogue hyperstimulation in rodents) or cause extensive yet poorly controlled degrees of destruction (retrograde duct injection).<sup>5</sup>

We have recently undertaken a series of studies characterising a model of biliary pancreatitis in the opossum. Obstruction of the common bile pancreatic duct (CBPD) in that animal with a balloon catheter results in acute necrotising pancreatitis, which has a severity that is dependent upon the duration of duct obstruction. With obstruction for five days, roughly 40% of acinar cells become necrotic. Relief of obstruction, by removal of the balloon catheter, prevents further progression of the pancreatitis and, as noted previously, the animals can recover.<sup>8</sup> We reasoned that this model might permit further studies that could characterise the events that occur during recovery from severe pancreatitis and that the controversial issue of whether or not severe acute pancreatitis evolves into chronic pancreatitis could be examined in such studies. In this communication, we report the results of experiments designed to examine these issues. We note that complete recovery occurs comparatively rapidly after relief of obstruction and that chronic pancreatitis does not develop.

## Methods

### Preparation of animals

Randomly trapped, apparently healthy, opossums (*Didelphis Virginiana*) of either sex weighing 1.1-5.8 kg were obtained from R-Zoo (Neshkoro, WI), Northeastern Wildlife (South Plymouth, NY) or R Singleton (Arcachia, FL). Conditioned animals were housed in individual steel cages in a climate controlled room with ambient temperature of 23±3°C and with a 12 hour light/dark cycle. Animals were fed an opossum laboratory diet and given water ad libitum. Because trapped opossums commonly harbour a variety of parasites, all animals were extensively dewormed (Ivomectin, 1% solution, 0.2 ml/kg intramuscularly, Merck-Agvet, Brassway, NJ) before starting the experiments. In addition, all animals were pre-treated with a five day course of penicillin G (50 000 U/kg intramuscularly

Department of Surgery, Beth Israel Hospital, Harvard Medical School, Harvard Digestive Diseases Center, Boston, USA  
M Rünzi  
A Saluja  
A Kaiser  
D Gerdes  
M L Steer

Division of Pediatric Gastroenterology and Nutrition, Boston University School of Medicine, Boston, USA  
A Sengupta

Correspondence to: Dr M Steer, Department of Surgery, Beth Israel Hospital, 330 Brookline Avenue, Boston, MA 02215 USA.

Accepted for publication 31 December 1994

on alternate days). This prophylactic treatment with penicillin G was continued for 10 days after operation and induction of pancreatitis. This regimen of prophylactic penicillin treatment was chosen because opossums are very susceptible to infection, especially with streptococcus D, and fatal acute bacterial endocarditis is comparatively common among these animals if they are left untreated.<sup>9</sup>

The experimental protocol was approved by the Institutional Animal Care and Use Committee. Animals were anaesthetised by intraperitoneal injection of pentobarbital (50 mg/kg). Using sterile technique, an upper mid-line laparotomy was performed and the cystic duct was ligated to prevent the gall bladder from serving as a bile reservoir. Control sham operated animals underwent duodenotomy and closure of the duodenotomy but no further surgical manipulation. In contrast, the experimental animals underwent placement of a balloon tipped catheter (size 4F, Shiley Inc, Irvine, CA) in the CBPD as previously described.<sup>8</sup> For this purpose, the duodenum was opened on its antimesenteric surface and the catheter was passed into the ampulla of Vater without performance of a sphincterotomy. After inflation of the balloon and closure of the duodenotomy, the catheter was secured to a subcutaneous site and the abdomen was closed. The control sham operated group of animals (n=3), which had only cystic duct ligated, underwent sham re-operation (laparotomy) five days later and they were then killed 36 days after that procedure. In the experimental animals, ductal obstruction was relieved by removing the balloon tipped catheter, after a laparotomy under pentobarbital anaesthesia, five days after catheter placement. At that time, those experimental animals were randomly assigned to seven different groups based on the length of time that was allowed to elapse between relief of obstruction and death. That time was as follows: group A (n=4), zero days; group B (n=3), one day; group C (n=4), two days; group D (n=4), seven days; group E (n=4), 14 days; group F (n=3), 21 days; group G (n=7), 65 days; and group H (n=3), 90 days. At those times, animals were killed by the intravenous administration of a lethal dose of pentobarbital, the abdomen was opened, and blood as well as pancreas was harvested for various assays (see later). In addition to the sham operated and experimental groups of animals described, a non-operated control group of animal (n=4) were also studied. The results obtained in that group were, in all aspects studied, not significantly different from those noted for the sham operated control group.

We chose to study recovery from acute necrotising pancreatitis induced by a five day period of duct obstruction after performing preliminary studies to evaluate the relation between animal survival and the duration of duct obstruction. Those studies (not shown) showed that all animals survived when the ductal obstruction was relieved after five days. On the other hand, when ductal obstruction was present for seven or more days, animal

death was common (approximately 80%) and, under those circumstances, most of the animals died within 10–14 days of the time of initial ductal obstruction.

#### *Assessment of acinar cell necrosis by morphometry*

Complete cross-sections of the head, body, and tail of the pancreas were fixed in 10 per cent neutral phosphate buffered formaldehyde. Paraffin wax embedded sections (5  $\mu$ m) were stained with haematoxylin and eosin, periodic acid Schiff, and Sudan black. They were examined by an experienced morphologist who was not aware of the identity of the sample. Acinar cell necrosis was defined as destruction of acinar histo-architecture with the remaining tissue being composed of amorphous debris, cellular ghosts, and inflammatory cells. The extent of necrosis was morphometrically quantified using a computerised image analysis video unit (model CCD-72, Dage-MTI, Michigan City, IN) equipped with the NIH-1200 image analysis software. As previously reported,<sup>7-9</sup> foci of necrosis in this model of acute pancreatitis are equally distributed between the head, body, and tail of the pancreas. Thus, morphometric data from the various sections obtained from each animal were pooled for data analysis. Approximately 10 randomly chosen high power microscope fields were examined for each tissue sample and three tissue samples were evaluated for each experimental animal.

#### *Thymidine incorporation*

The incorporation of [<sup>3</sup>H]-thymidine into tissue samples was used to evaluate the rate of DNA synthesis. For these studies, animals were given a bolus of [<sup>3</sup>H]-thymidine (100  $\mu$ Ci/kg, 24.5 mCi/mmol, Amersham, Arlington Heights, IL) two hours before death. [<sup>3</sup>H]-thymidine incorporation was evaluated as previously described.<sup>10</sup> After tissue homogenisation, [<sup>3</sup>H]-labelled DNA was precipitated by addition of 20% trichloroacetic acid. The precipitates were washed twice in 10% trichloroacetic acid and radioactivity quantified in a Packard Tricarb Scintillation counter (Packard, Sterling, VA). Results were expressed as counts per minute per mg DNA.

#### *Immunocytochemistry for collagen*

Fragments of pancreas were fixed by immersion in neutral buffered picroformaldehyde for 18 hours at 4°C. They were then washed extensively overnight with cold phosphate buffered saline (pH 7.4) and cryoprotected with 15% sucrose enriched ice cold phosphate buffered saline (pH 7.4). The samples were rapidly freeze blocked in Tissue-Tek OCT compound (Miles, Inc, Elkhart, IN) and stored at -80°C until sectioning. Cryosections of 10  $\mu$ m were prepared and placed in gelatin subbed slides, which were allowed to dry overnight. They were rinsed in phosphate buffered saline and sites of non-specific protein binding were blocked by incubation with goat serum (10 minutes, room

temperature). After washing they were exposed for 18 hours at 4°C to the primary polyclonal antiserum (rabbit anti-collagen intravenously, #PS46, Monosan, Rotterdam, the Netherlands), which had been diluted 1:40 before use. After thorough rinsing, they were exposed for one hour at room temperature to the secondary antibody (goat antirabbit IgG conjugated with fluorescein isothiocyanate (ICN Immunobiologicals, Lisle, IL), which had been diluted 1:33 before use. Antigen was identified using an appropriate excitation filter and epi-illumination with an Olympus BHT-2 microscope. Immunocytochemistry controls included samples in which the primary antibody was omitted or in which the primary antiserum had been previously exposed to purified collagen (100 µg/ml) for 24 hours at 4°C. Samples of opossum achilles tendon and plantaris longus tendon were examined as positive controls while samples of rat brain were examined as negative controls.

#### Assays

Blood was harvested from the right ventricle and serum prepared for measurement of amylase activity as described by Pierre *et al*<sup>11</sup> as well as bilirubin content as described by Winsten and Cehelyk.<sup>12</sup> Fragments of pancreas were rapidly removed and weighed to determine pancreatic wet weight. These fragments were then desiccated by incubation at 160°C for 48 hours and re-weighed to determine dry weight. Water content was calculated as the difference between wet and dry weight and expressed as a per cent of the pancreatic wet weight. Other fragments of pancreas were harvested for measurement of DNA, protein, amylase, ornithine decarboxylase (ODC), and hydroxyproline. The fragments were minced with scissors on ice and homogenised three times (20 seconds each) in ice cold buffer (50 mM phosphate, pH 7.4) using a Polytron homogeniser (Brinkman, Westbury, NY). DNA was quantified fluorometrically using Hoechst dye 33258 and calf thymus DNA as the standard.<sup>13</sup> Protein was quantified according to Lowry *et al*<sup>14</sup> using bovine serum albumin as the standard. Amylase was quantified as described by Pierre *et al*.<sup>11</sup> Ornithine decarboxylase (ODC) activity was measured as described by Langlois and Morrisset<sup>15</sup> and calculated as [<sup>14</sup>C]-CO<sub>2</sub> released per mg DNA. Hydroxyproline content was measured according to Ho and Pang<sup>16</sup> with slight modifications. In addition to hydroxyproline measurement, collagen formation was further evaluated using the chromatographic technique of Lopez de Leon and Rojkind.<sup>17</sup> For these measurements, paraffin wax embedded cross sections of the head, body, and tail regions of the pancreas (see Table) were deparaffinised, stained with 0.1% Sirius red (Miles, Inc, Elkhart, IN), and 0.1% Fast Green FCF (Sigma Chemicals, St Louis, MI) in saturated picric acid. Sirius red labels collagenous protein while Fast Green FCF labels non-collagenous protein. After incubation for 30 minutes at room temperature the stains were eluted with 0.1 N

NaOH in absolute methanol and the eluted dye was quantified in a spectrophotometer (Danbury, CT). The amount of collagenous protein was expressed as a per cent of total protein in the cross sections.

#### Analysis of data

Statistical analysis of the data was accomplished using analysis of variance (ANOVA) and the Newman-Keul's test as a post hoc test. The data shown in the Figures represent mean (SEM) values. The absence of error bars indicates that the SEM was too small to illustrate. Significant differences in results were defined as those with a p value <0.05.

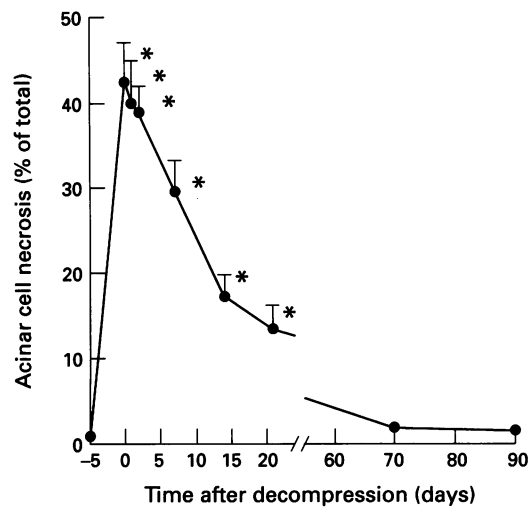
#### Results

All animals recovered quickly from anaesthesia and displayed appropriate behaviour until the time of death. Food and water consumption for control and experimental animals were similar. In accord with our previous finding, serum bilirubin concentration and amylase activity were increased five days after duct obstruction but then rapidly declined to the control value after relief of ductal obstruction (data not shown). Pancreatic water content was also increased five days after duct obstruction with a decline to control values noted shortly after relief of obstruction (data not shown). During the period of ductal obstruction, pancreatic protein and amylase content declined. Both pancreatic protein and amylase content returned to control values within one week after relief of obstruction, increased to values above the control level over the subsequent week (165 (10)% of control value), and then gradually declined.

#### Acinar cell necrosis

**Morphometry** – five days after CBPD obstruction, morphometric analysis at the light microscope level showed that 42.5 (4.5)% of acinar cells were necrotic. With relief of CBPD obstruction, evidence of acinar cell necrosis rapidly diminished reaching a value of 17.3 (2.5)% of acinar cells 14 days later and returning to the value noted in control sham operated animals by 60 days after relief of CBPD obstruction (Fig 1).

**Microscopy** – Figure 2(A)-(D) shows light micrographs from representative animals. The normal pancreas morphology is shown in (A) while that noted after CBPD obstruction for five days is shown in (B). Figure 2(B) shows various features of acinar cell injury and necrosis including single foci of necrotic cells (arrowheads in (B)) as well as the presence of cellular ghosts. At this time, numerous inflammatory cells as well as spindle cells, which may be fibroblasts (asterisks in (B)) were seen in the interstitial tissue spaces. Nine days after relief of ductal obstruction, only infrequent necrotic acinar cells were seen although inflammatory cells as well as spindle shaped cells were still noted in the interstitial space (asterisks in (C)). Ninety days after relief of CBPD obstruction,

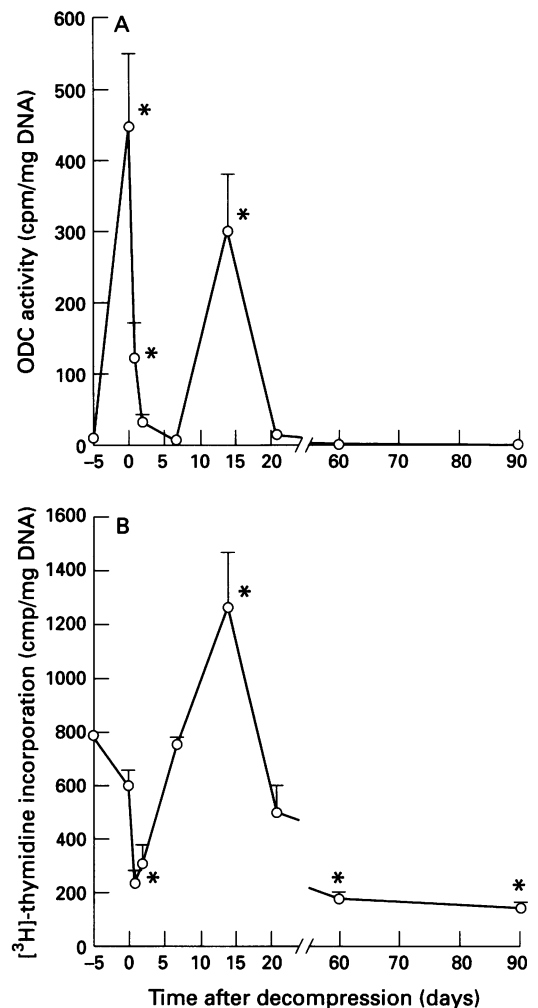


**Figure 1:** Effect of bile pancreatic duct decompression on acinar cell necrosis. Opossums underwent obstruction of the bile pancreatic duct as described in the text and decompression by removal of the balloon tipped catheter five days later. They were killed 0–90 days after decompression. Acinar cell necrosis was determined by morphometry, as described in the text, and expressed as the per cent of total surface area that was occupied by necrotic cells. Asterisks show values significantly different ( $p < 0.05$ ) from control.

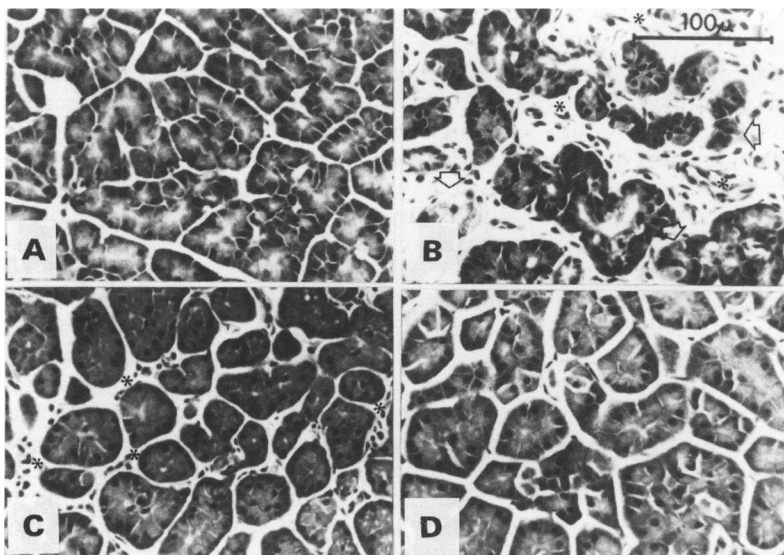
no evidence of inflammation, acinar cell necrosis, or fibrosis was seen (D) and the pancreatic morphology was similar to that noted for samples taken from control animals (A).

#### ODC activity and DNA synthesis

Duct obstruction was associated with an increase in ODC activity but no change in the rate of incorporation of [ $^3\text{H}$ ]-thymidine into pancreatic DNA (Figs 3(A) and (B)). With relief of ductal obstruction, ODC activity rapidly returned to the pre-obstruction value while the rate of [ $^3\text{H}$ ]-thymidine incorporation into DNA fell below the control value. Subsequently, both ODC activity and the



**Figure 3:** Effects of bile pancreatic duct decompression on pancreatic ornithine decarboxylase (ODC) activity and incorporation of [ $^3\text{H}$ ]-thymidine into pancreatic DNA. Conditions are as described in Figure 1 legend. ODC activity (A) was measured as described in the text and expressed as cpm of [ $^{14}\text{C}$ ]- $\text{CO}_2$  released per mg DNA. [ $^3\text{H}$ ]-thymidine incorporation into DNA (B) was measured as described in the text. Results represent mean (SEM) values for three to seven animals in each group with each measurement being performed in duplicate. Asterisks show values significantly different ( $p < 0.05$ ) from control.



**Figure 2:** Effect of bile pancreatic duct decompression on pancreatic morphology. Representative light microscopic images for animals from the following groups are shown: (A) Sham operated control; (B) CBPD obstruction for five days with zero days decompression; (C) CBPD obstruction for five days with 90 days decompression. Arrowheads in (B) point to areas of acinar cell damage indicated by loss of polarity and architecture, loss of cellular borders, and the presence of amorphous debris as well as cell ghosts. Asterisks in (B) and (C) indicate presence of inflammatory cells as well as spindle shaped cells.

incorporation of [ $^3\text{H}$ ]-thymidine into pancreatic DNA were transiently increased. The rise in DNA synthesis was first noted seven days after relief of obstruction, reached a peak value on the 14th day after relief of obstruction, and thereafter slowly declined over the subsequent two months. The rise and fall of ODC activity after relief of obstruction were more abrupt but ODC activity was also found to reach a peak value 14 days after relief of obstruction.

#### Collagen metabolism

Figure 4 shows the effects of CBPD obstruction as well as the relief of CBPD obstruction on pancreatic content of hydroxyproline and collagen. Hydroxyproline values were approximately fivefold higher than the control value after five days of CBPD obstruction and those values remained increased during the initial seven days after relief of obstruction (A). Thereafter, pancreatic hydroxyproline values returned to that found in samples taken from

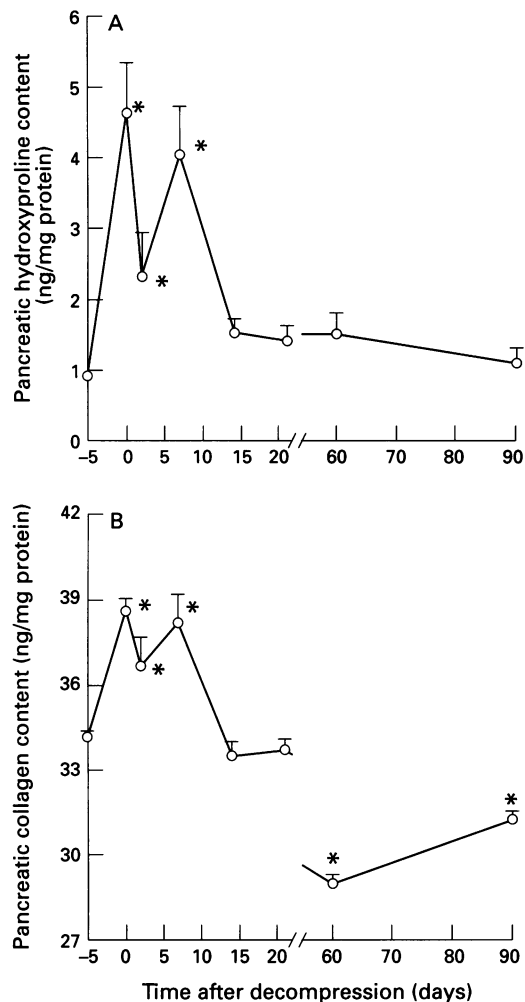


Figure 4: Pancreatic hydroxyproline and collagen content after relief of CBPD obstruction. Pancreatic content of hydroxyproline (A) was measured as described in the text and expressed as ng hydroxyproline per mg pancreatic protein. Pancreatic content of collagen (B) was measured using the Sirius Red-Fast Green FCF spectrophotometric technique as described in the text and expressed as  $\mu\text{g}$  collagen per mg non-collagenous protein. Groups are as described in the Figure 1 legend. Results represent mean (SEM) values for three to seven animals in each group with each measurement being performed in duplicate. Asterisks show values significantly different ( $p < 0.05$ ) from that noted for control sham operated animals.

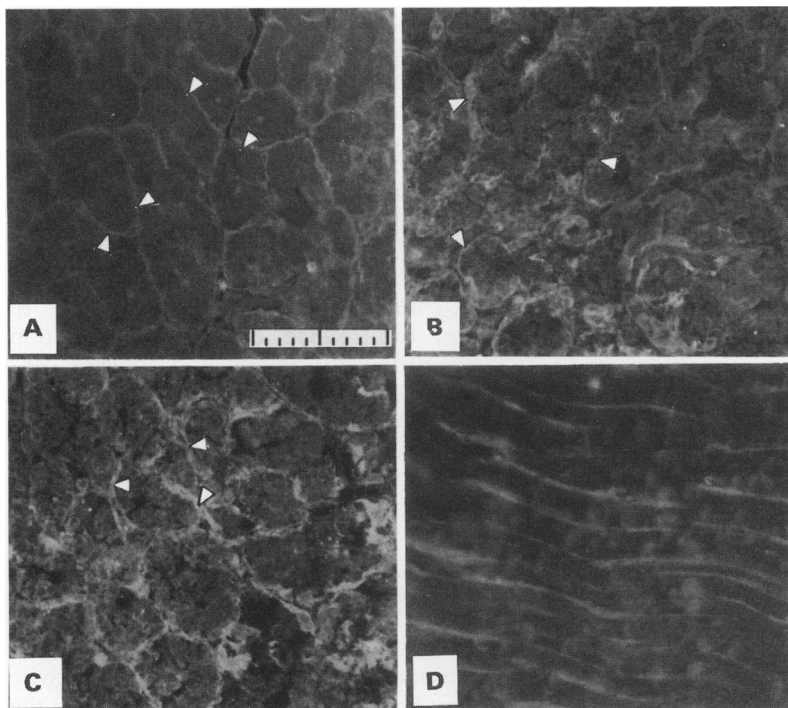
sham operated control animals. Pancreatic collagen content was also increased five days after ductal obstruction and remained transiently increased during the initial seven days after relief of ductal obstruction (B). Thereafter, pancreatic collagen content declined below that value noted for control sham operated animals. Pancreatic content of types I-V collagen was also evaluated using an immunocytochemical fluorescence microscopy technique. As Figure 5 shows, no increase in the pancreatic content of collagen during the period of duct obstruction or after relief of duct obstruction could be shown using this approach.

### Discussion

Most patients recover from an episode of acute pancreatitis, even if it is associated with necrosis of significant portions of the pancreas. The intrapancreatic events that accompany that recovery are poorly understood. We have studied this issue using an animal model of acute

pancreatitis, which closely resembles gall stone induced pancreatitis in humans. As previously noted, obstruction of the opossum CBPD results in haemorrhagic necrosis of the gland and extensive peripancreatic fat necrosis. The extent of parenchymal necrosis is dependent on the duration of duct obstruction and affects roughly 40% of acinar cells after five days of obstruction. During those five days of obstruction, serum amylase activities and pancreatic water content initially rise, then begin to decline, but remain above pre-obstruction values. Pancreatic protein and amylase content, on the other hand, fall during the period of duct obstruction. These various changes probably reflect the fact that extensive intrapancreatic injury and intraparenchymal inflammation accompany obstruction of the opossum CBPD. We have also noted that CBPD obstruction in the opossum is associated with an increase in pancreatic ODC activity but no change in the rate of incorporation of [ $^3\text{H}$ ]-thymidine into pancreatic DNA. The cells responsible for the rise in ODC activity have not been identified. We would favour the hypothesis that it reflects infiltration and possible replication of inflammatory cells during the early stages of pancreatitis but many other potential mechanisms may underlie these phenomena.

The CBPD obstruction in this model can be easily relieved by removing the balloon tipped catheter from the CBPD. The fact that serum bilirubin concentrations rapidly decline after removal of the catheter is consistent with the conclusion that obstruction is relieved at the time of catheter removal. The progressive increase in the extent of acinar cell necrosis is abruptly halted by relief of obstruction and, over the following three weeks, the extent of necrosis rapidly falls. Other indicators of pancreatic injury also are favourably changed by relief of ductal obstruction. For example, serum amylase activities and pancreatic water content, as well as the pancreatic content of protein and amylase gradually return to their pre-obstruction values. Pancreatic ODC activity returns to the pre-obstruction value shortly after relief of obstruction but then both ODC activity and the rate of [ $^3\text{H}$ ]-thymidine incorporation into pancreatic DNA, two indicators of cell replication, rise approximately 14 days after the relief of obstruction. A transient increase in pancreatic protein and amylase content is also noted at roughly the same time. It is probable that these changes reflect acinar cell replication. Morphological evaluation of samples obtained 14 days after relief of obstruction suggest the appearance of so called tubular complexes, which are believed to reflect pancreatic regeneration<sup>18-21</sup> but identification of tubular complexes in this model is made difficult by the fact that ductal obstruction causes the lumina of many of the acini to dilate and the cells lining the acinar lumina to assume a more cuboidal shape. Conclusive evidence that acinar cell replication occurs at this time during recovery would, therefore, require performance of autoradiographic nuclear labelling studies, which were, unfortunately,



**Figure 5:** Immunohistochemical demonstration of collagen. (A) shows representative sample taken from unoperated control animal. Arrowheads identify areas of periacinar collagen in the basement membrane area at the basalateral surface of cells. (B) shows representative section taken from opossim after five days of CBPD obstruction while (C) shows representative section taken from animal subjected to five days of CBPD obstruction followed by 90 days of ductal decompression. Arrowheads in (B) and (C) show areas of periacinar collagen which, although less fine in its appearance, does not seem to be increased in amount when compared with that noted in the non-operated control groups (A). (D) shows section of plantaris longus tendon (positive control). Controls were negative (not shown). Calibration bar in (A) applies to all panels and is 100  $\mu\text{m}$  long with 10  $\mu\text{m}$  gradations.

not possible because of the very large doses of radioactive tracer that would be needed for such studies in opossims. It would also be interesting to find out if the increase in ODC activity precedes the rise in [ $^3\text{H}$ ]-thymidine incorporation and to evaluate the temporal relation between these events and the transient changes in tissue protein as well as amylase content that we have seen. Unfortunately, use of wild animals such as the opossim is associated with considerable interanimal variation, which makes the temporal resolution of these events difficult if not impossible.

We were particularly interested in noting whether recovery from acute necrotising pancreatitis was associated with changes consistent with the development of chronic pancreatitis. On light microscopic examination of the tissue, no evidence of chronic inflammation or fibrosis was noted. Deposition of collagen in interstitial areas of the pancreas is, however, the essential feature of chronic pancreatitis and such changes might have been overlooked by light microscopic examination.

To further explore this issue, we have used three different but complementary techniques to discover if relief of the ductal obstruction and recovery from acute necrotising pancreatitis is associated with formation of collagen in the pancreas. The first method entails direct quantifications of pancreatic hydroxyproline values. Those studies (Fig 4(A)) showed that pancreatic hydroxyproline values were not increased 60 or 90 days after relief of CBPD obstruction. This negative finding suggests

that pancreatic collagen values are not increased at those times. On the other hand, an increase in pancreatic hydroxyproline content was seen five days after induction of ductal obstruction and this increase persisted during the initial seven days after relief of CBPD obstruction. These findings show that CBPD obstruction triggers transient collagen formation and that this phase of collagen formation is followed by rapid degradation of the newly formed collagen (Fig 4(A)). These findings and conclusions are consistent with those of Elsässer *et al*<sup>22 23</sup> who found that collagen was transiently formed as a result of fibroblast influx during secretagogue induced pancreatitis in the rat. We have also noted the appearance of spindle shaped cells suggestive of fibroblasts during this phase of induction and recovery from necrotising pancreatitis in the opossim (Fig 2(B) and (C)).

The second technique that we have used to evaluate collagen metabolism during recovery from necrotising pancreatitis entails the chromatographic measurement of the ratio of collagenous to non-collagenous protein in the pancreas. Using this technique, we have found collagen values in control samples that are similar to those found by others who have used this method to study human tissues.<sup>24 25</sup> In accord with our results for studies evaluating tissue hydroxyproline values, we have also noted that pancreatic content of collagenous protein is increased within five days of CBPD obstruction and that those values remain increased during the initial seven days after relief of CBPD obstruction (Fig 4(B)). Thereafter, pancreatic content of collagenous protein declines to values below those noted for control sham operated animals.

The third method that we have used to evaluate collagen metabolism during recovery from necrotising pancreatitis entails immunocytochemistry using polyclonal antibodies directed against types I-V collagen. Those studies showed no evidence of increased pancreatic content of collagen during induction or recovery from necrotising pancreatitis (Fig 5).

In summary, the findings reported show that relief of CBPD obstruction in the opossim is associated with rapid recovery from acute necrotising pancreatitis. We suggest that this recovery is associated with acinar cell replication, which peaks seven to 14 days after relief of obstruction. Tissue concentrations of collagen are transiently increased during the recovery phase but fibrosis and chronic pancreatitis do not develop. Rather, the pancreas re-acquires its previous morphological appearance – that is, *resstituto ad integrum* occurs. Using this model of necrotising pancreatitis, we could detect no evidence in support of the necrosis-fibrosis hypothesis.

There are significant differences between this opossim model of necrotising pancreatitis and human pancreatitis, particularly that caused by alcohol misuse. Thus, the conclusions reached from our experimental studies may or may not be applicable to the clinical situation and the question of whether human acute necrotising pancreatitis can evolve into

chronic pancreatitis must remain, to some extent, unresolved. At a minimum, however, our studies show that necrosis of pancreatic tissue during severe biliary acute pancreatitis does not inevitably result in chronic pancreatitis or fibrosis of the gland, or both.

- 1 Gyr KE, Singer MV, Sarles H. Revised classification of pancreatitis – Marseille 1984. In: Gyr KE, Singer MV, Sarles H, eds. *Pancreatitis, concepts, and classification*. Amsterdam: Elsevier, 1984.
- 2 Klöppel G, Maillet B. Pseudocysts in chronic pancreatitis: a morphological analysis of 57 resection specimens and 9 autopsy pancreata. *Pancreas* 1991; **6**: 266–74.
- 3 Angelini G, Cavallini G, Pederzoli P, Bovo P, Bassi C, DiFrancesco V, et al. Long-term outcome of acute pancreatitis: prospective study with 118 patients. *Digestion* 1993; **54**: 143–7.
- 4 Büchler M, Hanke A, Malfertheiner P. Follow-up after pancreatitis: morphology and function. In: Beger HG, Büchler M. *Acute pancreatitis*. Berlin, Springer, 1987: 367–74.
- 5 Lerch MM, Saluja AK, Dawra R, Ramarao P, Saluja M, Steer ML. Acute necrotizing pancreatitis in the opossum: earliest morphological changes involve acinar cells. *Gastroenterology* 1992; **103**: 205–13.
- 7 Lerch MM, Saluja AK, Rünzi M, Dawra R, Saluja M, Steer ML. Pancreatic duct obstruction triggers acute necrotizing pancreatitis in the opossum. *Gastroenterology* 1993; **104**: 853–61.
- 8 Rünzi M, Saluja A, Lerch MM, Dawra R, Nishino H, Steer ML. Early ductal decompression prevents the progression of biliary pancreatitis: an experimental study in the opossum. *Gastroenterology* 1993; **105**: 157–64.
- 9 La Plante ES, Burrell RG. Bacterial endocarditis in opossums. *Bull Wildlife Disease Assoc* 1966; **2**: 10–2.
- 10 Dawra R, Saluja A, Lerch MM, Logsdon C, Steer ML. Stimulation of pancreatic growth by cholecystokinin is mediated by high affinity receptors on rat pancreatic acinar cells. *Biochem Biophys Res Commun* 1993; **193**: 814–20.
- 11 Pierre KJ, Tung KK, Nadj H. A new enzymatic kinetic method for determination of amylase. *Clin Chem* 1976; **22**: 1219.
- 12 Winsten S, Cehelyk B. A rapid micro diazo technique for measuring total bilirubin. *Clin Chim Acta* 1969; **25**: 441–6.
- 13 Labarca C, Paigen K. A simple, rapid, and sensitive DNA assay procedure. *Anal Biochem* 1980; **102**: 344–52.
- 14 Lowry OH, Rosebrough NJ, Farr AL, Randall RJ. Protein measurement with the Folin phenol reagent. *J Biol Chem* 1951; **193**: 265–75.
- 15 Langlois A, Morisset J. Effects of feeding, fasting, and caerulein treatment on ornithine decarboxylase in rate pancreas. *Pancreas* 1991; **6**: 534–41.
- 16 Ho K-C, Pang C-P. Automated analysis of urinary hydroxyproline. *Clin Chim Acta* 1989; **185**: 191–6.
- 17 Lopez de Leon A, Rojkind M. A simple micromethod for collagen and total protein determination in formalin-fixed paraffin-embedded sections. *J Histochem Cytochem* 1985; **33**: 737–43.
- 18 Willemer S, Elsässer HP, Kern HF, Adler G. Tubular complexes in cerulein- and oleic acid-induced pancreatitis in rats: glycoconjugate pattern, immunocytochemical, and ultrastructural findings. *Pancreas* 1987; **2**: 669–75.
- 19 Elsässer HP, Adler G, Kern HF. Time course and cellular source of pancreatic regeneration following acute pancreatitis in the rat. *Pancreas* 1986; **1**: 421–9.
- 20 Iovanna JL, Odaira, Berger Z, Sarles H. Temporary pseudo-chronic lesions during the recovery of acute necrohemorrhagic pancreatitis in rabbits. *Pancreas* 1988; **3**: 433–8.
- 21 Lachene de la Porte P, Iovanna J, Odaira C, Houx R, Sarles H, Berger Z. Involvement of tubular complexes in pancreatic regeneration after acute necrohemorrhagic pancreatitis. *Pancreas* 1991; **6**: 298–306.
- 22 Elsässer HP, Haake T, Grimmig M, Adler G, Kern HF. Repetitive cerulein-induced pancreatitis and pancreatic fibrosis in the rat. *Pancreas* 1992; **7**: 385–90.
- 23 Elsässer HP, Adler G, Kern HF. Fibroblast structure and function during g regeneration from hormone-induced acute pancreatitis in the rat. *Pancreas* 1989; **4**: 168–78.
- 24 Valderrama R, Navarro S, Campo E, Campos J, Gimenez A, Pares A, et al. Quantitative measurement of fibrosis in pancreatic tissue. *Int J Pancreatol* 1991; **10**: 23–9.
- 25 Bedossa P, Lemaigre G, Bacci J, Martin E. Quantitative estimation of the collagen content in normal and pathologic pancreas tissue. *Digestion* 1989; **44**: 7–13.