

Induction of NGAL synthesis in epithelial cells of human colorectal neoplasia and inflammatory bowel diseases

B S Nielsen, N Borregaard, J R Bundgaard, S Timshel, M Sehested, L Kjeldsen

Abstract

In inflammatory and neoplastic disorders of the colon a defect barrier function of the mucosa may result in absorption of bacterial products from the intestinal lumen. These products may further recruit inflammatory cells and thus augment the inflammatory response. A novel lipocalin in neutrophils, neutrophil gelatinase associated lipocalin (NGAL), with the ability to bind bacterial formyl-peptides, has been described and therefore it is of interest to investigate the expression of this protein in diseases of the colon. Expression of NGAL was investigated by immunohistochemistry and by mRNA in situ hybridisation in normal colon and in neoplastic and inflammatory colorectal diseases. A very high expression of NGAL was seen in colonic epithelium in areas of inflammation, both in non-malignant epithelium (diverticulitis, inflammatory bowel disease, and appendicitis) as well as in premalignant and malignant neoplastic lesions of the colon. In adenocarcinoma, the NGAL expression was especially abundant in the transitional mucosa and in the superficial ulcerated area. On the other hand, no NGAL expression could be detected in lymph node metastases from these adenocarcinomas. A weak expression of NGAL in some epithelial cells was only occasionally seen in normal colon. In conclusion, NGAL synthesis is induced in epithelial cells in inflammatory and neoplastic, colorectal diseases. NGAL may serve an important anti-inflammatory function as a scavenger of bacterial products.

(Gut 1996; 38: 414-420)

Keywords: in situ hybridisation, immunohistochemistry, neutrophils, lipocalin, inflammation.

Inflammatory bowel diseases are characterised by a prominent infiltration of the mucosa by inflammatory cells including macrophages, lymphocytes, plasma cells, and neutrophils. The cellular infiltration is especially abundant around ulcerations or fissures of the bowel wall. Ulceration is also a characteristic feature of adenocarcinoma of the colon, in which acute inflammation with infiltration of macrophages and neutrophils is seen. The role of cytokines in inflammatory bowel disease has been the subject of intense investigation over recent

years. In inflammatory bowel disease, synthesis of interleukin 1 (IL1), tumour necrosis factor α (TNF α), and IL2 in macrophages and lymphocytes may be induced as a result of passage through the colonic mucosa of bacterial products, including lipopolysaccharide.¹⁻⁶ These cytokines may in turn induce synthesis of a variety of other inflammatory mediators including prostaglandins, platelet activating factor, leukotrienes, IL8, granulocyte colony stimulating factor (G-CSF),^{1,5,7-11} most of which are chemotactic for neutrophils, which are then recruited to and activated in the inflammatory focus. This may induce tissue destruction and ulceration, and further impair the barrier function of the mucosa.¹² The role of the mucosa itself in the inflammatory reaction of inflammatory bowel disease and colon cancer has become increasingly evident.¹³ In response to local inflammation/inflammatory mediators, colonic epithelial cells (including cancer cell lines) are induced to express immunologically active molecules like MHC class II,¹⁴⁻¹⁶ the adhesion protein intercellular adhesion molecule-1,^{14,17} the cytokines IL8, GM-CSF, MCP-1, and TNF α ,^{10,18,19} prostanoids,^{7,20} and 12-lipoxygenase, which participates in the formation of leukotrienes from arachidonic acid.²¹

We have described the isolation and characterisation of a novel protein in human neutrophils, neutrophil gelatinase associated lipocalin (NGAL).²² By northern blotting of a variety of tissues including brain, lung, heart, kidney, liver, blood, and bone marrow cells, we only found mRNA expression in neutrophil precursors in the bone marrow.²³ Furthermore, NGAL was shown to exist both as a 25 kDa monomer, as a 46 kDa homodimer, and in a covalent complex with neutrophil gelatinase.^{22,24} As the name implies, NGAL is a member of the lipocalin family. These glycoproteins all have a protein backbone of 18 to 20 kDa.^{25,26} Despite a low degree of overall amino acid identity, the lipocalins share certain conserved motifs, which are responsible for their common tertiary structure consisting of one α helix and an eight stranded β barrel surrounding a hydrophobic core.²⁶⁻²⁸ The hydrophobic core has been described as a pocket that enables the lipocalins to bind small lipophilic substances. Rather than being specific for one ligand, it has been postulated that many lipocalins might bind several different lipophilic substances.²⁵ We have shown that NGAL can bind a radioiodinated derivative of the bacterial chemotactic formyl-peptide FMLP,²⁶ and it is possible that

Department of
Pathology, Sundby
Hospital, Denmark
B S Nielsen
S Timshel
M Sehested

Finsen Laboratory
B S Nielsen

Granulocyte Research
Laboratory,
Department of
Hematology
N Borregaard
L Kjeldsen

Department of Clinical
Biochemistry
J R Bundgaard

University Hospital,
Rigshospitalet,
Copenhagen, Denmark

Correspondence to:
Professor Niels Borregaard,
Granulocyte Research
Laboratory, Department of
Hematology, L-4042,
University Hospital,
Rigshospitalet, Blegdamsvej
9, 2100 Copenhagen Ø,
Denmark.

Accepted for publication
7 September 1995

Expression of NGAL mRNA detected by in situ hybridisation in colorectal lesions

Colorectal lesion	Total examined	Positive
Normal epithelium*	13	4§
Appendix (normal)†	9	4§
Appendix (inflamed)	8	8
Diverticulitis	5	4
Ulcerative colitis	3	3
Crohn's disease	5	5
Adenoma	2	2
Adenocarcinoma	11	10
Lymph node metastasis‡	3	0

*Obtained from patients with adenocarcinoma (seven specimens) and from patients suffering from ulcerative colitis and Crohn's disease (six specimens), †obtained at hysterectomy, ‡from primary colon cancers that expressed NGAL. §Only weak staining was seen.

NGAL also binds other lipophilic inflammatory mediators like platelet activating factor, leukotriene B₄, and lipopolysaccharide. NGAL therefore may possess important immunomodulatory actions.

One way of obtaining knowledge about the function of a protein is to study its localisation in various organs and diseases. A number of proinflammatory mediators are induced in inflammatory bowel diseases and presumably also in adenocarcinoma of the colon. Furthermore, a defect barrier function of the mucosa in these disorders potentially leads to the transepithelial passage of lipopolysaccharide and bacterial formyl-peptides. As NGAL may have the ability to bind these substances, we found it of interest to investigate the expression of NGAL in inflammatory bowel disease and neoplastic lesions of the colon. This was done by immunohistochemistry and mRNA in situ hybridisation.

Methods

Tissues

Specimens from 14 colorectal adenocarcinomas containing both malignant and normal epithelium were used for immunohistochemistry and 11 of these also for in situ hybridisation. The Table lists the additional specimens of different inflammatory bowel diseases used for in situ hybridisation. All specimens were obtained at surgery.

For optimal fixation of tissue for immunohistochemistry, specimens were fixed for only one hour in 4% phosphate buffered formalin followed by ethanol dehydration/fixation and paraffin wax embedding. Prolonged fixation of specimens caused loss of NGAL immunoreactivity. These short-term fixed specimens completely lacked detectable mRNA, however, as determined by in situ hybridisation with a 28' mer thymidine probe for the poly-A tail of mRNAs (see later). On the other hand, there was a strong mRNA signal in 24 hour formalin fixed specimens using the poly-T probe. Similar findings with absence of in situ hybridisation signal in ethanol fixed specimens but increased mRNA signal and reduced immunoreactivity after prolonged formalin fixation have been described by Urieli-Shoval *et al.*³⁰ For optimal fixation of tissues for in situ hybridisation specimens were therefore fixed

for 24 hours in 4% phosphate buffered formalin and subsequently embedded in paraffin wax.

Immunohistochemistry

Five µm sections were cut and air dried overnight. Paraffin wax was dissolved in 60°C cocoa oil for 20 minutes and sections were then hydrated through decreasing concentrations of ethanol. Sections were trypsinised (0.05% trypsin (Merck, Darmstadt, Germany)) in 50 mM TRIS, 0.1% CaCl₂ (w/v), pH 7.4, followed by blocking using 10% normal swine serum (X-901, Dako, Glostrup, Denmark). Incubation of affinity purified polyclonal rabbit anti-NGAL antibodies (0.5 mg/ml²²) was performed at 500 to 2000-fold dilution in TRIS buffered saline (TBS), pH 7.6, containing 0.25% bovine serum albumin (BSA). Sections were incubated at 4°C overnight followed by incubation at room temperature for an additional 30 to 60 minutes. Primary antibodies were detected by biotinylated swine antirabbit immunoglobulin antibodies followed by incubation with the ABCComplex/HRP (according to instructions given in the ABC kit from Dako). All steps were followed by three washes in TBS. Sections were developed with 3-amino-9-ethyl-carbazol (Sigma Chemical, St Louis, MO) for 10 minutes and counterstained with haematoxylin. Pre-immune rabbit IgG (Dako, X-903) was used as a negative control. In addition, absorbed anti-NGAL (adding 10-fold molar excess of purified NGAL to the anti-NGAL antibodies) was used as a control of the specificity of the reaction.

In situ hybridisation

NGAL cDNA was subcloned in pBluescript (Stratagene) and sequenced as described.²³ Antisense and sense ³⁵S labelled RNA probes were obtained by in vitro transcription and subsequently used for in situ hybridisation using the method described by Pyke *et al.*³¹ Briefly, ³⁵S UTP labelled antisense and sense riboprobes were diluted to a final activity of 10⁶ cpm/µl. Four µl were used for hybridisation for each section. Hybridisation was performed overnight at 50°C. Sections were subsequently exposed on an autoradiographic emulsion for 10–14 days before development. For staining of total mRNA pretreatment of tissue sections was performed as above. The 92-3T-Dig Poly-T probe was applied (5 ng/ml) in 50% formamid, 12.5% dextran sulphate, 1 mg/ml tRNA, Ficoll 400 (0.02% (wt/vol)), polyvinylpyrrolidone (0.02% (w/v)), TRIS-HCl (10 mM, pH 6.8), and EDTA (0.5 mM). Sections were incubated for one hour followed by washes with SSC-buffers as follows: 2×SSC (0.3 M sodium chloride, 0.03 M sodium citrate, pH 7.0), 1×SSC, and 0.5×SSC each for 30 minutes. All steps were performed at room temperature. After washing in TBS-Triton, sections were blocked for unspecific binding with 0.25% normal rabbit serum for 10 minutes. Sections were then incubated with alkaline phosphatase conjugated mouse antidigoxigenin

(Boehringer Mannheim no 1093 274, Mannheim, Germany) diluted 1:500 in TBS-BSA and finally developed for 30 minutes with nitroblue tetrazoleum/5-bromo-4-chloro-3-indolylphosphate (Sigma Chemical, St Louis, MO).

Results

Expression of NGAL in colorectal neoplasia

Immunohistochemistry – in all 14 cases of adenocarcinoma an intense staining was seen in both normal and malignant epithelial cells in the transitional mucosa, and in the malignant epithelial cells just below the ulcer (Fig 1a). No or very few epithelial cells were positive in the adjacent normal appearing epithelium of the same specimens and in the invasive area of the tumour. Intense NGAL immunostaining was seen in all neutrophils as expected. These were found located in vessels and as tissue infiltrating neutrophils in the tumour and in the ulcer (Fig 1a).

In situ hybridisation was performed on 11 of 14 tumours investigated by immunohistochemistry. These samples also contained both normal and malignant epithelium, but differed from the samples used for immunohistochemistry in the fixation procedure (see Methods). A strong in situ hybridisation signal was seen in 10 of 11 cases (Table and Fig 1b and 1e). In these 10 cases, hybridisation was confined to epithelial cells localised to a pattern identical to the pattern seen by immunohistochemistry – that is, in cancer cells below the ulcer (Fig 1b) and in normal and malignant cells in the transitional mucosa (Fig 1e). In contrast with the immunohistochemical localisation, no in situ hybridisation signal was seen in any neutrophils. Cancer cells located in the deeper part of the tumour and at the invasive front were usually negative. At a distance of up to 1 cm from the tumour a few crypts of the normal epithelium were weakly positive in some of the cases. Furthermore, we investigated three lymph node metastases, which were obtained from specimens from patients with NGAL expressing primary tumours. These were all negative. In colonic adenomas, NGAL mRNA expression was seen only in the epithelial cells on the luminal surface of the lesions (Fig 1f).

Expression of NGAL mRNA in various

inflammatory diseases of colon and in appendicitis
The epithelial cells of virtually all specimens of diverticulitis (Fig 2a and 2b), ulcerative colitis (Fig 2c and 2d), and inflamed specimens of Crohn's disease (even with low grade inflammation as seen in Fig 2e and 2f) showed strong NGAL expression (Table). On the other hand, all epithelial cells of unaffected colorectal specimens from these patients with inflammatory bowel disease or diverticulitis were negative for NGAL expression (not shown). No signal was seen in infiltrating neutrophils.

A strong signal was seen in the epithelial cells in all the inflamed appendixes investigated (Table, Fig 2g).

Expression of NGAL mRNA in normal colon and appendicitis

NGAL mRNA was detected at a low level in crypts of four of 14 cases of histologically normal colonic epithelium from patients with inflammatory bowel disease or colorectal cancer, and in four of nine cases of normal appendix (Table). No differences regarding cellular infiltration were seen in the positive specimens compared with the negative ones. Scattered neutrophils present in normal colon were strongly positive by immunohistochemistry, but negative by in situ hybridisation. In addition, mast cells were positive by immunohistochemistry, but stained much weaker than neutrophils.

Control experiments

As negative controls in immunohistochemistry we used pre-immune rabbit IgG or absorbed antibodies (see Methods). No signal was seen showing that no unspecific binding of primary antibodies occurred and that endogenous peroxidase activity was blocked (Fig 1c). As a negative control for the in situ hybridisation, we applied the antisense and the sense probe on adjacent sections. The sense probe was always negative (Fig 1d).

Discussion

Induction of NGAL synthesis is a striking and consistent finding in epithelial cells in neoplastic and inflammatory disorders of colon and appendix, as shown by a very strong signal for NGAL by in situ hybridisation in most specimens of affected tissue (32 of 34 specimens), and furthermore by immunohistochemical staining of epithelial cells of colorectal cancers (all 14 cases investigated). The combined use of in situ hybridisation and immunohistochemistry and the identical staining pattern seen in epithelial cells provide evidence that the increased mRNA expression of NGAL in epithelial cells is actually accompanied by production of mature protein. Although we found an expression of mRNA for NGAL in epithelial cells in four of nine specimens of normal appendixes and in four of 13 sections of normal colon by in situ hybridisation, this expression was weak and mature protein could not be detected by immunohistochemistry.

As expected, neutrophils present in both normal and inflamed colon contain NGAL as shown by a strong immunohistochemical staining of these cells. No mRNA for NGAL was present in neutrophils, showing that mature neutrophils in the colonic mucosa do not actively synthesise NGAL despite the potential presence of inflammatory mediators like interferon γ and TNF α , which have been shown to induce the synthesis of a variety of proteins in mature neutrophils.³²⁻³⁴ This implies that NGAL, present in neutrophils in colonic mucosa, is synthesised in immature neutrophil precursors in the bone marrow,²³ where NGAL is packed in specific granules.³⁵ It is clear that the induction of NGAL synthesis in colon

Figure 1: NGAL protein and mRNA detected by immunohistochemistry and in situ hybridisation in neoplastic colorectal lesions. Immunohistochemical staining of an adenocarcinoma (a) shows NGAL expression in superficial cancer cells below the ulcer (large arrows in (a), ulcer marked by (u)). In addition, neutrophils present in the ulcer and in the stroma (small arrows) are strongly stained. The reactivity of the staining is specific as shown in (c), which shows lack of staining, when pre-immune rabbit antibodies were applied in an adjacent section to (a). Cancer cells below the ulcer were also strongly stained by mRNA in situ hybridisation (arrows in (b)). In addition, cancer cells in the transitional mucosa were positive (arrow in (e)). No in situ hybridisation signal is seen in adjacent normal (n) appearing epithelium in (e) and (f). Likewise, neutrophils present in the ulcer and in the stroma were negative. Appropriate controls for in situ hybridisation were negative as shown in (d), which shows lack of hybridisation with the sense probe in a section adjacent to (b). In adenoma (f), NGAL mRNA expression was only seen in epithelial cells on the luminal surface of the lesion (arrows). Magnifications: (a)–(d): $\times 40$, (e): $\times 10$, and (f): $\times 4$.

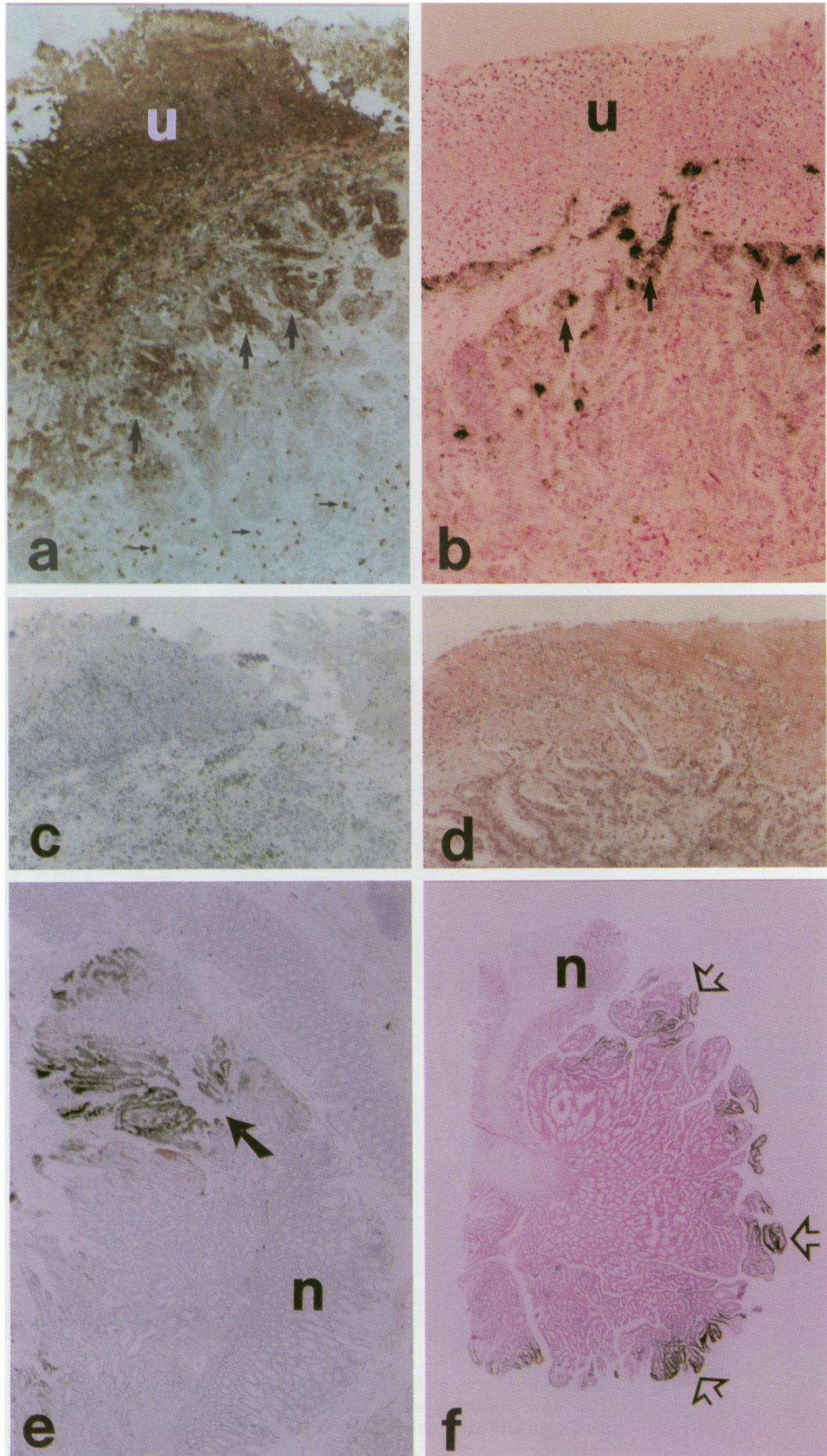
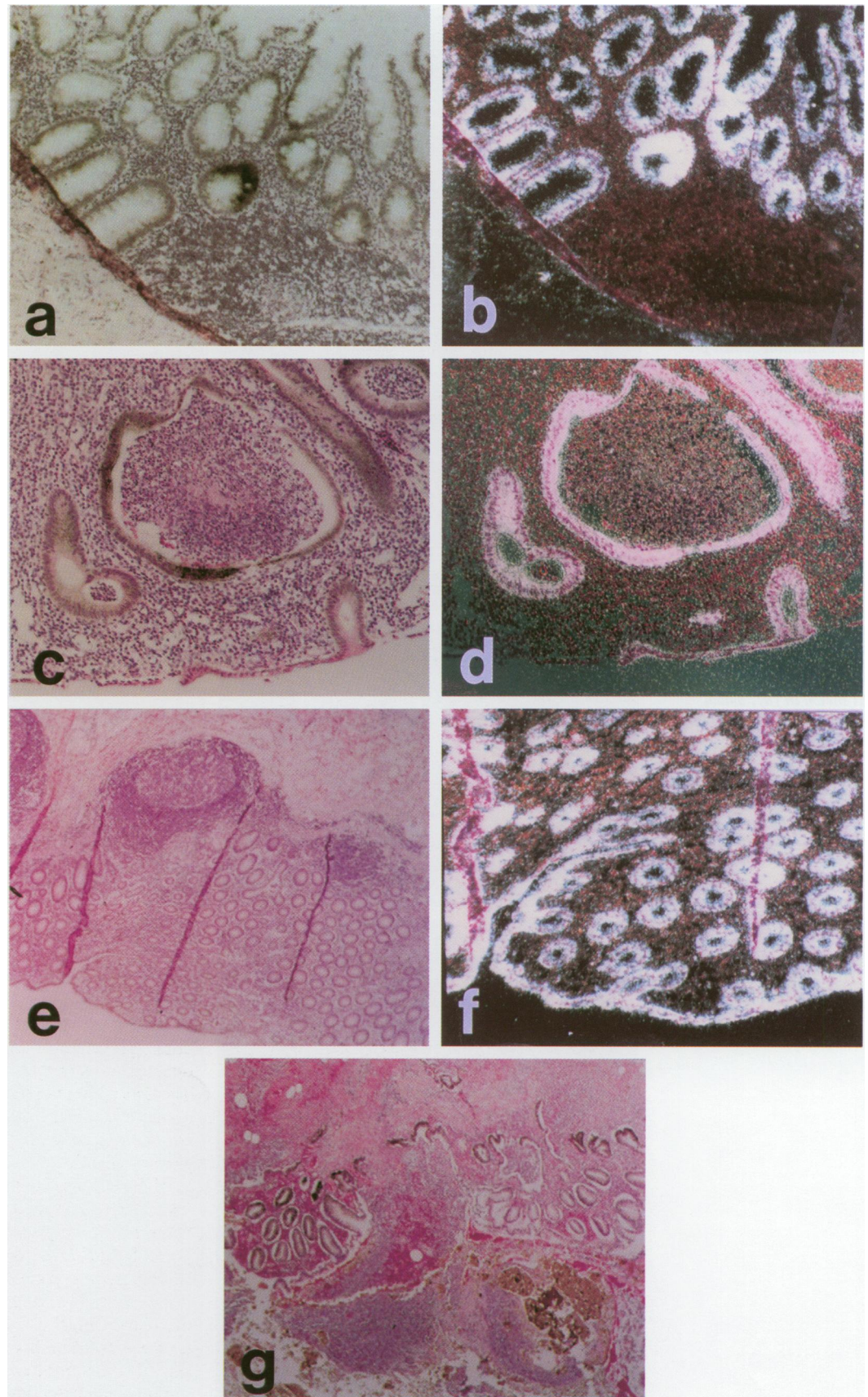


Figure 2: *In situ* hybridisation for NGAL mRNA in various inflammatory diseases of colon and appendix. Photomicrographs show diverticulitis ((a): bright field and (b): dark field), ulcerative colitis ((c): bright field and (d): dark field), Crohn's disease ((e): bright field and (f): dark field, magnification of lower left corner of (e), and appendicitis (g)). A strong signal for NGAL mRNA is seen in the epithelium of affected tissue. Note the characteristic crypt abscesses in the centre of the photomicrographs (c) and (d). Magnification: (a)–(d) and (f) $\times 200$, (e) and (g) $\times 40$.



epithelium is local, as it is seen in the affected tissue only. Furthermore, the induction is not specific for any particular colorectal disease but seems to be a response to inflammation in general, as inflammation is a common feature of inflammatory bowel disease, diverticulitis, appendicitis, and adenocarcinoma of the colon. The importance of the inflammatory response

for induction of NGAL synthesis is underscored by the fact, that no NGAL synthesis could be detected in lymph-node metastases from NGAL expressing primary tumours. This shows that the ability to synthesise NGAL is not part of the neoplastic process, but is induced as a result of the presence of inflammatory mediators liberated from the

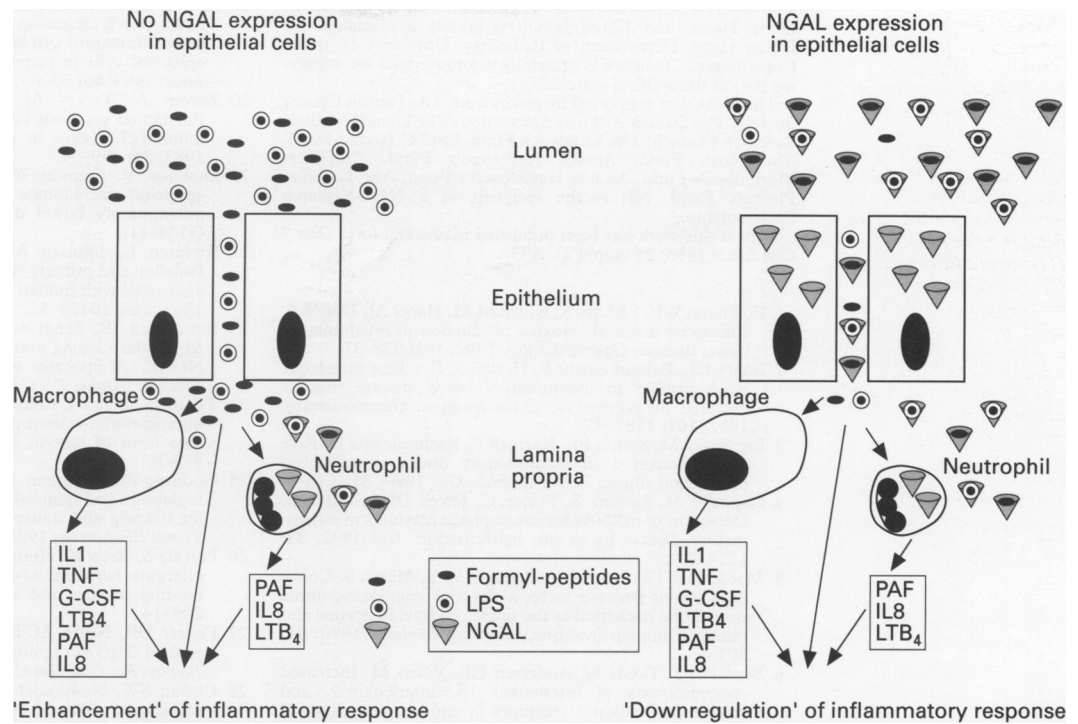


Figure 3: Schematic presentation of the putative function of NGAL expressed in epithelial cells during inflammation. To the left is shown two epithelial cells, where a defect barrier function permits the transepithelial passage of lipopolysaccharide and formyl-peptides from the lumen to the lamina propria. Lipopolysaccharide induces the synthesis in macrophages of TNF α and IL1, which in turn may lead to production of mediators like G-CSF, LTB $_4$, PAF, and IL 8.^{1 5 7-11} These mediators will, in concert with formyl-peptides, attract and activate neutrophils, which may result in augmented tissue damage. To the right are two epithelial cells that synthesise NGAL. NGAL is presumably liberated to the intestinal lumen where it binds lipopolysaccharide and formyl-peptides, thus preventing these substances from recruiting and activating macrophages and neutrophils. The NGAL production in epithelial cells may therefore downregulate the inflammatory response. Other cells participating in the inflammatory reaction are omitted for reasons of simplicity. Likewise, no neutrophils are shown on the luminal face of the epithelium, although NGAL liberated from these may act in conjunction with NGAL from epithelial cells in the binding of bacterial products.

local environment. The mechanisms underlying induction of NGAL synthesis are unknown, but the presence of NGAL in only the most superficial parts of adenomas and adenocarcinomas suggests that the initiating agents originate in the intestinal lumen. One candidate is lipopolysaccharide, which has been shown to induce the synthesis of the NGAL analogue 24p3 in cultured murine macrophages.³⁶

Many cytokines and inflammatory mediators that are induced in various inflammatory states of the colon (including IL1, TNF α , IL2, platelet activating factor, and G-CSF^{1-6 8}) are produced by 'traditional' inflammatory cells like lymphocytes, macrophages, and neutrophils, but several reports have shown that the epithelial cells also take part in the inflammatory reaction.^{13 19} An array of substances like MHC class II,¹⁴⁻¹⁶ ICAM-1,^{14 17} various proinflammatory cytokines,^{10 18 19} prostanoids,^{7 20} and 12-lipoxygenase²¹ are induced in colonic epithelial cells in response to inflammatory mediators like interferon γ , IL1, and TNF α . The induction of NGAL synthesis is the first description of induction of a lipocalin in colonic epithelial cells. This may represent a novel mechanism by which epithelial cells participate in the regulation of inflammatory processes as part of the mucosal defence. The functional significance of the observed 'neo-expression' of NGAL in inflamed colorectal epithelium is very intriguing. It has been shown that the transmigration of neutrophils across intestinal epithelial monolayers results in a reduction in the barrier function of

the epithelium, permitting the transepithelial passage of a variety of tracers.¹² As mentioned, NGAL binds a derivative of the bacterial chemotactic formyl-peptide FMLP,²⁹ and could therefore serve a function in the colonic epithelium as a scavenger of bacterial products that would otherwise traverse the epithelium and further recruit both macrophages and neutrophils (Fig 3). In this context it is interesting to note that CALLA (common acute lymphoblastic leukaemia antigen), a neutral endopeptidase, has also been shown to be induced in epithelial cells as a result of inflammation.³⁷ Neutral endopeptidase is known to hydrolyse a variety of physiologically active peptides including FMLP.³⁸ This shows that NGAL and neutral endopeptidase might act in concert to inactivate bacterial formyl-peptides. The passage of lipopolysaccharide over the epithelial lining is a well known stimulus for macrophages to produce IL1^{1 6} and TNF α ,⁴ which are central mediators in the inflammatory reaction. The binding by NGAL of lipopolysaccharide would therefore be an effective means of downregulating the inflammatory reaction (Fig 3).

We conclude that induction of NGAL synthesis is an important cellular response to inflammation in colon epithelium. The faecal content of NGAL may therefore prove to be a useful marker for disease activity in inflammatory bowel disease. The structure of NGAL together with its presence in a broad variety of large bowel diseases strongly supports its role as a modulator of the inflammatory response.

The expert technical assistance of Charlotte Horn, Pia L Olsen, Dorte Holm, and Karen Jensen is greatly appreciated. Dr Esther Hage, Department of Pathology, University Hospital, Copenhagen, Denmark is gratefully acknowledged for supplying part of the archival material.

This work was supported by grants from The Danish Cancer Society, The Danish Arthritis Association, The Danish Medical Research Council, The Lundbeck Fund, Emil C Hertz's Fund, The Novo Fund, Amalie Jørgensen's Fund, Brøchner-Mortensen's Fund, Anders Hasselbach's Fund, Ane Kathrine Plesners Fund. NB is the recipient of a Neye-Research Professorship.

Part of this work has been published in abstract form (*Eur J Clin Invest* 1995; 25 (suppl 2): A33).

- Pullmann WE, Elsbury S, Kobatani M, Hapel AJ, Doe WF. Enhanced mucosal cytokine production in inflammatory bowel disease. *Gastroenterology* 1992; 102: 529-37.
- Isaacs KL, Balfour Sartor R, Haskill S. Cytokine messenger RNA profiles in inflammatory bowel disease mucosa detected by polymerase chain reaction. *Gastroenterology* 1992; 103: 1587-95.
- Ligumsky M, Simon PL, Karmeli F, Rachmilewitz D. Role of interleukin 1 in inflammatory disease - enhanced production during active disease. *Gut* 1990; 31: 686-9.
- Cappello M, Keshav S, Prince C, Jewell DP, Gordon S. Detection of mRNAs for macrophage products in inflammatory disease by in situ hybridisation. *Gut* 1992; 33: 1214-9.
- Macdonald TT, Hutchings P, Choy M-Y, Murch S, Cooke A. Tumour necrosis factor-alpha and interferon-gamma production measured at the single cell level in normal and inflamed human intestine. *Clin Exp Immunol* 1990; 81: 301-5.
- Brynskov J, Tvede N, Andersen CB, Vilien M. Increased concentrations of interleukin 1 β , interleukin-2, and soluble interleukin-2 receptors in endoscopic mucosal biopsy specimens with active inflammatory bowel disease. *Gut* 1992; 33: 55-8.
- Lauritsen K, Laursen LS, Bukhave K, Rask-Madsen J. In vivo profiles of eicosanoids in ulcerative colitis, Crohn's disease and Clostridium difficile colitis. *Gastroenterology* 1988; 95: 11-7.
- Eliakim R, Karmeli F, Razin E, Rachmilewitz D. Role of platelet-activating factor in ulcerative colitis. *Gastroenterology* 1988; 95: 1167-72.
- Sharon P, Stenson WF. Enhanced synthesis of leukotriene B₄ by colonic mucosa in inflammatory bowel disease. *Gastroenterology* 1984; 86: 453-60.
- Mazzucchelli L, Hauser C, Zraggen K, Wagner H, Hess M, Laissue JA, et al. Expression of interleukin-8 gene in inflammatory bowel disease is related to the histological grade of active inflammation. *Am J Pathol* 1994; 144: 997-1007.
- Thornton AJ, Streiter RM, Lindley I, Baggiolini M, Kunkel SL. Cytokine-induced gene expression of a neutrophil chemotactic factor/IL-8 in human hepatocytes. *J Immunol* 1990; 144: 2609-13.
- Nash S, Stafford J, Madara JL. Effects of polymorphonuclear leukocyte transmigration on the barrier function of cultured intestinal epithelial monolayers. *J Clin Invest* 1987; 80: 1104-13.
- Perdue MH, McKay DM. Integrative immunophysiology in the intestinal mucosa. *Am J Pathol* 1994; 267: G151-65.
- Das KM, Squillante L, Robertson FM. Amplified expression of intercellular adhesion molecule-1 (ICAM-1) and M₁ 40K protein by DLD-1 colon tumor cells by interferon-gamma. *Cell Immunol* 1993; 147: 215-21.
- Bland P. MHC class II expression by the gut epithelium. *Immunol Today* 1988; 9: 174-8.
- Kvale D, Brandtzaeg P, Løvhaug D. Up-regulation of the expression of secretory component and HLA molecules in a human colonic cell line by tumour necrosis factor- α and gamma interferon. *Scand J Immunol* 1988; 28: 351-7.
- Kelly CP, O'Keane JC, Orellana J, Schroy PC, III, Yang S, LaMont JT, et al. Human colon cancer cells express ICAM-1 in vivo and support LFA-1-dependent lymphocyte adhesion in vitro. *Am J Pathol* 1992; 263: G864-70.
- Lammers KM, Jansen J, Bijlsma PB, Ceska M, Tytgat GNJ, Laboisse CL, et al. Polarised interleukin-8 secretion by HT-29/19A cells. *Gut* 1994; 35: 338-42.
- Jung HC, Eckmann L, Yang S-K, Panja A, Fierer J, Morzycka-Wroblewska E, et al. A distinct array of proinflammatory cytokines is expressed in human colon epithelial cells in response to bacterial invasion. *J Clin Invest* 1995; 95: 55-65.
- Zifroni A, Treves AJ, Sachar DB, Rachmilewitz D. Prostanoid synthesis by cultured intestinal epithelial and mononuclear cells in inflammatory bowel disease. *Gut* 1983; 24: 659-64.
- Shannon V, Stenson WF, Holtzman MJ. Induction of epithelial arachidonate 12-lipoxygenase at active sites of inflammatory bowel disease. *Am J Pathol* 1993; 264: G104-11.
- Kjeldsen L, Johnsen AH, Sengeløv H, Borregaard N. Isolation and primary structure of NGAL, a novel protein associated with human neutrophil gelatinase. *J Biol Chem* 1993; 268: 10425-32.
- Bundgaard JR, Sengeløv H, Borregaard N, Kjeldsen L. Molecular cloning and expression of a cDNA encoding NGAL. A lipocalin expressed in human neutrophils. *Biochem Biophys Res Commun* 1994; 202: 1468-75.
- Triebel S, Bläser J, Reinke H, Tschesche H. A 25 kDa α_2 -microglobulin-related protein is a component of the 125 kDa form of human gelatinase. *FEBS Lett* 1992; 314: 386-8.
- Godovac-Zimmermann J. The structural motif of β -lactoglobulin and retinol-binding protein: a basic framework for binding and transport of small lipophilic molecules? *Trends Biochem Sci* 1988; 13: 64-6.
- Pervaiz S, Brew K. Homology and structure-function correlations between α_1 -glycoprotein and serum retinol-binding protein and its relatives. *FASEB J* 1987; 1: 209-14.
- Flower DR, North ACT, Attwood TK. Mouse oncogene protein 24p3 is member of the lipocalin family. *Biochem Biophys Res Commun* 1991; 180: 69-74.
- Cowan SW, Newcomer ME, Jones TA. Crystallographic refinement of human serum retinol binding protein at 2Å resolution. *Proteins: Structure Function and Genetics* 1990; 8: 44-61.
- Sengeløv H, Boulay F, Kjeldsen L, Borregaard N. Subcellular localization and translocation of the receptor for N-formyl-methionyl-leucyl-phenylalanine in human neutrophils. *Biochem J* 1994; 299: 473-9.
- Urieli-Shoval S, Meek RL, Hanson RH, Ferguson M, Gordon D, Benditt EP. Preservation of RNA for in situ hybridization: Carnoy's versus formaldehyde fixation. *J Histochem Cytochem* 1992; 40: 1879-85.
- Pyke C, Kristensen P, Ralfkiær E, Grøndahl-Hansen J, Eriksen J, Blasi F, et al. Urokinase-type plasminogen activator is expressed in stromal cells and its receptor in cancer cells at invasive foci in human colon adenocarcinomas. *Am J Pathol* 1991; 138: 1059-67.
- Beaulieu AD, Paquin R, Rathanaswami P, Mccoll SR. Nuclear signaling in human neutrophils. Stimulation of RNA synthesis is a response to a limited number of proinflammatory agonists. *J Biol Chem* 1992; 267: 426-32.
- Botto M, Lissandrini D, Sorio C, Walport M. Biosynthesis and secretion of complement component (C3) by activated human polymorphonuclear leukocytes. *J Immunol* 1992; 149: 1348-55.
- Cicco NA, Lindemann A, Content J, Vandenbussche P, Lübbert M, Gauss J, et al. Inducible production of interleukin-6 by human polymorphonuclear neutrophils: role of granulocyte-macrophage colony-stimulating factor and tumor necrosis factor-alpha. *Blood* 1990; 75: 2049-52.
- Kjeldsen L, Bainton DF, Sengeløv H, Borregaard N. Identification of neutrophil gelatinase-associated lipocalin as a novel matrix protein of specific granules in human neutrophils. *Blood* 1994; 83: 799-807.
- Meheus LA, Fransen LM, Raymackers JG, Blockx HA, van Beeumen JJ, van Bun SM, et al. Identification by microsequencing of lipopolysaccharide-induced proteins secreted by mouse macrophages. *J Immunol* 1993; 151: 1535-47.
- Fais S, Pallone F. Ability of human colonic epithelium to express the 4F2 antigen, the common acute lymphoblastic leukemia antigen, and the transferrin receptor. Studies in inflammatory bowel disease and after in vitro exposure to different stimuli. *Gastroenterology* 1989; 97: 1435-41.
- Shipp MA, Look AT. Hematopoietic differentiation antigens that are membrane-associated enzymes: cutting is the key. *Blood* 1993; 82: 1052-70.