

## CASE REPORTS

## Granulomatous hepatitis caused by *Bacillus Calmette-Guerin* (BCG) infection after BCG bladder instillation

F W G Leebeek, R J Th Ouwendijk, A H J Kolk, A Dees, J Ch E Meek, J E Nienhuis, A M Dingemans-Dumas

### Abstract

**Background**—Bladder instillations with *Bacillus Calmette-Guerin* (BCG) are commonly used as immunotherapy for bladder carcinoma. Sometimes patients experience serious systemic side effects, such as sepsis or pneumonitis. Granulomatous hepatitis is a rare serious side effect, which has been considered a hypersensitivity reaction to BCG.

**Patient**—The first case of granulomatous hepatitis after BCG bladder instillation in which mycobacteria were identified by staining techniques and mycobacterial DNA was detected in liver tissue using the polymerase chain reaction is reported.

**Conclusion**—The granulomatous hepatitis was caused by BCG infection of the liver after haematogenous dissemination of BCG, rather than hypersensitivity.

(Gut 1996; 38: 616-618)

Keywords: *Bacillus Calmette-Guerin*, bladder carcinoma, granulomatous hepatitis, mycobacterium.

Bladder instillations with *Bacillus Calmette-Guerin* (BCG), a viable attenuated strain of *Mycobacterium bovis*, are widely used as non-specific immunotherapy in the treatment of bladder carcinoma.<sup>1,2</sup> The mechanism by which BCG exerts its antitumour activity is unknown, but it has been suggested that a non-specific immune response to BCG might also destroy tumour cells.<sup>3</sup> Another suggested mechanism is that the severe inflammation caused by BCG leads to local ischaemia, thereby killing tumour cells.<sup>4</sup> BCG instillation of the bladder is highly efficacious, with a success rate varying between 63 and 100%.<sup>1</sup> Bladder instillations are frequently accompanied by local side effects, such as prostatitis and haematuria.<sup>2</sup> Often patients experience high grade fever after bladder instillations, which resolves in a few days. Systemic side effects, such as sepsis, pneumonitis, and hepatitis, which are usually only seen after traumatic catheterisation, are more serious. Sepsis is the most serious complication and may be associated with shock, disseminated intravascular coagulation or multiple organ failure. These systemic complications are life threaten-

ing, and so far at least seven patients have died because of systemic BCG infection after BCG immunotherapy.<sup>2</sup>

We report on a patient with a granulomatous hepatitis as a major side effect of BCG bladder instillation.

### Methods

Blood, urine, and bone marrow specimens, as well as homogenised liver tissue obtained by biopsy were tested for the presence of BCG DNA using the polymerase chain reaction (PCR).<sup>5,6</sup> The clinical samples were pretreated as described.

### Treatment of urine

Urine (100 ml) was centrifuged at 5000×g for 30 minutes, and 100 µl of the DNA in the pellet was extracted and purified by the addition of 900 µl of lysis buffer containing approximately 5 M guanidine thiocyanate, 1% Triton X-100, 50 mM TRIS-HCl (pH 6.4, and 20 mM EDTA (L6 lysis buffer<sup>7</sup>). DNA was purified according to the thiocyanate method using 20 µl diatoms.<sup>5,7</sup> The diatoms to which the DNA was bound were washed twice with 'L2 washing buffer', twice with 70% ethanol, and once with acetone. After the diatoms were dried the DNA was eluted in two steps with 60 and 40 µl TE buffer (10 mM TRIS-HCl (pH 8.3), 1 mM EDTA).

### Treatment of liver biopsy material for PCR

The liver biopsy specimen was incubated for one hour at 60°C in 0.1 mg/ml proteinase K, 0.5% Triton X-100, and 20 mM TRIS-HCl (pH 8.3). The biopsy material was further disrupted by adding 900 µl L6 lysis buffer. The mixture was shaken in a mechanical disruptor (MiniBeadBeater model 3110, Biospec Products, Bartlesville, OK) for three minutes. Afterwards DNA was purified according to the guanidinium thiocyanate method.<sup>7</sup>

### Treatment of blood and bone marrow

These samples were treated as previously described.<sup>6</sup> EDTA blood or bone marrow

Departments of  
Internal Medicine  
F W G Leebeek  
R J Th Ouwendijk  
A Dees

Pulmonary Diseases  
J Ch E Meek

Urology  
J E Nienhuis

and Microbiology  
A M Dingemans-Dumas

Ikazia Hospital  
Rotterdam, the  
Netherlands

Royal Tropical  
Institute, Amsterdam,  
the Netherlands  
A H J Kolk

Correspondence to:  
Dr F W G Leebeek,  
Department of Internal  
Medicine II, Dr  
Molewaterplein 40, 3015  
GD Rotterdam, the  
Netherlands.

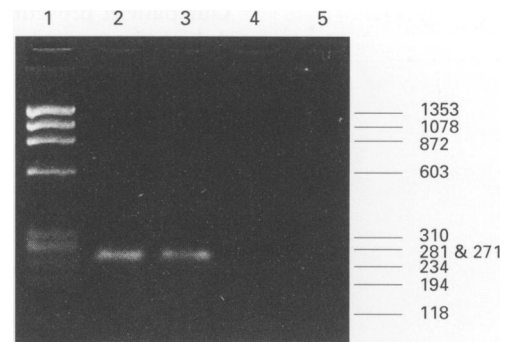
Accepted for publication  
9 October 1995

(500  $\mu$ l) was mixed with 250  $\mu$ l TE buffer (1 mg/ml proteinase K, 5% Triton X-100, and 200 mM TRIS-HCl (pH 8.3)) for 18 hours at 60°C. DNA was isolated from the digest by phenol-chloroform extraction. A volume of 900  $\mu$ l phenol (saturated with 100 mM TRIS-HCl (pH 8.3)) was added. After shaking on a gyratory shaker at 100 rpm the mixture was centrifuged for 10 minutes at 12 000 $\times$ g and the aqueous phase was collected and to this one volume phenol:chloroform was added. The aqueous phase was collected again and an equal volume of chloroform was added. The aqueous phase was collected again after a further shaking and centrifugation step. DNA was precipitated by the addition of 0.05 volume 5 M NaCl and two volumes of cold 100% ethanol and incubated for at least one hour at -20°C, and then centrifuged at 12 000 $\times$ g for 20 minutes. The pellet was washed with 1 ml -20°C 70% ethanol. The pellet was then dried and dissolved in 100  $\mu$ l TE buffer.

PCR was performed using two oligonucleotide primers within the IS6110 insertion element. This element is specific for the *Mycobacterium tuberculosis* group of bacteria including *Myco bovis* BCG.<sup>8</sup> The PCR was based on the amplification of a 245 base pair fragment within the insertion element. Routine cultures for *Myco bovis* BCG were performed using Löwenstein-Jensen media.

### Case report

A 69 year old man presented with fever (39.5°C) and haematuria six hours after a BCG bladder instillation. A transitional cell carcinoma of the bladder was diagnosed three years earlier. The patient had previously undergone two trans-urethral resections and 12 BCG instillations without any complication. The recent catheterisation had been difficult and painful. The patient was sick and pale on examination. Pulmonary examination was unremarkable. The liver was slightly enlarged and painful on palpation. Laboratory investigations were normal with the exception of an anaemia, a mild renal insufficiency, and shifting to the left of the leucocyte differential. Intravenous treatment with ampicillin and gentamycin was started. His clinical condition deteriorated and fever remained high. No bacteria grew from routine urine and blood cultures. A systemic BCG infection was suspected on the basis of the recent BCG instillation and the failure to improve despite several days of antibiotic treatment. Therefore treatment with isoniazid and rifampicin was started seven days after BCG instillation. Liver function abnormalities were first apparent four days after starting tuberculostatic drugs: serum aspartate aminotransferase 43 U/l (n<25), serum alanine aminotransferase 65 U/l (n<30), lactate dehydrogenase 591 U/l (n=160-340), alkaline phosphatase 143 U/l (n=20-120),  $\gamma$ -glutamyltransferase 405 U/l (n<40), and bilirubin 16  $\mu$ mol/l (n<16). A liver biopsy was performed 14 days after BCG bladder instillation, to discriminate between a drug induced



*Analysis of PCR products by agarose gel electrophoresis. PCR was based on the amplification of a 245 base pair fragment of the insertion element IS6110 of Myco tuberculosis. The PCR incubations were as follows: five minutes at 40°C to allow breakdown of amplicons by uracil DNA glycosylase, followed by 40 cycles of 1.5 minutes of denaturation at 94°C, and three minutes of primer extension at 72°C. DNA was isolated from the clinical samples as previously described by Kox et al.<sup>6</sup> Numbers at the right show the sizes of the DNA fragments (in base pairs) of the HaeIII-digested  $\Phi$ X174. Lane 1: HaeIII  $\Phi$ X174 DNA molecular size marker. Lanes 2 to 5: liver biopsy, urine, blood, and bone marrow from the patient respectively.*

hepatitis and an infective hepatitis. Histological examination showed several non-caseating epithelioid granulomas. No acid-fast bacilli were seen with Ziehl-Neelsen staining, but fluorescence staining with auramine showed some acid-fast bacilli. The PCR performed on homogenised liver tissue was positive for mycobacterial DNA (>150 *Myco bovis* BCG per 15 mg biopsy) (Figure). PCR on urine, taken 14 days after bladder instillation, was also positive (estimated 10 *Myco bovis* per ml). Blood and bone marrow taken at the same time were PCR negative (Figure). A systemic BCG infection causing granulomatous hepatitis was diagnosed and streptomycin and corticosteroids were added to isoniazid and rifampicin. The clinical condition of the patient gradually improved. Fever subsided after three weeks of treatment. Tuberculostatic drugs were continued for six months. Routine cultures of urine, blood, bone marrow, and liver for *Myco bovis* BCG using Löwenstein-Jensen media remained negative. PCR on urine performed one month after treatment was started was negative. Currently the patient is in a good clinical condition and the liver function tests are normal.

### Discussion

BCG related hepatitis is a rare complication after BCG instillation. In a review of 2602 patients undergoing BCG bladder instillation, Lamm *et al* reported 18 patients (0.7%) with pneumonitis or hepatitis, or both.<sup>2</sup> Only a few cases of BCG hepatitis have been reported elsewhere.<sup>9-14</sup> The pathogenesis of the granulomatous hepatitis is unclear. Most authors suggest that granulomatous hepatitis is caused by a hypersensitivity reaction to BCG, based on negative Ziehl-Neelsen staining and negative cultures of liver tissue.<sup>2,9-13</sup> In one patient with an overwhelming sepsis after bladder instillation, acid-fast bacilli were seen in the liver on Ziehl-Neelsen staining, suggesting a systemic BCG infection.<sup>14</sup>

Our patient presented early after instillation with high fever and haematuria. This is probably caused by a traumatic catheterisation, thereby enabling the intravesical mycobacteria to enter the circulation leading to bacteraemia or sepsis. Liver function abnormalities were noted after a few days, caused by a granulomatous hepatitis, as diagnosed on liver biopsy. Ziehl-Neelsen staining was negative, but a few mycobacteria were seen on auramine fluorescence staining of the liver biopsy specimen. Because of the importance of distinguishing between a hypersensitivity reaction and infection for treatment of our patient, we used a recently developed PCR to assess mycobacterial DNA. This quantitative PCR was performed using two oligonucleotide primers within the IS6110 insertion sequence. This element is specific for the *Mycobacterium tuberculosis* complex of bacteria including *Mycobacterium bovis* BCG.<sup>8</sup> The PCR proved the presence of DNA from *Mycobacterium bovis* BCG in the patient's liver tissue. The rapidity with which an accurate result is obtained with PCR is especially important because Ziehl-Neelsen staining for mycobacteria is frequently negative, as in our case. Furthermore, the results of cultures for *Mycobacterium bovis* BCG, which are also frequently negative in this situation, only become available after six to eight weeks.<sup>2,9-13</sup>

Granulomatous hepatitis after BCG immunotherapy has been considered a hypersensitivity reaction, so treatment with corticosteroids alone has been given in the past.<sup>13</sup> Our report shows that BCG infection of the liver does occur and therefore corticosteroids should never be given in these cases as sole treatment. A consensus treatment schedule for treating BCG related complications has been proposed by Lamm *et al.*<sup>2</sup> They suggest the use of three tuberculostatic drugs for severe systemic side effects. In granulomatous hepatitis caused by BCG infection, treatment should consist of isoniazid (300 mg daily) and rifampicin (600 mg daily). In acutely ill patients it has been advised to combine this with ethambutol (1200 mg daily). This treatment should be continued for six months. In view of the good survival rates in several reports where tuberculostatic drugs were combined with corticosteroids, it is recommended that 40 mg of prednisolone daily is added.<sup>2</sup>

Our finding that the systemic side effects of BCG bladder instillations are caused by BCG infection rather than hypersensitivity has also been shown in patients suffering from pneumonitis after BCG bladder instillation. In one patient described by McParland *et al* the culture of a lung biopsy specimen was positive for *Mycobacterium bovis* BCG.<sup>15</sup> Another study in two patients with pneumonitis after BCG bladder instillation confirmed *Mycobacterium bovis* BCG DNA

in the clinical isolates from the patients using pulsed field gel electrophoresis.<sup>16</sup> Ziehl-Neelsen staining of most of the clinical samples were negative, showing the importance of DNA techniques.

In this report a case of BCG induced granulomatous hepatitis complicating BCG bladder instillation for bladder carcinoma is presented. It is the first case in which proof of the presence of *Mycobacterium bovis* BCG in liver tissue has been obtained using PCR. We therefore conclude that the granulomatous hepatitis was caused by BCG infection of the liver after haematogenous dissemination of BCG after bladder instillation rather than hypersensitivity.

- 1 Witjes JA, van der Meijden APM, Debruyne FMJ. Use of intravesical Bacillus Calmette-Guerin in the treatment of superficial transitional cell carcinoma of the bladder: an overview. *Urol Int* 1990; 45: 129-36.
- 2 Lamm DL, van der Meijden APM, Morales A, Brosman SA, Catalona WJ, Herr HW, *et al.* Incidence and treatment of complications of Bacillus Calmette Guerin intravesical therapy in superficial bladder cancer. *J Urol* 1992; 147: 596-600.
- 3 Lamm DL. BCG immunotherapy in bladder cancer. In: Rouse SN, ed. *Urology annual*. Los Altos: Norwalk, Appleton & Lange, 1987: 67-80.
- 4 Witjes JA, van der Meijden APM, DeBruyne FMJ. Use of intravesical Bacillus Calmette-Guerin in the treatment of superficial transitional cell carcinoma of the bladder: an overview. *Urol Int* 1990; 45: 129-36.
- 5 Kolk AHJ, Schuitema ARJ, Kuiper S, van Leeuwen J, Hermans PWM, van Embden JDA, *et al.* Detection of Mycobacterium tuberculosis in clinical samples using polymerase chain reaction and a nonradioactive detection system. *J Clin Microbiol* 1992; 30: 2567-75.
- 6 Kox LFF, Rhienthong D, Medo Miranda A, Udomsantisuk N, Ellis K, van Leeuwen J, *et al.* A more reliable PCR for detection of Mycobacterium tuberculosis in clinical samples. *J Clin Microbiol* 1994; 32: 672-8.
- 7 Boom R, Sol CJA, Salimans MMM, Jansen CL, Wertheim van Dillen PME, van der Noordaa J. Rapid and simple method for purification of nucleic acids. *J Clin Microbiol* 1990; 28: 495-503.
- 8 Kolk AHJ, Noordhoek GT, de Leeuw O, Kuijper S, van Embden JDA. Mycobacterium smegmatis strain for the detection of Mycobacterium tuberculosis by PCR used as internal control for inhibition of amplification and for quantitation of bacteria. *J Clin Microbiol* 1994; 32: 1354-6.
- 9 Marans HY, Bekirov HM. Granulomatous hepatitis following intravesical Bacillus Calmette-Guerin therapy for bladder carcinoma. *J Urol* 1987; 137: 111-2.
- 10 Steg A, Leleu C, Debre B, Boccon-Gibod L, Sicard D. Systemic Bacillus Calmette-Guerin infection, BCG-itis, in patients treated by intravesical Bacillus Calmette-Guerin therapy for bladder cancer. *Eur Urol* 1989; 16: 161-4.
- 11 Thompson D, Cumming J. Granulomatous hepatitis following intravesical BCG therapy. *Br J Urol* 1990; 66: 432-3.
- 12 Graziani DA, Jacobs D, Lozano RG, Buck RL. A case of granulomatous hepatitis after intravesical Bacillus-Calmette Guerin administration. *J Urol* 1991; 146: 118-9.
- 13 Molina JM, Rabian C, D'Agay MF, Modai J. Hypersensitivity systemic reaction following intravesical Bacillus Calmette Guerin: successful treatment with steroids. *J Urol* 1992; 147: 695-7.
- 14 Proctor DD, Chopra S, Rubenstein SC, Jokela JA, Uhl L. Mycobacteremia and granulomatous hepatitis following initial intravesical Bacillus Calmette Guerin instillation for bladder carcinoma. *Am J Gastroenterol* 1993; 88: 1112-5.
- 15 McParland C, Cotton DJ, Gowda KS, Hoepfner VH, Martin WT, Weckworth PF. Miliary Mycobacterium bovis induced by the intravesical Bacillus Calmette Guerin immunotherapy. *Am Rev Respir Dis* 1992; 146: 1330-3.
- 16 Kristjansson M, Green P, Manning HL, Slutsky AM, Brecher SM, von Reyn CF, *et al.* Molecular confirmation of Bacillus Calmette Guerin as the cause of pulmonary infection following urinary tract instillation. *Clin Infect Dis* 1993; 17: 228-30.