Gut 1996; **39:** 870–875

Liver transplantation for haemophiliacs with hepatitis C cirrhosis

M McCarthy, E Gane, S Pereira, C J Tibbs, N Heaton, M Rela, H Hambley, Roger Williams

Abstract

***Background*—Experience of liver transplantation in haemophiliacs with end stage hepatitis C liver disease is limited and particularly difficult questions are raised when there is also HIV infection.**

***Aims*—This is the first report in Great Britain to describe the operative replacement therapy and initial outcome in four haemophiliacs with end stage HCV cirrhosis.**

***Patients*—Two patients had factor VIII, one had factor IX, and one had factor X deficiency. One patient had also contracted HIV infection from factor replacement but had no AIDS defining illnesses.**

***Methods*—Intraoperatively patients were given either factor VIII infusions, factor IX bolus, or fresh frozen plasma, according to formulae devised to calculate exact clotting factor requirements. Baseline preoperative coagulation studies included prothrombin time, activated partial thromboplastin time, fibrinogen concentrations, and factor VIII, IX, and X concentrations. Factor concentrations were then assayed at 12, 24, 48, and 72 hours postoperatively.**

***Results*—Postoperatively all patients had coagulation factor concentrations sustained within the normal ranges by 72 hours unsupported (137, 125, 95, 104 IU/dl), representing de novo synthesis by the graft. Transfusion requirements during the operative and immediate post-transplant period were no greater than those of patients without clotting disorders. Two patients had episodes of bleeding postoperatively, one of which was fatal, occurring at the site of a previous untreated subdural bleed. In both instances the bleeding occurred in the presence of normal concentrations of clotting factor. The remaining three patients are at 6, 6, and 12 months post-transplant and remarkably improved clinically with sustained factor concentrations. One patient has evidence of graft dysfunction from HCV recurrence and all have evidence of recurrent viraemia with HCV on polymerase chain reaction studies.**

***Conclusions*—Orthotopic liver transplantation should be considered in haemophiliac patients with end stage liver disease from hepatitis C infection with or without concomitant HIV infection. Their clinical condition is likely to be greatly improved by orthotopic liver transplantation and the haemophilia cured with only a small risk of severe graft dysfunction from recurrent HCV infection.**

(*Gut* 1996; **39:** 870–875)

Keywords: liver transplantation, haemophilia, hepatitis C virus, cirrhosis.

Institute of Liver Studies
M McCarthy
E Gane
S Pereira
C J Tibbs
R Williams

Liver Transplant Surgical Service
N Heaton
M Rela

Department of Haematology
H Hambley

King's College Hospital, London

Correspondence to: Professor Roger Williams, CBE, Institute of Liver Studies, King's College Hospital, Denmark Hill, London SE5 9RS, UK.

Accepted for publication 8 July 1996

Infection with hepatitis C virus (HCV) was virtually universal in haemophiliacs who received repeated pooled clotting factor concentrates until the introduction of more effective methods of viral inactivation (heat treatment in 1985, solvent detergent method in 1987) primarily designed to reduce the risk of HIV infection. Of the estimated 3200 haemophiliacs in the United Kingdom infected with HCV,[1] many are also coinfected with HIV. Two recent reports suggest that HIV seropositivity in this group may be as high as 40–60%.[2 3] The estimated cumulative risk of developing hepatic decompensation in haemophiliacs with HCV infection is 1·7% at 10 years and 19·8% at 20 years after first exposure to the virus.[3] However, data from Eysher *et al*[2] showed that HCV infection can have a more aggressive course in those coinfected with HIV, with the incidence of liver failure increasing to 17% at 10 years. Risks of hepatic decompensation were greater with a more rapid decline in the CD4 count and the development of p24 antigenaemia, correlating with higher levels of viraemia. At the present time, only a minority of haemophiliacs in the United Kingdom have developed cirrhosis; however, it is likely that, over the next 5–10 years, even with the use of interferon, a sizeable number of these patients will progress to end stage liver disease and meet the requirements for orthotopic liver transplantation. After early animal studies in 1974 by Webster and colleagues, dogs with haemophilia B (factor IX deficiency) were transplanted, and these experiments showed that normal clotting function could be achieved post-transplantation.[4] To date, there have been seven reports of haemophiliacs being transplanted for end stage liver disease. Starzl's group reported the first two successful cases of transplantation in two patients with haemophilia and chronic liver disease between 1982 and 1985. This was followed by several reports of patients with both factor VIII and IX deficiency being given transplants.[5–9] These earlier cases of transplantation for chronic liver disease were

secondary to chronic hepatitis B infection as well as a non-A non-B hepatitis although not isolated as hepatitis C antibody positive at the time. Causes of death in these earlier cases included intraoperative bleeding and systemic sepsis. Despite the obvious benefits of correction of clotting disorder after liver transplantation, significant concerns have been expressed, including the risks of bleeding during transplantation, the frequent concomitant HIV infection, and the likely probability of recurrent HCV infection within the graft. We report here the clinical course and outcome of orthotopic liver transplantation in four haemophiliacs with end stage HCV cirrhosis, one of whom was HIV antibody positive, together with the unique factor replacement schedules used during and after surgery.

Methods

Between June 1994 and April 1995, four men, aged between 27 and 54 years and with haemophilia, underwent orthotopic liver transplantation. Of these, two had factor VIIIC deficiency (haemophilia A), one had factor IX deficiency (haemophilia B or Christmas disease), and one had mild factor X deficiency. No patient had a plasma inhibitor detected on routine coagulation studies. All four patients had decompensated end stage liver disease secondary to HCV infection, with positive HCV antibody and HCV RNA, the infection having been acquired through contaminated clotting factor infusions given before 1985. Patient 3 was known to be HIV antibody positive at the time of his transplantation, but had remained asymptomatic from his HIV disease and in particular, had had no AIDS defining illnesses since his diagnosis.

CLOTTING FACTOR REPLACEMENT SCHEDULE

Baseline preoperative coagulation studies consisted of prothrombin time (PT), activated partial thromboplastin time (APTT), fibrinogen concentrations, and factor VIII, IX, or X concentrations, and screening for inhibitor to coagulation factor. Factor concentrations were then assayed at 12, 24, 48, and 72 hours postoperatively. For patients 1 and 3 with factor VIIIC deficiency, an initial preoperative intravenous bolus of factor VIII was given. The required amount in international units (IU) was calculated by the equation:

$$\frac{(100\text{–baseline value})\times\text{body weight (kg)}}{2}$$

This was followed by an intraoperative infusion at a rate of 2 IU/kg/h. Postoperatively this was decreased to 1 IU/kg/h when the International Normalised Ratio (INR) was less than 2·2 and ceased altogether at an INR less than 1·5. The INR was used as a marker for recovery of hepatic function and synthesis of clotting factors, rather than as a direct marker of factor VIII concentration. Factor VIII infusion was given via a central venous access to avoid peripheral vein thrombophlebitis.

For patient 4, with factor IX deficiency, an initial preoperative intravenous bolus of factor IX was given with the required amount in IU being calculated by the equation:

$$(100\text{–baseline value})\times\text{body weight (kg)}$$

This was supplemented by intermittent intravenous boluses intraoperatively as required. At 12 hours, if factor IX concentration was less than 30 IU then a 50 IU/kg bolus was given, if the concentration was greater than 30 IU but less than 50 IU then 25 IU/kg was given; once the concentration was greater than 50 IU no further supplement was required.

For patient 2, with mild factor X deficiency, the standard intraoperative transfusion regime for orthotopic liver transplantation was used, with fresh frozen plasma and platelets given as required. Four further units of fresh frozen plasma were given postoperatively to supplement factor X concentration and to keep the INR less than 1·5.

SURGICAL TECHNIQUE

With the exception of patient 3, the standard orthotopic liver transplantation procedure with the use of venovenous bypass was performed. Patient 3 was younger and had normal renal function, allowing him to tolerate caval clamping more easily than the other patients. A further reason to avoid the use of bypass in this case was to limit the potential exposure of infective HIV blood products to the theatre staff. Techniques employed to minimise blood loss included the use of the cell saver to return washed red cells to the patients. Routine infective precautions were adhered to including the use of blunt needles in closure of the abdominal wound.

Case histories

CASE 1

A 47 year old man with mild haemophilia A (factor VIIIC concentration of 23 IU/dl, NR 50–150) first became jaundiced in 1982 and was referred to King's College Hospital in 1991. At that time, his serum aspartate transaminase (AST) was raised to 500–600 IU/l and a liver biopsy showed features of an active cirrhosis. He was seropositive for both anti-HCV antibody (second generation immunosorbent assay (ELISA 2)) and HCV RNA (reverse transcriptase-polymerase chain reaction (RT-PCR)). He was treated with α-interferon for nine months, but had biochemical and virological relapse towards the end of that period. Over the next 12 months he deteriorated with recurrent episodes of variceal bleeding, diuretic resistant ascites, and severe lethargy, accompanied by a significant worsening of hepatocellular function (INR 1·6, albumin 24, bilirubin 85). In June 1994 he underwent orthotopic liver transplantation. The immediate postoperative course was uneventful apart from one episode of acute cellular rejection at day 10. At three months he developed abnormal liver function tests and

thrombocytopenia. Liver histology was suggestive of cytomegalovirus hepatitis, confirmed by serology, which resolved with intravenous gancyclovir. Postoperatively he remains seropositive for HCV RNA and a recent liver biopsy performed at nine months post-transplantation, after liver function test abnormalities, showed features consistent with a progressive active hepatitis. He has since been started on antiviral treatment with ribavirin. His factor VIII concentrations remain in the normal range at 12 months follow up.

CASE 2

A 54 year old man with factor X deficiency (factor X concentration of 31 IU/dl, NR 50-150) first developed abnormal liver function tests in 1991. On referral to King's College Hospital he was found to be seropositive for both anti-HCV antibody (ELISA-2) and for HCV RNA (RT-PCR). Serum AST ranged between 200 and 300 IU/l although a liver biopsy was not performed because of the severity of his clotting disorder. A trial of interferon was complicated by significant thrombocytopenia (platelet count 30×10^9/l) and was discontinued after nine months with only slight biochemical improvement. Subsequently he deteriorated with intermittent episodes of confusion and the eventual development of grade 4 encephalopathy. Synthetic function worsened with an INR of 2.1, albumin 19, and bilirubin 105). In February 1995 he proceeded to an orthotopic liver transplantation. At operation, histology of the explained liver showed an active cirrhosis. His postoperative course was uneventful with no episodes of rejection or sepsis. Postoperative serum assays have shown continuing seropositivity for HCV RNA; however, a liver biopsy performed at two months does not show any histopathological evidence of an active hepatitis. Factor X concentrations have remained within the normal range at six months after the transplant.

CASE 3

A 27 year old man with severe haemophilia A (factor VIIIC 4 IU/dl) had experienced recurrent haemarthroses resulting in chronic arthropathy despite regular factor VIII concentrate. Since 1990, he had been noted to have hepatosplenomegaly with abnormal liver function tests and was found to be seropositive for both anti-HCV antibody (ELISA-2) and for HCV RNA (RT-PCR). Serum AST concentrations ranged between 100–200 IU/l and a subsequent liver biopsy confirmed an active cirrhosis. At the same time he was found to be coinfected with HIV and for this reason he was not treated with interferon. Over the past five years his CD4 counts were stable between 280 and 300×10^6/l and he had remained well with no symptoms or AIDS defining illnesses. From November 1994 he deteriorated with diuretic resistant ascites, debilitating lethargy, and worsening of synthetic function (INR 1·8, albumin 25, and bilirubin 60). He underwent orthotopic liver transplantation in February 1995. His postoperative course was complicated at 48 hours by retroperitoneal haemorrhage and renal failure secondary to renal vein compression. Following an evacuation of the haematoma at laparotomy, when several small bleeding vessels were isolated in the retroperitoneum and haemostasis quickly achieved with diathermy, his renal function was restored. At two months post-transplant he had a mild rise of his AST to 170 IU/l. Liver biopsy showed features of a mild cholangitis but no rejection or features of a viral hepatitis. However, he too shows continuing positivity for HCV RNA by PCR. His factor VIIIC concentration remains within the normal range at six months follow up.

CASE 4

A 49 year old man with severe haemophilia B (factor IX concentration of 3 IU/dl, NR 50–150) and a significant degenerative arthropathy from multiple interarticular bleeds earlier in life, was found to be hepatitis C antibody positive (ELISA 2) on routine testing in 1990. He first developed abnormal liver function tests in 1992 and received a 12 month course of interferon between November 1992 and October 1993, which was discontinued after a biochemical relapse and poor tolerance. He has since been found also to be positive for HCV RNA (RT-PCR) but negative for HIV. During this period he also had a small left sided subdural haematoma, confirmed on computed tomography, which did not require any neurosurgical intervention. He had an index variceal bleed in September 1994 and has had three further bleeds since, accompanied by a significant deterioration of synthetic function (INR 1·5, albumin 19, and bilirubin 73). He underwent orthotopic liver transplantation in April 1995. At day 10 postoperatively, he developed acute renal failure, secondary to cyclosporin toxicity, which required intermittent haemodialysis (urea 37, creatinine 540). On day 14 he had graft dysfunction with a rise in his AST to 220 IU/l. He was treated for acute rejection with three days of intravenous methylprednisolone. On the morning of day 18 he developed an intermittent generalised headache without any accompanying focal neurological signs and collapsed while undergoing haemodialysis. Brain computed tomography confirmed a large left sided subdural haematoma in the same site as his previous bleed. An evacuation of the clot that night was not successful and he died on day 20 post-transplantation. At the time of his subdural bleed factor IX concentration was within the normal range at 104 IU/dl.

Results

SERIAL ASSAYS OF FACTORS VIII, IX, AND X

In patients 1 and 3, factor VIIIC concentrations rose from 23 and 4 IU/dl respectively to 62 and 42 IU/dl by 12 hours post-

transplantation (NR 50–150 IU/dl). Despite cessation of supplemental factor VIIIC infusion at 48 hours concentrations remained within the normal range at 72 hours with values of 137 and 95 IU/dl, representing de novo synthesis of factor VIIIC by the grafts. Similarly, despite several episodes of temporary graft dysfunction in the postoperative course of patient 1, with acute cellular rejection, CMV hepatitis and recurrent hepatitis C infection of the graft, concentrations have remained within the normal range at up to 12 months follow up. Patient 3 has had little graft dysfunction since his operation apart from a mild episode of cholangitis at two months; however, his concentration has remained normal at 165 IU/dl (Table I and Figure).

The preoperative concentration of factor X in patient 2 rose from 31 IU/dl and reached 54 IU/dl by 12 hours (NR 50–150 IU/dl). The patient received 16 units of fresh frozen plasma intraoperatively to supplement his factor X concentration but did not require any additional fresh frozen plasma post-transplantation. Concentrations were sustained at 24 hours at 72 IU/dl, representing graft synthesis of factor X. The patient's own production of factor X by his graft has maintained his concentrations within the normal range at up to six months without any intervening graft dysfunction.

Baseline factor IX concentration in patient 4 rose from 3 IU/dl to 68 IU/dl at 12 hours (normal range 50–150 IU/dl). He required one intraoperative bolus of factor IX concentrate but by 12 hours he was synthesising adequate concentrations by his own graft. At 24 and 48 hours, concentrations were similarly maintained within the normal range at 81 and 113 IU/dl. Measurements on samples taken within two hours of his intracerebral bleed confirmed that factor IX concentration had still been maintained within an accepted normal range at 104 IU/dl, suggesting that, despite a recent episode of graft dysfunction from acute rejection, his concentration had not fallen and contributed to the bleed. Concentrations had therefore been maintained up to 18 days in this patient.

INTRAOPERATIVE LOSSES AND SUPPLEMENTS

Intraoperative blood losses for the four patients during transplantation were similar to other patients without clotting disorders (Table II). Similarly, this group of patients did not require any additional supplementation with blood

TABLE I *Clotting factor indices in patients 1, 2, 3, and 4 before and 72 hours after transplantation*

Patient No	INR (0·9–1·2)		APPT (30–40 s)		Fibrinogen (150–450 mg/dl)		Factor VIII (50–150 IU/dl)		Factor IX (50–150 IU/dl)		Factor X (50–150 IU/dl)	
	Pre	Post	Pre	Post	Pre	Post	Pre	Post	Pre	Post	Pre	Post
1	1·6	1·0	107	–	154	158	23	137	–	–	–	–
2	1·5	0·9	57	37	255	270	–	–	–	–	31	125
3	1·8	1·1	83	45	190	345	4	97	–	–	–	–
4	1·5	0·9	85	35	170	280	–	–	3	104	–	–

Normal ranges are shown in parentheses.

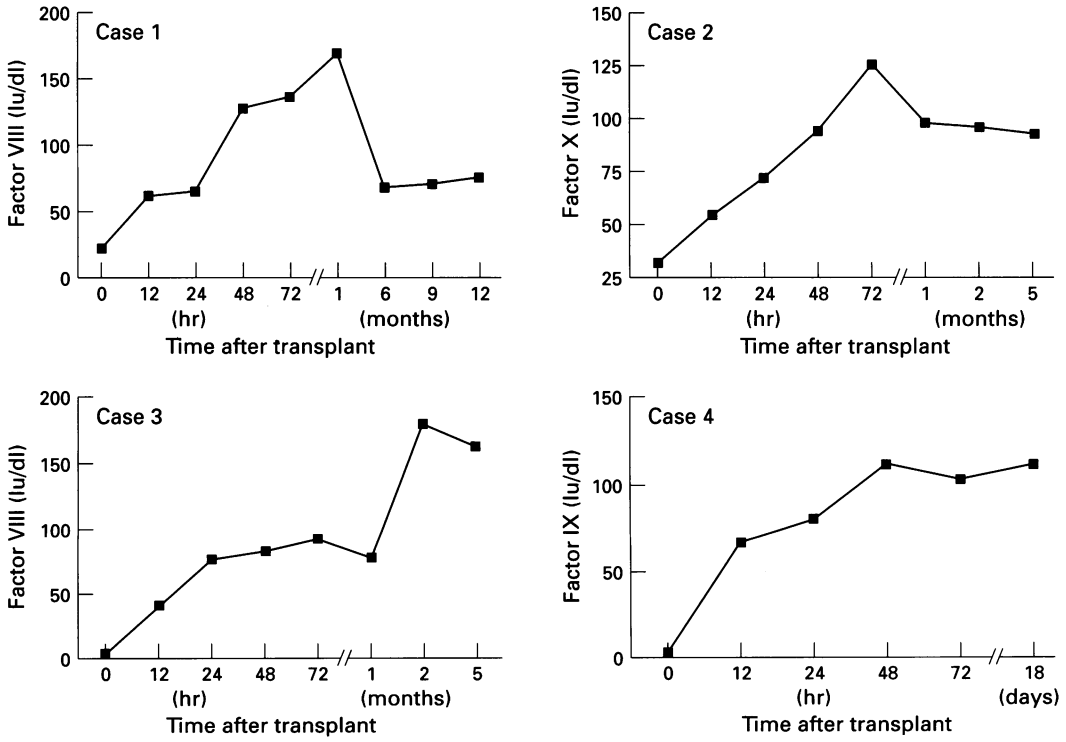

Serial factor concentrations before and after transplantation for patients 1 to 4.

TABLE II *Intraoperative transfusion requirements for patients 1, 2, 3, and 4*

Patient No	Duration of operation	Blood loss (ml)	Transfusion requirements (units)			
			Packed cells	Platelets	Fresh frozen plasma	Cryoprecipitate
1	7 h 35 min	4620	6	0	10	0
2	6 h 28 min	5940	8	0	16	0
3	5 h 30 min	5090	3	3	4	0
4	6 h 30 min	4028	6	2	16	12

products (apart from fresh frozen plasma for patient 2) than those without clotting disorders, confirming that from a haemostatic point of view they were at no greater risk of bleeding during the procedure itself.

Discussion

These results show that patients with severely decompensated chronic liver disease and accompanying clotting factor deficiencies of either VIII, IX, or X, can be safely brought through orthotopic liver transplantation without excessive transfusion requirements, provided that appropriate factor replacement regimens are used. Close cooperation is required between the transplant team and the transfusion department at all stages of the procedure. The use of the continuous intravenous infusion of factor VIII during the surgical procedure, as decribed here, provides a more reliable and predictable factor VIII concentration. Monitoring can be reduced and the amount of factor VIII used is 40% less than that used by conventional bolus regimes, as described in the previous reports. At the initial assessment it is important to qualify the factor deficiency and to determine whether an inhibitor is present. Predictable rises in factor concentration after replacement are more difficult to achieve when an inhibitor can be detected and this situation may pose more of a bleeding risk of the patient. The two bleeding complications in this series were in patients 3 and 4 although neither patient had a detectable fall in their factor concentration at or near the time of their bleed. Patient 3 recovered completely from his retroperitoneal bleed at 48 hours postoperatively, with a concentration of 85 IU/dl at the time and as there was no spontaneous bleeding from his wound or drain sites, it would seem unlikely that his bleeding was a direct result of a clotting disorder. The subdural haematoma in patient 4 was similarly not associated with a fall in factor concentration, at 104 IU/dl, and was most likely related to his renal impairment and his previous intracerebral bleed. This case helps demonstrate that certain groups of haemophiliacs may be at later risk of bleeding complications and these must include those who have had significant previous intracerebral bleeds.

In earlier reports, restoration of normal factor VIII concentration was not achieved until 10 days post-transplantation, indicating the possibility of delayed early de novo synthesis by the allograft as a result of poor intrinsic graft function.[5] In our series, normal clotting factor concentrations were achieved as early as 12 hours and in all cases had been sustained within a normal therapeutic range by 72 hours. As the half life of factors VIII, IX, and X are all less than 72 hours, this must represent de novo synthesis of factor by the new graft. Although graft dysfunction will result in impairment of clotting factor production leading to decreased plasma concentration, this does not apply to factor VIII in these situations as it often acts as an acute phase reactant, resulting in an initial rise in serum concentration. Similarly, in patients with fulminant hepatic failure due to a viral hepatitis, increases in factor VIII concentration are seen compared with the other factors, which are reduced. Likely mechanisms for this effect are an increased synthesis secondary to cytokine release.

Given current statistics and treatment an increasing proportion of patients with HIV infection will survive up to 10 years after seroconversion without developing AIDS[10] and the proportion coinfected with HCV are more likely to die as a result of end stage liver disease than HIV complications. HIV used to be regarded as an absolute contraindication to transplantation, as patients were thought to be at an increased risk of opportunistic infections. However, patients have now been successfully transplanted who were knowingly or unknowingly HIV antibody positive at the time of transplantation.[11 12] In a recent review by Schwartz and colleagues, of 53 transplanted patients with HIV infection caused by either a blood transfusion or an infected transplant, the cumulative incidence of developing the AIDS syndrome was significantly lower in the 40 who received cyclosporin A as part of the immunosuppression regimen (31%) than in 13 patients not given cyclosporin (90%).[12] The best long term data currently on survival of HIV positive transplanted patients is from Starzl and colleagues[11] who reviewed 25 transplanted patients who were either HIV positive before transplantation or who seroconverted postoperatively. Of the 15 who had had liver transplants, seven were known to be HIV positive at the time of transplant and eight later seroconverted after their transplant. When this group was compared with liver transplants overall, there was no difference in survival at one year but by five years survival was 53% in the HIV positive group compared with 63% overall. In vitro studies have shown that both cyclosporin and tacrolimus (FK506) reduce cell to cell transmission of HIV-1 virus and can also significantly reduce the yield of infectious HIV by 100-fold.[13] Both groups of drugs were found to inhibit the growth of infected cells at concentrations that did not impair the growth of uninfected cells. Recent studies have shown that tacrolimus was more potent than cyclosporin in decreasing CD4+ expression in cultured murine microglia, concluding that overall both drugs may have some potentially beneficial role in the treatment of patients with HIV disease.[14]

The exact role of HIV coinfection in HCV related liver disease remains unclear but evidence suggests that it may accelerate the

rate of hepatic decompensation.[3 15 16] Replication of HCV may be enhanced resulting in a greater viral load and greater extent of hepatocyte damage.[3] Telfer *et al* reported an association between the rate in decline of CD4 cells, p24 antigenaemia, and the risk of hepatic decompensation to cirrhosis.[3] Coinfection with HIV would also be expected to increase the severity of recurrent HCV infection of the graft.

Recurrence of HCV infection is virtually universal after liver transplantation for hepatitis C cirrhosis. Most patients develop acute hepatitis in the graft during the early postoperative period[2] and most will develop chronic liver disease.[17-19] Although the clinical course of recurrent HCV infection is usually benign, some patients may develop rapidly progressive liver disease leading to cirrhosis and graft loss within five years.[20] The possible host and viral factors associated with this accelerated graft damage have not yet been identified, although in addition to coinfection with HIV, the degree of HLA donor/recipient mismatch, HCV genotype, and level of immunosuppression have all been suggested.[21]

We acknowledge the contribution of the referring doctors: Dr J Duncan, Consultant Haematologist, Royal Sussex County Hospital; Dr M Makris, Consultant Haematologist, Royal Hallamshire Hospital, Sheffield; Dr H Desani, Consultant Haematologist, University Hospital of Wales, Cardiff; and Dr M Dudley, Consultant Haematologist, Lewisham Hospital.

1 Tibbs C, Williams R. Hepatitis C and haemophilia: a report of a meeting held at The Royal Free Hospital, London, 12 December 1994. *Haemophilia* 1995; **1:** 207–9.
2 Wright T, Donegan E, Hsu H, Ferrell L, Lake J, Kim M, *et al.* Recurrent and acquired hepatitis C viral infection in liver transplant recipients. *Gastroenterology* 1992; **103:** 317–22.
3 Telfer P, Sabin C, Devereux H, Scott F, Dusheiko G, Lee C. The progression of HCV associated liver disease in a cohort of haemophiliac patients. *Br J Haematol* 1994; **87:** 555–61.
4 Webster W, Mandel S, Reddick R, Wagner J, Penick G. Orthotopic liver transplantation in canine hemophilia B. *Am J Physiol* 1974; **226:** 496–500.
5 Bontempo F, Lewis J, Gorenc T, Spero J, Ragini M, Scott J, Starzl T. Liver transplantation in haemophilia A. *Blood* 1987; **69:** 1721–4.
6 Gibas A, Diastag J, Schafer A, Delmonico F, Bynum T, Schooley R, *et al.* Cure of haemophilia A by orthotopic liver transplantation. *Gastroenterology* 1988; **95:** 192–4.
7 Lewis J, Bontempo F, Spero J, Ragini M, Starzl T. Liver transplantation in a haemophiliac [letter]. *N Engl J Med* 1985; **312:** 1189.
8 Merion R, Delius R, Campbell D, Turcotte J. Orthotopic liver transplantation totally corrects factor IX deficiency in haemophilia B. *Surgery* 1988; **104:** 929–31.
9 Lerut J, Laterre P, Lavenne-Pardonge E, Donataccio M, Geubel A, Reynaert M, Otte J. Liver transplantation and haemophilia A. *J Hepatol* 1995; **22:** 583–85.
10 Phillips AN, Sabin CA, Elford J, Bofill M, Janossy G, Lee CA. Use of CD4 lymphocyte count to predict long-term survival free of AIDS after HIV infection. *BMJ* 1994; **309:** 283–4.
11 Tzakis A, Cooper M, Dummer J, Ragini M, Ward J, Starzl T. Transplantation in HIV+ patients. *Transplantation* 1990; **49:** 354–8.
12 Schwartz A, Offerman G, Keller F, Benhold I, L'Age-Stehr J, Krause PH, Mihatsch MJ. The effect of cyclosporine on the progression of human immunodeficiency virus type 1 infection transmitted by transplantation – data of 4 cases and review of the literature. *Transplantation* 1993; **55:** 95–103.
13 Karpas A. Potential therapeutic effects of Cyclosporin and FK506 with HIV disease. *IXth International Conference on AIDS in affiliation with the IVth STD world congress*. Berlin, Germany, 1993. (Abstract No PO-A25 0570 p229.)
14 Sawada M, Suzumura A, Marunouchi T. Down regulation of CD4 expression in cultured microglia by immunosuppressants and lipopolysaccharide. *Biochem Biophys Res Commun* 1992; **189:** 869–76.
15 Eyster M, Fried M, Bisceglie A, Goedert J. Increasing hepatitis C virus RNA levels in haemophiliacs: relationship to human immunodeficiency virus infection and liver disease. *Blood* 1994; **84:** 1020–3.
16 Eyster M, Diamondstone L, Lien J, Ehmann W, Quan S, Goedert J. Natural history of hepatitis C virus infection in multi-transfused haemophiliacs: effect of co-infection with human immunodeficiency virus. *Journal of Acquired Immune Deficiency Syndromes* 1993; **6:** 602–10.
17 Feray C, Gigou M, Samuel D, Paradis V, Wilber J, David M, Urdea M, Reynes M, Brechot C, Bismuth H. The course of hepatitis C infection after liver transplantation. *Hepatology* 1994; **20:** 1137–43.
18 Berg T, Konig V, Hopf U, Bauditz J, Neuhaus P, Blumhardt G, *et al.* Long term follow up of hepatitis C virus infected patients after orthotopic liver transplantation. *Hepatology* 1993; **18:** 72A.
19 Konig V, Bauditz J, Lobeck H, Lusenbrink R, Neuhaus P. Blumhart G, *et al.* Hepatitis C reinfection in allografts after orthotopic liver transplantation. *Hepatology* 1992; **16:** 1137–43.
20 Gane E, Portmann B, Smith H, Tibbs C, Naoumov N, Williams R. Hepatitis C virus infection after liver transplantation is associated with severe graft disease. *J Hepatol* 1994; **21:** 521.
21 Feray C, Gigou M, Samuel D, Okamoto H, Reynes M, David M, *et al.* Influence of the genotypes on the severity of recurrent liver disease after liver transplantation. *Gastroenterology* 1995; **108:** 1089–97.