

DIRECT INGUINAL HERNIA

LAWRENCE S. FALLIS, M.D.

DETROIT, MICH.

FROM THE DEPARTMENT OF SURGERY OF THE HENRY FORD HOSPITAL, DETROIT, MICH.

DIRECT inguinal hernia is that type of protrusion in which the hernial sac comes directly through the abdominal wall in contradistinction to indirect inguinal hernia in which the sac come obliquely through the abdominal wall by reason of its intimate association with the spermatic cord. The appearance of both of these otherwise dissimilar herniae at the external inguinal ring has led to their being grouped together for purposes of treatment. The poor results of operation for direct hernia are directly attributable to the employment of methods of repair which are satisfactory for indirect hernia, but are unsuitable for the direct variety because of the different problems involved. Recurrences after operation for direct inguinal hernia, judging from reports in the literature, vary from 6 to 50 per cent. It is instructive to note that the longer the time which had elapsed since operation and the more complete the follow-up, the greater was the number of recurrences. A review of our records in the Henry Ford Hospital reveals that during the decade 1920-1929, inclusive, we had 251 operations for direct hernia. We were able to trace 154 patients who were followed for a minimum period of two years after operation, and of these 18 had recurred, giving us a rate of recurrence of 11.6 per cent in direct hernia.

It has been customary to follow the teachings of Hamilton Russell and to designate a congenital origin to indirect inguinal hernia, and consider direct hernia as being of acquired origin. However, a consideration of the anatomic variations obtained in direct hernia suggests that the etiology of this type of rupture may also be explained on a congenital basis.

Surgical Anatomy of Direct Hernia.—The sac of a direct hernia pushes its way through the abdominal wall in an area designated as Hesselbach's triangle. The base of this triangle is formed by Poupart's ligament and the superior ramus of the pubes, its lateral boundary by the deep epigastric artery, and its medial boundary by the lateral edge of the rectus muscle and its sheath. The floor of the triangle is formed by the transversalis fascia. Next to the umbilicus, Hesselbach's triangle is the weakest spot in the abdominal parietes, lying as it does directly behind the external inguinal ring. It receives theoretic support from the peritoneum and preperitoneal fat posteriorly, and from the inconstant and attenuated conjoint tendon anteriorly. The floor of the triangle as viewed from the abdominal surface is seen to be divided into two unequal parts by a fold of peritoneum covering a fibrous cord which represents the obliterated hypogastric artery. The greater proportion, by far, of

Submitted for publication September 4, 1937.

direct herniae comes through the larger medial compartment close to the pubic spine. Rarely the sac of a direct hernia protrudes through the smaller lateral compartment, constituting the so-called Hesselbach's hernia.

Anatomic Variations of the Inguinal Region in Direct Hernia.—The first anatomic variation that may be observed at operation on a direct hernia is the large size of the external inguinal ring in proportion to the size of the hernial sac. This point may be controversial since it might be claimed that the enlarged inguinal ring is secondary to the appearance of the hernia. However, it has been our observation, in following patients over a period of years, that those with large external inguinal rings frequently proceed to the development of direct hernia. The aponeurosis of the external oblique in cases of direct hernia is usually found to be intact and its fibers are not separated in the line of the inguinal canal, a condition that is so constant in oblique inguinal hernia. An examination of the rectus muscle after separation of the fibers of the external oblique aponeurosis, during the course of an operation for direct hernia, will commonly reveal three definite departures from the normal. The body of the muscle itself is much narrower than usual. The fleshy fibers of the internal oblique and transversalis muscles arch upwards to unite at the lateral edge of the rectus muscle and appear to be inserted directly into the anterior sheath of the rectus muscle rather than through the intermediary of a fibrous tendon. The conjoined tendon is rudimentary or absent. It will be noted that these three factors deprive the weak area of the abdominal wall of additional support and thus render it more vulnerable and prone to hernial formation. It is true that nature recognizes the weakness and makes a futile effort to remedy it by causing the cremaster muscle to hypertrophy and cover over the defect. Inasmuch as these variations may be said to be congenital, it is maintained that there is some justification for suggesting that direct hernia has a congenital origin.

Diagnosis.—The clinical diagnosis of direct inguinal hernia is not especially difficult in spite of the frequent assertion that differentiation between direct and indirect hernia can sometimes be made only at operation. It is essential to give consideration to certain points in the history and clinical examination if the observer is to arrive at a correct conclusion in the majority of cases. Direct hernia is a condition which appears in middle age at the time of life when there is a decrease in muscular tone, and fibrous tissue loses its elasticity. This relationship between loss of muscle tone and direct hernia is well exemplified in emaciated individuals and in those suffering from debilitating diseases. The subjects of direct hernia are usually adult males, though occasionally the condition exists in women or children.

The onset is often so gradual that a moderate sized hernia will develop without the individual's knowledge. Pain, therefore, is a rare symptom of direct hernia in contradistinction to the usual traumatic history obtained in indirect inguinal herniae.

Direct hernia is frequently bilateral, and while this is also true of indirect inguinal hernia, there is this difference, that in the former, both sides tend

to appear simultaneously while in the latter there is often an interval between the appearance of the hernia on the two sides.

Occupation also has a bearing on the differential diagnosis. If we take for example a man who has been engaged in heavy labor since early adult life, the hernia which he develops at age 45 is more likely to be direct, for if he has been possessed of the preformed sac of an indirect hernia, the hazards of his occupation must have provided, on many occasions, the extra strain necessary to force down the abdominal contents and produce clinical evidence of hernia.

The nature of a hernia can be readily defined by observing the passage of the contents of the sac through the abdominal wall. The patient should be standing in a good light in order to determine whether the sac comes straight through the abdominal wall, as in direct hernia, or obliquely through, as in indirect hernia. The incorporation of the sac of an indirect hernia in the coverings of the spermatic cord permits the sac and its contents to follow this structure to the upper pole of the testes so that even a moderate sized indirect inguinal hernia is found in the scrotum. The sac of a direct hernia, regardless of its size, since it has no relationship with the spermatic cord, cannot enter the scrotum. The bulging of a large direct hernia may encroach on the skin of the scrotum but the sac does not enter the scrotal cavity. Direct herniae appear instantly when the patient assumes the erect position and are as rapidly reduced when the recumbent position is resumed, whereas, in indirect hernia there is usually some delay in the appearance and in the reduction of the hernia. The larger mouth and more direct course of the sac explain this difference and account for the comparative rarity of incarceration of a direct hernia.

The clinical appearance of a direct hernia depends primarily on a defect in the transversalis fascia. This structure, in patients who develop direct hernia, provides practically the only barrier against protrusion of peritoneum through the abdominal wall. The additional strain thrown on the transversalis fascia by loss of muscle tone of the abdominal wall, by increased intra-abdominal pressure or by the laying down of preperitoneal fat in large amounts, causes stretching and ultimate rupture of its fibers. A break in the continuity of the transversalis fascia can be brought about by trauma as is well evidenced by the practice of inducing hernia by this method in conscripts who seek to avoid military service. The clinical diagnosis of direct hernia depends, to a large extent, on an examination of the floor of Hesselbach's triangle. After inspection of the inguinal region in the erect position, to determine if possible the direction of the passage of the hernial sac through the abdominal wall and to observe the relation of the sac to the scrotal cavity, the patient should be put in the recumbent position. An investigation of the integrity of the floor of Hesselbach's triangle is carried out by invaginating the elastic wall of the scrotum through the enlarged external inguinal ring. If the tip of the examining finger encounters no resistance, the impression is given of passing directly into the pelvic cavity, and it can, therefore, be

assumed that the transversalis fascia is disrupted and that we are dealing with a direct hernia. It is also possible, in most instances, to palpate, above and medially, the sharp lateral edge of the rectus sheath, and below, the smooth superior ramus of the pubic bone. In some very large indirect inguinal herniae of long standing, Hesselbach's triangle may be so much encroached upon as to present similar findings, but then the fact that the hernial sac enters the scrotal cavity serves as the differential diagnostic point. Stiles, of Edinburgh, was frequently able to diagnose an indirect inguinal hernia by determining the presence of a sac from palpation of the structure of the spermatic cord in the scrotum.

Incidence.—In a recently reported series of 1,600 hernia operations performed at this hospital during the decade 1920–1929, the proportion of direct herniae was 15.7 per cent. However, at the present time, the figures closely approximate 25 per cent. This increase is due, in part at least, to more rigid preemployment examinations which result in the rejection of an increasing number of workmen with small inguinal herniae. These men are now obliged to undergo operation in order to obtain work, and it is in this group of cases that we have observed an increased proportion of direct herniae, more especially when the condition is bilateral.

Operative Technic.—The repair of a direct hernia is essentially a plastic operation, the success of which depends on adherence to the cardinal rules of plastic surgery: namely, utilization of all available tissue to the best advantage and suturing without tension. The medial extremity of the usual hernial incision should extend well over the external inguinal ring to provide adequate exposure of the pubic spine and to allow enough retraction of the medial flap of the external oblique aponeurosis to expose the rectus muscle and sheath. The hockey-stick incision will be found useful in obese patients. The fibers of the external oblique aponeurosis are separated in line with the upper pillar of the external inguinal ring so as to prepare a large lateral flap for subsequent imbrication. The ilio-inguinal nerve is identified and isolated for protection, before incising the cremaster muscle and fascia. The structures constituting the spermatic cord are then shelled out of their enveloping cremasteric fibers for the entire length of the canal and isolated by tape. The fat covered direct sac is now well exposed lying in the medial half of the canal, and the diagnosis of direct hernia substantiated by the fact that the sac lies entirely free of the spermatic cord and is not incorporated in its structures (Fig. 1).

The sac is best opened in the manner advocated by Hoguet,⁴ whose contribution constitutes a real advance in the treatment of direct hernia. The tediousness of the dissection necessary to open and free the direct sac and the constant anxiety regarding possible bladder injury are entirely obviated by adopting Hoguet's maneuver which is as follows: The internal inguinal ring is exposed by gentle traction on the spermatic cord and by retraction of the internal oblique and the transversalis muscle with a vein retractor. A careful inspection of the posterior internal aspect of the cord will reveal the crescentic peritoneal border of the potential indirect inguinal hernia sac, a

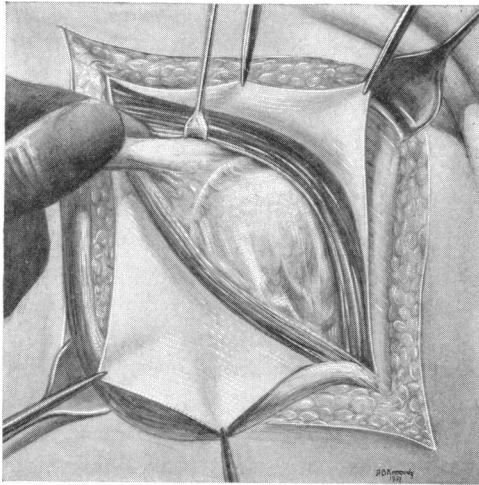


FIG. 1.—The direct sac is shown in Hesselbach's triangle medial to the deep epigastric vessels. The region of the internal ring is displayed and the spermatic cord elevated to show the potential indirect sac on its postero-internal aspect.

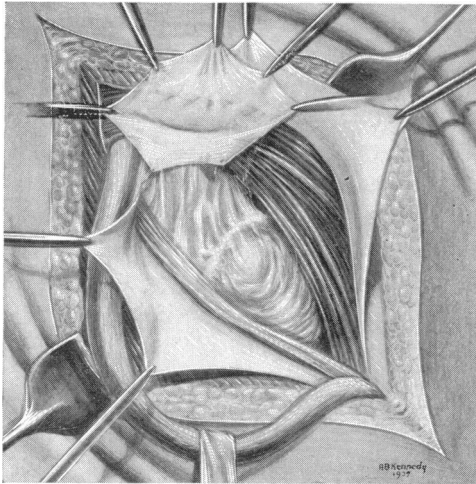


FIG. 2.—The potential indirect sac has been separated from the spermatic cord, freed from the peritoneal fat at its neck and opened.

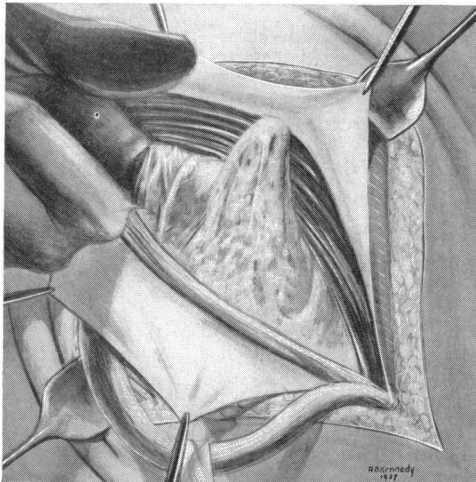


FIG. 3.—The surgeon's index finger has been passed into the peritoneal cavity through the opened potential indirect sac and directed medially to enter the mouth of the sac.

structure which is constantly present in close association with the vas (Fig. 2). The peritoneal cavity is opened here by picking up and incising the potential sac after separating the fibers of the internal spermatic fascia. An examining finger now enters the peritoneal cavity and is directed medially behind the deep epigastric vessels to enter the mouth of the direct sac and verify the diagnosis (Fig. 3). Traction is now put on the small indirect sac, and by brushing away the preperitoneal fat and bringing into view first the deep epigastric vessels, and the fibrous cord of the obliterated hypogastric artery, until the bladder is drawn up in the wound, it will be found that the direct sac now lies lateral to the deep epigastric vessels and that the two sacs have been converted into one wide-mouthed indirect sac (Fig. 4). Closure of the sac is now effected by a purse string suture inserted from within.

This method of dealing with the sac entirely guards against overlooking a saddle bag hernia and, since it is admitted that failure to recognize and remove both sacs is a frequent cause of recurrence, this feature alone commends its use.

Since the appearance of a direct hernia depends primarily upon a break in continuity of the transversalis fascia, it follows that repair of this structure must be the most important step in the operation. It is absolutely essential to identify the course of the deep epigastric vessel before proceeding with suture of the trans-

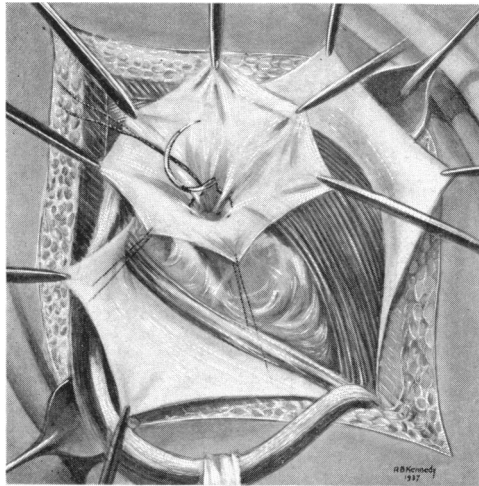


FIG. 4.—The lax peritoneum of the direct sac has been pulled up from underneath the deep epigastric vessels after brushing away the preperitoneal fat, and the direct hernia is now "converted" into an indirect hernia. It is closed by a purse string suture inserted from within the sac.

versalis fascia if troublesome hemorrhage is to be avoided. In small direct herniae, where there is simply a stretching and thinning out of the fibers of the fascia, a purse string suture or series of purse string sutures will suffice to close the defect. Rarely in addition to a generalized bulging is there a definite small opening in the transversalis fascia with a protrusion of preperitoneal fat or even a small fat-covered secondary sac, the so-called diverticulum described by Andrews.¹ It is important in these cases to reduce the contents and suture this opening before proceeding with the usual repair. In the majority of direct herniae, however, there is complete separation, or attenuation, of the fibers of the transversalis fascia, from the pubic spine to the internal ring. It is necessary at this stage to retract the rectus muscle strongly and bring into view the transversalis fascia which in this region is of surprising strength, because here it takes the place of the deficient posterior rectus sheath. It is easily recognized as a strong aponeu-

rotic sheet which may be adequately mobilized to permit its suture to the shelving edge of Poupart's ligament, from the pubic spine to the internal inguinal ring (Fig. 5). Special care should be taken in suturing the medial half because this is the critical area where recurrence takes place. It is usually necessary to divide the remnants of the cremaster muscle in order to effect complete apposition of the transversalis fascia to the medial half of Poupart's ligament.

When the first line of defense against recurrence is completed, the question of support arises. It is apparent, that in the majority of cases the usual Bassini operation must be doomed to failure because of the difficulty of closing the defect. It will be found impossible in many instances to approximate the arching fibers of the internal oblique and transversalis muscles to Poupart's ligament, and even in those cases in which apposition can be made, the sutures are tied under tension, thereby violating the first principle of plastic repair. Numerous efforts have been made to solve the problem of closing in this triangle. Bloodgood opened the lateral margin of the rectus sheath and brought down the fleshy fibers of the muscle to Poupart's ligament, and Halsted turned down a flap of anterior rectus sheath, but the late results of these modifications were not good. Gallie's effort to close the defect by weaving in strips of fascia lata has proved effective, and while it has a definite place when the structures are poor and in the repair of recurrent hernia, disadvantages such as tediousness and increased risk of infection prevent its universal adoption. Free fascial grafts have been employed with indifferent results. A solution of the problem of obtaining adequate tissue to close the defect without tension on the sutures is found in a modification of the device suggested by Downes,² who advocated opening the rectus sheath by an incision just internal to its lateral margin and then bringing the fibers of the rectus muscle down to Poupart's ligament. The second part of this step has all the disadvantages of the Bloodgood and Halsted procedures and may be omitted by making a more medial incision in the rectus sheath. The aponeurosis of the external oblique has a loose attachment to the rectus sheath at its lower end and actually has its main insertion close to the midline. Advantage is taken of this loose attachment to separate the external oblique aponeurosis from the rectus sheath by sharp dissection. It will now be found that the anterior rectus sheath, which in reality is composed of the conjoined tendon of the internal oblique and transversalis muscles, is exposed almost to the midline. The incision of the sheath is made in a vertical direction as close as possible to the reflection of the aponeurosis of the external oblique and extends from the pubic crest upwards for a distance of from two and one-half to three inches. A muscular branch of the deep epigastric artery is almost always severed, but bleeding is easily controlled by a transfixion suture. The firm, fibrous lateral edge of the rectus muscle and sheath is now easily approximated to Poupart's ligament without tension. The first interrupted suture is introduced at the lower angle and includes the periosteum over the

FIG. 5.—The transversalis fascia has been mobilized and sutured to Poupart's ligament.

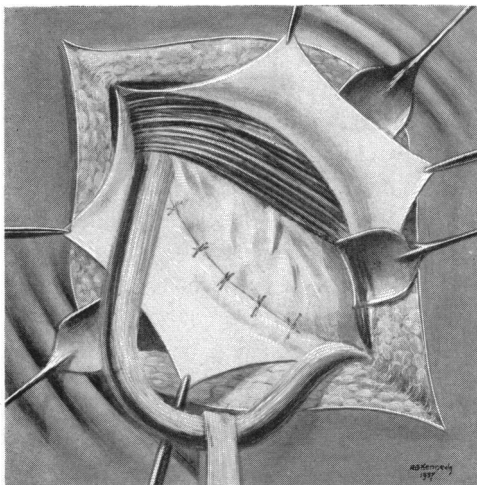


FIG. 6.—The lateral margin of the rectus muscle and sheath and margin of the internal oblique and transversalis muscle have been sutured to Poupart's ligament. Note the wide gap in the anterior rectus sheath.

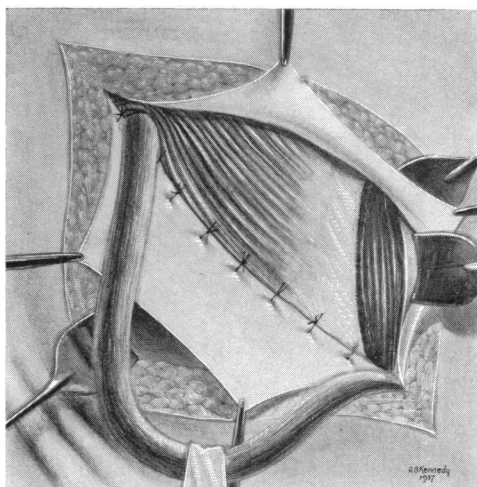
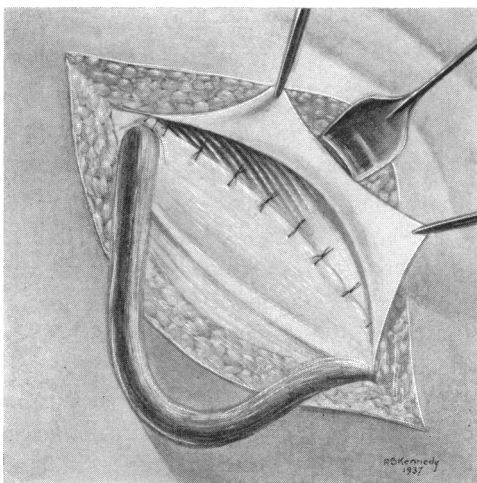


FIG. 7.—The lateral flap of the external oblique aponeurosis has been sutured to the anterior surface of the internal oblique and rectus muscles. Note the incision opposite the internal ring.



pubic spine. The suturing is continued up to the internal inguinal ring and one or two sutures are placed above the spermatic cord, care being taken not to include the ileo-inguinal nerve (Fig. 6). The triangle defect is thus adequately closed by a firm fibromuscular bundle without weakening the abdominal wall, for the gap which now exists in the anterior rectus sheath is amply protected by the fleshy fibers of the rectus muscle posteriorly and the aponeurosis of the external oblique anteriorly.

Additional support is rendered by modifying the classic Bassini technic and imbricating the aponeurosis of the external oblique behind the spermatic cord. The lateral flap of the external oblique which has purposefully been

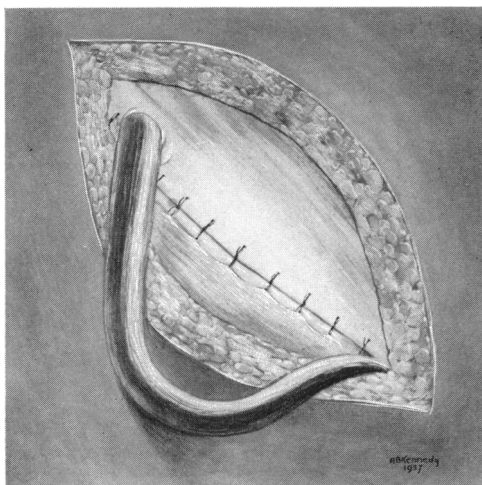


FIG. 8.—The medial flap of external oblique aponeurosis is sutured down to Poupart's ligament behind the cord and a new external ring has been fashioned.

fashioned as large as possible is now sutured down to the anterior rectus sheath and internal oblique muscles with interrupted sutures. This lower flap is incised opposite the internal inguinal ring, in order that the spermatic cord may not be subjected to pressure and the viability of the testes endangered (Fig. 7). The medial flap of external oblique aponeurosis is now sutured down to the external aspect of Poupart's ligament for the whole length of the canal. One or two sutures are placed above the point where the cord emerges, thus forming a new external inguinal ring (Fig. 8). The external inguinal ring is now superimposed on the internal ring, but in our experience this does not predispose to recurrence if a high closure of the sac has been effected. The operation is now completed by allowing the cord to fall back upon the surface of the external oblique and closing the subcutaneous tissues and skin over it.

SUMMARY AND CONCLUSIONS

- (1) The surgical anatomy of the inguinal region concerned with direct hernia is briefly reviewed.
- (2) An attempt is made to attribute a congenital origin to direct hernia on the basis of certain constant anatomic variations.
- (3) The diagnosis of direct hernia rests upon the recognition of two facts: First, that the sac has no relationship to the spermatic cord; and second, that there must be a separation or stretching of the fibers of the transversalis fascia.
- (4) The cure of direct hernia is essentially a plastic operation. A method of repair in which the transversalis fascia is utilized and the defect in Hesselbach's triangle is further reinforced by a fibromuscular bundle derived from the rectus muscle and sheath is described.

REFERENCES

- ¹ Andrews, E., and Bissell, A. D.: Direct Hernia: Record of Surgical Failures. *Surg., Gynec., and Obst.*, **58**, 753-761, April, 1934.
- ² Downes, W. A.: Management of Direct Inguinal Hernia. *Arch. Surg.*, **1**, 53-73, July, 1920.
- ³ Fallis, L. S.: Inguinal Hernia. *ANNALS OF SURGERY*, **104**, 403-418, September, 1936.
- ⁴ Hoguet, J. P.: Direct Inguinal Hernia. *ANNALS OF SURGERY*, **72**, 671-674, December, 1920.
- ⁵ Hotchkiss, L. W.: Observations on Treatment of Direct Inguinal Hernia in Adults. *ANNALS OF SURGERY*, **68**, 214-216, August, 1918.
- ⁶ Hutchins, E. H.: Operation for Direct Inguinal Hernia. *Surg., Gynec., and Obst.*, **54**, 964-968, June, 1932.
- ⁷ Partipilo, A. V.: Direct Inguinal Hernia Incident to Indirect Hernia; Method of Detection and Repair. *Am. Jour. Surg.*, **7**, 99-102, July, 1929.
- ⁸ Taylor, A. S.: Results of Operations for Inguinal Hernia. *Arch. Surg.*, **1**, 382-406, September, 1920.
- ⁹ Watson, L. F.: *Hernia*. St. Louis, C. V. Mosby Co., 1924.