

Bronchial Adenoma

JOHN K. DONAHUE, M.D., RUDOLPH F. WEICHERT, M.D.,
JOHN L. OCHSNER, M.D.

*From the Department of Surgery, Ochsner Clinic and Ochsner Foundation Hospital,
New Orleans, Louisiana*

THE DESIGNATION, bronchial adenoma, implies a benign tumor of bronchial origin, but the term is used to describe a group of bronchial neoplasms which resemble each other grossly but are microscopically different. Moreover, they are not benign, but are low-grade adenocarcinomas arising from different cell types in the bronchial mucosa. Because the terminology is firmly entrenched in our medical language, it will be difficult to change it.

These relatively uncommon tumors have such variable clinical manifestations that many gaps remain in our knowledge of their natural history, behavior, and treatment. The true nature of the various types of tumors considered as bronchial adenomas and their interrelationship are ill-defined. It may be that few answers will be forthcoming without a better knowledge of the cellular physiology and intracellular pathology of these tumors. Until such time, efforts should be made to study patients with these tumors. Our experience with patients having bronchial adenomas was therefore reviewed in the hope of clarifying some of the existing confusion.

Clinical Material

During the 20-year period ending in 1966, 2,953 patients with pulmonary neoplasms were treated at the Ochsner Clinic.

Presented before the Southern Surgical Association, in Hot Springs, Virginia, December 3-6, 1967.

Reprint requests to John L. Ochsner, M.D.

Only 35 (1.2%) of these neoplasms were classified as bronchial adenomas. The ages of the 35 patients with these tumors ranged from 23 to 79 years, with an average of 49 years. Of the patients, all Caucasian, 15 were men and 20 women. Followup data to the present time are available on all but one patient.

Historical Background

Although Müller²⁶ first described these tumors in 1882, it was not until 1930 that the term, bronchial adenoma, was first used to distinguish a group of bronchial tumors which were more benign, both in morphology and in behavior, than bronchogenic carcinomas.²⁰ Bronchial adenomas remained a grouping of histologically different tumors until Hamperl¹⁵ subdivided them into two main groups. He believed that the most common of these tumors resembled intestinal carcinoids. His contention was questioned because of histologic differences, especially the lack of argentaffinity in the bronchial carcinoid. The description of the carcinoid syndrome produced by a bronchial tumor in 1956,²³ however, established the link between bronchial and intestinal carcinoids. Hamperl¹⁵ described another group of bronchial adenomas as cylindromas (adenoid cystic carcinomas) because of their resemblance to salivary gland tumors. In 1945 a third tumor was identified among bronchial adenomas and was termed mucoepidermoid carcinoma.³⁴ It also is commonly found in salivary glands. A

fourth member, bronchial mucous gland adenoma,¹² although rare, is probably the tumor most suited to be called a bronchial adenoma, for it alone has always been benign.³⁹

Etiology

The cause of bronchial adenomas is not apparent. Orr²⁸ produced pulmonary adenomas in mice by intraperitoneal injection of Urethane. The immediate effect of such an injection on mice is initiation of a chronic inflammatory process in the lung. At necropsy the lungs of the animals showed evidence of active or old pneumonia. Orr concluded from extensive histologic study that tumors originate in the foci of inflammation and that the extent of the original inflammatory focus determines the degree of the formed adenoma. In only one case of this large experimental series was malignant change noted.⁷ Dreissens *et al.*⁷ reported development of pulmonary adenomas about the twentieth week after feeding Urethane to mice. If the mice were fed Urethane to the twenty-fifth week, adenomas with malignant emboli frequently developed.

These experimental tumors histologically resemble bronchial epithelial proliferations, often referred to as tumorlets, and in their later stage of development simulate carcinoids. Tumorlets are occasionally malignant.²⁵ The surgical specimen of one patient in our series contained a typical tumorlet adjacent to a carcinoid tumor, and within the same specimen were multiple areas of hyperplasia or metaplasia of the bronchoepithelium (Fig. 1). Others⁸ have noticed resemblance of peripheral bronchial carcinoids to the minute epithelial proliferations common in organizing pneumonia or associated with various inflammatory conditions. Since Kulchitsky's cells can be found in the epithelium of foregut derivatives, epithelial proliferations, tumorlets, and carcinoids could represent in es-

sence varying stages of development of the same lesion.

Pathology

Bronchial adenomas originate from the epithelium of the bronchial mucous membrane. The carcinoid tumor arises from the argentaffin or Kulchitsky cells, which have been found in the mucosa of the alimentary tract from the mouth to the anus, in some foregut derivatives of the intestinal tract, such as the nasal mucosa, salivary glands, bronchi, biliary tree, pancreas, and pancreatic ducts, and in parts of the genitourinary tract.^{9-11, 38} Carcinoid tumors have been reported in most of these locations. They have also been described in teratomatous growths, sometimes arising from bronchial mucosa within these teratomas.¹⁹

Cylindromas (adenoid cystic carcinomas), mucoepidermoid carcinomas, and bronchial mucous gland adenomas all arise from the mucus secreting cells. Cylindromas resemble salivary gland tumors and have also been reported in the oral cavity, pharynx, larynx, trachea, breast, and sweat glands. Mucoepidermoid carcinomas arise from the mucous cells, usually in areas of squamous metaplasia. They also are a type of salivary gland tumor, and in addition, have been described in the anus and uterus.³⁹

Bronchial adenomas are reported to comprise from 6 to 10% of all primary pulmonary tumors. Carcinoids are the most common, comprising from 80 to 85% of these tumors, whereas cylindromas account for from 12 to 15% and mucoepidermoid from 2 to 3%.³ Bronchial mucous gland adenomas are rare.³⁹ Both carcinoids and cylindromas metastasize to perineural lymphatics, regional nodes, liver, lung, bone, skin, and other organs.³ About 10% of bronchial adenomas are reported to metastasize. The cylindroma metastasizes three times more often than does the carcinoid type. The histologic pattern of the primary tumor is helpful in predicting the likelihood of me-

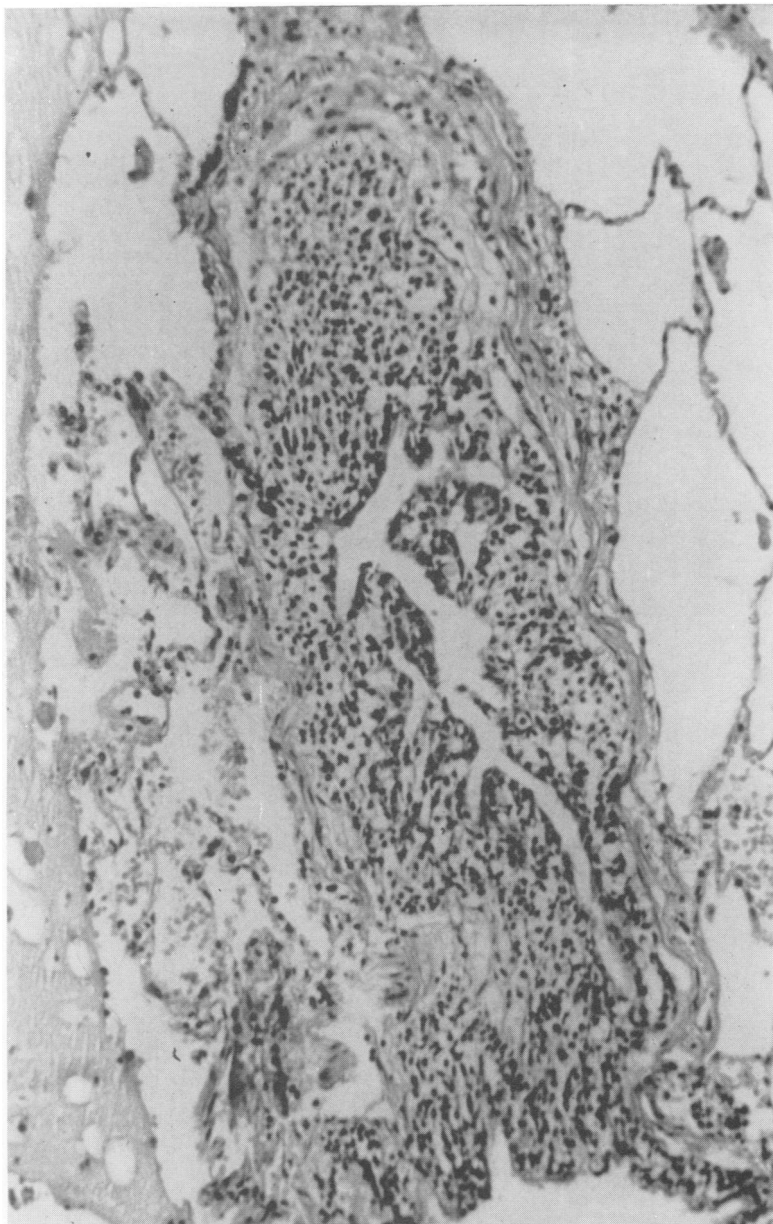


FIG. 1A. Photomicrographs. Bronchiole showing proliferation of bronchial epithelium.

tastasis. The degree of anaplasia is apparently directly related to the incidence of metastasis. The tumor with orderly morphology does not metastasize. Mucoepithelioid tumors are locally invasive without evidence of vascular or lymphatic involvement and are the more benign of

these malignant tumors. They, like other adenomas, cause disability by bronchial obstruction and secondary pulmonary supuration.^{29, 40} Mucous gland adenomas are benign.³⁹

Bronchial adenomas are usually located in the major bronchi in reach of the bron-

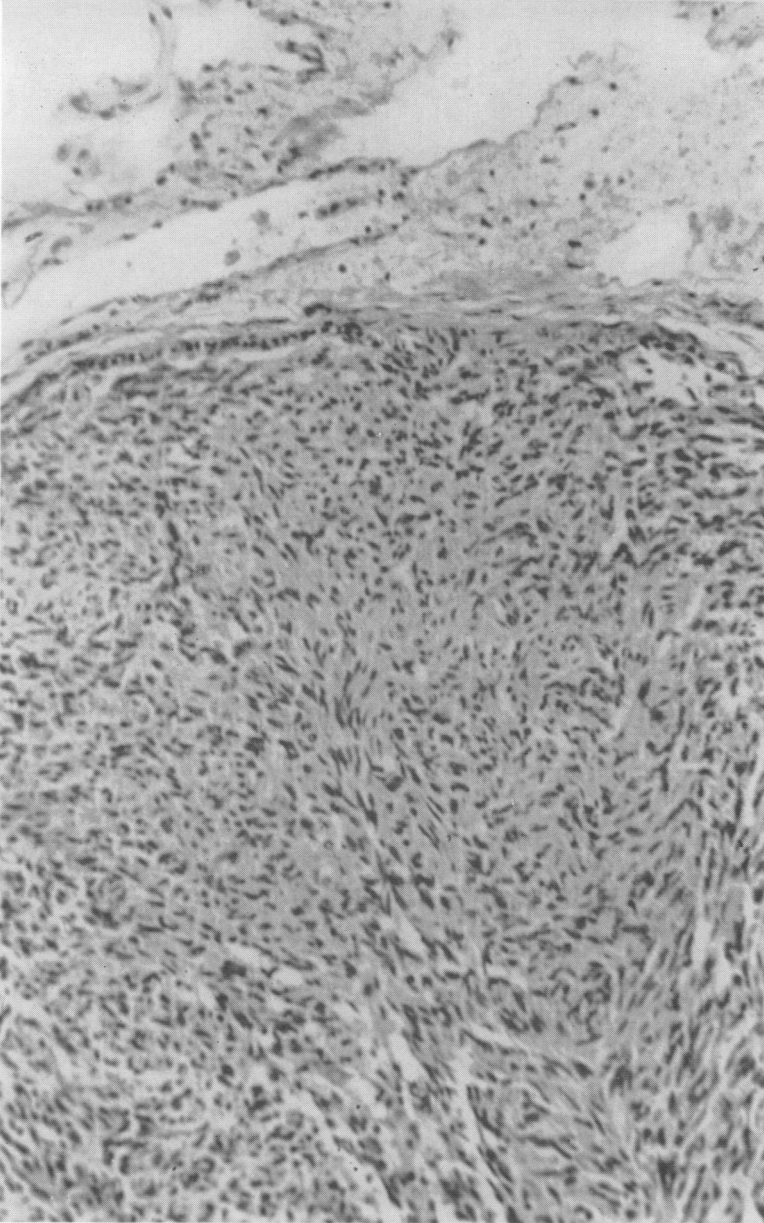


FIG. 1B. Portion of tumorlet shows lesion composed of small uniform, but atypical bronchial epithelial cells.

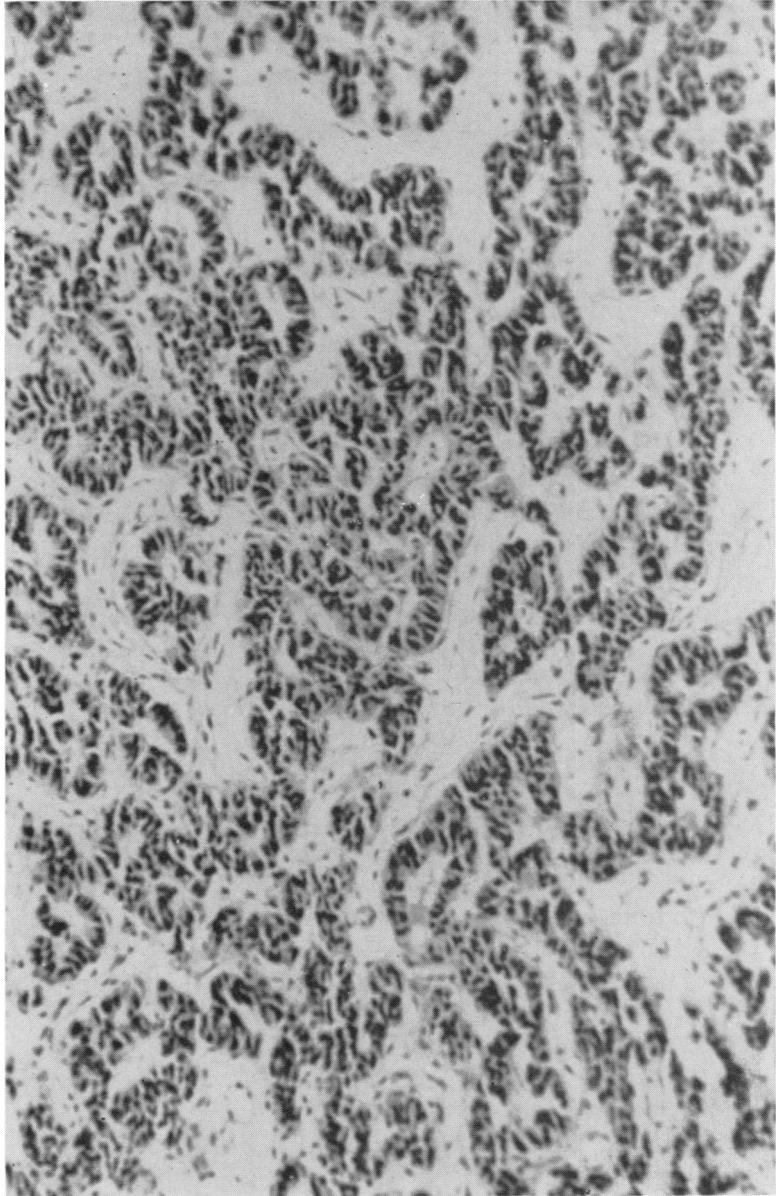
choscope.¹⁴ Cylindromas are more centrally located and frequently involve the trachea. Carcinoids, on the other hand, may be more peripherally located and out of reach of the bronchoscope.³ Multiple bronchial carcinoids are usually peripheral.⁸

In our series, as in other reports, most

bronchial adenomas were carcinoid (31 of 35). The other 4 were bronchial cylindromas.

Of the 31 patients with carcinoid tumors, regional lymph node metastases were found at operation in 7 patients. Two of these also had distant metastasis, one to

FIG. 1C. Carcinoid tumor. Uniform cells with dark-staining nuclei arranged in an orderly pattern.



the liver and one to bone. Three other patients had evidence of local perivascular and peribronchial lymphatic invasion or vascular invasion without lymph node metastasis. One patient was not operated upon, but had hepatic metastasis, proved by percutaneous liver biopsy. Therefore,

more than one-third of the patients with carcinoid tumors (11 of 31) had extension of the primary tumor initially.

All 3 patients with the cylindromatous type of bronchial adenoma treated surgically had metastases. One patient had extensive lymph node metastases, and the

TABLE 1. *Clinical Manifestations in 35 Patients With Bronchial Adenomas*

Symptom	No. Patients
Cough	25
Hemoptysis	21
Pneumonia	12
Bronchitis	9
Pleurisy	7
Wheezing	5

other 2 showed perivascular and peribronchial lymphatic invasion. One patient with a bronchial cylindroma was not operated upon, but extension into both major bronchi was demonstrated by bronchoscopic biopsies. In all, 16 of 35 patients (46%) were known to have local extension or metastasis at the time of initial examination or operation.

Clinical Manifestations

Bronchial adenomas are manifested as obstructing lesions of the bronchi, bleeding bronchial masses, locally invasive or metastasizing carcinomas, or physiologically active tumors producing a variety of endocrine syndromes. Some are asymptomatic, being discovered on routine roentgenography of the chest. These tumors grow both intrabronchially and extrabronchially. The extrabronchial component is usually much larger.¹⁴ Growth produces at first partial, and then complete, bronchial obstruction. This causes ventilatory obstruction and prevents normal drainage, eventually leading to suppuration and an airless lung. Clinically, this is manifested by localized wheezing or air-trapping, recurrent purulent bronchitis, bronchiectasis, or pneumonia. Radiologically, one sees a peripheral nodule, a hilar, perihilar, or mediastinal mass, bronchiectasis, pneumonitis, localized emphysema, or atelectasis. Bronchograms and planigrams may show a smooth, convex intrabronchial mass, which may suggest the

TABLE 2. *Major Radiographic Signs in 35 Patients With Bronchial Adenomas*

Sign	No. of Patients
Hilar mass	12
Parenchymal mass	6
Atelectasis	11
Pneumonitis	3
Bronchiectasis	1
Middle lobe syndrome	1
No abnormality	1

diagnosis.^{4, 27} Roentgenologic examination almost always indicates the presence of disease.

Bronchial adenomas are frequently vascular and their propensity to bleed, especially when biopsied, is well known.^{3, 4, 40} Hemoptysis is more common in patients with bronchial adenomas than in those with bronchogenic carcinoma. Three patients in our series bled severely after biopsy of the tumor. Because deaths from exsanguination have followed bronchial biopsy,⁴⁰ some have advocated no biopsy if operation is contemplated.^{3, 4, 40}

Cough and hemoptysis were the most common complaints of our patients. These usually isolated complaints were sometimes associated with other symptoms (Table 1). One-third of the patients recalled one or more episodes of pneumonia and one-fourth complained of recurrent infections of the lower respiratory tract. The duration of symptoms varied considerably. Twenty-two patients (63%) had had symptoms referable to the tumor for one or more years before definitive treatment. One woman had had intermittent hemoptysis for 20 years. Thirty patients had had symptoms for an average of 35.9 months before treatment. In 5 patients, who were asymptomatic, the tumors were discovered on routine roentgenography of the chest.

Carcinoid tumors of the bronchi were first associated with the carcinoid syndrome in 1956.²³ Since then, reported cases have

become numerous. The typical carcinoid syndrome associated with midgut tumors was at first thought to be the product of serotonin, but as new cases were reported the precursors of serotonin (5-hydroxytryptophan and other related substances,³⁰⁻³² as well as histamine,³¹ bradykinin,²⁴ and other vasoactive amines have been discovered which modify the symptoms of the syndrome. This has been particularly true of the foregut carcinoids, of which the bronchial carcinoids are a member.⁴¹ Because of this, it has been hypothesized that carcinoids of the foregut are less differentiated, and therefore, have a greater endocrine potential than those in the midgut or hindgut.³⁸

The carcinoid syndrome, first clearly defined by Thorson and associate,³¹ is a complex clinical syndrome which is constantly changing as multiple hormones produced by the carcinoid are identified and their functions are elucidated. In brief, the syndrome is characterized by episodic symptoms which vary in duration and are caused by the circulation of physiologically active substances from the tumor. In addition, the patient has continuous symptoms, which result from structural changes caused by prolonged exposure to these agents. The transitory symptoms are flushing of the face, neck, chest, and arms in various hues, sweating, tachycardia, pruritus, paresthesias, edema of the hands and face, asthma, diarrhea, hyperperistalsis, and vasomotor collapse. The permanent features may include hyperemia and edema of the face, neck, and hands, and endocardial fibrosis, particularly on the right side of the heart.

Hepatic metastases produce the carcinoid syndrome in carcinoids within the portal system. Serotonin is detoxified by the liver and lungs, and only with hepatic metastases can sufficient serotonin spill into the systemic circulation from intestinal carcinoids to cause this syndrome. Detoxification of serotonin by the lungs explains the

TABLE 3. *Bronchoscopic Observations in 30 Patients*

Pathology	No. of Patients
Neoplasm	24
Granulation tissue	2
Suppuration	2
Occluded bronchus	1
None	1

predilection of endocardial fibrosis for the right side of the heart. The endocrine substances and tumor emboli of bronchial carcinoids pass, however, directly into the systemic circulation without passing through the liver or lungs. This explains why metastases from bronchial carcinoids are frequently found in organs other than the liver, particularly skin and bone. It also explains why bronchial carcinoids can produce the carcinoid syndrome without hepatic metastases¹⁸ and why endocardial fibrosis has been found isolated to the left side of the heart with these tumors²⁴

The presence of circulating serotonin without evidence of the carcinoid syndrome has been reported,³⁷ and patients with sustained elevation of serotonin may have only intermittent symptoms. For this reason, it has been suggested that urine tests for 5-hydroxyindolacetic acid, the final breakdown product of serotonin, should be more widely used in the patients with pulmonary tumors. Levels of 5-HIAA may be normal in patients with the carcinoid syndrome,⁶ probably because the syndrome is mediated through other related substances or because degradation is by other pathways.

It has been suggested that the argentaffin cell is a common cell of origin for both the carcinoid and islet cell tumor. Histologic, embryologic, physiologic, and clinical data support this concept.³⁸ If this is the case, one might expect bronchial carcinoids to produce glucagon, insulin, and gastrin, as well as serotonin and the multitude of other hormones which have reportedly been pro-

TABLE 4. *Method of Treatment in 35 Patients With Bronchial Adenomas*

Treatment	No. Patients
Resection	
Pneumonectomy	16
Bi-lobectomy	2
Lobectomy	13
Segmental excision	2
Radiation	1
No treatment	1
	—
Total	35

duced by bronchial and other foregut carcinoids. Hypoglycemia has been demonstrated in several patients with bronchial carcinoids, and in one of these patients, insulin was isolated from the primary tumor and its hepatic metastasis.³³ Hyperglycemia^{21, 32} has been reported in many patients with bronchial carcinoids, but this manifestation is difficult to evaluate because of its many causes. The concentration of glucagon isolated from the intestinal mucosa closely follows the distribution of argentaffin cells.³⁵ Gastrointestinal ulceration is more common in the carcinoid syndrome²¹ and in bronchial carcinoids.³⁰ This may be explained by the production of histamine,^{22, 31} 5-hydroxytryptophan³² (a serotonin precursor which causes gastric ulceration in rats,¹⁷ or gastrin³³ by the tumor).

Bronchial and other foregut carcinoids have been implicated in the production of ACTH or ACTH-like hormones,¹⁶ melanocyte stimulating hormone,²⁴ possibly anti-diuretic hormone,^{1, 21} the catechol amine-epinephrine and norepinephrine,²⁴ bradykinin,²⁴ and other kinins and histamines.^{16, 22} In addition, bronchial carcinoids have been associated with multiple endocrine adenomatoses²; this association suggests that carcinoids also react to the unknown stimulus responsible for the hyperplasia and adenomas found in this syndrome. It has been stated that if a patient has a pulmonary tumor and an endocrine syndrome, think of

a bronchial carcinoid. Perhaps this should be restated: if a person has an endocrine syndrome of unknown cause, search for a bronchial or foregut carcinoid.

Mucoepidermoid and cylindromatous tumors have not been found to produce hormones. Bradykinin has been implicated, however, in mediating some atypical symptoms of the carcinoid syndrome, particularly flushing.²⁴ This substance is normally produced by salivary and sweat glands, and therefore, might be found in salivary gland tumors or their bronchial counterpart (cylindromas). Bronchial carcinoids are sometimes described as having adenocystic or cylindromatous elements. Perhaps these are the cells responsible for the production of bradykinin and the other kinins in atypical carcinoid syndromes.

Urinary 5-hydroxyindolacetic acid (5-HIAA) concentration was determined in 8 patients in our series. The only patient who had a positive reaction had the carcinoid syndrome. Another patient on whom no specific endocrine studies were performed had known hepatic metastasis and died after 6 months with symptoms of the carcinoid syndrome (intractable diarrhea, flushing of the face, neck, and chest, tachycardia, sweating, and edema of the face). Thus, 2 of the 31 patients with carcinoid tumors exhibited the carcinoid syndrome.

A hilar mass was the most common radiographic observation (Table 2). Such a mass is expected to be common, since bronchial adenomas are centrally located and grow both intrabronchially and extrabronchially. The complications of bronchial obstruction—atelectasis, pneumonitis, bronchiectasis, and the middle lobe syndrome—were repeatedly noted. In 6 patients the only finding was radiographic evidence of a peripheral parenchymal mass. In one patient no abnormality was demonstrated in the roentgenogram of the chest but a lesion was visualized only at bronchoscopy.

Bronchoscopy was performed in 30 of the

35 patients (Table 3). In all except one pathologic changes were visualized. A definite neoplasm was seen in 24 patients, whereas in 5 occluded bronchi, suppuration, or granulation tissue was observed. Biopsies were obtained in 22 of the 24 patients in whom neoplasms were visualized. In the two exceptions the endoscopist considered the tumor typical of bronchial adenoma and that biopsy was not warranted because of the hazard of bleeding. In every instance histologic examination of the biopsy specimen proved the lesion to be bronchial adenoma. Brisk bleeding from the biopsy site was common. Although 3 patients had such profound bleeding as to cause concern, the bleeding progressively diminished and soon stopped in each instance.

Treatment

Because of the poorly understood natural history of these tumors, the treatment employed varies widely. Although transbronchoscopic removal has been suggested, in only 10 per cent of patients is the tumor limited to the bronchus.¹³ Since rarely can cure be expected from endobronchial excision, this operation should be resorted to only for palliation in debilitated patients. No patient in our series was definitively treated by endobronchoscopic excision. Thirty-three of the 35 had resectional procedures (Table 4). Sixteen had pneumonectomies. Excision of one or two lobes made possible complete removal of the lesion and the distal pulmonary parenchyma in 15, and in 2 segmental excision eliminated the disease. Only 2 patients were not treated surgically. One, an 80-year-old man with severe heart disease, was not treated; he died 4 years later of pneumonia due to obstruction by the bronchial adenoma. The other was a woman with a cylindroma of the carina and both mainstem bronchi. Three months after supravoltage irradiation, bronchoscopic biopsy showed no evi-

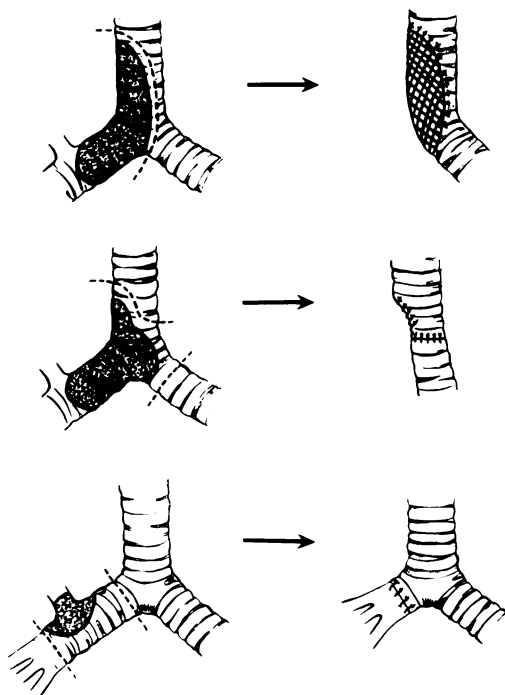


FIG. 2. Tracheal and bronchoplastic procedures performed in removal of bronchial adenomas. (Top) Resection of tumor involving trachea and right mainstem bronchus with reconstruction by replacement of the tissue defect with a prosthetic mesh. (Center) Bronchial adenoma involving trachea and right mainstem bronchus. Reconstruction by primary closure of defect in trachea and suture of left mainstem bronchus to end of trachea. (Bottom) Bronchial adenoma involving right mainstem bronchus. Reconstruction by anastomosis of intermediate bronchus to trachea after sleeve resection.

dence of endobronchial lesions. She has had no further treatment.

As much functioning pulmonary tissue as possible should be preserved. An effort has been made in this direction at our institution. During the first 10 years which this study encompassed, 14 of 15 patients undergoing excisional therapy had pneumonectomies. In contrast, during the past 11 years, except for cylindromatous lesions involving the trachea, bilobectomy, lobectomy, or segmental resection has been sufficient to remove the tumor. Tracheoplastic and bronchoplastic procedures are helpful in preserving pulmonary function and often are necessary for the preservation of

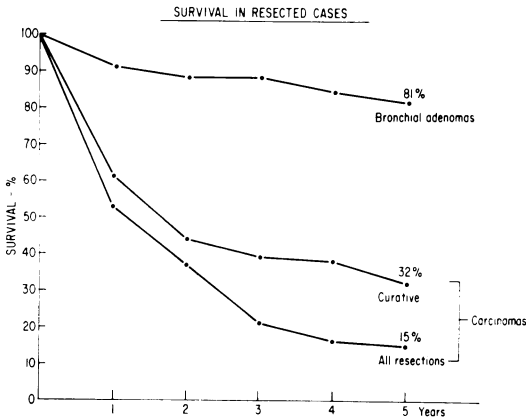


FIG. 3. The absolute 5-year survival curve of the surgically treated patients with bronchial adenoma compared with patients who underwent resection for carcinoma of the lung. Comparison is made between all those undergoing resections, and those undergoing curative resection for carcinoma of the lung, with all those undergoing resection for bronchial adenoma.

life. Three patients had such procedures (Fig. 2). Two had large cylindromatous tumors involving the right mainstem bronchus, trachea, and carina; the involved trachea and right lung were excised. In one patient the defect in the tracheal wall was sutured directly, and the left mainstem bronchus was anastomosed to the reconstructed trachea. In these 2 patients the involved trachea and right lung were excised. The third bronchoplastic procedure consisted of removal of the right upper lobe along with sleeve resection of the mainstem bronchus and a portion of the intermediate bronchus. The intermediate bronchus was then anastomosed to the trachea. In performing tracheal resections, we have found it unnecessary to employ extracorporeal circulation, anesthesia and ventilation being maintained through a sterile bronchial tube maneuvered within the operative field.

In patients with the carcinoid syndrome, as much of the primary and as many of the metastatic deposits as possible should be removed, for the prognosis depends on the amount of functioning neoplastic tissue.

Hepatic lobectomy may be necessary to reduce the serotonin levels.⁶

Because bronchial adenomas are essentially radioresistant, irradiation offers little chance of cure. Local irradiation of cylindromas has some palliative effect,¹⁴ and can be used to decrease production of serotonin in hepatic metastasis.⁶ Radon seed implantation¹⁴ through the bronchoscope in patients with bronchial carcinoids has resulted in palliation for 10 to 20 years in a number of patients, but recurrence has been the rule. In one patient in our series the tumor was controlled for 20 years after implantation of radon seeds. The patient eventually required pneumonectomy and died from distant metastases 6 years after the operation. The only other patient treated by irradiation, mentioned earlier, had a cylindroma of both major bronchi and the carina and received supravoltage radiation to this area.

Chemotherapeutic control of bronchial adenomas has not been advocated. The list of chemotherapeutic agents used to control the carcinoid syndrome include cytotoxins given systemically or by hepatic artery catheterization, serotonin antagonists, tryptophan antagonists, kinin antagonists (particularly chlorpromazine), and adrenocortical hormones which have been

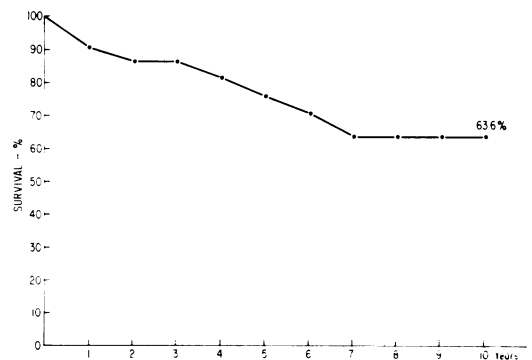


FIG. 4. The calculated cumulative survival for the 35 patients with bronchial adenoma is charted for a period of 10 years.

the most widely used and successful.^{6, 24} Nonallergenic diets have also been used.⁵ All of these methods have occasional success in patients in whom palliative resection was impossible.

Results

There were 2 operative deaths among the 33 patients who had resectional procedures (6%). One death resulted from disruption of a tracheal prosthesis and sepsis 10 days after operation. The other was due to massive cerebral infarction. On examination of the operative specimen, tumor could be seen occluding the lobar pulmonary vein, and ligation of this structure obviously dislodged tumor into the systemic circulation.

Four patients died as the result of diffuse metastatic disease, 1, 4, 6, and 7 years after pneumonectomies. Two patients died of unrelated causes 2 and 16 years after operation. Two patients are known to have metastases 8 and 18 years after operation. The remaining 23 patients are apparently well. One patient who did not receive treatment died from pneumonia 4 years after bronchoscopic diagnosis.

The absolute 5-year survival rate among patients with bronchial adenoma and those with carcinoma of the lung treated surgically differs greatly (Fig. 3). Since excision of bronchial adenomas is considered curative, a better comparison would be between the curative resections of carcinoma of the lung and all resections of bronchial adenoma. There still remains a great discrepancy in survival rates, and for this reason the two groups of tumors should be classified separately.

To date 7 (21%) of the 34 patients on whom we have complete follow-up data have died as the result of the bronchial adenoma. Since, however, 2 are known to be alive with metastatic disease, and since the follow-up period is short in a number of patients, a calculated cumulative survival is more representative of the true his-

tory of this disease. The cumulative survival at 10 years is 63.6 per cent (Fig. 4).

Summary

The cause of bronchial adenomas remains obscure. Experimental observations of others, as well as personal observations in one case, have led us to hypothesize that the epithelial proliferations often seen after chronic inflammatory diseases of the lung, tumorlets, and bronchial carcinomas may represent varying stages of development of the same lesion.

Thirty-five patients with bronchial adenomas have been seen at the Ochsner Clinic in the 20-year period ending in 1966. During the same time 2,953 patients with pulmonary neoplasms were seen, an incidence of 1.2 per cent. Thirty-one adenomas were carcinoids and 4 cylindromas. Eleven carcinoids and all of the cylindromas were malignant with evidence of metastases or local invasion. Two patients had the carcinoid syndrome.

Cough, hemoptysis, pulmonary suppuration, or incidental roentgenographic demonstration of the lesion were the most common clinical manifestations. Surgical extirpation was the only curative treatment, although irradiation provided palliation in some patients. Because of slow growth and tendency to metastasize late, large lesions involving major bronchi and the trachea should be removed, even if tracheoplastic and bronchoplastic procedures are required. The 10-year cumulative survival rate in our series was 63.6 per cent.

References

1. Askergren, A. and Hillenius, L.: Bronchial Adenomas and the Carcinoid Syndrome. *Acta Med. Scand.*, 175:43, 1964.
2. Ballard, H. S., Fame, B. and Hartsock, R. J.: Familial Multiple Endocrine Adenoma-Peptic Ulcer Complex. *Medicine*, 43:481, 1964.
3. Batson, J. F., Gale, J. W. and Hickey, R. C.: Bronchial Adenomata. A Clinical Résumé. *Arch. Surg.*, 92:623, 1966.
4. Bower, G.: Bronchial Adenoma. A Review of Twenty-eight Cases. *Amer. Rev. Resp. Dis.*, 92:558, 1965.

5. Breneman, J. C.: Bronchial Carcinoid. Report of a Case with Features of a Food Allergy. *Ann. Allerg.*, 21:101, 1963.
6. Brindley, G. V., Jr. and Bonnet, J. D.: Bronchial Adenoma and the Carcinoid Syndrome. *Ann. Surg.*, 165:670, 1967.
7. Driessens, J. *et al.*: L'Adénome Pulmonaire Expérimental à L'uréthane de la Souris Swiss. *Etudes Histologique et Cytologique. Bull. Ass. Franc. Cancer*, 50:171, 1963.
8. Felton, W. L., II, Liebow, A. A. and Lindskog, G. E.: Peripheral and Multiple Bronchial Adenomas. *Cancer*, 6:555, 1953.
9. Feyrter, F.: Zur Normung der Silberimpragnation Neuraler und Nichtneuraler Gewebe. *Virchow Arch. Path. Anat.*, 320:551, 1951.
10. Feyrter, F.: Zur Pathologie des Argyrophilen Helle-Zellen-Organen im Bronchialbaum des Menschen. *Virchow Arch. Path. Anat.*, 325:723, 1964.
11. Feyrter, F.: Über die Peripheren Endokrinen (Parakrinen) Drüsen des Menschen; Einführendes Referat. *Krebsarzt*, 13:169, 1958.
12. Gilman, R. A., Klassen, K. P. and Scarpelli, D. G.: Mucous Gland Adenoma of Bronchus; Report of Case with Histochemical Study of Secretion. *Amer. J. Clin. Path.*, 26:151, 1956.
13. Goodner, J. T.: The Malignant Nature of So-Called Bronchial "Adenoma." *Med. Trial Techn. Quart.*, 11:37, 1964.
14. Goodner, J. T., Berg, J. W. and Watson, W. L.: The Nonbenign Nature of Bronchial Carcinoids and Cylindromas. *Cancer*, 14:539, 1961.
15. Hamperl, H.: Über Gutartige Bronchialtumoren (Cylindrome und Carcinoid). *Virchow Arch. f. Path. Anat.*, 300:46, 1937.
16. Harrison, M. T. *et al.*: Cushing's Syndrome with Carcinoma of Bronchus. *Lancet*, 1:23, 1957.
17. Haverback, B. J. and Bogdanski, D. F.: Gastric Mucosal Erosion in the Rat Following Administration of the Serotonin Precursor, 5-Hydroxytryptophan. *Proc. Soc. Exp. Biol. Med.*, 95:392, 1957.
18. Joseph, M. and Taylor, R. R.: Argentaffinoma of the Lung with Carcinoid Syndrome. *Brit. Med. J.*, 2:568, 1960.
19. Kephart, S. B., Jackson, C. E. and Caylor, H. D.: Argentaffinoma (Carcinoid) in Benign Cystic Ovarian Teratoma: Report of a Case. *Obstet. Gynec.*, 15:93, 1960.
20. Kramer, R.: Adenoma of Bronchus. *Ann. Otol.*, 39:689, 1930.
21. MacDonald, R. A.: A Study of 356 Carcinoids of the Gastrointestinal Tract. Report of Four New Cases of the Carcinoid Syndrome. *Amer. J. Med.*, 21:867, 1956.
22. Majcher, S. J. *et al.*: Carcinoid Syndrome in Lung Cancer. *Gastroenterology (Abstr.)*, 48:832, 1965.
23. Mattingly, T. W.: Functioning Carcinoid Tumor-new Clinical Entity; Review of Clinical Features of Nonfunctioning and Functioning Carcinoid, Including Review of 38 Cases from Literature. *Med. Ann. D. C.*, 25:304, 1956.
24. Melmon, K. L., Sjoerdsma, A. and Mason, D. T.: Distinctive Clinical and Therapeutic Aspects of the Syndrome Associated with Bronchial Carcinoid Tumors. *Amer. J. Med.*, 39:568, 1965.
25. Mikail, M. and Sender, B.: Nodular Epithelial Hyperplasia (Tumorlets) of the Lungs. Report of a Case. *Amer. J. Clin. Path.*, 37:515, 1962.
26. Müller, H.: Zur Entstehungsgeschichte Der Bronchialerweiterungen. *Inaug. Diss. Vol. 15 (Halle)*, Ermsleben A. H., 1882.
27. Ochsner, S. and Ochsner, A.: Bronchial Adenomas: Problems in Diagnosis and Treatment with Particular Reference to Roentgenologic Aspects. *Southern Med. J.*, 50:1089, 1957.
28. Orr, J. W.: Induction of Pulmonary Adenomas in Mice by Urethane. *Brit. J. Cancer*, 1:311, 1947.
29. Payne, W. S. *et al.*: The Surgical Treatment of Cylindroma (Adenoid Cystic Carcinoma) and Mucoepidermoid Tumors of Bronchus. *J. Thorac. Cardio. Surg.*, 38:709, 1959.
30. Sandler, M., Scheurer, P. J. and Wat, P. J.: 5-Hydroxytryptophan-Secreting Bronchial Carcinoid Tumour. *Lancet*, 2:1067, 1961.
31. Sandler, M. and Snow, P. J.: An Atypical Carcinoid Tumour Secreting 5-Hydroxytryptophan. *Lancet*, 1:137, 1958.
32. Schneckloth, R. E., McIssac, W. M. and Page, I. H.: Serotonin Metabolism in Carcinoid Syndrome with Metastatic Bronchial Adenoma. *JAMA*, 170:1143, 1959.
33. Shames, J., Dhurandhar, N. R. and Blackard, W. G.: Insulin Secreting Bronchial Carcinoid Tumor with Widespread Metastasis. (In Press).
34. Smetana, H. F., Iverson, L. and Swan, L. L.: Bronchogenic Carcinoma; Analysis of 100 Autopsy Cases. *Mil. Surgeon*, 111:335, 1952.
35. Sutherland, W. E. and de Duve, C.: Origin and Distribution of the Hyperglycemic-Glycogenolytic Factor of Pancreas. *J. Biol. Chem.*, 175:663, 1948.
36. Thorson, A. H. *et al.*: Malignant Carcinoid of Small Intestine with Metastases to Liver, Valvular Disease of Right Side of Heart (Pulmonary Stenosis and Tricuspid Regurgitation without Septal Defects), Peripheral Vasomotor Symptoms, Bronchoconstriction, and Unusual Type of Cyanosis; Clinical and Pathologic Syndrome. *Amer. Heart J.*, 47:795, 1954.
37. Warner, R. R., Kirschner, P. A. and Warner, G. M.: Serotonin Production by Bronchial Adenomas without the Carcinoid Syndrome. *JAMA*, 178:1175, 1961.
38. Weichert, R., Reed, R. and Creech, O., Jr.: Carcinoid-Islet Cell Tumors of the Duodenum. *Ann. Surg.*, 165:660, 1967.
39. Weiss, L. and Ingram, M.: Adenomatoid Bronchial Tumors. A Consideration of Carcinoid Tumors and Salivary Tumors of the Bronchial Tree. *Cancer*, 14:161, 1961.
40. Wilkins, E. W., Jr. *et al.*: A Continuing Clinical Survey of Adenomas of the Trachea and Bronchus in a General Hospital. *J. Thorac. Cardio. Surg.*, 46:279, 1963.
41. Williams, E. D. and Sandler, M.: The Classification of Carcinoid Tumours. *Lancet*, 1:238, 1963.