

# Neuroblastoma: Natural History and Results of Treating 133 Cases \*

JOSEPH FORTNER, M.D., ANTHONY NICASTRI,\*\* M.D.,  
M. LOIS MURPHY, M.D.

*From the Departments of Surgery, Pediatrics, and Pathology, Memorial Hospital for Cancer and Allied Diseases, New York City*

NEUROBLASTOMA is seldom manifest before its extent is massive or metastases are distant from the primary site. Efforts to control the lesion are therefore usually those reserved for advanced cancer. An occasional patient has survived without definitive treatment or after therapeutic attempts have been abandoned. This tendency for spontaneous growth control seems to have been activated in some instances by partial or complete removal of the primary tumor.<sup>8, 9</sup>

This paper reports 10 years' experience at Memorial Hospital in managing patients with neuroblastoma. Of particular concern is further evaluation of the efficacy of the removal of the primary tumor even in the presence of diffuse metastatic disease.<sup>8, 9</sup> An attempt has been made to define those features of the cancer or characteristics of the patient which are associated with survival.

## Materials and Methods

The records of all patients with a diagnosis of "Neuroblastoma," who were admitted to Memorial Hospital from July 1, 1951 to June 30, 1961 were reviewed. Histologic slides of tissue obtained at opera-

tion or necropsy were re-examined. Failure to obtain material for re-evaluation and changes in the histologic diagnoses of some led to rejection of 54 records from the group classified as "neuroblastoma" in the hospital files. There remained 133 cases for detailed review.

The cancers were graded on a scale from I to III in general accordance with the system of Poore *et al.*<sup>11</sup> as modified by Horn.<sup>8</sup> In the least differentiated or grade III tumors, the structure was small cells with essentially no discernible cytoplasm or stroma (Fig. 1). If rosettes were present, a subclassification, IIIr was employed. In grade II or the intermediate group, the cells were separated by a finely fibrillar, eosinophilic stroma (Fig. 2). In grade I, ganglion cells were present. The appearance may approach that of ganglioneuroma (Fig. 3, 4), but true ganglioneuromas were excluded. Tumors in which Grade I structure was prominent might have been designated as ganglioneuroblastomas. Olfactory or esthesioneuroblastomas were also excluded.

The grade of a particular tumor was not decided on the basis of the least differentiated element seen. Rather, varying levels of differentiation in a given tumor were recorded as a summation of grades, i.e., grade I + II + III. Sampling precluded an attempt to determine what proportion of a given tumor each grade comprised.

The time of onset of disease was arbitrarily chosen as the beginning of symptoms which subsequently proved to be due

---

Submitted for publication June 1, 1967.

\* Presented at New York Surgical Society November 1967.

\*\* Present address: State University of New York, Downstate Medical Center, Brooklyn, New York 11203.

Supported in part by Public Health Service Traineeship, C S T, 174-64 from the Cancer Control Program.

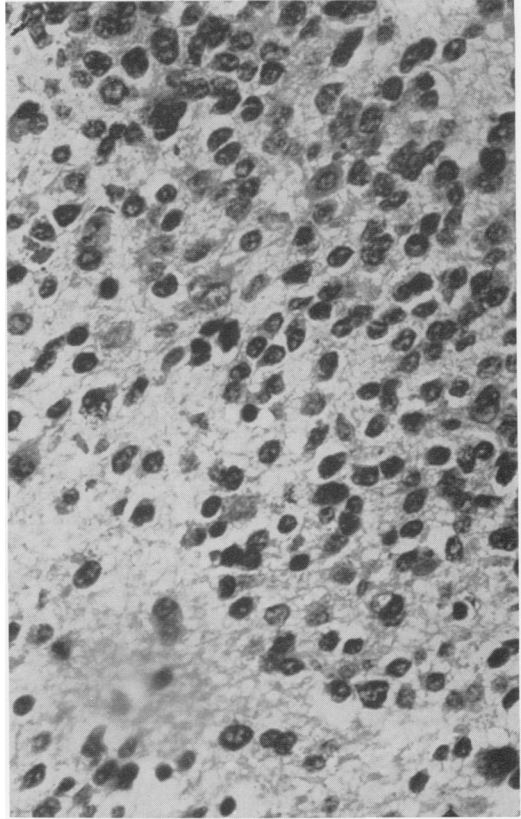
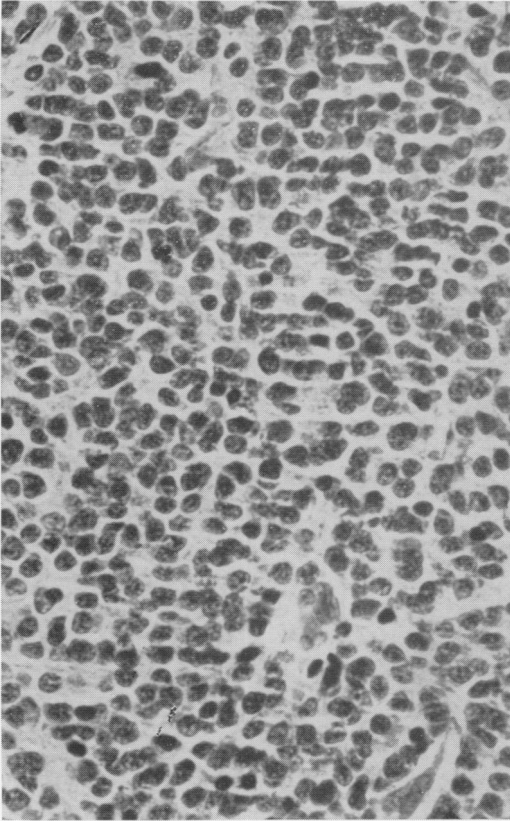


FIG. 1. Grade III neuroblastoma. Note absence of discernible cytoplasm and scanty stroma. Case II, Table 3. Nine year survivor after bone metastasis. H & E  $\times 200$ .

FIG. 2. Grade II neuroblastoma. Note abundant fibrillary stroma. Another area from tumor illustrated in Fig. 1. H & E  $\times 320$ .

to the neuroblastoma. Clinical and laboratory findings evaluated were those recorded at the time of first definitive treatment. The data were tabulated and subjected to statistical analyses. Information on excretion of catecholamines and vanillylmandelic acid is not included.

**Results**

**Age and Sex.** Onset of disease was evident most commonly in the first 6 years of life with peak incidence in the first 3 years. Age distribution curves reached a low plane from 6 to 20 years (Fig. 5). Four patients were from 20 to 50 years of age. Males predominated in the series.

**Primary Site.** The site of origin of neuroblastoma could not always be determined

with precision. Table 1 gives an approximation, and includes sites which were evident and estimates of sites made after all information had been considered. The most common areas of origin were adrenals and

TABLE 1 *Primary Site*

Location	Number
Adrenal (Total)	67
Left	39
Right	27
Not specified	1
Retroperitoneal (Other)	25
Mediastinal	11
Cervical	3
Spinal	4
Pelvic	5
Undetermined	18
<b>Total</b>	<b>133</b>

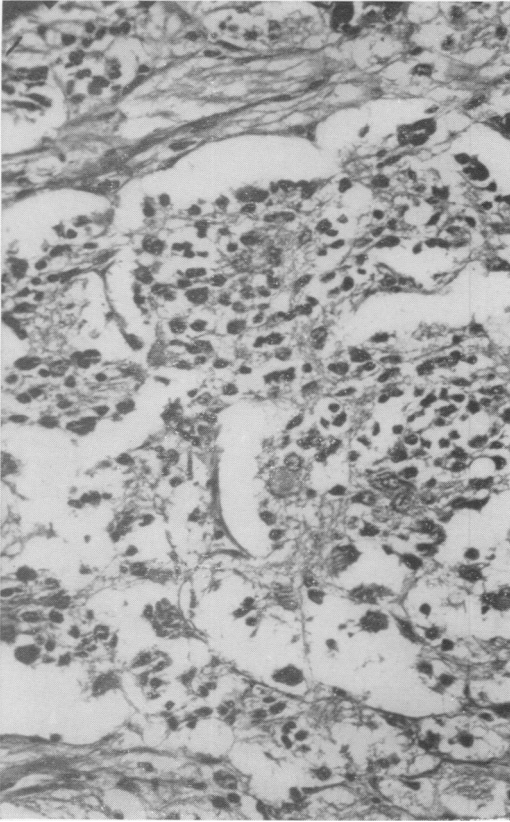


FIG. 3. Grade I neuroblastoma. Ganglion cells are present, as well as small undifferentiated cells. Case 6, Table 3. Eight year survivor with adrenal primary, extensive lymph node and skeletal metastases. H & E  $\times 200$ .

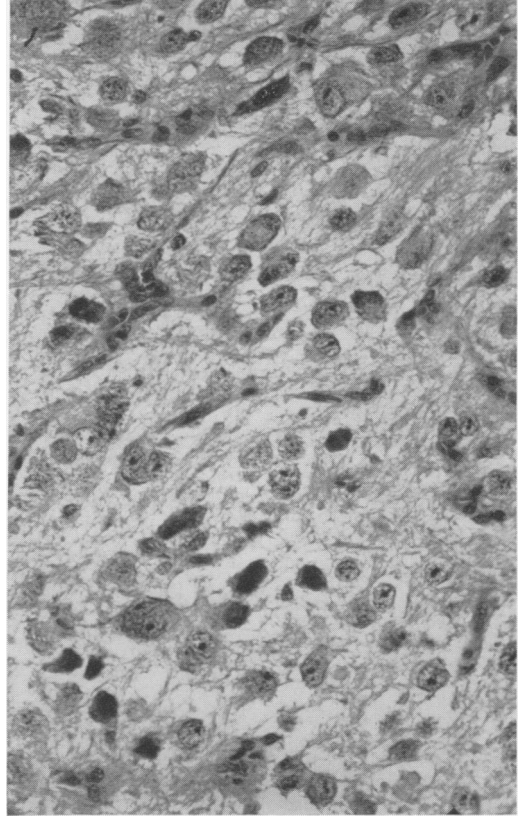


FIG. 4. Another area from tumor illustrated in Fig. 3 in which structure more closely simulates ganglioneuroma. H & E  $\times 200$ .

other retroperitoneal regions followed by the mediastinum. It was impossible to estimate the primary site in 18 instances. These findings generally conform to those published by other authors.<sup>2, 5, 6, 8, 10, 11</sup>

**Histologic Grade.** Sixty-five or 48.9% of the tumors showed no evidence of differentiation beyond the presence of rosettes. The remainder showed both maturing and undifferentiated areas. The scatterdiagram of Figure 6 indicates that poorly differentiated cancers were seen in all age groups but differentiation tended to occur in tumors of younger children. There was no relationship between histologic grade and sex in patients who died. Nine surviving patients were females and in all but one

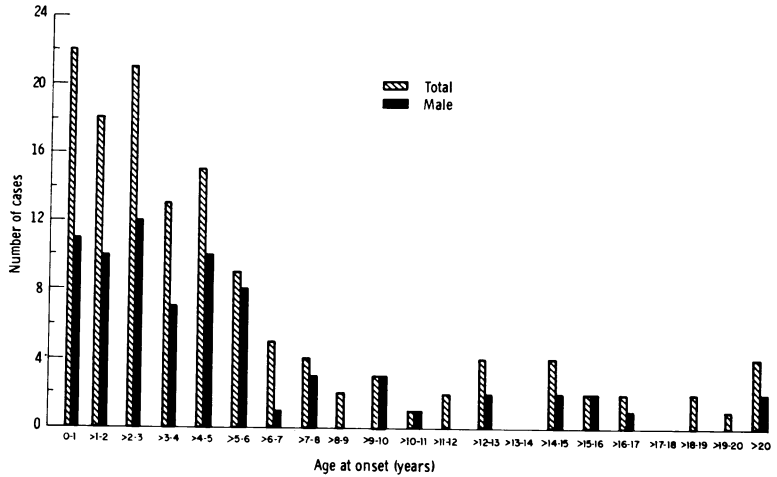
there was extensive maturation of the tumors. All four males who survived had tumors which appeared mature.

Table 2 gives the histologic grade of cancers in 25 patients who had regionally confined disease on admission. Ten of the 25 tumors showed no significant differentiation.

**Bone Marrow.** Extrinsic cancer cells were found in the marrow of 50 patients at the time of admission. One or more examinations were negative in 66 patients, and there was no record of this investigation in 17.

Fourteen patients with neuroblastoma cells in bone marrow were reported as having no roentgen evidence of metastases to bone. Contrariwise, skeletal metastases demonstrable by x-rays were not always associated with cells in the marrow. Of 71

FIGURE 5.



patients with skeletal metastases, 34 had positive marrows, 30 had negative marrows, and in seven instances this data was not available. In 25 patients whose disease was clinically confined to one area, only two had positive marrows; in three, the status of bone marrow was unknown and in 20, the marrows were considered negative. Twenty-eight patients had soft tissue or visceral metastases without demonstrable bone metastases on admission. Twelve of these had positive marrows and 16 had negative marrows.

**Treatment.** A general policy during the time encompassed by this review was that all children with neuroblastoma should receive radiation therapy and chemotherapy in addition to surgical management of the primary lesion. The primary lesion was removed *in toto* if possible or in part, oft-times piecemeal, if necessary. Surgical resection was carried out even in the presence of widespread metastases. The child's physical condition was the only limiting factor.

**Complete removal of the primary tumor** was carried out in 11 patients. The adrenals were the primary site in seven, the pelvis in one, juxta-renal region in one and the head and neck region in two. Ten of the 11 had metastases or extensive local invasion. Preoperative radiation therapy was

given to four patients to decrease the size of massive tumors. Three of these were given a preoperative course of nitrogen mustard in addition to the x-ray therapy.

The kidneys were removed with the primary tumors in three patients. A portion of the pancreas was excised with the kidney of one of these and in another a segment of inferior vena cava was removed. Two of the 11 patients whose tumor was excised, were operated upon elsewhere before being referred to Memorial Hospital.

**Partial removal of the primary tumor** was accomplished in 27 patients. In these, the adrenals were the primary sites in 14, periaortic regions in six, mediastinum in four, pelvis in two and the neck in one. Six of the 27 patients had massive local disease precluding complete removal. The remainder had metastases to bones, viscera, bone marrow, usually combined with massive local disease. Twenty patients did not receive preoperative radiation or chemotherapy. Of seven who received preoperative x-ray therapy, two received chemotherapy in addition to radiation. Actinomycin Dactinomycin was used in both instances. Twenty-one patients received postoperative radiation therapy and chemotherapy. One received postoperative x-ray therapy without chemotherapy. Three patients had only chemotherapy postopera-

TABLE 2. *Histologic Grade of Regionally Localized Cancers*

III	IIIr	III + II	III + II + I	III + I	II + I	
6	4	8	4	1	2	Localized
31	34	36	25	3	4	Total patients
$\frac{10}{65}$	15.3%			$\frac{15}{68}$	22.0%	% With differential

tively. One patient had no postoperative treatment and one was an operative death. Eight patients had partial removal of tumor elsewhere before being referred here.

Biopsies were the only surgical procedures on primary tumors of 42 patients. The sites of primary neuroblastomas conforms to the overall group. Twenty-nine patients had extensive skeletal or soft tissue metastases usually in addition to massive local tumor. Nine had extensive local disease at time of biopsy without evident metastases. Twenty-two of the 42 were operated upon and biopsied elsewhere before being referred for radiation and chemotherapy. Disease was so extensive that with a histologic diagnosis available, further operation was deemed unnecessary. Only one patient received preoperative radiation. And one received HN2 (methyl bis

beta chlorethyl amine hydrochloride) Actinomycin Dactinomycin and methotrexate before operation.

No biopsies or operations were performed on the primary tumors of 53 patients in whom histologic diagnosis was made by biopsy of a metastatic lesion. In many instances, the primary site was unknown. Radiation therapy and a variety of chemotherapeutic agents were given.

**Complications.** Substantial bleeding was encountered in attempts to remove extensive cancers in some instances. Complete removal of one primary neuroblastoma was associated with a tear in the inferior vena cava. This was controlled and the course was otherwise uneventful. Slow oozing from the tumor bed for several days followed operation in another patient with complete removal of the primary lesion. One operative death resulted from massive laceration of the aorta produced in an attempt at removal of an extensive tumor. A second operative death followed uncontrolled bleeding during attempts at removal of a neuroblastoma. One patient with thrombocytopenia had persistent oozing from the wound for several days after partial removal of a tumor. A subsequent pancreatic fistula closed spontaneously.

**Survival Rates.** Ninety per cent (108) of the 119 patients who died of neuroblastoma succumbed within a year of onset of symptoms. Eighty-three (69.7%) died within 6 months of initial symptoms. No patient who lived for 5 years has died subsequently. Three patients died between the fourth and fifth year after onset of symptoms.

Table 3 shows details of the 13 or 9.7%

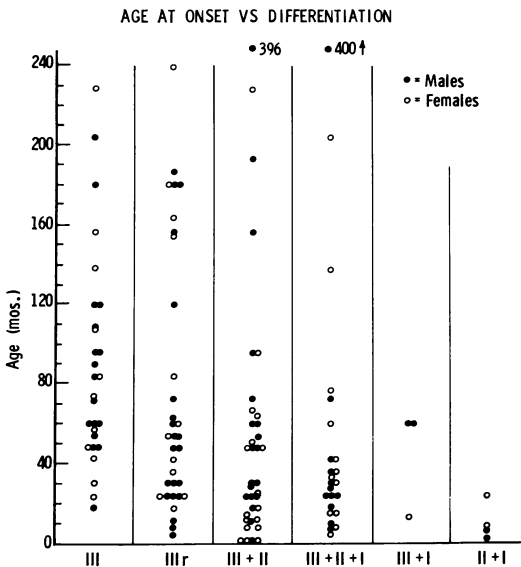


FIGURE 6.

of the 133 patients who survived 5 or more years after the onset of symptoms. There appears to be random distribution insofar as age is concerned. Nine of the 58 females (15.5%) survived 5 or more years in contrast to 4 of 75 males (5.3%) who survived 5 or more years. When subjected to the Chi Square test, these differences are not statistically significant.

Survival appears directly related to the kind of surgical treatment given (Table 4). Complete removal of the primary tumor resulted in the best prognosis even though such patients had extensive local disease or metastases. Four of 11 patients (36.3%) in this group were long term survivors (Cases 2, 6, 9, 10, Table 3). Five of 27 (18.5%) who had partial removal of the primary neuroblastoma survived more than 5 years (Cases 1, 7, 8, 11, 13, Table 3). Four of the five had extensive metastatic disease in addition to massive local tumor. Two of 42 who had only biopsy of the primary tumor were long-term survivors. One patient with an extensive mediastinal tumor was treated by radiation therapy and given cyclic doses of methotrexate for 5 years (Case 3, Table 3). A second patient had a tumor involving only the spinal cord. Two laminectomies and a biopsy were performed. Radiation therapy was given in an unknown amount elsewhere. The child is paraplegic (Case 12, Table 3). Two of 53 patients whose primary lesion was undisturbed surgically lived more than 5 years. One patient is a true spontaneous regression (Case 4, Table 3, Fig. 7). She received no chemotherapy other than a small amount of metacorten for 2 weeks (Fig. 5). A second received extensive radiation therapy in addition to chemotherapy (Case 5, Table 3). Another patient whose primary site was unknown had excision of a presumed solitary metastasis in the cheek. No other treatment was given and the patient was well when last seen, 4 years after treatment.

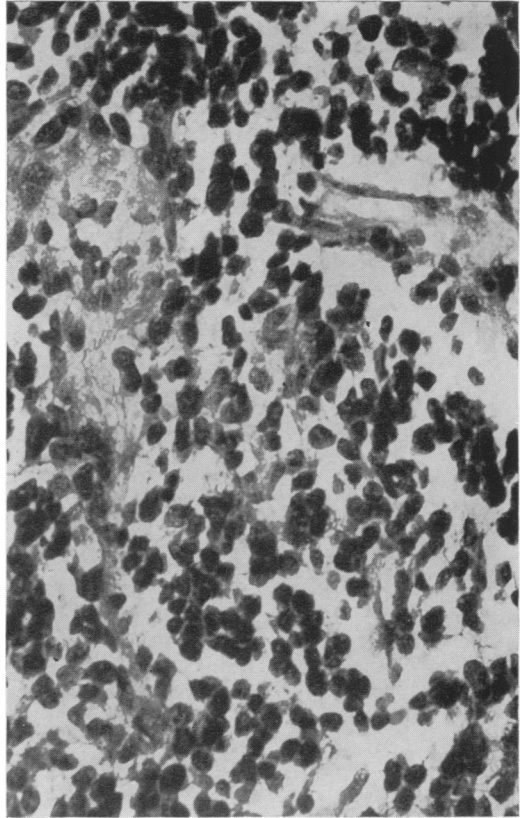


FIG. 7. Poorly differentiated neuroblastoma in an inguinal lymph node biopsy. Case 4, Table 3. True spontaneous regression. Nine year survivor. H. & E.  $\times 320$ .

Differentiation of the tumor was related to survival in that only one patient survived of 65 with a neuroblastoma histologically grade III (Table 5). This patient showed rosette formation in an otherwise undifferentiated lesion.

Particularly interesting is survival of four of 71 (5.6%) patients with skeletal metastases. Soft tissue or visceral metastases without bone metastases carried a similar prognosis. One of 28 (3.6%) such patients survived. Nine of the 25 with disease confined to one area lived 5 or more years. No patient with extrinsic cancer cells in the bone marrow lived 5 years.

An analysis was made of 21 patients who survived more than 15 months but less than 5 years after onset of symptoms. More pro-

TABLE 3.

Age at Onset	Sex	Histology	Primary Site	Regional Spread	Metastases	Surgery	X-Ray	Chemotherapy*	Survival	Current Status
8 mos.	F	III-II	Adrenal (left)	Extensive Extra-dural Spinal cord paralysis	Extradural	Partial removal primary 9/59	3700 r.T.D. in 7 wks. to T11-L3; 2100 r.T.D. in 4 wks. T3-T10 600 r.T.D. in 4 wks. to C2-T10	HN2, Medrol initially. Methotrexate for several months	6 yrs. N.E.D.	Flaccid paralysis lower extremities; urinary and fecal retention
6 yrs. and 2 5 mos.	F	III-II-I	Juxta-renal	Vena cava, kidney, abdominal wall, mesentery	0	Complete removal with narrow margin of resection 2/58	Preop -2000 r.T.D. in 21 days upper abdomen	None	7.5 yrs. N.E.D.	Right leg cooler and larger than left
1 yr. and 2 mos.	F	III-II	Mediastinum	Extensive mediastinal	0	Thoracotomy and biopsy 4/51	4000 r.T.D. in 2 courses medias-tinum	Methotrexate 1.25 mg. daily for 10 days. Off 2 wks. and then recycle for 5 years	13.5 yrs. N.E.D.	Scoliosis with retraction of rib cage
5 days	F	III-II	Adrenal ? (left)	? Liver, ? abdomen	Lymph nodes, subcutaneous nodules	Excisional biopsy inguinal node-1956	None	Metacorten for 2 wks.	9 yrs. N.E.D.	Normal
13 yrs.	F	IIIr	Mediastinal ?	Extensive mediastinal; pleural effusion	T10, T11, L2, 6th, 7th ribs. Probably mediastinal adenopathy	Excisional biopsy 10th rib 7/58	Cobalt-25 rads x4, 50 rads x3; 2960 r.-1 mev. chest	HN2 10 mg. intrapleurally; 2 courses Coley's toxin; Metacorten for several mos.	7 yrs. N.E.D.	Fibrosis of lung, some scoliosis
5 mos.	F	III-II-I	Adrenal (right)	None	Lymph nodes in axillae and mediastinum; 3-4 ribs, left femur, extradural	Right adrenal-ectomy 4/59	Preop 4500 r.T.D. spine	Preop-HN2 3, 4 mg. I.V.; Methotrexate 1.25 mg. intermittently for several wks.	8 yrs. N.E.D.	Paraplegia, incont. urine, bright, cheerful

TABLE 3. (Cont.)

Age at Onset	Sex	Histology	Primary Site	Regional Spread	Metastases	Surgery	X-Ray	Chemotherapy*	Survival	Current Status
13 mos.	F	III-I	Mediastinum?	Upper chest with extension into supra-clavicular region	?Cervical lymph nodes	Complete removal in two stages 2/58 and 5/58	Preop. 2465 r. T.D. lt. hemithorax, mediastinum	Preop. Act. D-75 $\gamma$ /Kg. in each of 2 courses	8 yrs. N.E.D.	Left Horner's syndrome & left phrenic paralysis
5 yrs.	F	III-II-I	Adrenal (left)	None	Skull and subcutaneous tissue of head	Partial removal 1/56	Postop. skull and abdomen, factors unknown	HN2 4.5 mg. I.V. $\times$ 2 Methotrexate 1.25 mg. 10 days on and 10 days off for 2½ yrs.	9 yrs. N.E.D.	Scoliosis. Diminished hearing
16 mos.	F	III-II-I	Neck	None	Multiple lymph node in neck	Radical neck dissection 2/56	None	None	9 yrs. N.E.D.	Speech difficulties; asymmetry of face
8 mos.	M	III-II-I	Pelvis	Massive buttock and pelvic mass	None	Complete excision of pelvic mass 8/56	Preop. 2000 r. T.D. pelvis	Preop. HN2 IV $\times$ 2 Postop. Methotrexate 1.25 mg. daily for 2 wks. and off 2 wks. cycle for 4 yrs.	9.5 yrs. N.E.D.	Shortness of leg; Talipes equinovarus
2 yrs. and 3 mos.	M	III-II-I	Adrenal (left)	Extensive retroperitoneal and mediastinal	Rt. mandible and mediastinum	Retropitoneal mass partially removed 1/57	Postop. chest and upper abdomen 2190 r.T.D.; mandible 1160 r.T.D.	Act. D 1,350 $\gamma$ IV in 4 doses. Orally 2-3 mg. daily for 14 mos.	9 yrs. N.E.D.	I.V.P. calcification. Left kidney not functioning
21 mos.	M	II-I	Spinal canal	Soft tissue 2" lateral to vertebral column	None	2 laminectomies and biopsy '53	2,000 r. to cord recommended	None	5 yrs. +	Paraplegia. Uses crutches and braces
2 mos.	M	III-II	Pelvis	None	None	Partial excision '51	15 treatments to pelvis	Methotrexate for 2 mos.	14 yrs. N.E.D.	Normal

\* Actinomycin D, Dactinomycin Cosinegen® Merck  
Methotrexate® Lederle  
HN2 Methyl bis betachlorethylamine hydrochloride Mustargen® Merck  
Prednisone Meticorten®  
Methotrexate amethopterin



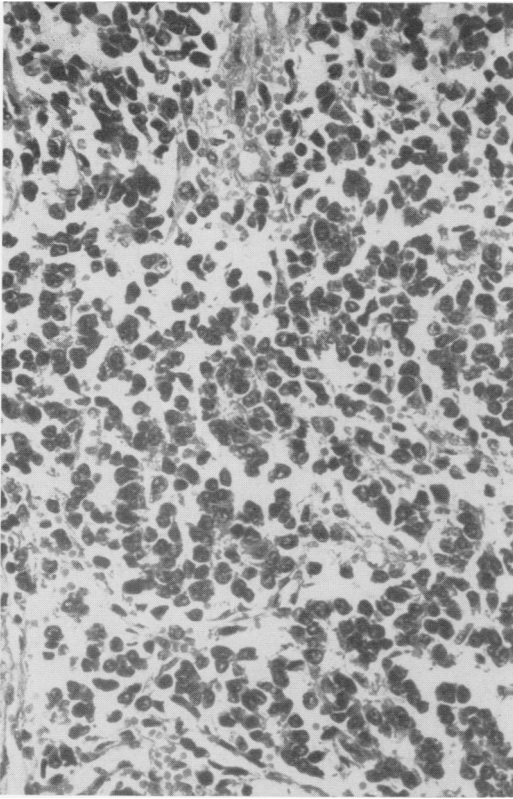


FIG. 8. Rosettes in an Ewing's sarcoma, histologically simulating neuroblastoma. H. & E.  $\times 200$ .

longed survival was not relatable to their age, sex, tumor grade, or treatment.

**Pitfalls in Differential Diagnosis.** A group of cases was encountered which deserves special attention because of the stress placed on the pathologist in differential diagnosis. These were patients with skeletal lesions which appeared to be primary bone tumors, e.g., Ewing's sarcoma, but which histologically resembled neuroblastoma. An illustrative case is that of K. W., an 8-year-old girl who developed an irregular, osteolytic lesion of the left femur involving the mid-portion of the neck and extending down the proximal third of the shaft. The irregular lytic destruction involved mainly the medullary area. The cortex was thickened in areas and there was no bone production or calcification. The periosteum was markedly thickened but seemed destroyed in some areas with bone spicules protruding into

adjacent soft tissue. An incisional biopsy was performed on November 11, 1959 and a histologic diagnosis of metastatic neuroblastoma was made (Fig. 8). Detailed work-up including intravenous pyelograms was negative for other sites of tumor. A tumor dose of 3510 r was given in 21 days with the 1,000 KV to the entire femur. Recurrence in the femur was demonstrated on December 13, 1962. On December 20, 1962 an exploratory laparotomy revealed no primary or metastatic cancer. A hemipelvectomy was performed. The patient has subsequently remained well more than 4 years.

The possibility of an extraosseous neuroblastoma which regressed before the bone lesion became clinically evident cannot be excluded in this case. Rosettes have been demonstrated in otherwise acceptable Ewing's sarcoma.<sup>3, 4</sup> The histogenesis of the current lesion is conjectural but it seems likely to be primary sarcoma of bone.<sup>7</sup>

Differentiation of neuroblastoma from other poorly differential sarcoma may also be a problem, e.g., embryonal rhabdomyosarcoma, reticulum cell sarcoma.

### Discussion

The main determinants of survival of patients with neuroblastoma in this series are the degree of differentiation of the tumor, and the treatment received. The predominance of females in survivors is not statistically significant. Histologic gradation of the tumors is important in a negative sense in that without differentiation beyond rosettes only one patient survived 5 or more years. There is a trend (Table 5) toward better survival with increasing differentiation of the tumor but the number of survivors is too small for statistical significance. The presence of a very marked differentiation however, does not guarantee success in treatment.

A majority of patients with neuroblastoma were in a late stage of disease when first seen at Memorial Hospital. Only 6 (4.5%) of the 133 patients in the current



TABLE 5. Relationship of Differentiation of Neuroblastoma to Survival

	Number of patients with tumor grade:						Total
	III	III + r	III + II	III + II + I	III + I	II + I	
Patients dead							
Number	31	33	32*	19	2	3	120
%	25.8	27.5	26.6	15.8	1.6	2.5	
Patients alive							
Number	0	1	4	6	1	1	13
%	0	7.6	30.7	46.1	7.6	7.6	
Total patients with each grade							
Number	31	34	36	25	3	4	133
%	23.3	25.6	27.1	18.8	2.3	3.0	
Proportion surviving with each grade							
Number	0/31	1/34	4*/36	6/25	1/3	1/4	13*/133
%	0	2.9	11.1	24.0	33.3	25.0	9.7

\* An additional patient was well at 4 years, after which she was lost to follow-up.

therapy appeared essential for the management of our cases and there is no obvious deleterious effect on host resistance which might be present. The mechanism by which arrest of disease occurs with complete or partial removal of a primary tumor with extra-regional metastases intact is obscure.

There is no clear explanation for the prolonged survival of 21 patients living more than 15 months but less than 5 years. Twelve of the survivors were males and nine were females. They belonged, however, to an older age group. It is possible that the tumors had a slower doubling time than in more short-lived patients.<sup>1</sup>

Survival rates must be viewed against a natural background of spontaneous regression which this disease manifests. A search for morphologic evidence of host resistance was made but none was identified. Only one of 133 patients clearly demonstrated spontaneous regression. This child was completely untreated. Other survivors, particularly those with skeletal metastases may be examples of spontaneous growth control. They were vigorously treated however, so that this factor cannot be evaluated. Even so, the number of these patients is rather high for natural cure.

Most long-term survivors have physical defects of varying severity. Scoliosis and

paraplegia are the most common deformities (Table 3). Neurological changes seem to be a residue of damage caused by the tumor. Skeletal and pulmonary abnormalities are probably secondary to treatment although one child has a congenital talipes equinovarus.

#### References

- Collins, V. P., Loeffler, R. K. and Tivey, H.: Observations on Growth Rates of Human Tumors. *Amer. J. Roentgenol.*, 76:988, 1956.
- Dargeon, H. W.: Neuroblastoma. *J. Pediat.*, 61:456, 1962.
- Foote, F. W., Jr. and Anderson, H. R.: Histogenesis of Ewing's Tumor. *Amer. J. Path.*, 17:497, 1941.
- Gharpure, V. V.: Endothelial Myeloma (Ewing's Tumor of Bone). *Amer. J. Path.*, 17:503, 1941.
- Gross, R. E., Farber, S. and Martin, L. W.: Neuroblastoma Sympatheticum. *Pediatrics*, 23:1179, 1959.
- Horn, R. C., Koop, C. E., and Kiesewetter, W. B.: Neuroblastoma in Childhood: Clinicopathological Study of 44 Cases. *Lab. Invest.*, 5:106, 1956.
- Hutter, R. V. P., Foote, F. W., Jr., Francis, K. C. and Sherman, R. S.: Primitive Multipotential Primary Sarcoma of Bone. *Cancer*, 19:1, 1966.
- Koop, C. E. and Hernandez, J. R.: Neuroblastoma: Experience with 100 Cases in Children. *Surgery*, 56:726, 1964.
- Koop, C. E., Kiesewetter, W. B. and Horn, R. C., Jr.: Neuroblastoma in Childhood. Survival after Major Surgical Insult to Tumor. *Surgery*, 38:272, 1955.
- Phillips, R.: Neuroblastoma: Hunterian Lecture. *Ann. Roy. Coll. Surg.*, 12:29, 1953.
- Foore, T. N., Dockerty, M. B., Kennedy, R. J. and Walters, W.: Abdominal Neuroblastoma. *Surg. Clin. N. Amer.*, 31:1121, 1951.