

# Intestinal Ischemic Syndromes

JOHN J. BERGAN, M.D., LAURENCE DRY, M.D.,  
JULIUS CONN, JR., M.D., OTTO H. TRIPPEL, M.D.

*From the Department of Surgery, Northwestern University Medical School,  
Chicago, Illinois 60611*

*"Since abdominal angina is curable with appropriate surgical correction and is almost invariably fatal otherwise, physicians have an obligation to look for it."*

WEHRMACHER

DESPITE an explosive accumulation of knowledge concerning vascular reconstruction, experience in surgery of the intestinal arteries remains sparse. Reports from vascular centers and from individuals with experience in cerebral, renal and peripheral revascularization indicate the paucity of knowledge about intestinal ischemic syndromes.<sup>14, 19</sup> While these conditions are not rare, difficulty in uncovering them is often due to failure to include intestinal ischemia in the differential diagnosis of a patient with atypical abdominal pain.<sup>21</sup>

Operative surgery of the intestinal arteries has now arrived at a frontier. Sufficient clinical investigation has been correlated with laboratory data to form new concepts. These require that ancient dicta be put aside. In this category is the idea that two or more intestinal arteries must be compromised before symptoms of intestinal ischemia supervene. While this is true, the cases cited below and reports of others are proof that distinct syndromes of single artery intestinal ischemia exist.<sup>1</sup>

Operative surgery for acute occlusion of the mesenteric circulation has also reached a cross road. It is no longer acceptable merely to resect ischemic bowel without attempts at revascularization.<sup>16</sup> The acknowledged 85 per cent mortality of resectional therapy for acute mesenteric artery

occlusion can be reduced to 25 per cent or less if revascularization is done.

Furthermore, it is clear that a non-definitive diagnosis of mesenteric vascular occlusion is no longer tenable. Surgeons must distinguish between embolic, thrombotic, and nonorganic occlusions, each of which is manifested in a distinct fashion, carries a particular prognosis and requires specific therapy. Mesenteric embolus, for example, is relatively easily diagnosed before bowel gangrene occurs.<sup>2</sup>

This report describes experience with 22 patients subjected to intestinal arterial revascularization over an 8-year period ending January 1, 1968. Not all of these patients would be operated upon today nor would an identical operation be performed currently. Analysis of these cases justifies classification into distinct visceral ischemic syndromes (Table 1). The syndromes do not include rare causes of arterial occlusion such as those due to trauma and do not differentiate between intraluminal blockage and that due to extrinsic compression.

## Clinical Material

All patients requiring intestinal arterial reconstruction treated by the authors during the study period are included in the present report. There were 22 patients, 13 with acute and nine with chronic intestinal ischemic syndromes. Sixteen patients were men. The age range was from 36 years of age in one patient with mesenteric arterial embolus to 77 years in one patient with chronic celiac axis stenosis. Nine patients with chronic occlusive lesions averaged 60.9 years of age and 6 were men. Thirteen patients with acute occlusions aver-

---

Submitted for publication April 30, 1968.

Supported in part by NIH Grant No. 2-RO1-HEO9153-04.

aged 65.8 years in age and 10 were men. Associated conditions were frequent. In order of occurrence these were arteriosclerotic heart disease, peripheral arterial occlusions, diabetes and hypertension.

A single intestinal artery was reconstructed in each case, in chronic as well as acute occlusions. Six of nine patients with chronic occlusions required celiac axis repair while three others had reconstructions of the superior mesenteric arteries. All patients with acute intestinal arterial occlusions had superior mesenteric arterial repair. The acute occlusions were embolic in eight cases, thrombotic in three and non-organic in two.

In a discussion of results, patients under study are divided into two groups, chronic and acute. Chronic occlusions are subdivided into patients who had celiac arteries repaired and those who had superior mesenteric arteries reconstructed. Acute occlusive lesions are divided further into embolic, thrombotic or non-organic etiologies and differences in these groups are emphasized.

#### Chronic Celiac Axis Occlusion

Although 10 patients had chronic celiac axis occlusions, only six had a combination of symptoms and angiographic findings which were believed to require operation. One patient is illustrative: This 48-year-old woman had a combination of history, physical findings, and angiographic picture which suggested the syndrome described by Marable.<sup>4</sup> She had a 3-year history of postprandial abdominal pain, a 30-pound weight loss, postprandial vague epigastric tenderness and hyperactive bowel sounds. An upper abdominal bruit was heard. Malabsorption was absent as shown by a normal d-xylose absorption and excretion test. Hypoglycemia was documented on several occasions. The gastrointestinal roentgenographic survey was negative, but the lateral aortogram showed stenosis of the origin of the celiac axis.

She was relieved of postprandial pain by an aorta to splenic artery bypass graft. She

TABLE 1. *Intestinal Ischemic Syndromes*

	Patients
Chronic intestinal ischemia	
Celiac axis occlusion	6
Superior mesenteric occlusion	3
Acute intestinal ischemia	
Embolic occlusion	8
Thrombotic occlusion	3
Non-organic occlusion	2
Total	22

has been examined regularly for 3 years during which time most of her gastrointestinal symptoms have subsided and she has gained weight.

Patients with celiac axis occlusions ranged from 48 to 77 years in age with all but one being men. Four of the six had severe atherosclerotic coronary or peripheral arterial insufficiency. In three, the peripheral disease was sufficiently severe to require correction. Marked weight loss in all patients ranged from 10 to 60 pounds. Pain was a common symptoms, appearing in four of the six patients. In all pain was related to food intake and varied in intensity with the time of eating. Pain was mid-abdominal, cramp-like, aching and resembled the squeezing pain of claudication. Although two patients had abnormal glucose tolerance curves, the remainder had few positive diagnostic findings. A retrospective review of records confirmed the difficulty of diagnosis.

Profound weight loss in an otherwise normal person with an upper abdominal bruit and miscellaneous digestive complaints is suggestive of ischemia of the splanchnic circulation. The diagnosis can be confirmed on lateral aortography. Catheter aortograms are most revealing. Early in this experience translumbar aortograms were done and were satisfactory.

Operative repair in each patient has been curative. An 8 mm. dacron aorta to hepatic artery graft was placed in three instances. Aorta to splenic artery bypass was done twice. In one patient removal of the celiac ganglion and stripping of con-

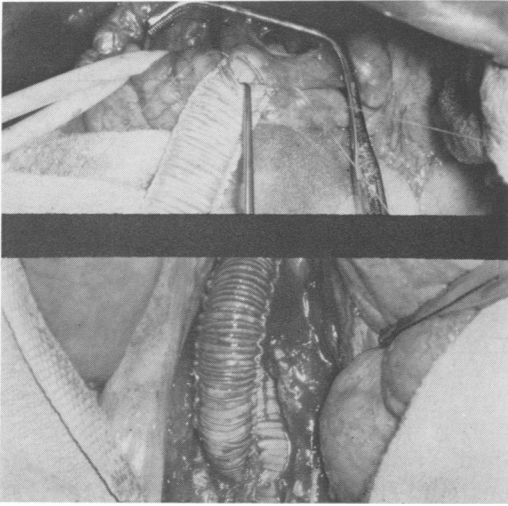


FIG. 1. This composite operative photograph shows the aorta to splenic artery bypass being constructed. The lower photo shows its aortic graft origin and the upper indicates the final graft to artery anastomosis.

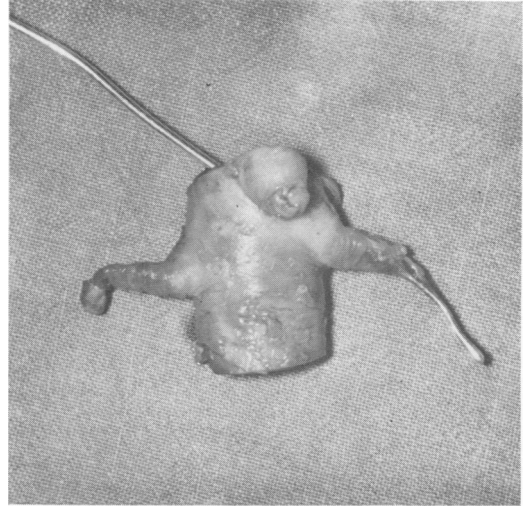


FIG. 2. This photograph shows an intact surgical specimen resulting from a simultaneous bilateral renal, superior mesenteric, and aortic thromboendarterectomy. Note the near total occlusion of the superior mesenteric artery.

strictive bands about the celiac axis removed the pressure gradient. In another, ganglionectomy of the celiac axis was performed, and this abolished the pressure gradient. In the latter two instances, operative arterial pressure measurements were most helpful in directing surgical therapy.

One patient illustrates the occasional accelerated development of intestinal ischemic symptoms. This 77-year-old man had symptoms of postprandial abdominal pain, profound weight loss and dehydration following resection of an abdominal aortic aneurysm. A large inferior mesenteric artery was ligated at the time of aneurysmectomy. The patient had been convalescing at home but was re-admitted in a cachectic state. Within 6 weeks of operation, total weight loss was 18 pounds and dehydration, inanition and anemia had developed.

The lateral aortogram showed a constriction of the origin of the celiac axis but no abnormality of the superior mesenteric artery. An aorta to splenic artery bypass was constructed. The aortic limb took origin from the dacron graft used to replace the abdominal aortic aneurysm (Fig. 1). Following this the patient rapidly gained 14

pounds and postprandial pain was relieved. Extensive malabsorption evaluation was negative before and after operation. Three similar cases have been reported by Gonzalez.<sup>7</sup>

#### Chronic Superior Mesenteric Artery Occlusion

Three patients, two men and one woman, underwent reconstruction of superior mesenteric arteries. In two, endarterectomy was performed (Fig. 2). In one, an aorta to mesenteric graft was done. This is the favored technic today. The men were 62 and 63 years of age, and the woman was 58. In two patients mesenteric artery repairs were performed in conjunction with renal artery reconstructions for renovascular hypertension. One of these patients has been a subject of a previous report.<sup>18</sup>

Symptoms of superior mesenteric artery insufficiency are illustrated by the following patient. For several years, this 58-year-old woman experienced diffuse abdominal distress. This increased in severity rapidly over a three-week period prior to admission, during which time there had been an 8-pound weight loss. The mid-abdominal discomfort occurred after eating, and the

severity of pain was proportional to the size of the meal. An epigastric systolic bruit was present, but all other physical findings were normal.

A transfemoral aortogram showed stenosis of the origin of the superior mesenteric artery. An aortomesenteric arterial graft corrected the 15 mm. Hg pressure gradient across the stenosis. Post operative aortogram showed the graft patent and functioning. The patient had complete remission of her symptoms.

A review of the records of these three patients and of others studied for intestinal ischemia fails to disclose a common pattern of symptoms, signs and laboratory findings. The authors agree with Marston and with Dick *et al.*, that "the only consistent feature of this anatomical lesion is the variability of its symptoms!"<sup>5, 16</sup>

#### Acute Embolic Occlusion

Superior mesenteric arteries were acutely occluded by emboli in 8 cases. These patients were 36 to 75 years of age. The one woman had auricular fibrillation secondary to rheumatic heart disease. Two men had embolization from aortic valvular prostheses. One embolus in another patient followed cardioversion, another occurred during an acute arrhythmia, and another developed 3 months after a myocardial infarction. The other patients had advanced arteriosclerotic cardiac disease with congestive failure or auricular fibrillation.

Clinical manifestations in these patients included rapid onset of abdominal pain, vomiting and diarrhea, leukocytosis, a history of prior embolization and an obvious source for the embolus.

In patients who had embolectomy within 30 hours of embolization, bowel resection was avoided. One died of fulminant hepatitis but the others are alive and well up to 5 years postoperatively. One case illustrates the features of mesenteric artery embolization.

This 53-year-old man was admitted with a 6-hour history of severe cramping abdominal pain, vomiting and non-bloodly




FIG. 3. These photographs show the superior mesenteric artery embolus which was removed in the case described. Note the similarity of the clot to the annulus of the aortic prosthesis.

diarrhea. A MacGovern aortic valvular prosthesis had been implanted one year previously. In the interval, he had peripheral emboli to the femoral artery, aortic bifurcation and right cerebral hemisphere. The initial white blood count was 18,000 but other laboratory tests were normal.

The mesenteric artery embolus which was removed immediately assumed a crescentic shape similar to the configuration of the valve annulus (Fig. 3). Bowel resection was not done. He had no diarrhea or intestinal malabsorption postoperatively. The patient has been given anticoagulant drugs for 2 years without further incident.

Bowel resections were performed in only three patients. In one, the embolus was removed and a 30 cm. segment of bowel was immediately resected. In another, embolectomy restored very little bowel circulation. At a second look procedure 8 hours later, the entire small bowel except for 8 inches of jejunum was removed with the cecum, ascending and one-half of the transverse colon. This patient survived and under rigid dietary control has lost no weight.<sup>22</sup> The third patient, a 75-year-old man with an atypical onset survived initial embolectomy without bowel resection. He then sustained a femoral embolus and survived that

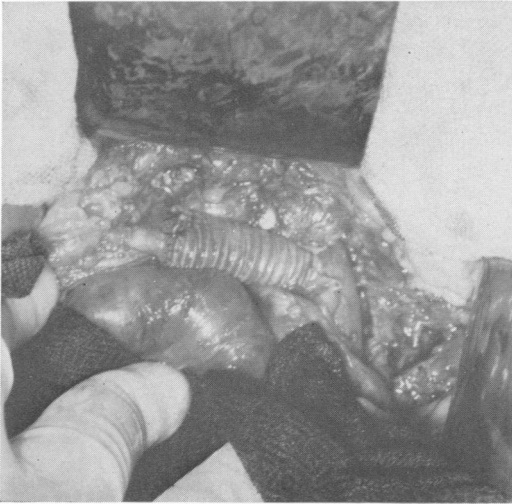


FIG. 4. This operative photograph shows a bypass graft placed from aorta to superior mesenteric artery. The occlusion of the artery at its origin was not removed.

embolectomy. Bowel necrosis developed insidiously many days later and the patient died of inanition following intestinal resection.

#### Acute Thrombotic Occlusion

Although nine patients were operated upon with acute thrombotic occlusions of the superior mesenteric arteries, only three appeared suitable for intestinal revascularization. In one, a 69-year-old woman, endarterectomy restored mesenteric blood flow but the bowel did not regain viability. In another, a 63-year-old woman, bowel viability was restored but the patient died suddenly 5 hours postoperatively.<sup>1</sup> In a third, a 75-year-old man, an aorto-mesenteric arterial graft restored bowel blood flow. However, the patient regurgitated ingested liquid which he aspirated on the seventh postoperative day. He died of pneumonia on the ninth day.

A 75-year-old man was comfortable without digestive complaint or weight loss until he developed severe cramping, abdominal pain followed by diarrhea. The relentless pain was followed by vomiting and diaphoresis. Sixteen hours later, a single bloody

stool was passed; there was no abdominal distension and bowel sounds were present. Signs of peritoneal irritation were elicited. Bilateral superficial femoral arterial occlusions were diagnosed by physical findings and a left carotid bruit was also present. Blood pressure was 210/110. The patient appeared cyanotic and extremely sick. Because of persistent severe pain despite 10 mg. of morphine sulfate, bloody diarrhea and vomiting and the absence of heart disease, a diagnosis of mesenteric thrombosis was made rather than mesenteric embolus. This was confirmed at laparotomy and an aortomesenteric graft done with full revascularization of ischemic bowel (Fig. 4).

Review of records of other patients undergoing operation without revascularization failed to suggest a consistent pattern of symptoms which would lead to early diagnosis. Patients are older, have more severe pain, have fewer physical findings, have a higher white blood count, and have more peripheral arterial occlusions than other patients with acute abdominal pain. Only one half had histories of prior abdominal pain related to meals. The common hospital course is one of hydration, gastrointestinal decompression and general physical deterioration before a diagnosis of late mesenteric arterial occlusion is made. Ottiger and Austen noted a lack of success of attempts at revascularization in mesenteric thromboses.<sup>15</sup> Rob's experience has been different and remarkably successful.<sup>17</sup>

#### Non-Organic Splanchnic Occlusion

Some patients appear to have acute mesenteric arterial occlusions but clinical circumstances suggest a non-organic cessation of blood flow. Two such patients were operated upon because of a possibility of a correctable mesenteric arterial occlusion. One case is illustrative of this syndrome of non-organic occlusion.

This 49-year-old man had an acute right visual field defect, pulselessness and loss of blood pressure in the right arm 3 years be-

fore the present admission. At that time thrombosis of the innominate artery had been diagnosed and an aorta to subclavian and right carotid artery bypass was done in another city. The present admission was precipitated by severe progressive cardiac failure and paroxysmal auricular tachycardia complicated by aortic valvular insufficiency. This patient's physician believed for some time that the patient had a chronic dissecting aneurysm which first became manifest as an innominate artery occlusion.

The abdominal complication began with loose stools, abdominal pain, hypotension, rising SGOT, and a leukocytosis of 29,000. While the possibility of non-organic mesenteric occlusion was recognized because of the aortic valvular insufficiency, it also seemed possible that a correctable mesenteric arterial occlusion was present.

The findings at operation were characteristic of non-organic mesenteric arterial occlusion. There was diffuse spasm of the peripheral arterial arcades with no demonstrable mechanical occlusion. Splanchnic blockade and dilation of accessible arteries was ineffective. Autopsy showed a chronic dissecting aneurysm with a double lumen aorta. All visceral arteries and the aortic graft arose from the false outer lumen of the aorta.

This case is more complex than the usual non-organic occlusion but is typical of the difficulty in excluding a surgically correctable lesion. The usual patient has signs of splanchnic ischemia with vomiting, diarrhea, abdominal pain, leukocytosis, and progressive abdominal distention. This is followed by toxicity, fever, and obvious peritonitis.<sup>13</sup> An associated congestive cardiac failure, aortic valvular insufficiency, digitalis intoxication or use of vasopressor drugs facilitate the diagnosis.<sup>6, 8, 9</sup> Operation should be avoided and conservative means used to increase splanchnic flow. Non-surgical therapies include administration of low molecular weight dextran or

continuous epidural block in addition to treatment of the basic cardiac disease.<sup>3, 10</sup>

### Discussion

Several visceral ischemic syndromes can now be defined. These include celiac artery insufficiency, mesenteric artery embolus, and non-organic mesenteric artery occlusion. Less distinct are superior mesenteric arterial insufficiency and superior mesenteric artery thrombosis.

The celiac artery compression syndrome is a new clinical entity.<sup>20</sup> In all patients, pain is common and although variously described, it is usually post-prandial and mid-epigastric. The pain may be so intense as to discourage eating which leads to weight loss. Marable states that all of his patients had epigastric systolic bruits which were not transmitted down the aorta or femoral vessels. His patients were not atherosclerotic and 27 of 30 were women. When the syndrome appears in older individuals, as in the present series, the findings are identical but associated cardiac and peripheral vascular occlusions may aid in suggesting the diagnosis.

Mesenteric arterial embolization must be diagnosed early because it produces acute occlusion of a vascular tree without collateral blood supply. Since the first response of the intestine to ischemia is intense spasm, dramatic manifestations usually appear. The clinical picture is one of catastrophic abdominal pain with forceful vomiting and diarrhea in a patient with a cardiac disease as the source of an embolus. When leukocytosis supervenes and a prior embolic episode has occurred the diagnosis of mesenteric embolization is virtually certain.

Non-organic intestinal arterial occlusion is known to pathologists who see the late effects at autopsy. Shock is the most common clinical setting and vasopressor therapy is a frequent participant. Gastrointestinal bleeding is common and may be accompanied by abdominal pain, fever and

leukocytosis. The course is a pathologic manifestation of a low blood flow state which causes patchy hemorrhagic lesions chiefly involving intestinal mucosa. Although often terminal, there is evidence that some lesions are reversible.<sup>3</sup>

Less specific syndromes of superior mesenteric artery stenosis and thrombosis remain to be defined. Watt<sup>21</sup> suggested that "the characteristic presentation of persistent post-prandial pain in an undernourished male patient who tends to eat small meals and who may be known to have arteriosclerosis constitutes a syndrome which should be readily recognizable as due to ischemia of the mid-gut." In fact, such patients are rare. Morris reported only 31, Rob 18, and Dardik could collect only 18 from world reports.<sup>4</sup> Although rarely diagnosed, atheromata of the mesenteric arteries are common. Even complete occlusions of splanchnic vessels may be incidental autopsy findings. Although aortography is precise and aids in the diagnosis, no other test is sufficiently accurate to designate patients with intestinal angina.

Mesenteric thrombosis remains diagnostically obscure. The late occurrence of ileus, abdominal distension, shock, and sepsis is well recognized. But earlier colicky or steady abdominal pain, with or without vomiting, diarrhea and nausea is too non-specific to indicate surgical operation. Laboratory tests are not suggestive and time is lost to gastrointestinal decompression, rehydration and roentgen studies during which bowel becomes necrotic.

### References

1. Bergan, J. J.: Recognition and Treatment of Intestinal Ischemia. *Surg. Clin. N. Amer.*, **47**:109, 1967.
2. Bergan, J. J.: Recognition and Treatment of Superior Mesenteric Artery Embolization. *Geriatrics* (In Press).
3. D'Angelo, G. J., Ameriso, L. M. and Tredway, J. B.: Survival after Mesenteric Arterial Occlusion by Treatment with Low Molecular Weight Dextran. *Circulation*, **22**:662, 1963.
4. Dardik, H., Seidenberg, B., Parker, J. G. and Hurwitt, E. S.: Intestinal Angina with Malabsorption Treated by Elective Revascularization. *JAMA*, **194**:1206, 1965.
5. Dick, A. P., Graff, R., Gregg, M. C., Peters, N. and Sarner, M.: An Arteriographic Study of Mesenteric Arterial Disease. *Gut*, **8**:206, 1967.
6. Ferrer, M. I., Bradley, S. E., Wheeler, H. O., Enson, Y., Preisig, R. and Harvey, R. M.: The Effect of Digoxin in the Splanchnic Circulation in Ventricular Failure. *Circulation*, **32**:524, 1965.
7. Gonzalez, L. and Jaffe, M. S.: Mesenteric Arterial Insufficiency Following Abdominal Aortic Resection. *Arch. Surg.*, **93**:10, 1966.
8. Heer, F. W., Silen, W. and French, S. W.: Intestinal Gangrene without Apparent Vascular Occlusion. *Amer. J. Med.*, **110**:231, 1965.
9. Hoffman, F. G., Zimmerman, S. L. and Cardwell, W. S., Jr.: Massive Intestinal Infarction without Vascular Occlusion Associated with Aortic Insufficiency. *N. Eng. J. Med.*, **263**:436, 1960.
10. Jackson, B. B. and Lykins, R.: Serial Epidural Analgesia in Mesenteric Arterial Failure. *Arch. Surg.*, **90**:177, 1965.
11. Marable, S. A., Kaplan, M. F., Beman, F. M. and Molnar, W.: Celiac Compression Syndrome. *Amer. J. Surg.*, **115**:97, 1968.
12. Marston, A.: Mesenteric Arterial Disease: The Present Position. *Gut*, **8**:203, 1967.
13. Ming, S. C.: Hemorrhagic Necrosis of the Gastrointestinal Tract and its Relations to Cardiovascular Status. *Circulation*, **32**:332, 1965.
14. Morris, G. C., DeBaKey, M. E. and Bernhard, V.: Abdominal Angina. *Surg. Clin. N. Amer.*, **46**:919, 1966.
15. Ottinger, L. W. and Austen, W. G.: Study of 136 Patients with Mesenteric Infarction. *Surg. Gynec. Obstet.*, **124**:251, 1967.
16. Rob, C.: Stenosis and Thrombosis of the Celiac and Mesenteric Arteries. *Amer. J. Surg.*, **114**:363, 1967.
17. Rob, C. G.: Surgical Diseases of the Celiac and Mesenteric Arteries. *Arch. Surg.*, **93**:21, 1966.
18. Starzl, T. E. and Trippel, O. H.: Reno-mesenteric-aortic-iliac Thromboendarterectomy in a Patient with Malignant Hypertension. *Surgery*, **46**:556, 1959.
19. Stoney, R. J. and Wylie, E. J.: Recognition and Surgical Management of Visceral Ischemia Syndromes. *Ann. Surg.*, **164**:714, 1966.
20. Terpstra, J. L.: Intestinal Angina Secondary to Compression of the Celiac Axis. *Arch. Chir. Neerl.*, **18**:245, 1966.
21. Watt, J. K., Watson, W. C. and Haase, S.: Chronic Intestinal Ischemia. *Brit. Med. J.*, **3**:199, 1967.
22. Zurier, R. B., Campbell, R. G., Hashim, S. A. and Van Italline, T. B.: Use of Medium-chain Triglyceride in Management of Patients with Massive Resection of the Small Intestine. *New Eng. J. Med.*, **274**:490, 1966.