

# The Long-Term Effectiveness of Carotid Endarterectomy in Prevention of Strokes

W. STERLING EDWARDS, M.D., THOMAS A. S. WILSON, M.D.,  
AUSTEN BENNETT, M.D.

*From the Department of Surgery, Medical College of Alabama, Birmingham*

THE OBJECTIVE in surgery for stenosis of the carotid arteries is relief from transient ischemic attacks, reversal or prevention of further progression of neurologic deficit. Enough time has now elapsed since the development of carotid endarterectomy to begin to evaluate the long-term effectiveness of this procedure in meeting these goals. It is also important to examine the durability of patency of the carotid artery after endarterectomy.

## Methods

A series of seventy-five patients operated five to nine years ago (November 28, 1958 to April 15, 1963) have been carefully followed. These individuals ranged from 49 to 76 years of age and there were 66 men and 9 women. This is not a consecutive series, but includes all patients during this period who underwent carotid endarterectomy for transient ischemic attacks, or mild neurologic deficit and who left the hospital after operation with a patent operated artery and either slight or no neurologic deficit. We have eliminated from this study those who died in the hospital postoperatively, those who were operated for a completed stroke, and those who developed hemiplegia or severe neurologic deficit as a result of the operation.

Before surgery an attempt was made to visualize all the major intracranial and ex-

tracranial cerebral vessels arteriographically in each patient. There was great variation in the quality of the examinations during this period as satisfactory technics were being developed. Direct carotid and direct subclavian artery injection, retrograde femoral artery catheterization, right atrial cannulation and injection, and retrograde brachial artery catheter technics were all utilized with varying degrees of success. In each person subjected to operation, however, it was considered mandatory to obtain good visualization at the very least of the carotid bifurcations and as often as possible in two planes so that the degree of stenosis could be grossly quantitated. Endarterectomy was performed only in those arteries with a stenosis of fifty per cent or more.

During the period under consideration most carotid endarterectomies were done under local anesthesia with a 10 minute test period of occlusion of the carotid artery after surgical exposure and after the intravenous administration of 5,000 units of sodium heparin. If the patient tolerated this temporary occlusion, the operation was performed without an internal shunt and without any other method of cerebral protection. Jugular venous oxygen saturation monitoring had not been developed and was not utilized in these early patients but was used extensively in later patients. If syncope or contralateral extremity weakness occurred during the test period, the clamp was quickly released, and an internal shunt was used during a second period

---

Presented before the American Surgical Association, April 17-19, 1968, Boston, Massachusetts.

This work was conducted under U.S.P.H. Grant No. HE-04943.

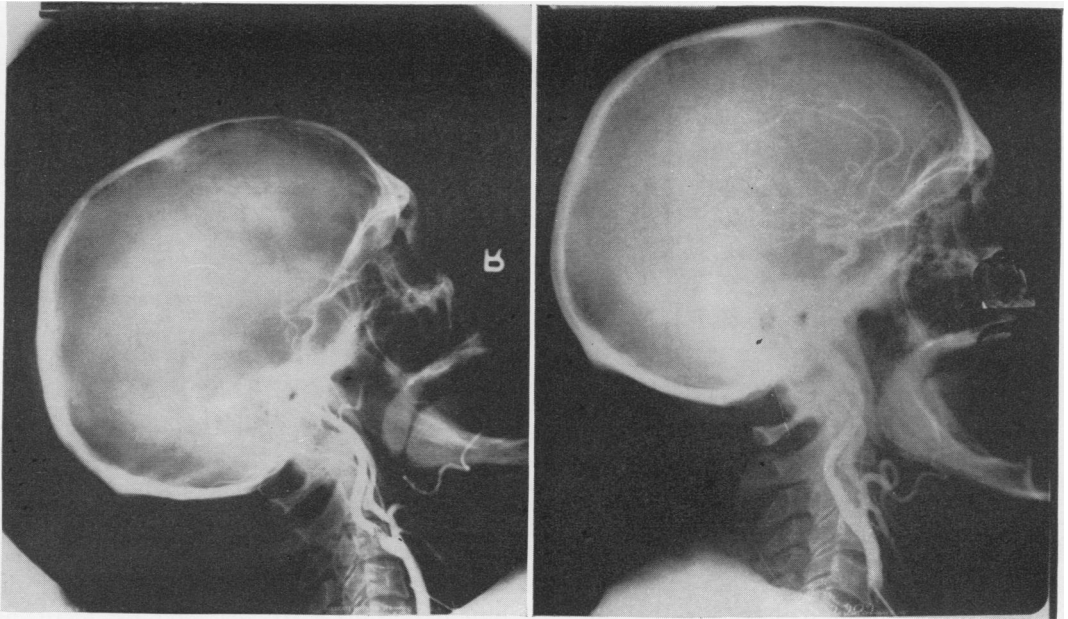


FIG. 1A (left). Preoperative right carotid arteriogram in 1962 showing severe internal carotid stenosis. 1B (right). Follow-up arteriogram in 1967 showing normal lumen at site of endarterectomy.

of carotid clamping for endarterectomy. Fifty-seven patients had unilateral carotid endarterectomies and eighteen patients had bilateral operations, a total of ninety-three arteries. The second side was operated one to several weeks after the first. The arteriotomy was closed with a Teflon patch in 13 arteries and one was closed with a saphenous vein patch. A patch was used only when an internal shunt was required since the incision was necessarily extended further up the internal carotid artery to insert the shunt. If no shunt was used, the incision was kept in the common carotid and the bulb or dilated first centimeter of the internal carotid, and the distal plaque was carefully detached with an endarterectomy spatula. In almost all cases the plaque terminated cleanly with a pointed end, but if there was any uncertainty about leaving a loose flap of tissue, the incision was extended further up the artery. Simple arteriotomies were closed with a 5-0 or 6-0 silk suture, but patches were fixed with synthetic fiber suture. Heparin was always

neutralized by an equal amount of protamine given immediately after restoring flow.

All living patients were brought back for thorough examination. The cause of death was ascertained from the patient's physician or from a death certificate in all patients who had died. A follow-up arteriogram was requested from all patients whose general health did not make this procedure seem hazardous. Those patients who accepted were admitted to the hospital for forty-eight hours and bilateral percutaneous carotid arteriograms were made with anterior-posterior and lateral views of the cervical and intracranial carotid circulation. Arteriography was usually performed under light general anesthesia without endotracheal intubation.

### Results

Follow-up study of these seventy-five patients indicated that thirty-eight (50.6%) were alive and neurologically asymptomatic. Twenty patients (26.6%) developed

postoperative neurological symptoms not present at the time of discharge from the hospital after surgery. Fifteen of these patients (20%) had one or more transient episodes of neurological deficit with complete recovery, while five patients (6.6%) had completed strokes, all of whom had died at the time of this study. Two of these five had had several episodes of progressive neurological deficit prior to death. Of fifteen patients with transient episodes, six had spells of syncope, six had motor weakness of one or more extremities, and three had periods of vertigo. Twenty-two patients (29.3%) had died. Five patients (6.6%) as indicated above had died of acute cerebral vascular symptoms and were thought to have died of a stroke. Fourteen had died of coronary occlusion, and three had died of other causes: one of ruptured abdominal aneurysm four years after carotid surgery, one of pulmonary congestion from multi-valvular disease, and one gastrointestinal hemorrhage.

Thirty patients (forty-three operated arteries) were subjected to follow-up carotid arteriography five or more years after operation. Three patients proved to have significant restenosis which required reoperation of a previously endarterectomized artery. These three patients all developed recurrent symptoms clinically suggesting restenosis before the arteriograms confirmed this. In addition to these three patients there were six other operated arteries with insignificant restenosis of less than 25%, and these patients were asymptomatic. All other visualized arteries (34) were 100% patent. The case histories of three patients with significant restenosis were as follows:

### Case Reports

**Case 1.** A 61-year-old man had transient episodes of blindness of the right eye and numbness of the left arm once a month for six months. Arteriography in December 1962 revealed complete occlusion of the right internal carotid and 80% stenosis of the left internal carotid. Left carotid

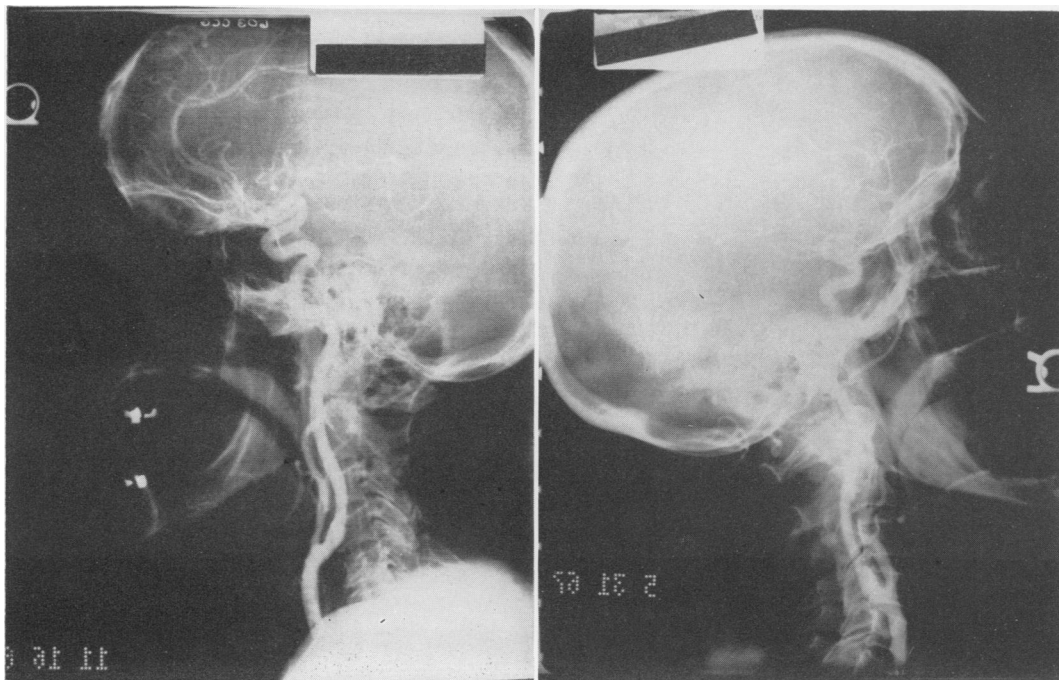


FIG. 2A (left) & B (right). Carotid arteriograms 6 and 7 years after carotid endarterectomy showing normal lumen at operated site.

endarterectomy was done without a patch and he was symptom free until November 1967, when left arm numbness and the left carotid murmur reappeared. Arteriogram in December 1967 revealed the right internal carotid still completely occluded and the left 60% stenotic. Exploration in December 1967 revealed fibrous thickening of the wall of the carotid bifurcation without sclerosis or a cleavage plane of dissection. It was necessary to widen the lumen with a saphenous vein patch. The murmur disappeared and the patient has remained asymptomatic.

**Case 2.** A 49-year-old man gave a history of three months of episodes of transient right arm and leg weakness, aphasia and left eye blindness with memory loss for several hours. He was found to have 95% stenosis of the left internal carotid with only a tiny trickle of dye past the stenosis. The right carotid was normal. Left carotid endarterectomy was done 2/4/63 without a patch and he was asymptomatic until early 1965 when he developed recurrent episodes of right arm and leg weakness but no neck murmur. Repeat arteriogram showed recurrent stenosis of about 80% (Fig. 3A). Reoperation was done 5/2/65. There was a fibrous adherent thickening of the carotid bifurcation and no cleavage plane as in a sclerotic artery (Fig. 4). The lumen was widened with autogenous saphenous vein. He developed motor deficit in his right arm and leg which rapidly im-

proved and was completely normal at discharge. He has returned to work and is asymptomatic.

**Case 3.** A 71-year-old man had transient weakness of the right arm and leg for two months. Arteriogram showed 90% stenosis of the left internal carotid and 80% stenosis of the right carotid. He underwent bilateral carotid endarterectomies one week apart in September 1959, with knitted Teflon patch closure of the arteriotomy. He was asymptomatic until December 1966 (seven years) when he developed two syncopal episodes. Arteriograms showed 50% restenosis of the right internal carotid (Fig. 3B), and a normal left carotid. Re-operation was done January 1967, and again a fibrous thickening of the lumen which could not be detached was found. The lumen was widened with saphenous vein patch and he has done well since.

Among the thirty patients who were subjected to arteriograms two were found to have developed significant stenosis of the opposite unoperated carotid artery. Both patients were having transient symptoms consistent with the new carotid stenosis and this artery was operated at 5 and 6 years following the original procedure.

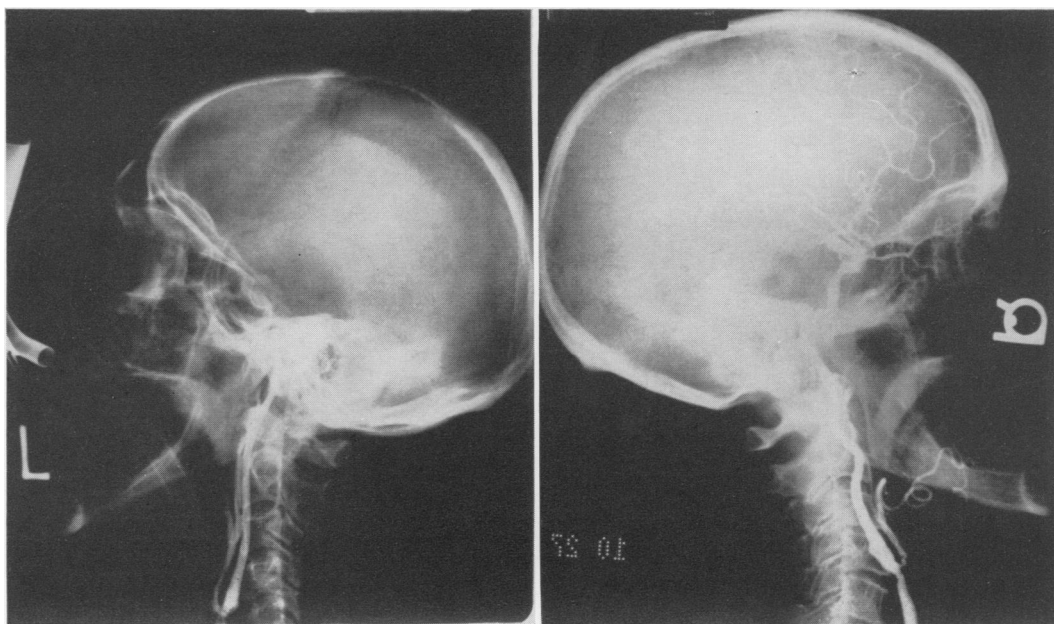



FIG. 3A (left). Carotid restenosis 3 years after endarterectomy (Case 2 in text). 3B (right). Restenosis 7 years after endarterectomy with Teflon patch closure of arteriotomy. (Case 3 in text.)

FIG. 4. Cross section photomicrograph (H & E  $\times 25$ ) of fibrous tissue causing restenosis of lumen. Vacuole is space occupied by a silk suture. (Case 2 in text.)



### Discussion

An important consideration of any form of treatment is the mortality and morbidity associated with the method. No attempt has been made to analyze the operative deaths and complications that occurred during the period of time under consideration, but these were undoubtedly much greater than at present. In the last fifty consecutive patients undergoing carotid endarterectomy there have been three patients (6%) who had transient neurological deficits postoperatively and one death from coronary occlusion (2%). From recent literature and from discussions with others, this would seem to be a reasonably typical experience. Methods of cerebral protection by maintaining a normal or slightly elevated blood pressure, the use of carbon dioxide inhalation to produce maximum cerebral blood flow, general anesthesia, and technical methods to prevent intraoperative embolization have all helped lower mortality and morbidity. At present, age alone is seldom a contraindication to operation, and the procedure is well toler-

ated by individuals who would not be considered good candidates for an intrathoracic or abdominal operation.

So little is as yet known about the natural history of cerebral vascular insufficiency states due to carotid stenosis or obstruction that no conclusion can be reached about how many patients in a series such as this one would have suffered strokes without surgery or with anticoagulant therapy, or even without treatment. The use of long-term anticoagulation has been reported by some<sup>4</sup> as effective in stopping transient ischemic attacks and preventing strokes, and by others<sup>1, 2, 3</sup> as causing no better results than no treatment in similar patients. Unfortunately, all of these studies were done without arteriographic identification of the intracranial or extracranial point of obstruction. Surgical treatment is the only mode of therapy that may effectively increase total cerebral blood flow and would seem to have an advantage over anticoagulant therapy in this regard, but this has yet to be proved by carefully controlled studies.

The pathological findings in the three

patients operated for restenosis were interesting. A tough, thick fibrous lining had developed suggesting chronic deposition of fibrin in the endarterectomized area. This occurred with or without the presence of a patch to widen the arteriotomy. Since seeing these cases, we have been making a greater effort to do a meticulous endarterectomy of the carotid bifurcation removing the yellowish transverse layer of media to the thin blue outer layer in hopes that a smoother surface will prevent the fibrin deposition that may rarely result in restenosis. The arteriographic follow-up we believe indicates that patches are not necessary and do not guarantee freedom from restenosis.

### Summary

Seventy-five patients who underwent carotid endarterectomy five to nine years ago were carefully followed. Thirty patients were subjected to carotid arteriograms. Twenty-two patients (29.3%) had died; twenty (26.6%) developed postoperative

neurological symptoms. In fifteen individuals (20%) these were transient but in five patients (6.6%) completed strokes occurred and each of these five had died. There were three persons who developed symptomatic re-stenosis of an operated artery requiring re-operation.

This study has led us to feel that carotid endarterectomy is a worthwhile and durable procedure and that there is a very low incidence of late development of stroke.

### References

1. Baker, R. N.: Cerebral Vascular Disease. Edited by R. G. Siekert and J. P. Whisenant. Heineman, London, Greene and Stratton, 1960, p. 213.
2. Hill, A. H., Marshall, J. and Shaw, D. A.: Cerebrovascular Disease: Trial of Long Term Anticoagulant Therapy. *Brit. Med. J.*, 2:1003, 1962.
3. McDowell, F., McDevitt, S. and Wright, I. S.: Anticoagulant Therapy, Five Years Experience with the Patient with an Established Cerebrovascular Accident. *Arch. Neurol.*, 8:109, 1963.
4. Millikan, C. H., Siekert, H. G. and Whisenant, J. P.: Anticoagulant Therapy in Cerebral Vascular Disease—Current Status. *JAMA*, 166: 587, 1958.

### DISCUSSION

DR. CHARLES G. ROB (Rochester): I have enjoyed this paper by Dr. Edwards and his colleagues. It is of interest that in 1957 we reported a series of 27 patients and I am able to give you a follow-up on these. Of those, with transient ischemic effects, which were 15 of the 27, 8 patients or a little over 50 per cent are alive today with a follow-up of between 10 and 14 years without neurological symptoms. It is of interest that of these patients, my colleague who was working with me then, Dr. Eastcott in London, has done post-operative arteriograms at various times on almost half of them and only one of them shows restenosis. And our first patient is alive and well more than 14 years after operation.

DR. RICHARD WARREN (Boston): I just wish to ask a question which has always puzzled me. Why is it that the short segments of endarterectomy such as occur here in the carotid area and also in the renal, do so well for so long and yet the long ones that are done in the femoral region have their problems?

We have many sequential arteriograms on femoral endarterectomies and although the segments are quite dilated for the first 3 or 4 months, they become progressively narrowed for about 6

or 9 months, become stable then for 2 or 3 years and then many of them have closed at a later date. I suppose this is just a question of extent of local trauma and subsequent fibrosis, both external and internal, but I wonder if Dr. Edwards would have any comments about that discussion.

DR. W. STERLING EDWARDS (Closing): I was hopeful that Dr. Rob would give us a report on his patients operated years ago and I am happy to know that there has been little restenosis. As far as restenosis is concerned, a problem Dr. Warren talked about in comparing this with long femoral segments, I think we know too little about why this occurs. An occasional patient will develop fibrin deposition on the inner surface and then go on to significant stenosis, like the femorals more often do.

I think this is the limiting factor in the possibility of ever doing the coronary endarterectomies on any significant number of patients. Unless we can find the answer to this, then I do not think we are going to help the bulk of coronary patients with a surgical approach. I think the purely mechanical reason the carotid segments stay open is they are short and the resistance to flow is so low, whereas the resistance to flow in a long femoral segment is quite a lot greater.