

# Control of the Hyperdynamic Circulation in Patients with Bleeding Esophageal Varices

GEORGE JOHNSON, JR., M.D., NATHAN A. WOMACK, M.D.,  
ORLANDO F. GABRIELE,\* M.D., RICHARD M. PETERS, M.D.

*From the Departments of Surgery and Radiology, University of North Carolina School of Medicine, Chapel Hill, North Carolina 27514*

AS EARLY AS 1904 Kretz,<sup>19</sup> using gelatin injections to demonstrate arteriovenous communications in the cirrhotic liver attributed portal hypertension to an increased arterial mixture in the portal vein:

A small part of the portal blood passes through the remnants of the old acinous channels into the hepatic veins; this passage forms an internal portocaval anastomosis supplementing the external; to the remaining branches of the portal vein more than the normal amount of arterial blood is furnished; this, on the one hand, supplies the granular areas of the parenchyma devoid of hepatic veins, and on the other, the hypertrophic remains of acinous tissue. This excess of blood passes under increased pressure through the remainder of the capillaries, narrowed by atrophy of the acini and lengthened by hypertrophy of the liver tissue. The lengthening and narrowing of the capillary vessels and the excess of arterial blood are the true causes of the increase of portal pressure, as is shown by the occurrence of ascites in subacute atrophy of the liver with regeneration, but without contracting connective tissue.<sup>17</sup>

Since this early description, numerous investigators,<sup>3, 7, 10, 11, 20, 30</sup> have documented the widespread presence of functioning arteriovenous communications in patients with cirrhosis of the liver. The hemodynamic effects of these vascular abnormalities on the cardiovascular system have been

emphasized by the work of Del Guercio and co-workers<sup>7</sup> and by studies from this laboratory.<sup>14, 16</sup> In many cirrhotic patients a hyperdynamic cardiovascular system characterized by an elevated cardiac output and blood volume, is accompanied by a decrease in peripheral resistance—findings similar to those associated with arteriovenous fistulas elsewhere in the circulatory system.

In 1965, we reported<sup>14</sup> a 12-year experience with an ablative operation designed to excise or ligate some of the numerous, large, functioning arteriovenous connections in the portal system. The procedure consists of splenectomy, resection of the superior two-thirds of the greater curvature of the stomach, ligation of the left gastric artery and its ascending branch, transesophageal ligation of the varices, and in some cases, vagotomy and pyloroplasty. The presence of a hyperdynamic cardiovascular system in these patients was documented by physiologic data obtained prior to operation.

The purpose of the present report is to update our clinical experience, to present roentgenologic data suggesting the presence of arteriovenous shunts in these patients, and to report hemodynamic data obtained on a small number of patients both before and after the ablative operation.

## Method and Materials

### Clinical Data

This series of 55 cases includes all patients with portal hypertension and bleeding esophageal varices in whom the opera-

\* Department of Radiology, University of North Carolina School of Medicine.

Presented at the Annual Meeting of the Southern Surgical Association, December 9–11, 1968, Boca Raton, Florida.

Supported by United States Public Health Service Grant #HE-0608608, and USPHS Grant #FR-46, from the General Clinical Research Centers, Branch of the Division of Research Facilities and Resources.

tion just described was carried out at North Carolina Memorial Hospital between 1952 and 1968. In 28 instances, the operation was performed as an emergency measure to control massive esophageal bleeding.

The patients ranged in age from 21 to 77 years; 33 were men and 22 women. All but two had cirrhosis; in 34 the cirrhosis was attributed to alcohol; in 19, it followed hepatitis. Liver biopsies were obtained on all patients. Twenty-five patients were classified as being in clinical grade A or B, and 30 as grade C.\* The patient's alcohol consumption and working habits were evaluated when possible. Portal pressures were usually not obtained following the operation because of the difficulty in cannulating mesenteric veins from the chest. Survival data will be presented as a life table analysis.<sup>6</sup>

#### Roentgenologic Data

Angiograms of the celiac and superior mesenteric arteries performed on nine patients with cirrhosis documented by liver biopsy were compared with angiograms obtained in 31 patients without cirrhosis. (In most of these 31, carcinoma in the area of the pancreas was suspected.)

After selective catheterization of the celiac axis or superior mesenteric artery with a double-curved Teflon catheter, 35 to 40 ml. of 60% Renografin or Hypaque-M (both mixtures of sodium and meglumine diatrizoates) were injected at a rate of 10 ml. per second. Timed serial roentgenograms, made with a Schönander rapid film changer, were used to follow the course of the contrast material through the portal system.

Measurements recorded were the diameters of the splenic and hepatic arteries and of the portal and splenic veins and in some the time elapsing between injection of the dye and opacification of the portal or splenic vein. The data from the two series

of patients were compared by a paired *t* test.

#### Hemodynamic Data

In ten adult patients with portal hypertension and bleeding esophageal varices, measurements of systemic hemodynamics (cardiac output, blood pressure, right atrial pressure, and blood volume) were obtained by methods previously described,<sup>14</sup> before operation and again six months or more after operation. The pre- and postoperative data were compared by the paired *t* test.

All but two of these 10 patients had cirrhosis of the liver secondary to alcohol or secondary to hepatitis documented by liver biopsy; in these two patients portal hypertension was present but the liver biopsy was interpreted as not showing cirrhosis. None of the patients had had active bleeding for at least one week preceding the study.

The patients used for this part of the study were drawn from those in whom the operation was not done as an emergency and who survived the immediate postoperative period.

#### Results

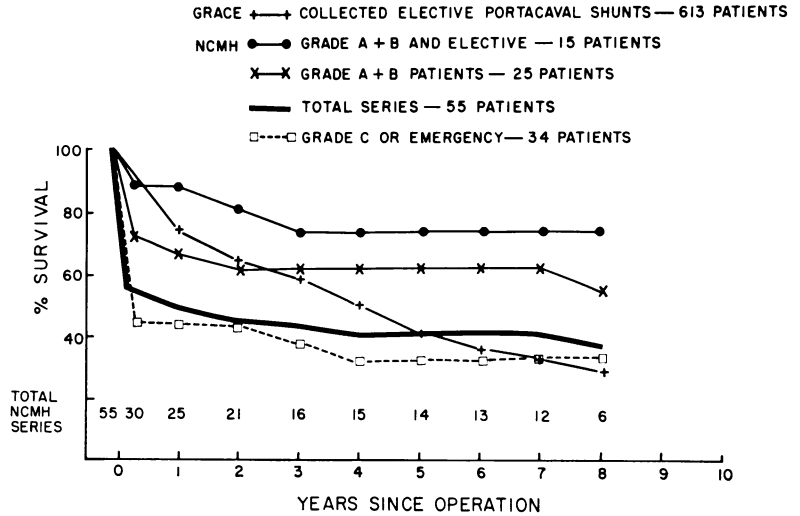
In this small series of patients, we are unable to find any correlation between clinical results, roentgenologic findings, and systemic hemodynamic data.

Of the 30 patients discharged from the hospital, 14 patients subsequently died; six as a result of gastrointestinal bleeding, two of liver failure, and six of causes not related to cirrhosis.

Twenty-five of the 55 patients died in the postoperative period, six of persistent gastrointestinal bleeding. Twenty-three of the 25 were either grade C or operated upon in an emergency to control bleeding. Fifteen patients subjected to the ablative procedure have lived 5 years or longer; of these, 12 were classified as grade A or B. Nineteen of the 25 patients who survived one year or more returned to their pre-

\* Grading system described by Wantz and Payne.<sup>31</sup>

FIG. 1. Life table analysis comparing survival in our series of operations with those in the series of portacaval shunts collected by Grace.<sup>9</sup>



operative occupations. In no instance has encephalopathy been a major problem.

X-rays of barium swallows obtained in 25 patients one month to 14 years following the operation revealed no evidence of varices in 11, a decrease in the varices in 9, and no change in 5.

Of the 18 patients with alcoholic cirrhosis who survived the postoperative period, 11 have apparently continued to drink, although in most cases not as heavily as they did before operation. Eight of these 11 have had more bleeding, and of these, three have died of hemorrhage. Of the remaining patients, one died of hepatic failure 2 years after the operation and the other two have survived for 4 and 7 years respectively. Of the seven patients who apparently stopped drinking, five have had no further bleeding since the operation (a period of 2 to 7 years), one has had one episode of bleeding, and another had a fatal hemorrhage.

A total of 15 patients have had further bleeding since their discharge from the hospital, but in two of these the source was proven to be a duodenal ulcer. Three of the 13 patients who rebelled from varices are still living—one, 7 years after the operation and other, 11 years after. One of the three living patients had a portacaval shunt at another institution. Six patients died from bleeding esophageal varices; four

deaths occurred less than 2 years following the operation, one 7 and one 10 years after the operation. Four patients who had had a nonfatal bleeding episode after the operation have died of other causes.

No patients have been lost to follow-up. The survival data are presented in Figure 1 as a life table analysis. To emphasize the various factors that altered survival, the series has been divided into 1) those patients classified as being grade A or B risk and operated upon as an elective procedure, 2) all A and B risk patients, and 3) grade C risk patients, or patients operated upon as an emergency measure. The results of an elective therapeutic portacaval shunt in 613 patients collected by Grace (9) are superimposed on the results of our series.

In Figure 2 survival of the 27 patients of the North Carolina Memorial Hospital series who had elective procedures are compared to survival of Grace's collected patients who had elective therapeutic portacaval shunts. In Figure 3, 28 patients with emergency operations are compared to the patients collected by Grace subjected to an emergency portacaval shunts.

Since there were only 6 grade A and 9 grade B patients who had elective operations, the survival of these two groups was combined to compare with Child's (2) grade A and grade B patients subjected to

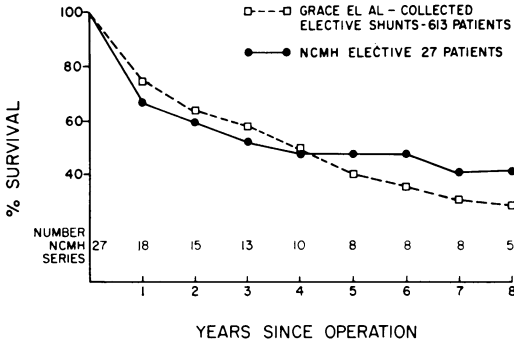


FIG. 2. Life table analysis comparing survival in our series of elective ablative operations with those in the series of elective therapeutic portacaval shunts collected by Grace.<sup>9</sup>

what we assume to be elective end-to-side portacaval shunt (Fig. 4). The patients with side-to-side shunts in his series did not have as good results. Grade C patients from this hospital and from Child's series are presented in Figure 5.

**Roentgenological Data**

The portal vein was visualized in seven of the nine patients with cirrhosis and the splenic vein, in six. The blood flowed freely from the portal vein into the liver in every case. In the 31 patients without cirrhosis, the portal vein was seen in 21 and the splenic vein in 20.

The sizes of the hepatic and splenic arteries and of the splenic and portal veins in the cirrhotic and noncirrhotic patients are compared in Table 1. There was a sig-

nificant increase in the diameter of the splenic artery and vein in the patients with cirrhosis. In Table 2 the time required for visualization of the splenic and portal veins in cirrhotic patients is compared with that in the non-cirrhotic group.

Figure 6 shows a series of rapid-sequence x-rays made in a patient with cirrhosis. The splenic vein was visualized 4 seconds after the injection of contrast medium into the celiac axis. A splenoportogram made in the same patient (Fig. 7) reveals a rapid flow of portal venous blood through the liver.

**Hemodynamic Data**

Comparison of the hemodynamic studies performed before and after operation (Table 3) revealed a slight but statistically insignificant decrease in cardiac index, blood volume, and right atrial pressure, and a slight increase in mean arterial pressure. Total peripheral resistance (mean arterial pressure divided by cardiac output) rose 0.2 units; this is a significant change ( $p < 0.05$ ).

**Discussion**

As the late follow-up data on large series of patients subjected to portacaval shunt become available,<sup>1, 4, 9, 23</sup> it is increasingly evident that other means of controlling portal hypertension are needed. The portacaval shunt imposes an added burden on

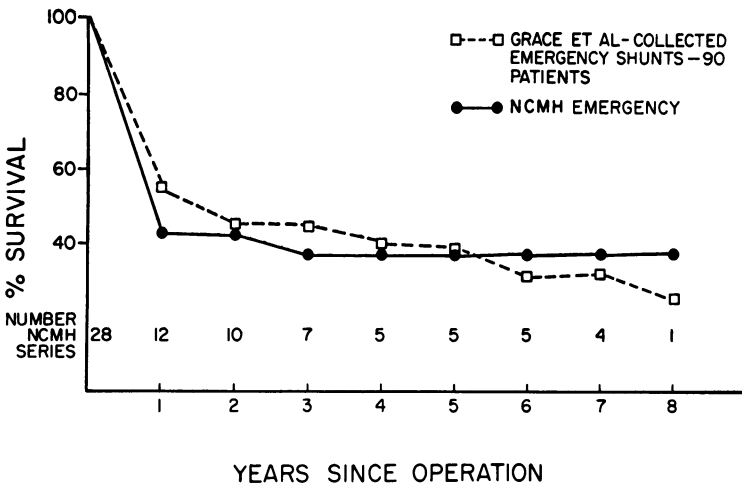
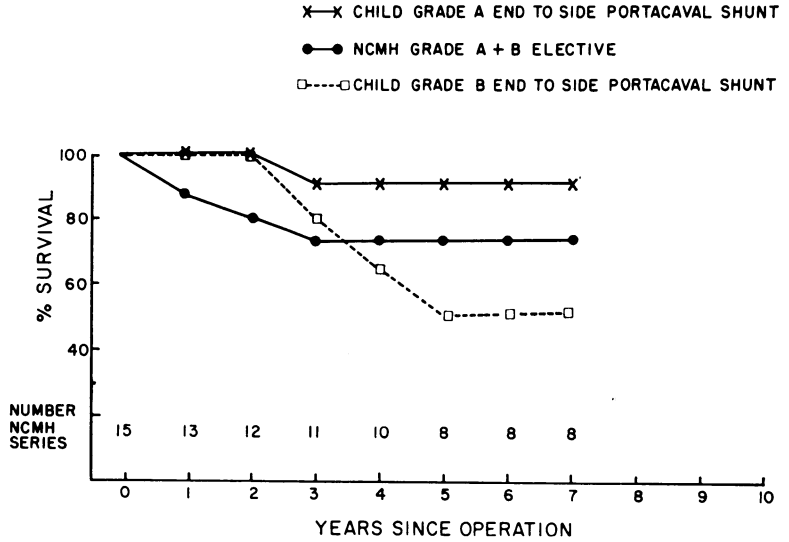


FIG. 3. Life table analysis comparing survival in our series of emergency ablative operations with that in the series of emergency portacaval shunts collected by Grace.<sup>9</sup>

FIG. 4. Life table analysis comparing survival in our grade A and B risk patients subjected to an ablative operation with grade A and grade B risk patients in a series of end-to-side portacaval shunts reported by Child.<sup>2</sup>



a cardiovascular system that is already strained by the physiological abnormalities associated with arteriovenous shunts.<sup>8, 16, 26</sup> Pulmonary hypertension<sup>24</sup> and a ventilation-perfusion defect<sup>5</sup> have been reported. The increase in hepatic-arterial flow does not compensate for the lack of intrahepatic portal-venous flow.<sup>22</sup> Following portacaval shunt, alterations in liver metabolism have been demonstrated in experimental animals<sup>23</sup> and undoubtedly occur in human patients. In human patients portacaval shunts have resulted in massive hepatic necrosis, apparently due to the shunting of portal blood away from the liver.<sup>16</sup> Overt encephalopathy occurs in about 20% of patients in whom portacaval shunts is performed.<sup>9</sup> Late mortality apparently continues to occur at a consistent rate even 5 years after operation.<sup>9</sup> Cirrhotic patients on whom a "prophylactic" portacaval shunt is performed before the varices bleed have been reported not to live any longer than those who have no operation.<sup>4</sup>

The presence of functioning arteriovenous shunts in patients with cirrhosis is well documented. Arterialization of the liver in cirrhosis, demonstrated by Hales and others<sup>10</sup> and by Peters and Womack,<sup>20</sup> has been confirmed by Hulten and Hulten,<sup>13</sup> who have used vascular injections of

colored vinyl acetate, followed by corrosion of the liver parenchyma. Angiography of the hepatic artery has revealed intrahepatic shunts between the hepatic artery and the portal vein.<sup>30</sup> Del Guercio and coworkers<sup>7</sup> have demonstrated a decrease in "central" arteriovenous oxygen difference in patients with cirrhosis—a finding which suggests systemic arteriovenous communications. The existence of large intrasplenic communications between arteries and veins has been demonstrated by injecting glass spheres, 600 microns in diameter, into the splenic artery and recovering them in the splenic vein.<sup>20</sup>

In the artery supplying an arteriovenous

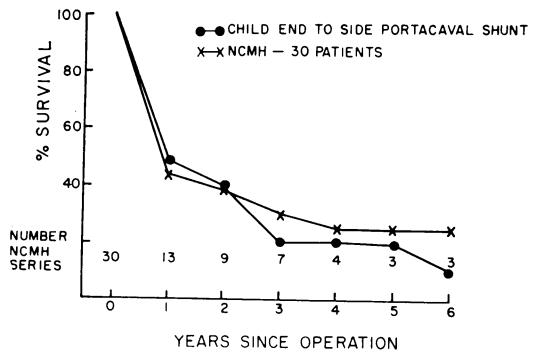


FIG. 5. Life table analysis comparing survival in our grade C risk patients subjected to an ablative operation with grade C risk patients in a series of end-to-side portacaval shunts reported by Child.<sup>2</sup>

TABLE 1. *Sizes of Arteries and Veins Shown on Angiograms in Cirrhotic Patients and Controls*

	Cirrhotic Patients		Controls		Significance of Difference
	No. Cases	Diameter (cm.)*	No. Cases	Diameter (cm.)*	
Splenic artery	8	0.86 ± 0.17	31	0.65 ± 0.15	<i>p</i> < 0.01#
Hepatic artery	7	0.57 ± 0.15	27	0.68 ± 0.17	<i>p</i> > 0.10
Splenic vein	6	1.63 ± 0.80	20	1.05 ± 0.44	<i>p</i> < 0.05#
Portal vein	7	1.96 ± 0.96	21	1.62 ± 0.41	<i>p</i> > 0.10

\* Mean ± standard deviation.

# Statistically significant difference.

TABLE 2. *Times Required for Opacification of the Veins on Angiograms Performed in Cirrhotic and Control Patients*

	Cirrhotic Patients		Controls		Significance of Difference
	No. Cases	Seconds from Injection*	No. Cases	Seconds from Injection*	
Splenic vein visualized	4	4.1 ± 2.6	16	7.3 ± 4.6	<i>p</i> > 0.10
Portal vein visualized	4	5.8 ± 3.2	11	6.9 ± 1.3	<i>p</i> > 0.10

\* Mean ± standard deviation.

TABLE 3. *Hemodynamic Data Obtained on Ten Patients Before and After Ablative Operation*

	Preoperative			Postoperative			Significance of Difference
	Mean	SD*	SE**	Mean	SD*	SE**	
Cardiac index (l./min./m <sup>2</sup> .)	4.01	± 1.08	0.34	3.58	± 0.50	0.16	<i>p</i> > 0.1
Arterial pressure (mm. Hg)	80.5	± 12.1	3.8	93.6	± 20.8	6.5	<i>p</i> > 0.5
Right atrial pressure (mm. Hg)	6.6	± 3.6	1.3	5.6	± 2.9	1.0	<i>p</i> > 0.05
Blood volume (liters)	6.6	± 1.8	0.7	6.0	± 1.9	0.3	<i>p</i> > 0.5
Total peripheral resistance (units)	0.72	± 0.18	0.06	0.95	± 0.24	0.07	<i>p</i> < 0.05#

\* Standard deviation.

\*\* Standard error.

# Statistically significant difference.

fistula, the flow of blood is increased, and as a result, the vessel is enlarged.<sup>15</sup> Angiograms performed on 10 of the cirrhotic patients in our series revealed an overall increase in the size of the splenic artery, indicating a large flow of blood through this artery. This change could not be accounted for on the basis of obstruction to outflow

from the portal vein. Rapid visualization of the splenic vein, such as occurred in the patients studied by angiography, would be extremely unlikely unless the contrast material bypasses the sinusoidal network through arteriovenous communications.

That arteriovenous fistulas in the portal system can cause portal hypertension has

been well documented in animals.<sup>20</sup> Stone and others<sup>27</sup> recently reviewed 38 patients with portal arteriovenous fistula and reported that portal hypertension with esophageal varices, splenomegaly and ascites were common complications.

An ablative operation designed to remove arteriovenous communications in the portal system in patients with portal hypertension was reported from this institution in 1961.<sup>20</sup> Although performed for a different disease, Hassab of Egypt has recently reported a satisfactory experience with a similar operation on 355 patients with bilharzial cirrhosis and portal hypertension.<sup>12</sup> Shafey and Hassab have presented data gathered from animal experiments that indicate an alteration in portal vein pressure as a result of the "decongestive" procedure.<sup>25</sup>

The clinical results of the ablative procedure as presented in this report are similar to those reported by us in 1961.<sup>13</sup> The operative mortality continues to be high in these poor risk patients. A large percentage of these patients continue to have bleeding from esophageal varices postoperatively and 20% of the patients who survive the operation ultimately die of gastrointestinal bleeding. Postoperative barium swallow x-rays show persistent varices in many of these patients.

An important advantage is the lack of hepatic encephalopathy following the procedure. Few patients die of liver failure and there is little evidence that the operation interferes with liver metabolism. If the alcoholic abstains from alcohol, he has a good chance of having no further trouble.

Since the number of patients who have had the ablative procedure is small, comparison to other series can be questioned. However, long term survival, including the postoperative mortality, is similar to that reported in larger series of patients in whom a portacaval shunt was performed. Also, the survival curve following the ablative procedure, apparently unlike that fol-

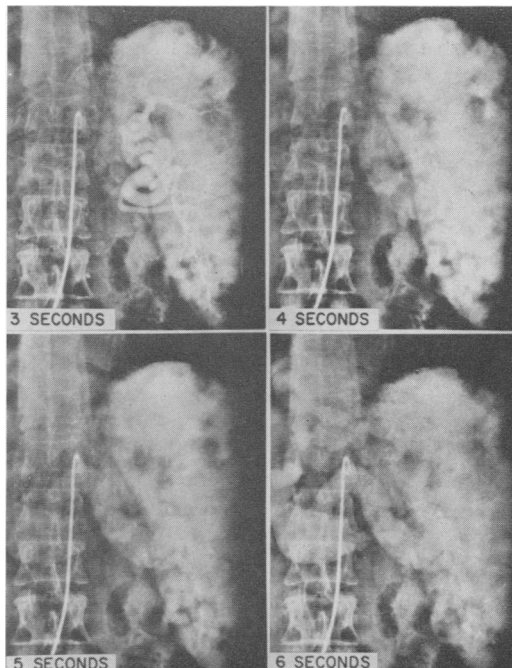


FIG. 6. Angiogram of the celiac axis, showing opacification of the splenic vein four seconds after injection of the dye and apparently one second after the bolus of dye leaves the splenic artery.

lowing the portacaval anastomosis, appears to level off after a year or two. The one year mortality in Grace's collected series of portacaval shunts seems unusually high, while the early mortality in Child's grade A and B patients is unusually low.

Although the hemodynamic studies per-

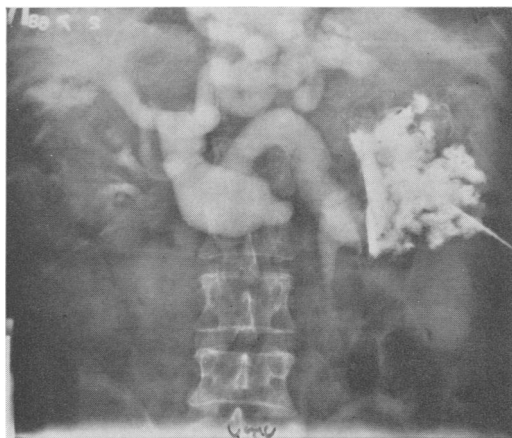

FIG. 7. Splenoportogram made in the patient whose angiogram is shown in Fig. 1. There is apparently no obstruction to the flow of portal-vein blood through the liver.

formed before and after the ablative procedure in ten of our patients show a slight increase in systemic vascular resistance following an ablative operation for control of portal hypertension, other changes in hemodynamics are not significant. The significant increase in peripheral resistance does suggest that the amount of blood flowing through arteriovenous shunts was reduced.

All patients with cirrhosis and portal hypertension do not have hyperdynamic cardiovascular systems and probably have varying physiological abnormalities in the portal system. While the operation of choice for portal hypertension might depend on the local and systemic hemodynamics, we have as yet found no correlation between the hemodynamic data and the clinical results. As more sensitive technics become available, it may be possible to evolve an approach to this disease based on sound physiological principles. Humoral control of the portal arteriovenous shunts in animals has been suggested in previous reports from this laboratory.<sup>21</sup> Further investigation and use of drugs to control this hyperdynamic circulation may be of benefit.

It is our opinion that an ablative operation designed to reduce the flow through functioning arteriovenous communications is worthy of further evaluation. Although it is not as effective as a portacaval shunt in controlling the bleeding from esophageal varices, it does have the following advantages:

- 1) It imposes no additional burden on an already strained systemic cardiovascular system.
- 2) The long-term survival compares favorably with that of a portacaval shunt.
- 3) Hepatic encephalopathy is not potentiated.
- 4) It may be less deleterious to the liver than is a portacaval shunt.

#### Summary and Conclusions

1. Follow-up data on a series of patients who had ablative procedures for portal hy-

per-tension and esophageal varices demonstrates a high incidence of recurrent bleeding but no encephalopathy and little evidence of hepatic dysfunction. Although the patients are few in number, long-term survival is similar to that after portacaval shunt as reported by other authors.

2. Roentgenological data are presented suggesting the presence of abnormal functioning arteriovenous communications in patients with cirrhosis of the liver.

3. Hemodynamic data before and after an ablative operation revealed an increase in peripheral resistance but no significant change in cardiac output, blood pressure, blood volume, or right atrial pressure.

4. It is our opinion that the ablative operation is worthy of further evaluation.

#### References

1. Basu, A. K., Mitra, S. K., Chatterjee, C. and Sen Gupta, D.: Experiences in the Surgical Treatment of Portal Hypertension. *Brit. J. Surg.*, **53**:127, 1966.
2. Child, C. G., III: The Liver and Portal Hypertension. Volume I. Major Problems in Clinical Surgery. Philadelphia, W. B. Saunders, 1964.
3. Cohn, J. D., Greenspan, M., Goldstein, C. R., Gudwin, A. L., Seigel, J. H. and Del Guercio, L. R. M.: Arteriovenous Shunting in High Cardiac Output Shock Syndromes. *Surg. Gynec. Obstet.*, **127**:282, 1968.
4. Conn, H. O. and Lindenmuth, W. W.: Prophylactic Portacaval Anastomosis in Cirrhotic Patients with Esophageal Varices. Interim Results, With Suggestion for Subsequent Investigation. *New Eng. J. Med.*, **279**:725, 1968.
5. Cotes, J. E., Field, G. B., Brown, G. J. A. and Read, A. E.: Impairment of Lung Function After Portacaval Anastomosis. *Lancet*, **1**:952, 1968.
6. Cutler, S. J. and Ederer, F.: Maximum Utilization of the Life Table Method in Analyzing Survival. *J. Chronic Dis.*, **8**:699, 1958.
7. Del Guercio, L. R. M., Commaraswamy, R. P., Feins, N. R., Wollman, S. B. and State, D.: Pulmonary Arteriovenous Admixture and the Hyperdynamic Cardiovascular State in Surgery for Portal Hypertension. *Surgery*, **56**:57, 1964.
8. Even, P., Nicollo, F., Benhamare, J.-P. and Fauvert, R.: Le Debit Cardiaque au Cours des Maladies du Foie. Effets de L'Anastomose Porto-Cave et des Diuretiques. *La Revue Francaise d'Etudes Cliniques et Biologiques*, **10**:799, 1965.
9. Grace, N. D., Muench, H. and Chalmers, T. C.: The Present Status of Shunts for Portal Hypertension in Cirrhosis. *Gastroenterology*, **50**:684, 1966.



10. Hales, M. R., Allan, J. S. and Hall, E. M.: Injection-Corrosion Studies of Normal and Cirrhotic Livers. *Amer. J. Path.*, **35**:909, 1959.
11. Hansoti, R. C. and Shah, N. J.: Cirrhosis of Liver Simulating Congenital Cyanotic Heart Disease. *Circulation*, **33**:71, 1966.
12. Hassab, M. A.: Gastroesophageal Decongestion and Splenectomy in the Treatment of Esophageal Varices in Bilharzial Cirrhosis: Further Studies with a Report on 355 Operations. *Surgery*, **61**:169, 1967.
13. Hulten, J. and Hulten, O.: Arterialization of the Liver in Cirrhosis. *Acta. Chir. Scand.*, **132**:711, 1966.
14. Johnson, G., Jr., Dart, C. H., Jr., Peters, R. M. and Macfie, J. A.: Hemodynamic Changes with Cirrhosis of the Liver: Control of Arteriovenous Shunts During Operation for Esophageal Varices. *Ann. Surg.*, **163**:692, 1966.
15. Johnson, G., Jr., Dart, C. H., Jr., Peters, R. M. and Steele, F.: The Importance of Venous Circulation in Arteriovenous Fistula. *Surg. Gynec. Obstet.*, **123**:995, 1966.
16. Johnson, G., Jr. and Lambert, J.: Cardiac Output after Portacaval Shunt. *Ann. Surg.*, **166**:207, 1967.
17. Kelly, A. O. J.: The Nature and the Lesions of Cirrhosis of the Liver with Special Reference to the Regeneration and Rearrangement of the Liver Parenchyma. *Amer. J. Med. Sci.*, **130**:951, 1905.
18. Koenemann, L. C. and Ceballos, R.: Massive Hepatic Necrosis Following Portacaval Shunt; Report of Two Cases and Consideration of Liver Hemodynamics After Shunt. *JAMA*, **198**:138, 1966.
19. Kretz, R.: Lebercirrhose. *Verhandl. Deutsch. Path. Gesselsch.*, **8**:54, 1904.
20. Peters, R. M. and Womack, N. A.: Surgery of Vascular Distortions in Cirrhosis of the Liver. *Ann. Surg.*, **154**:432, 1961.
21. Peters, R. M. and Womack, N. A.: Hemodynamics of Gastric Secretion. *Ann. Surg.*, **148**:537, 1958.
22. Price, J. B., Jr., Voorhees, A. B., Jr. and Britton, R. C.: Operative Hemodynamic Studies in Portal Hypertension: Significance and Limitations. *Arch. Surg.*, **95**:843, 1967.
23. Sedgwick, C. E., Poulantzas, J. K. and Miller, W. H.: Portasystemic Shunts in 102 Patients with Portal Hypertension. *New Eng. J. Med.*, **274**:1290, 1966.
24. Senior, R. M., Britton, R. C., Turino, G. M., Wood, J. A., Langer, G. A. and Fishman, A. P.: Pulmonary Hypertension Associated with Cirrhosis of the Liver and with Portacaval Shunts. *Circulation*, **37**:88, 1968.
25. Shafey, O. A. and Hassab, M. A.: Experimental Study on Hemodynamics of Hepatic Arterial and Portal Venous Flo. *Surgery*, **63**:962, 1968.
26. Siegel, J. H., Greenspan, M., Cohn, J. D. and Del Guercio, L. R. M.: The Prognostic Implications of Altered Physiology in Operations for Portal Hypertension. *Surg. Gynec. Obstet.*, **126**:249, 1968.
27. Stone, H. H., Jordan, W. D., Acker, J. J. and Martin, J. D., Jr.: Portal Arteriovenous Fistulas. Review and Case Report. *Amer. J. Surg.*, **109**:191, 1965.
28. Tamaki, A., Golby, M. and Orloff, M. J.: Effects of Side-to-Side Portacaval Shunt on Hepatic Hemodynamics and Metabolism. *Surg. Forum*, **19**:324, 1968.
29. Tamiya, T. and Thal, A. P.: Esophageal Varices Produced Experimentally in the Dog. *Surg. Gynec. Obstet.*, **111**:147, 1960.
30. Viamonte, M., Jr., Martinez, L., Parke, R. E., Warren, W. D. and Fomon, J.: Liver Shunts. *Amer. J. Roent. Nuc. Med.*, **102**:773, 1968.
31. Wantz, G. E. and Payne, M. A.: Experience with Portacaval Shunt for Portal Hypertension. *New Eng. J. Med.*, **265**:721, 1961.

#### DISCUSSION

DR. DENTON A. COOLEY (Houston): One technic of portacaval anastomosis which has either been neglected or ignored by the authors is a side-to-side splenorenal shunt. In the discussions that we have heard concerning these papers this technic has been omitted. The technic embraces some of the principles which Dr. Warren pointed out this morning.

(Slide) This slide happens to be on its side, but it does provide for drainage of the venous system in the left upper quadrant. I am somewhat skeptical about doing an extensive venous ligation in this area in the face of acute gastrointestinal bleeding, for fear of increasing the tendency toward bleeding which might occur.

(Slide) In the side-to-side splenorenal anastomosis, a technic which we described some 6 years ago, a left upper quadrant incision is made, a left subcostal is usually preferred. The tail of the pancreas is elevated, and the side-to-side anastomosis

can be accomplished with both renal and splenic vein in a single clamp.

(Slide) Here is a photograph showing the renal vein and the tail of the pancreas, with the hilum of the spleen here.

(Slide) The splenic vein has been exposed—this is the renal vein [indicating]—and the tail of the pancreas has been elevated, showing how readily accessible the two are to one another. The two vessels by this technic can be incorporated in a single clamp for side-to-side anastomosis.

The anastomosis may be done with the Cornell everting suture or with a simple over-and-over suture, which we prefer, and then the anastomosis is shown here. (Slide)

(Slide) A modification of this has recently been made in which the tail of the pancreas is not elevated, but a partial occlusion clamp is placed across the splenic vein without dissecting it out of the pancreatic bed. This can be a rather tedious procedure in patients, particularly with portal hy-