

# TRANSTHORACIC BRONCHOTOMY FOR REMOVAL OF BENIGN TUMORS OF THE BRONCHI\*

LEO ELOESSER, M.D.

SAN FRANCISCO, CALIF.

FROM THE STANFORD SURGICAL SERVICE AT THE SAN FRANCISCO HOSPITAL, DEPARTMENT OF PUBLIC HEALTH,  
SAN FRANCISCO, CALIF.

BRONCHOTOMY, in its narrower sense of incision into a bronchus, apparently dates from 1900, when Gluck proposed the operation for low tracheal stenosis; it had the object of permitting retrograde respiration through a large bronchial fistula. The operation seems to have been discussed and written about more than it was actually carried out. Sauerbruch mentions having performed it once; most other texts on thoracic surgery fail to mention it. The bronchotomies of older authors, from Bonetus down, reviewed by Gross in his treatise on foreign bodies in the air passages, include operative openings into the larynx and trachea, but not the bronchi. The lower bronchi, however, have been entered, *via* a posterior mediastinal route, with the object of extracting foreign bodies. Schwartz, in Quénu's Clinic, worked out such a procedure which was carried out successfully by Duncan, Schiasso, *et al.*: Danielson mentions three transpleural bronchotomies. The establishment of a large bronchial fistula may, occasionally, be indicated for incurable low tracheal stenosis; modern bronchoscopic methods have superseded bronchotomy for removal of foreign bodies.

Formal bronchotomy may have a place, however, in the treatment of benign bronchial tumors. Bigger,<sup>1</sup> in 1935, reported an operation performed upon a boy for a tumor of the left main bronchus. The bronchus was incised and the tumor removed; one week later the chest was reopened and the left lung removed. The course was complicated by a purulent pericarditis, to which the patient succumbed. Many pedunculated benign tumors, especially adenomata, may be removed bronchoscopically; they may be avulsed with a forceps or snare and their pedicles may be coagulated or cauterized. Some tumors, however, cannot be treated satisfactorily by endoscopic methods, especially those with pedicles originating in the upper lobe bronchus and sessile tumors with a broad base. Such tumors may be reached, and the possibility of their removal more accurately estimated through an incision into the bronchus than through a bronchoscope. Bronchotomy may even be justifiable for some more accessible bronchial growths. For it is notoriously difficult to judge whether a tumor mass seen protruding into the mouth of a bronchoscopic tube actually represents the whole tumor or merely the top of a submerged mass, of which, like a floating iceberg, but a small portion is visible while the great bulk lies submerged.

---

\* Presented by title before the American Surgical Association, St. Louis, Mo., May 1, 2, 3, 1940.

Bronchotomy *via* a thoracotomy opening allows accurate inspection of a growth, of its base and its extension; if palpation of the affected lobe discloses a large induration, of which it may be assumed that but a small portion has protruded into the bronchial lumen, while the main tumor lies or has extended extrabronchially, lobectomy or pneumonectomy may be undertaken at once. Otherwise the bronchus may be opened between stay sutures, the growth may be removed, its base cauterized and a portion of the bronchial wall removed with it, if necessary. The incision into the bronchus may then be repaired by suture and the chest closed, with or without drainage as seems most expedient. A long posterior thoracotomy incision with resection of the fifth rib, as described by Crafoord<sup>2</sup> for pneumonectomy, gives good access. The lung is retracted forward. The hilum is injected subpleurally with 15–20 cc. of 1/2 per cent procaine, to which epinephrine (two drops to 30 cc.) has been added. The procaine injection stops the objectionable cough reflex that follows handling of the hilar structures, and the edema resulting from the injection makes their dissection peculiarly easy. The hilar pleura is incised; the bronchial wall is steadied by two fine silk stay sutures passed through its soft posterior membranous portion and incised at a site calculated by bronchoscopic and roentgenographic observation. The lumen is inspected, the incision prolonged if necessary and the tumor removed. The incision is repaired with a single layer of fine catgut or silk sutures, including the whole thickness of the bronchial wall, care being taken to narrow the bronchial lumen as little as possible. More than one layer would be likely to lead to a stenosis. Repair of the intrapulmonary portion of the bronchus, where lung may be used to cover the suture line, is easier than that of the hilar portion. The suture need not be hermetically accurate; in the case reported it was far from so, yet the incision closed without sequela.

It would seem best in patients who cough not to attempt to cover the bronchial sutures by reuniting the incision into the hilar pleura. If the bronchus does leak air it is better that air escape into the pleura than into the mediastinum, mediastinal emphysema being a complication more difficult to handle than a pneumothorax, which is easily taken care of by a drainage tube.

The thoracotomy incision is closed; if the bronchial suture seems tight, drainage may be dispensed with, although the patient should be carefully watched for the first few days after operation and a pressure pneumothorax promptly dealt with. If there is doubt of an air leak, a catheter is introduced into the chest through a separate intercostal stab and led out under water.

Through the kindness of Dr. Cabot Brown, I was afforded the opportunity of carrying out a bronchotomy for what was thought, preoperatively, to be a benign tumor.

**Case Report.**—Mrs. Elise Y., age 33, was referred by Doctor Brown to the Stanford Surgical Service at the San Francisco Hospital, June 19, 1939. She had suffered for five years from chronic, intermittent obstruction of the left upper lobe, with febrile interludes, abscess formation, much cough and episodes of bleeding. A series of roentgenograms, dating from 1934 to 1937, showed intermittent obstruction of the left upper lobe. Lipiodol

injection by Doctor Brown, in April, 1939, demonstrated a round defect projecting into the bronchial lumen; at this site an obstruction was encountered bronchoscopically (Fig. 1). An abscess was drained through an interior incision in April, 1939. Bronchoscopy, four times repeated, failed to reveal a tumor and biopsies revealed nothing but shreds of inflamed bronchial mucosa. A ureteral catheter, introduced into the draining sinus of the previous thoracotomy, passed into the lower lobe bronchus beyond the site of obstruction, and a second catheter, introduced through the bronchoscope, traversed the stricture and also passed into the lower bronchus, but no ulcerative lesion, and no tumor mass, from which a biopsy could be taken, were seen. However, suspicion of a growth could not be allayed and exploratory bronchotomy was decided upon.

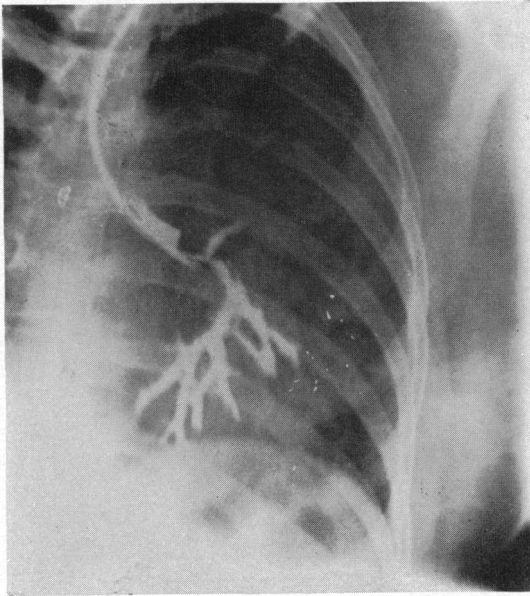


FIG. 1.—Bronchogram with lipiodol, April 26, 1939. Filling defect shown just above the bifurcation of the left stem bronchus.

*Operation.*—October 2, 1939: Under completely satisfactory anesthesia with avertin and gas, administered by Doctor Neff through an intratracheal tube, the chest was opened by Crafoord's incision; 22 cm. of the fifth rib was resected. Separation of dense adhesions offered considerable difficulty; those over the upper lobe were allowed to remain. The left lower bronchus was identified and opened between two stay sutures by a transverse incision into its membranous posterior portion; a catheter introduced into it and passed upwards met with no resistance. Upon close inspection one saw that the bronchus had been opened exactly opposite a tumor, which was attached by a pedicle to a site near the mouth of the upper lobe bronchus. As it hung down by its pedicle it occluded the upper lobe bronchus entirely and the lower lobe bronchus partially. Its anatomic situation explained its not having been visible through the bronchoscope, for coughing during the introduction of the bronchoscope had probably pushed it back into the upper lobe bronchus, where it remained hidden.

The incision was carried around at an angle so as to open the left upper bronchus; the tumor, measuring 1.5x1.4x1.2 cm., was carefully lifted up and removed by severing its pedicle with the diathermy current. The pedicle was inspected, its base cauterized again, and the incision closed with a series of fine, interrupted, chromic gut sutures

placed in one layer. The thoracotomy incision was closed, but a Pezzer catheter was placed in its posterior angle, the closure of the bronchus having seemed none too accurate.

*Pathologic Diagnosis.*—Dr. David Wood: Carcinoma, relatively benign.

*Postoperative Course.*—The catheter was submerged under water. On the second day, a small amount of subcutaneous emphysema was demonstrable over the sternal notch; a venous pressure of 21 cm. gave additional evidence of mediastinal emphysema. This, however, rapidly receded and the subsequent course was uneventful. The patient was discharged, November 2, 1939. There has been no evidence of recurrence. The left upper lobe is aerated.

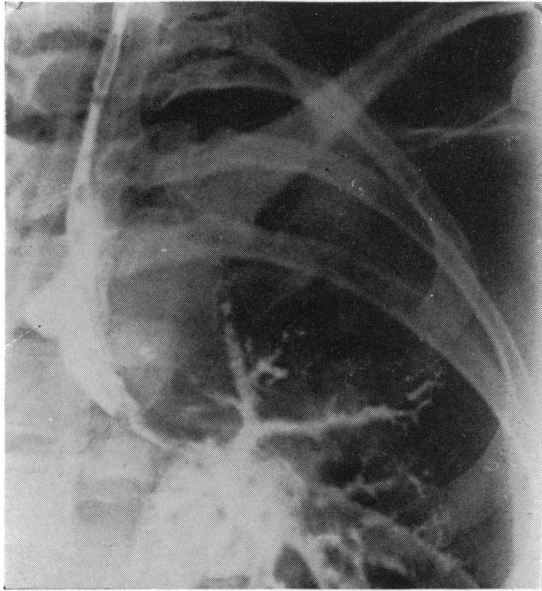


FIG. 2.—Lipiodol injection 29 days after operation, October 31, 1939. Both upper and lower lobe bronchi are open. (The central density is due to previous lipiodol injections into the abscess cavity.)

Lipiodol injection, October 31, 1939, demonstrated both upper and lower left bronchi to be open (Fig. 2). Bronchoscopy several months later revealed a normal bronchial tree.

#### CONCLUSION

Transpleural bronchotomy is a feasible, conservative method of removing benign tumors of the bronchus, which, by reason of their anatomic situation or their doubtful extension, are not amenable to safe and certain bronchoscopic removal.

#### REFERENCES

- <sup>1</sup> Bigger, I. A.: *Diagnosis and Treatment of Primary Carcinoma of Lung*. So. Surg., **4**, 401, December, 1935.
- <sup>2</sup> Crafoord, C.: *Technique of Pneumonectomy in Man*. Acta Chir. Scandinav., **81**, Sup. 54, 11, May, 1938.