

## ABC of wound healing

### Traumatic and surgical wounds

David J Leaper, Keith G Harding

This is the fifth in a series of 12 articles

Management of traumatic and surgical wounds has had a chequered history. For example, in 1346 at the Battle of Crécy, France, foot soldiers were issued with cobwebs to staunch haemorrhage caused by trauma. Two centuries later, the eminent surgeon Ambroise Paré (1510-1590) rejected boiling oil as a primary dressing after amputation, preferring a mixture of oil of turpentine, rosewater, and egg.



Although the 16th century French surgeon Ambroise Paré could successfully dress a wound, he felt that only God could heal it

### Classification

**Surgical incisions**—Surgical incisions cause minimal tissue damage. They are made with precision in an environment where aseptic and antiseptic techniques reduce the risk of infection, with the best of instruments and the facility to control haemostasis. Penetrating trauma may involve minimal damage to skin and connective tissue, though deeper damage to vessels, nerves, and internal organs may occur.

**Lacerations**—Lacerations are caused when trauma exceeds intrinsic tissue strength—for example, skin torn by blunt injury over a bony prominence such as the scalp. Tissue damage may not be extensive, and primary suturing (see below) may be possible. Sterile skin closure strips may be appropriate in some circumstances—for example, in pretibial laceration, as suturing causes increased tissue tension, with the swelling of early healing and inflammation leading to more tissue loss.

**Contusions**—Contusions are caused by more extensive tissue trauma after severe blunt or blast trauma. The overlying skin may seem to be intact but later become non-viable. Large haematomas under skin or in muscle may coexist; if they are superficial and fluctuant they can be evacuated with overlying necrosed skin. Ultrasound scanning or magnetic resonance imaging may help to define a haematoma amenable to evacuation. Extensive contusion may lead to infection (antibiotic prophylaxis should be considered in open wounds) and compartment syndromes (fasciotomy will be needed to preserve a limb).

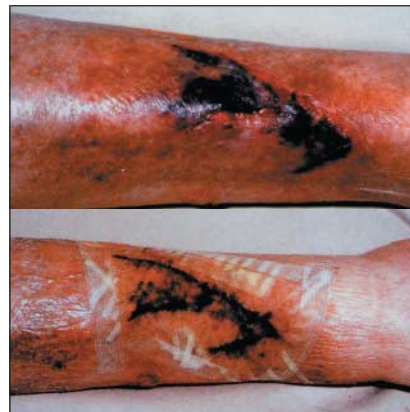**Large open wounds**—Such wounds may be left to heal “by secondary intention” (that is, the wound heals from the base upwards, by laying down new tissue) or with delayed skin grafting, depending on the extent of the residual defect. Exploration of a traumatic wound is needed if there is a suspicion of blood vessel or nerve damage, with attention to fractures and debridement of devascularised tissue and removal of foreign material.

**Abrasions**—Abrasions are superficial epithelial wounds caused by frictional scraping forces. When extensive, they may be associated with fluid loss. Such wounds should be cleansed to minimise the risk of infection, and superficial foreign bodies should be removed (to avoid unsightly “tattooing”).

### Management

Surgical wounds are made in optimum conditions with full anaesthetic and operating theatre support; traumatic wounds are not, and they may be associated with much more serious underlying injury. Triage and resuscitation may be needed before definitive wound management is started.

Wounds usually involve some loss or damage to an epithelial surface (usually skin) but may also include damage to underlying connective tissue, which may occur without epithelial loss



Pretibial laceration showing treatment with sterile skin closure strips

#### Types of traumatic and surgical wounds

Type of wound	Result	Cause
Incision	Penetrating	Surgical (rarely, trauma)
Laceration	Torn tissue	Usually trauma
Contusion	Extensive tissue damage	Usually trauma; skin may be intact
Abrasion	Superficial epithelial	Usually trauma
Combination	Usually severe trauma	Life threatening

In England, triage and resuscitation should be done following the Advanced Trauma Life Support guidelines of the Royal College of Surgeons of England ([www.rcseng.ac.uk](http://www.rcseng.ac.uk))

Arterial bleeding is easy to recognise—pulsatile and bright red—provided it is overt, but if it is hidden from view (for example, the result of a penetrating injury of the aorta) it may lead to profound unexpected haemorrhagic shock. Early exploration and repair or ligation of blood vessels may be required. Venous haemorrhage is flowing and dark red, and can be controlled by adequate direct pressure. Even large veins may spontaneously stop bleeding after this measure. Capillary bleeding oozes and is bright red; it can lead to shock if injury is extensive and it should not be underestimated.

The risk of infection in traumatic wounds is reduced by adequate wound cleansing and debridement with removal of any non-viable tissue and foreign material. If severe contamination is present, broad spectrum antibiotic prophylaxis is indicated and should be extended as specific therapy as recommended for surgical wounds that are classed as “dirty” or when there are early signs of infection. Traumatic wounds need tetanus prophylaxis (parenteral benzylpenicillin and tetanus toxoid, depending on immune status). Strong evidence supports the use of antibiotic prophylaxis and treatment for surgical wounds that are classed as “clean contaminated” or “contaminated.” The value of antibiotic prophylaxis in “clean” wounds is controversial but is widely accepted in prosthetic surgery (such as hip and knee replacement and synthetic vascular bypass surgery).

### Wounds from explosions and gunshot

When the source of the wound is high velocity (for example, an explosion or gunshot), it causes more damage because of the dissipation of kinetic energy (kinetic energy =  $\frac{1}{2}mv^2$ , where m is the mass of the bullet or shrapnel and v its velocity). In addition to gross skeletal injury, soft tissues (such as muscles of the thigh) develop cavitation ahead of the bullet track. These tissues are rendered ischaemic and there may be a large exit wound. Behind the missile there is a sucking action that deposits clothing or dirt in the wound. Together with ischaemia, this contamination provides an ideal culture medium for anaerobic organisms (such as *Clostridium perfringens*, which can lead to gas gangrene).

These wounds need extensive debridement down to viable tissue and should be left open until healthy granulation tissue has formed; repeated debridement may be necessary. Even after extensive debridement, infection may develop, requiring antibiotic treatment. Where there is doubt or an obvious crush injury, fasciotomy can prevent systemic complications, including infection. After debridement, delayed primary or secondary suturing may be done, with or without reconstructive surgery (see eighth article in this series). Alternatively, if the combination of wound contraction and epithelialisation will leave an acceptable cosmetic appearance, a wound may be left to heal by secondary intention. Human and animal bites are traditionally managed in this way, but primary closure can be done after wound debridement and excision of non-viable tissue.

### Methods of wound closure

For primary closure, the technique of closure, the suture material, and the type of needle or appliance all need to be considered.

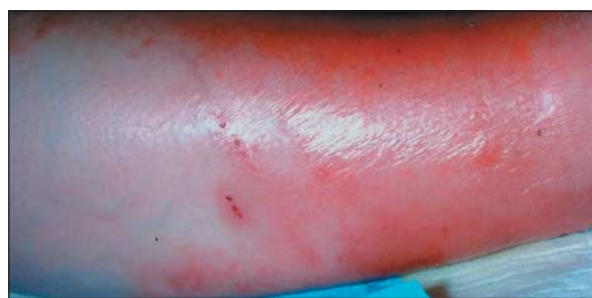Various suturing techniques exist. Skin may be closed with simple or mattress sutures using interrupted or continuous techniques. Knots should not be tied tightly, to allow swelling as a result of inflammation and to prevent necrosis at the skin edge. Mattress sutures ensure optimal eversion at the skin edge and appose deeper tissue, reducing the risk of formation of haematoma or seroma. The subcuticular suture is the most widely favoured technique for closing surgical skin wounds and

**A tourniquet is rarely needed in traumatic bleeding—control by direct pressure prevents irreversible ischaemia and nerve damage**

### Categories of surgical wounds

Category	Example	Recommendation for antibiotics
Clean	Hernia, varicose veins, breast	None
	Prosthetic surgery: vascular, orthopaedic implants	Prophylaxis
Clean contaminated	Elective cholecystectomy	Prophylaxis
Contaminated	Elective colorectal operations	Prophylaxis
Dirty	Drainage of abscess	Treatment if spillage
	Faecal peritonitis	Treatment

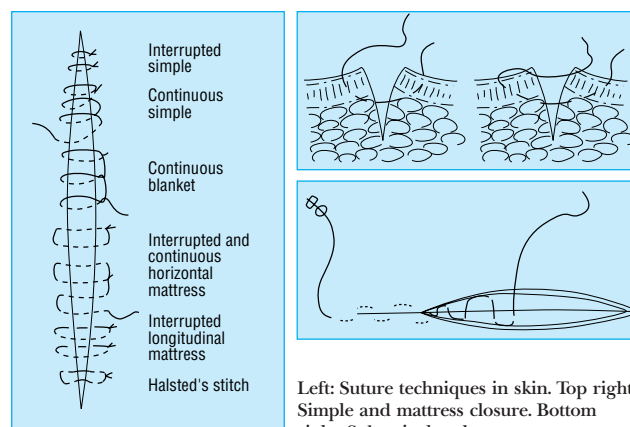
**Bomb blast and gunshot injuries should not be sutured—primarily because of the high risk of infection**



Streptococcal cellulitis complicating a leg wound (wound not shown)

### Wounds to consider for open management

- Severe contamination (during laparotomy for faecal peritonitis)
- Old laceration (> 12-24 hours; depends on amount of contusion)
- Shock (of any cause but usually haemorrhagic)
- Devitalisation (local poor tissue perfusion)
- Foreign body (either external or known dead tissue)
- Kinetic energy (in wounds caused by explosions; implies presence of dead tissue and foreign material)



Left: Suture techniques in skin. Top right: Simple and mattress closure. Bottom right: Subcuticular closure

has good cosmetic results. Arterial anastomoses and arteriotomies are closed to ensure eversion, but gut anastomosis conventionally has an inverted suture line.

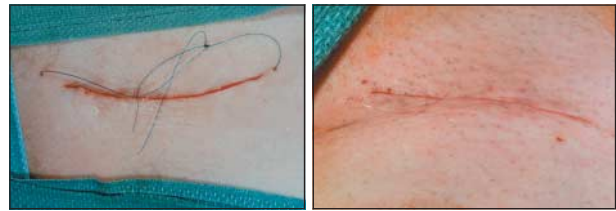The ideal suture material for a particular wound remains controversial. Sutures that are absorbable (for example, polyglactin or polydioxanone) clearly do not require removal. Catgut should no longer be used as it causes an excessive tissue reaction, which may predispose to infection. Such reactions are less likely to occur with the use of synthetic polymers. Non-absorbable sutures (for example, natural silk or synthetic polymers such as nylon or polypropylene) need removal. The monofilament polymers cause minimal tissue reaction and are least likely to lead to secondary (exogenous) infection. Silk can cause an intense tissue reaction, with an increased risk of excessive scarring and of formation of a suture abscess; silk is therefore no longer recommended.

Metal clips and staples are alternatives to conventional suturing. Despite their need for removal, they are associated with good cosmetic results and low infection rates. Disposable applicators are expensive but allow rapid closure of long wounds after prolonged surgical procedures. Some stapling devices are sophisticated and allow safer surgery—for example, for very low coloanal anastomosis.

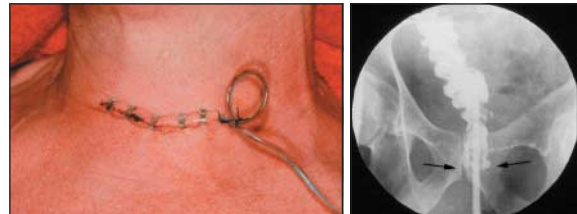
Adhesive strips are useful for closing superficial wounds. In emergency departments a child's forehead laceration can be closed without anaesthetic or tears. They allow for wound swelling and are associated with low infection rates. Adhesive polyurethane film dressings have a similar effect with sutured wounds and provide a barrier to infection. The methacrylate superglues are widely used for skin closure, particularly with scalp wounds (though surrounding hair should be trimmed first). Fibrin glues are relatively expensive but allow rapid closure.

Modern suture materials are presented in sterile, single use packets. Sutures are bonded on to hollow needles. Dispensing with the eye of the needle results in a "shoulderless" needle, permitting easier passage through, and less disruption of, tissues.

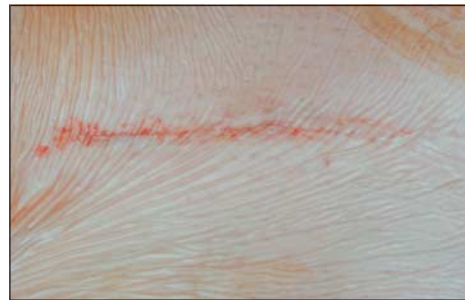Suture removal depends on the wound site. The role of dressings to cover sutured wounds remains controversial. Polyurethane dressings allow inspection and provide a bacterial barrier. Island dressings allow absorbance of wound exudate and lessen the risk of leakage.



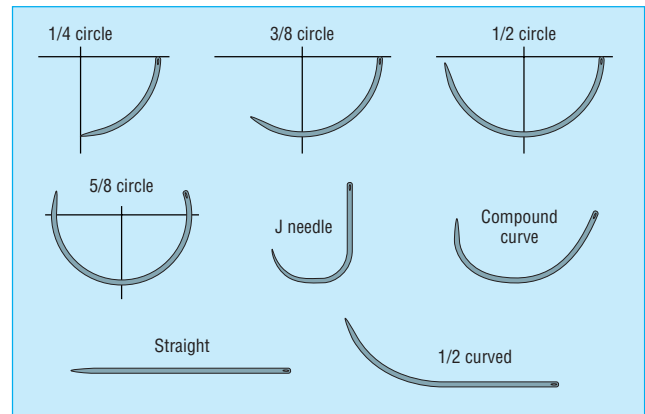
Left: Final appearance of subcuticular closure with polypropylene closure. Right: Final appearance of subcuticular closure with polyglactin closure



Left: Incision of neck closed with skin clips. Right: X ray showing stapled low anterior resection: the gastrografin enema shows no leakage from the anastomosis



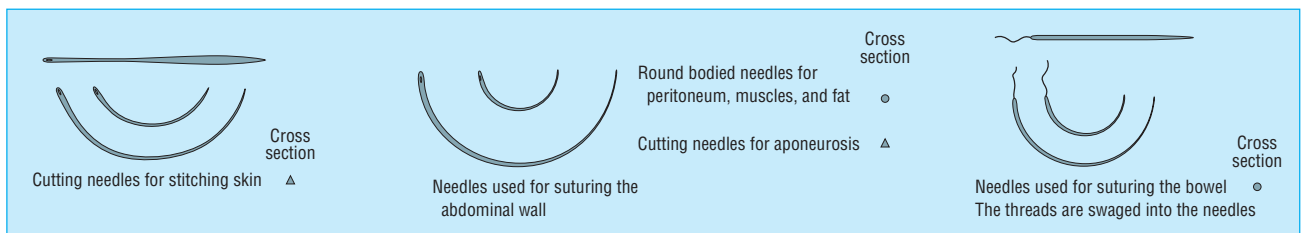
Polyurethane film dressing over a wound after subcuticular closure



Shapes of needle used in surgical and traumatic wound closure

**Time to removal of non-absorbable sutures**

Site of sutures	No of days
Scalp and face	3-4
Upper limb	7
Lower limb	7-10
Trunk	10-14



Types of needles used for different surgical procedures. Straight needles and all hand needles are no longer recommended as they have an added risk of causing needle stick injury and the passage of viruses through body fluids. Instrument mounted needles or, when appropriate (as in closure of abdominal fascia), blunted needles should be used

### Hidradenitis suppurativa and pilonidal sinus wounds

Hidradenitis, an infection of apocrine sweat glands, affects armpits and groins; pilonidal sinus, a tissue infection caused by ingrowing hair, mainly affects the natal cleft.

Failed, repeated drainage of the abscesses requires complete excision. The defect usually heals by secondary intention. Initially, excision wounds are usually dressed with polymeric foam. Once the wound has reduced in size, a topical antimicrobial dressing (such as those that contain iodine or silver) may be used. However, grafts or flaps are also used, either as the primary treatment or for non-healing wounds. These wounds often become infected and require prolonged treatment to cover Gram positive and anaerobic organisms.

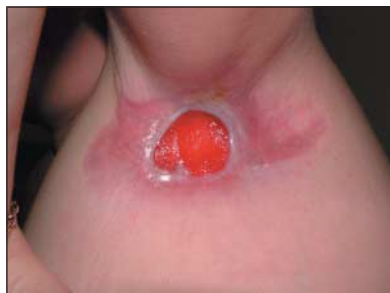The picture of Ambroise Paré is published with permission from TopFoto.

David J Leaper is visiting professor of surgery at the Wound Healing Research Unit, Cardiff University, Cardiff.

The ABC of wound healing is edited by Joseph E Grey (joseph.grey@cardiffandvale.wales.nhs.uk), consultant physician, University Hospital of Wales, Cardiff and Vale NHS Trust, Cardiff, and honorary consultant in wound healing at the Wound Healing Research Unit, Cardiff University, and by Keith G Harding, director of the Wound Healing Research Unit, Cardiff University, and professor of rehabilitation medicine (wound healing) at Cardiff and Vale NHS Trust. The series will be published as a book in summer 2006.

Competing interests: DJL has received an educational grant for his research group from Merck Sharp and Dohme and had expenses and a fee paid by Ethicon for attending an advisory panel and for the making of an educational film. For series editors' competing interests, see the first article in this series.

BMJ 2006;332:532-5



Excision wound in hidradenitis suppurativa

### Further reading

- Téot L, Banwell PE, Ziegler UE, eds. *Surgery in wounds*. Berlin: Springer, 2004.
- Leaper DJ, Harding KG, eds. *Wounds. Biology and management*. Oxford: Oxford Medical Publications, 1998.
- Bales S, Harding K, Leaper DJ. *An introduction to wounds*. London: Emap Healthcare, 2000.
- Leaper DJ, Harding KG, Phillips CJ. Management of wounds. In: Johnson C, Taylor I, eds. *Recent advances in surgery*. 25th ed. London: Royal Society of Medicine, 2002.
- Leaper DJ, Low L. Surgical access: incisions and the management of wounds. In: Kirk RM, Ribbons WJ, eds. *Clinical surgery in general*. 4th ed. Edinburgh: Churchill Livingstone, 2004.
- Leaper DJ. Basic surgical skills and anastomoses. In: Russell RCG, Williams NS, Bulstrode CJK, eds. *Bailey and Love's short practice of surgery*. 24th ed. London: Arnold, 2004.

### When I use a word

#### The very last word

What is the last word in the dictionary? Easy to answer, you might think. But there is a problem. We talk blithely about "the dictionary," as if there was only one. But there are many, even among monolingual dictionaries of English. And they don't all end with the same headword.

Samuel Johnson's dictionary (1755) ends with zootomy, "dissection of the bodies of beasts." Not a great effort, but then he wasn't going for broke. *Collins English Dictionary* (sixth edition) makes a better stab: Zyrian, the language spoken by the people of the Komi, in the erstwhile Soviet Union. Zyrian belongs to that curious group of languages, the Finno-Ugric (one of two branches of Uralic, the other being Samoyed). Its main members, despite the geographical divide, are Finnish and Hungarian; it also includes Estonian, Vogul (or Khanti), Ostyak (or Mansi), and the language of Sibelius's Karelia.

*The Chambers Dictionary* (new ninth edition, 2003) does better still: zythum, a kind of barley beer brewed by the ancient Egyptians and others, from the Greek word zuthos (beer). And a zytheptary is a brewery, got by adding hepsein (to boil). Hepsein also meant to smelt metals and to digest food, reminiscent of another Greek word, pepsis, meaning digestion or fermentation. And the yeast in zythum was called zyme, which gives us enzyme, a word that the Heidelberg physiologist Wilhelm Kühne introduced in 1877 to describe substances such as pepsin.

The *Oxford English Dictionary* (second edition) takes us further still: zyxt, which turns out to be, wait for it, an obsolete Kentish form of the second person singular present indicative of see. In other words, zyxt is "seest [thou]."

Now the OED is pretty comprehensive, but Philip Gove's controversial *Webster's Third New International Dictionary* (1961) went one better: zzyzgoton, a genus of large American

leaf-hoppers having the pronotum tuberculate and the front tibiae grooved (well that's what the dictionary says).

No dictionary that I've seen has another candidate: zyzzya, from *Zyzya fuliginosa*, a marine sponge found in the South Seas. It contains pyrroloiminoquinone alkaloids belonging to the makaluvamine family, which inhibit the enzyme topoisomerase II and so produce a cytotoxic action by cleavage of DNA. And zyzzyposide (modelled on etoposide) would be a great name for an anticancer drug.

However, this is trumped by *The American Heritage Dictionary of the English Language* (fourth edition, 2000), which has unearthed zyzzyva, any of various tropical American weevils of the genus *Zyzyva*, and by *The Random House Unabridged Dictionary* (1997) with Z-zero particle, one of three particles, intermediate vector bosons, that are thought to transmit the weak nuclear force.

Finally, turn to *Mrs Byrne's Dictionary of Unusual, Obscure and Preposterous Words* (yes really) of 1974. Mrs Byrne, a concert pianist and composer, was Jascha Heifetz's daughter, Josefa, so it is not perhaps surprising that the last word in her dictionary is musical: zzxjoanw, pronounced ziks-jo'-un and defined as a Maori drum. But anyone with the least smattering of Maori would look suspiciously at those zeds, the ex, and the jay. Here's a sample of the real thing, from the famous haka: "Tenei te tangata puhuruhuru nana mei i tiki mai whakawhiti te ra." Zzxjoanw can't be Maori. In fact, it turns out (Word Ways, November 1976) to have been invented by Rupert Hughes for inclusion in his *Music Lovers' Encyclopedia* of 1914, where he says that it is pronounced "shaw" and means "1. Drum. 2. Fife. 3. Conclusion."

To which one the only possible concluding response is "Pshaw," followed by a bout of heavy zzzz-ing.

Jeff Aronson *clinical pharmacologist, Oxford*  
(jeffrey.aronson@clinpharm.ox.ac.uk)