

# ANTEROTHORACIC ŒSOPHAGOPLASTY FOR IMPERMEABLE STRICTURE OF THE ŒSOPHAGUS

BY ALTON OCHSNER, M.D.,

AND

NEAL OWENS, M.D.

OF NEW ORLEANS, LA.

FROM THE DEPARTMENTS OF SURGERY, TULANE UNIVERSITY SCHOOL OF MEDICINE AND CHARITY HOSPITAL, NEW ORLEANS, LA.

THE ideal method of replacement of an obstructed thoracic œsophagus would probably be the removal of the diseased portion and the reconstruction of the œsophagus in the posterior mediastinum. Unfortunately, such operations are attended with an extremely high mortality and, therefore, are not feasible or justified. Formerly, reconstructive œsophageal surgical procedures were limited to the cervical portion of this viscus, which could be relatively easily attacked. Not until H. Bircher's attempt on May 21, 1894, to circumvent a carcinoma obstructed œsophagus, by the formation of a tube from the skin on the anterior surface of the thorax, was any progress made concerning the reconstruction of an obstructed thoracic œsophagus. The death of Bircher's first patient from a pulmonary embolism did not permit him to complete the operative procedure. The case demonstrated that the reconstruction of an œsophagus from skin was feasible (Fig. 1). In a second patient, also with carcinoma, the skin tube was satisfactorily formed and as in the first case sutured to the stomach. This patient, too, died before the operation could be completed. Since the original observations of Bircher,<sup>1, 2</sup> numerous attempts have been made according to various technics to reconstruct an extrathoracic œsophagus. Wullstein,<sup>3</sup> in 1904, based upon cadaveric dissections, suggested using a loop of jejunum for the reconstruction of the œsophagus. This he did by dividing the jejunum a short distance distal to the duodenojejunal junction. The proximal end he anastomosed to the distal portion about 20 to 30 centimetres below the division. The mobilized loop was brought up with the mesentery attached through the transverse mesocolon, the lesser sac, and the gastrocolic omentum to lie anterior to the stomach. The loop was brought anterior to the thorax under the skin. As a third stage, he suggested the reconstruction of a skin tube according to the technic of Bircher and a final anastomosis with the cervical œsophagus. In this way the food passing through the new œsophagus would not enter the stomach, but would empty directly into the jejunum. Roux,<sup>4</sup> in 1907, published the results of the first successful anterothoracic œsophagoplasty, which he performed in a child suffering with a benign stricture of the œsophagus. The procedure which he used differed from that suggested by Wullstein in that instead of a Y-anastomosis, he mobilized a free loop of bowel, anastomosed oral and aboral ends of the non-mobilized jejunum, and brought the jejunal loop and attached

mesentery which was partially divided to allow freer mobilization around the transverse colon. The aboral end of the mobilized segment was anastomosed by an end-to-side anastomosis with the anterior surface of the stomach similarly as in a Tavel gastrostomy. The oral end of the mobilized segment, after tunneling under the skin of the anterior thorax up to the suprasternal notch, was placed subcutaneously anterior to the thorax. At a subsequent operation after the jejunal loop had been shown to be viable, an anastomosis between the cervical œsophagus and the jejunal loop was accomplished. In 1911 Hirsch,<sup>5</sup> on the basis of observations made on cadavers and dogs, suggested that a gastric tube formed from a flap prepared from the anterior surface of the stomach be used in the construction of an anterothoracic œsophagus. He felt that such a tube would have the distinct advantage over a cutaneous tube in that the former would possess peristaltic movement. Shortly after this, in 1912, Jianu<sup>6</sup> described a method of œsophagoplasty which had been previously suggested as a method of gastrostomy by Carl Beck<sup>7</sup> (Fig. 1). This consisted of the formation of a tube from the greater curvature of the stomach. Concomitant with Jianu, Halpern<sup>8</sup> suggested the formation of a gastric tube from the greater curvature of the stomach and his technic differed from that of Jianu only in that he used curved clamps. He stated that in the normal cadaver, the new œsophagus could be made to extend up to the neck and that if the lowest costal cartilages 4 centimetres from the sternal attachment be resected, it could be brought up to the edge of the thyroid cartilage. He was successful in performing such an œsophagoplasty in dogs. In the same year, Fink<sup>9</sup> reported a case in which he had performed an anterothoracic œsophagoplasty, using the stomach for the new œsophagus. He divided the duodenum at the junction of the horizontal and vertical portions, freed the stomach of its attachments except at the cardiac end, and placed the mobilized viscus beneath the skin of the anterior thorax, following which a posterior gastroenterostomy was done. The operation was completed by constructing a skin tube extending from the upper end of the duodenum to the suprasternal notch. At a second stage the cervical œsophagus was mobilized and divided transversely. The upper end was anastomosed to the skin tube. Following this, the patient was able to swallow, but died within a few days as a result of perforation of the carcinoma at the cardia of the stomach. Kirschner<sup>10</sup> (1920) also used the mobilized stomach for the reconstruction of the œsophagus, but his technic differed from that of Fink in that the stomach was divided immediately below the cardia and after being mobilized was brought up through a subcutaneous tunnel anterior to the thorax in an isoperistaltic manner. The lower end of the œsophagus was anastomosed with the jejunum by means of a Murphy button. The mobilized stomach, after division of its mesenteric attachments along the lesser and greater curvatures, could be drawn out into a long tube and made to reach up the cervical region. In this way a tube placed isoperistaltically, one well supplied with blood and one long enough to reach to the cervical region without an intervening portion of skin could be formed (Fig. 1). In 1911, Kelling<sup>11</sup> in a forty-five-year-old woman

## ŒSOPHAGOPLASTY FOR STRICTURES OF ŒSOPHAGUS

with a carcinoma of the œsophagus performed a two-stage œsophagoplasty using the transverse colon. The distal end of the mobilized segment was anastomosed to the stomach, whereas the proximal end was brought up through a

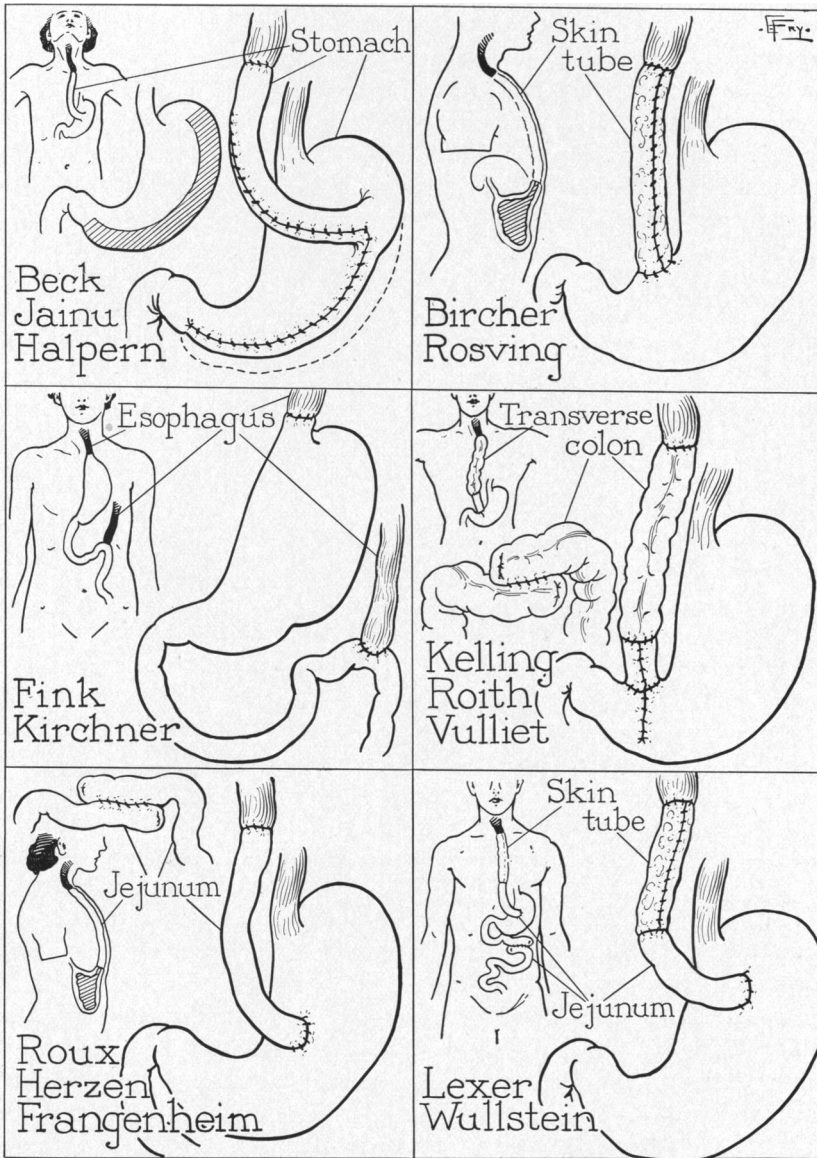
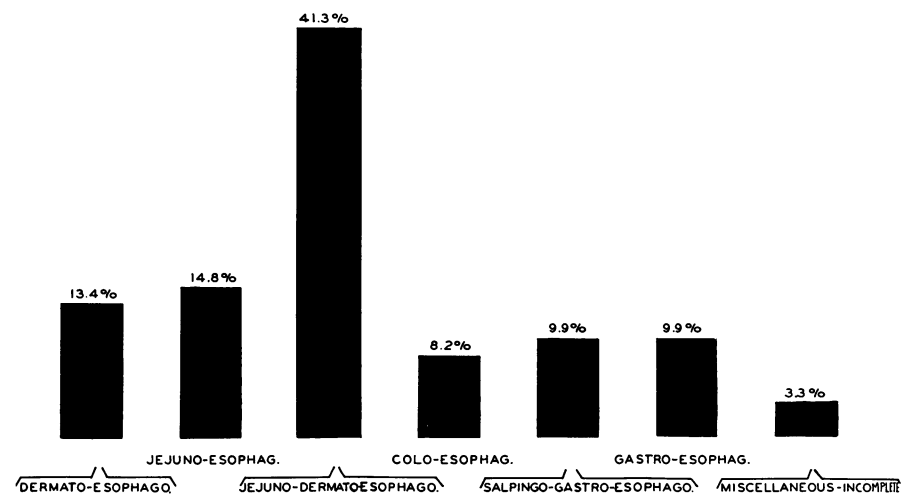


FIG. 1.—Diagrammatic drawing showing the various types of anterothoracic œsophagoplastic operations.

subcutaneous tunnel to the level of the nipple. Three weeks later the cervical œsophagus was mobilized and sutured to the cervical fascia below the skin, and a skin tube was formed between the œsophageal fistula and the opening in

the transverse colon. An anastomosis between the œsophageal fistula and the upper end of the skin tube was never accomplished, because the patient died of a carcinoma before this could be done. Modifications in the technic of colo-œsophagoplasty have been made by Vulliet and Roith<sup>12</sup> as follows: The former used a loop of transverse colon antiperistaltically, whereas the latter used the cæcum, ascending colon, and the right half of the transverse colon as a tube for the reconstruction of the œsophagus. A modification in the construction of a skin tube in an œsophagoplasty was suggested by Esser,<sup>13</sup> which consisted of lining a tunnel under the skin of the thorax with inlay Thiersch grafts placed on a "stent." He hoped to make the operative procedure simpler than construction of the skin tube according to the technic of Bircher and described two cases in which it was done.

## PERCENTAGE INCIDENCE OF OPERATIONS



GRAPH I.—Graph showing the percentage incidence of various operations used in performing the anterothoracic œsophagoplasty.

The various operative procedures employed in the reconstruction of an anterothoracic œsophagus may be classified as follows: I. Dermato-œsophagoplasty, use of skin alone: (A) Full thickness skin (Bircher). (B) Thiersch inlay grafts lining skin tunnel (Esser). II. Jejuno-œsophagoplasty, use of small bowel alone: (A) Mobilization of jejunal segment anterior to transverse colon (Roux). (B) Mobilization of jejunal segment through lesser sac (Herzen).<sup>14</sup> III. Jejuno-dermato-œsophagoplasty, use of small bowel and skin tube: (A) Y-anastomosis of jejunum (Wullstein).<sup>15</sup> (B) Jejunal segment anastomosed to stomach (Lexer).<sup>16, 17, 18, 19</sup> IV. Colo-œsophagoplasty: (A) Transverse colon, (1) isoperistaltic (Kelling); (2) antiperistaltic (Vulliet). (B) Ascending colon (Roith). V. Gastro-œsophagoplasty: (A) Salpingo-gastro-œsophagoplasty. Formation of tube from stomach, (1) from greater curvature (Beck-Jianu-Halpern); (2) from anterior surface

## ŒSOPHAGOPLASTY FOR STRICTURES OF ŒSOPHAGUS

(Hirsch). (B) Gastro-œsophagoplasty, use of entire stomach, (1) anti-peristaltically (Fink); (2) isoperistaltically (Kirschner).

Our interest in œsophagoplasty was stimulated by a case which we have had, a report of which will be included in this presentation. In order to evaluate the various operative procedures, we have reviewed all of the cases in which an anterothoracic œsophagoplasty has been reported up to the present time. Unfortunately, many of the reports are incomplete so that little could be gotten from the case except the type of operation and possibly the end-results. As many of the cases were operated upon in Russia and reported only in the Russian language great difficulty was encountered in obtaining accurate data. The majority of patients have been operated upon in the German, Austrian, Russian, and Scandinavian clinics. Relatively few have been operated upon in the English-speaking countries, particularly America. As a matter of fact, there is at the present time no case on record of a completed œsophagoplasty having been performed in America. The present study is based on an analysis of 240 cases in which œsophagoplasty was done for either benign or malignant strictures. In these 240 cases, 242 types of operation were used, the discrepancy between the number of cases and the types of operation being due to the fact that in two cases two types of operations were used, one failing and the surgeon resorting to another procedure before obtaining satisfactory results. In one of these patients Rehn<sup>20</sup> originally produced a Jianu gastric tube. Because, however, of the complete digestion of the gastric tube and the surrounding skin, it was subsequently necessary to mobilize a loop of jejunum and this together with a skin tube to reconstruct an œsophagus. The other case in which a second type of operation was necessary was reported by Hübler<sup>21</sup> in 1928. Originally a jejuno-dermato-œsophagoplasty was performed, but because of the development of a peptic ulcer in the jejunal loop, it became necessary to resect the loop and replace it with a segment of transverse colon. Of the 242 operations performed in the 240 patients the operative procedure employed was as follows (Chart I):

CHART I

Type of Operation	Number of Cases	Percentage of Whole
Dermato-œsophagoplasty . . . . .	32	13.4
Jejuno-œsophagoplasty . . . . .	36	14.8
Jejuno-dermato-œsophagoplasty . . . . .	100	41.3
Colo-œsophagoplasty . . . . .	20	8.2
Salpingo-gastro-œsophagoplasty . . . . .	24	9.9
Gastro-œsophagoplasty . . . . .	22	9.1
Miscellaneous and incomplete . . . . .	8	3.3

DERMATO-ŒSOPHAGOPLASTY.—Of the thirty-two cases in which only skin was used to reconstruct the œsophagus, thirty were operated upon according to the technic of Bircher: *i.e.*, a tube was formed from the skin of the anterior thorax by making parallel incisions approximately 6 to 8 centimetres apart extending from the cervical to the epigastric regions. The edges of the flaps

so formed were mobilized and sutured in such a way that the cutaneous surface formed the lining of the tube. Over this lateral skin flaps were mobilized to cover the newly formed skin tube (Fig. 1). In two of the thirty-two cases the skin tube was constructed according to the technic of Esser: *i.e.*, a subcutaneous tunnel was lined with Thiersch inlay grafts. In the group of thirty-two patients there were ten males and eleven females, whereas in eleven the sex was not stated. The cause of the œsophageal obstruction was cicatricial stenosis following ingestion of lye in eleven cases, hydrochloric acid in three cases, acetic acid, and sulphuric acid, each one case. Carcinoma was the cause of obstruction in two cases, whereas in fourteen the cause of obstruction was not stated. In twenty in which the age was given the oldest was fifty-five, the youngest six, and the average 24.2 years. Of the ten in which lye was the cause of obstruction in which the age was stated, the oldest was forty-two, the youngest six, and the average 22.9 years. Of the two patients with carcinoma, in only one was the age stated (forty-one years). Of the twenty cases in which the number of operations employed was stated, the largest number in any one case was eight, the least was one, and the average, 4.5 operations. The longest duration in the fifteen in which this was stated was eleven years, the shortest eight months, and the average 3.8 years. Of the thirty-two patients operated upon, twenty-one (70 per cent.) recovered, nine (30 per cent.) died. In two the result was not given. The operation was completed in nineteen (53.3 per cent.) of the patients, not completed in eleven (33.6 per cent.). In two no statement was made concerning completion. In twelve the function was classified as good, in two as fair, and in one as poor. In six it was not stated. The fourteen cases in which good or fair results were obtained represent 46.6 per cent. of all the cases operated upon, and 73.6 per cent. of those in which the operation was finished. The reconstruction of the œsophagus from skin alone has many advantages and disadvantages. An important advantage is that a minimal amount of intraperitoneal manipulation is necessary, whereas the mobilization of a segment of small or large bowel is a much more formidable procedure. Another advantage is that the entire skin tube can be made in one stage, shortening the hospitalization considerably. On the other hand, a distinct disadvantage of the dermato-œsophagoplasty is the danger of digestion of the skin tube by gastric contents because of the direct anastomosis of the lower end of the skin tube with the stomach. The vulnerability of the skin tube is illustrated by the number of complications in the group of thirty-two in which a dermato-œsophagoplasty was done. In eleven it was not stated whether any complications were present. Fistulæ, either single or multiple, occurred in eighteen instances, pneumonia in three, gangrene of the œsophagus in one, gangrene of the skin tube in one, infection in one, and an embolism in one. Another proposed disadvantage of the skin tube, which, however, has not been substantiated, is that the skin tube cannot function as well as bowel because it lacks peristalsis. Schreiber<sup>22</sup> fluoroscopically demonstrated in patients operated upon by Lexer and Frangen-

## ŒSOPHAGOPLASTY FOR STRICTURES OF ŒSOPHAGUS

heim<sup>23, 24, 25, 26</sup> that ingested contrast substances passed more rapidly through the skin tube than through the jejunal tube. Zaijer<sup>27, 28, 29</sup> has also corroborated this finding. The passage of substances through the skin tube which obviously lacks peristaltic movement is the result of the squirting action of the pharynx, which could be readily demonstrated in our case before the skin tube was anastomosed with the jejunal tube (Fig. 2). Repeatedly we have been able to demonstrate that concomitantly with the act of swallowing water would be forcefully ejected from the lower end of the skin tube. That gravity is not necessary for the passage of food through the newly formed œsophagus has been shown röntgenologically by Frangenheim and Sampson,<sup>30</sup> the former observing that the contrast substance passed through the œsopha-

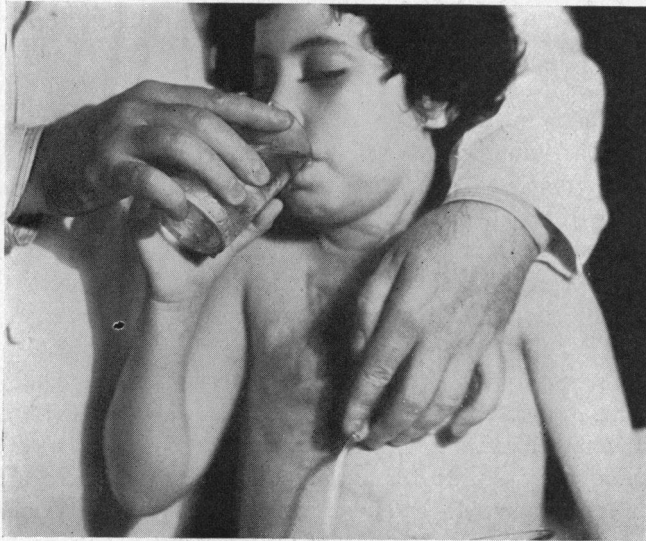

FIG. 2.—Photograph showing patient swallowing water, demonstrating its passage through the cervical œsophagus and out through the skin tube portion. A rubber tube has been inserted in the lower portion of the skin tube in order to facilitate the passage of the water and to make it more demonstrable for photography.

gus with the patient in the horizontal position, whereas the latter demonstrated that the contrast substance passed through the œsophagus with the patient even in the inverted-head position.

JEJUNO-ŒSOPHAGOPLASTY.—Thirty-six (14.8 per cent.) of the œsophagoplastic operations were performed by using only a loop of jejunum in the reconstruction of the œsophagus (Fig. 1). In this group there were twelve males and nine females, whereas in fifteen the sex was not stated. The etiology was as follows: Cicatricial stenosis following lye, seven cases; ammonia, sulphuric acid, acetic acid, hydrochloric acid, and silver nitrate each one case; benign stricture, the cause of which was not stated, four cases. In ten cases the cause of the obstruction was carcinoma. One case followed an œsophageal fistula after an empyema and in nine the cause was not stated.

Of the eighteen in which the age was stated the oldest was sixty-one, the youngest six and one-half, and the average 36.3 years. Of the seven cases which followed lye ingestion, the ages were given in five; the oldest was thirty-five, the youngest six and one-half, and the average 20.7 years. Of the ten cases in which carcinoma was the cause of obstruction, the ages were given in only three, the oldest being sixty-one, the youngest forty-eight, and the average 54.3 years. In the twenty-three cases in which the number of operations performed was stated, the largest number was six, the least number one, and the average 2.2 operations per patient. In eighteen the number of operations was not stated. There was considerable variation in the duration of symptoms before operation, the longest ten years, the shortest four months, and average 1.8 years. In twenty-six cases the duration of symptoms was not stated. Of the thirty-six cases, sixteen recovered, fourteen died, whereas in six it was not stated whether recovery occurred. Of the thirty in which the result was given, 53.3 per cent. recovered and 46.6 per cent. died, an almost prohibitive mortality rate. Of the thirty-six cases, in six it was not stated whether the operation was completed. Of the remaining thirty, thirteen (43.3 per cent.) were completed, whereas seventeen (56.6 per cent.) were incomplete at the time of the report. In twelve cases it was stated that the function was good, giving a ratio of 40 per cent. of all the cases started and 92.3 per cent. of those completed. The greatest number of complications (eight) consisted of interference with the circulation of the mobilized segment of bowel resulting in gangrene. Peritonitis was present in five; single or multiple fistulæ in six; stenosis in two; pneumonia, mediastinitis, regurgitation of the gastric contents, each in one case. In sixteen cases it was not stated whether there were any complications. The high incidence of gangrene of the jejunal loop was undoubtedly due to the fact that in order to secure a sufficiently long segment of jejunum to extend up to the cervical region and in order to complete the œsophagoplasty without an intervening portion of skin, the blood supply of the loop was jeopardized. In order to secure sufficient mobilization of the jejunal loop it is almost invariably necessary to divide the mesentery in its proximal portion as first recommended by Roux. As suggested by Blauel,<sup>31, 32, 33</sup> one should determine, before cutting the root of the mesentery, the viability of the proposed jejunal segment by compressing the vessels which are to be divided. The mobilized segment of gut in such an instance would receive its blood supply from the remaining branch or branches of the superior mesenteric vessels and the marginal vessels. In order not to interfere with the marginal vessels the incision in the mesentery must be made close to the root and at some distance from the bowel. Ritter and von Haberer have emphasized that the length of intestine which may be divided depends entirely upon the number of vessels which are severed. Ritter<sup>34, 35, 36</sup> showed that if the mesentery is divided close to the gut, it is possible to mobilize the intestine for a distance of from 2 to 7 centimetres, whereas if it is divided at a considerable distance from the intestine, this length may be increased



## ŒSOPHAGOPLASTY FOR STRICTURES OF ŒSOPHAGUS

to from 8 centimetres to 15 centimetres. The original proposal of Roux that the mobilized segment of jejunum be brought around anterior to the transverse colon, which was performed four times in the present collected series, should seldom be used because of the pressure exerted by the colon on the mesentery of the mobilized segment of jejunum. In these four cases complete necrosis of the tube occurred in two, partial necrosis in one, but in the fourth a good result was obtained. One of the advantages of an intestinal segment as compared with a skin tube for anastomosis with the stomach is the relatively greater immunity of the former to the action of gastric secretions. That an ulcer may occur in the mobilized segment of jejunum is evidenced by the case reported by Hübner,<sup>37</sup> in 1928, in which it was necessary to resect the jejunal loop because of a peptic ulcer which had developed. In this particular case the operation was completed by using a loop of transverse colon.

**JEJUNO-DERMATO-ŒSOPHAGOPLASTY.**—Lexer, realizing the danger of digestion of the skin tube by gastric contents when the skin tube was anastomosed directly with the stomach and also realizing the danger of necrosis of the distal portion of a segment of jejunum when too long a portion was mobilized, suggested combining a jejunal and a cutaneous segment (Fig. 1). The former, being anastomosed with the stomach, is more resistant to the gastric juice, whereas the length of the latter can be increased any amount without danger of jeopardizing the circulation. The procedure of jejuno-dermato-œsophagoplasty has undoubtedly been judged by the majority of surgeons as the method of choice, as the largest number of operations (100) have been done according to this technic. Of the 100 cases, there were twenty-nine males, thirty-six females, whereas in thirty-five the sex was not stated. The etiology in this group was as follows: stricture following ingestion of lye, forty-three cases; hydrochloric acid, five cases; sulphuric acid, formalin, ammonia, chloric acid, and congenital, each, one case. A benign stricture, the cause of which was not stated, occurred in six instances. The obstruction was carcinomatous six times and in thirty-five the cause was not stated. Of the fifty-six cases in which the age was given, the oldest was fifty-eight, the youngest three, and the average twenty-one years. Of the thirty-eight cases with lye stricture in which the ages were given, the oldest was forty-two, the youngest three, and the average nineteen and one-half years. Of the three cases of carcinoma in which the ages were given, the oldest was fifty-eight, the youngest forty-four, and the average forty-nine. Of the seventy cases in which the number of operations was stated, the greatest number was eight, the least, one, the average 4.3 operations per person. The duration of symptoms in fifty-one in which it was stated was as follows: the longest was seventeen years, the shortest two months, the average 3.2 years before the construction of the anterothoracic œsophagus. In twenty-one no statement was made concerning whether the patient recovered. Of the seventy-nine in which this information was given, sixty-one (78.4 per cent.) recovered and eighteen (22.7 per cent.) died. In only three of the 100 operations was there no state-

ment concerning whether the operation was completed. In the remaining ninety-seven the plastic was completed in sixty-four (65.3 per cent.) and not completed in thirty-three (35 per cent.). The results were classified as good in forty-six (47.4 per cent.) of all cases started and 97.8 per cent. of those in which the operation was completed. The complications encountered in the 100 jejuno-dermato-oesophagoplastic operations were as follows: fistulæ, single or multiple, thirty-nine; stenoses, seventeen; gangrene of the jejunum, nine; necrosis of the skin, six; infection, eight; pneumonia, five; regurgitation of gastric contents, five; dilatation of the jejunum, two; peritonitis, two; ulcer of the jejunum, empyema, perforation of a carcinoma into the bronchus, psychosis, necrosis of the oesophagus, dilatation of the stomach, cyst of the oesophagus, obliteration of the jejunum, inanition and diphtheria, each, one case. In thirty-three instances the presence or absence of complications was not stated. The danger of mobilizing a sufficiently long segment of jejunum to complete the oesophagoplasty and the comparative safety of employing a short cutaneous tube is shown by contrasting the complications in the two series of cases. In the jejuno-oesophagoplastic group of thirty-six cases, gangrene of the loop occurred eight times (22.2 per cent.), whereas in the jejuno-dermato-oesophagoplastic group (100 cases) this complication resulted in nine instances (9 per cent.). The comparative safety of the jejuno-dermato-oesophagoplastic operation is shown by the incidence of peritonitis in the two groups: 13.8 per cent. in the former and 2 per cent. in the latter. The relationship of the number of anastomotic sites to fistula formation is illustrated by comparing the jejuno-oesophagoplastic and the jejuno-dermato-oesophagoplastic groups. In the former, fistulæ developed in eight instances (16.6 per cent.), whereas in the latter, they occurred in thirty-nine instances (39 per cent.). This is undoubtedly due to the fact that in the latter group there were three sites of anastomosis instead of two. The occurrence of a fistula is undesirable, but seldom is there any real difficulty in closing it. The increased tendency toward fistula formation following a jejuno-dermato-oesophagoplasty is more than offset by the advantage that the mobilized segment of bowel has a greater chance of remaining viable and therefore the danger of peritonitis is less. The greater tendency for fistulæ to develop at a cutaneous anastomosis is demonstrated by comparing the incidence of fistulæ in the dermato-oesophagoplastic group with that in the jejuno-dermato-oesophagoplastic group. Of thirty-two dermato-oesophagoplasties, fistulæ developed in eighteen (56.2 per cent.), whereas of 100 jejuno-dermato-oesophagoplastic operations, fistulæ developed in 39 per cent. A disadvantage, both from the standpoint of the surgeon and the patient, in the jejuno-dermato-oesophagoplasty is the large number of operations required to complete the plastic. The average number of operations required per person in the jejuno-oesophagoplastic group was 2.2, whereas the average number required in the jejuno-dermato-oesophagoplastic group was 4.3. The number of operations required in the dermato-oesophagoplastic group was also high, five, probably because of the high incidence of fistula. In the jejuno-

## ŒSOPHAGOPLASTY FOR STRICTURES OF ŒSOPHAGUS

œsophagoplastic group the mobilized loop of jejunum was brought through the transverse mesocolon, the lesser sac, and gastrocolic omentum, to its position in the upper abdomen, in nine instances, whereas in two instances it was brought anterior to the colon, as suggested by Roux. In the jejuno-dermato-œsophagoplastic group, the mobilized segment was brought through the lesser sac in forty-four and anterior to the colon in two.

COLO-ŒSOPHAGOPLASTY.—In twenty cases (8.2 per cent.) of the collected series, the colon was used in the reconstruction of the new œsophagus (Fig. 1). There were seven males, four females, and nine in which the sex was not stated. The cause of obstruction was as follows: Cicatricial stenosis following ingestion of lye, eight cases; stricture of unstated origin, two cases; potassium permanganate tablets, one case. In two cases the obstructing lesion was carcinoma and in seven the cause was not stated. Of the eleven in which the age was stated, the oldest was sixty years, the youngest four, the average 25.7 years. In the six cases of lye stricture in which the age was given the oldest was nineteen years, the youngest four, the average twelve years. In fifteen cases in which the number of operations was stated, the largest number was five, the least one, the average 2.8 per person. Of the twenty cases in which a colo-œsophagoplasty was done, the technic of operation was stated in twelve and not stated in eight. Of the twelve, in seven the transverse colon was used isoperistally (Kelling) and in four it was placed anti-peristally (Vulliet). In one instance the æcum, ascending colon, and right half of the transverse colon were used for the formation of the œsophagus (Roith). This was successfully accomplished in one stage, the patient being able to eat on the eighth day and discharged seventeen days after operation. In ten cases in which the duration of symptoms before the beginning of the œsophagoplastic operation was stated, the longest was ten years, the shortest seven months, the average 3.1 years. As regards results, in two of the twenty cases no mention was made concerning the recovery. Of the remaining eighteen, fourteen (77.7 per cent.) recovered and four (22.2 per cent.) died. In two of the twenty cases, no statement was made concerning the completion of the operation. Of the remaining eighteen, the operation was completed in eleven (61.1 per cent.) and not completed in seven (38.8 per cent.). The end-results were termed as excellent in three, good in six, and fair in one, giving a total of 55.5 per cent. of fair to excellent results of all the cases in which the operation was started, and 90 per cent. good results in the cases completed. The complications consisted of fistulæ, single or multiple, seven; stenoses, three; infection, mediastinitis, gangrene of the œsophagus, each two cases; pouch in the colon tube, progression of carcinoma, progressive weakness, lobular pneumonia, peritonitis, leakage from a colocolostomy, and dilatation of the colon tube, each one case. The advantage of using a segment of colon in the reconstruction of the œsophagus is the ease with which a relatively long loop, the viability of which is quite definite, can be secured. As illustrated by Roith's case in which the entire œsophagoplasty was completed in one stage and the patient discharged seven-

teen days post-operatively, there is a great deal of merit in the procedure. One can hardly recommend, however, such a formidable one-stage procedure of mobilizing the ascending and right half of the transverse colon, reestablishing the continuity of the bowel by an ileocolostomy, anastomosing the distal end of the mobilized segment to the stomach, extending the mobilized segment through a skin tunnel of the anterior thorax to the neck, freeing the cervical œsophagus and anastomosing it to the mobilized colon segment. The percentage of recoveries in this group was greater than any other group, almost identical with that in the jejuno-dermato-œsophagoplastic group, 77.7 per cent. and 77.2 per cent., respectively. In the jejuno-dermato-œsophagoplastic group, the incidence of the completed cases (65.3 per cent.) was somewhat greater than in the colo-œsophagoplastic group (61.1 per cent.). A good result was obtained in 55.5 per cent. of all the cases in which a colo-œsophagoplasty was attempted as compared with 47.4 per cent. in the jejuno-dermato-œsophagoplastic group. A distinct disadvantage in the use of the colon is the extremely slow emptying time, the ingested food remaining in it for long periods of time before entering the stomach. Von Hacker in one of his cases found that an hour after a contrast meal more barium remained in the colonic œsophagus than had passed into the stomach.

**SALPINGO-GASTRO-ŒSOPHAGOPLASTY.**—In twenty-four (9.9 per cent.) of the cases the œsophagus was formed in whole or in part by means of a tube from the stomach (Fig. 1). In the majority of instances (70.8 per cent.), the tube was obtained from the greater curvature of the stomach and placed in an antiperistaltic manner anterior to the thorax with its attachment in the region of the cardia according to the technic of Beck-Jianu-Halpern. Of the twenty-four, six (25 per cent.) were performed according to the technic of Hirsch; *i.e.*, the gastric tube was formed from a flap of the anterior wall of the stomach and in one (4.1 per cent.), the tube from the greater curvature was formed in such a way that it was attached to the stomach at the pylorus and functioned isoperistaltically. There were eleven males, eight females, and five in which the sex was not stated. The etiology in the group was as follows: lye, seven cases; carcinoma, six cases; benign stricture, cause not stated, eight cases; ammonia and hydrochloric acid, each, one case, and one case in which the etiology was not stated. In twelve cases in which the ages were given the oldest was sixty-eight, the youngest four, the average thirty-one years. Of the six patients with lye stricture in which the ages were given, the oldest was thirty-one, the youngest four, the average nineteen. In the four patients with cancer in which the ages were given, the oldest was sixty-eight, the youngest forty-six, the average fifty-six. The greatest number of operations in any case was eight, the least one, the average two. In the eleven instances in which the duration of symptoms before operation was stated the longest was ten years, the shortest six weeks, the average 2.7 years. In the twenty-four cases, no statement was made concerning the recovery of the patient in six. Of the remaining eighteen, thirteen (72.2 per cent.) recovered, and five (27.7 per cent.) died. Of the twenty-four, in

## ŒSOPHAGOPLASTY FOR STRICTURES OF ŒSOPHAGUS

only two (8.3 per cent.) was the operation completed, whereas in twenty-one (91.6 per cent.) it was not completed. In only twenty was the statement made whether the operation was completed. It was completed in two (10 per cent.) and not completed in eighteen (90 per cent.). In none of the six cases in which a tube was constructed from a flap of the anterior surface of the stomach (Hirsch) was the operation completed. Similarly the formation of the gastric tube from the greater curvature with the gastric attachment at the pylorus in the case reported by Grigorjev<sup>38</sup> was never completed. The function was stated to be good in two (8.3 per cent.) of those started and 100 per cent. of those completed. The complications were as follows: fistulæ, four; necrosis of the gastric tube, four; regurgitation of the gastric contents, four; necrosis of the skin tube, three; necrosis of the œsophagus, stenosis, peritonitis, pneumonia, each, two; mediastinitis and infection, each, one. The extremely low percentage of cases in which the operation was carried to completion was appalling. There is indeed a great discrepancy between the percentage of those cases which recovered (72.2 per cent.) and those in which the operation was completed (10 per cent.). These figures indicate that the lack of completion was due not to the death of the individual, but rather due to technical difficulties or refusal of the patient to continue with the therapy. The high incidence of regurgitation of gastric contents (16.6 per cent.) was probably due to the fact that peristalsis through the tube was away from the stomach in seventeen of the twenty-four cases, which would tend to carry the gastric contents on to the thoracic wall. In several cases this regurgitation of gastric contents was responsible for the digestion of the skin surrounding the tube. The danger of skin digestion resulting from the contact with the gastric secretions in the gastric tube is the same as in those cases in which a skin tube is anastomosed directly to the stomach. Jianu hoped to be able to secure a sufficiently long tube from the stomach to reach to the cervical region in order that a direct anastomosis between the gastric tube and œsophagus could be made, without an intervening skin tube. This was accomplished in only one case reported by Lotheissen.<sup>39, 40, 41</sup> The gastro-œsophageal anastomosis failed to hold, however, resulting in a fistula which required subsequent excision of scar. The case was never completed; the defect was bridged by means of a rubber tube.

**GASTRO-ŒSOPHAGOPLASTY.**—In twenty-two (9.1 per cent.) cases the entire stomach was mobilized and used for the formation of the anterothoracic œsophagus. In six cases the operation was performed according to the technic of Fink; *i.e.*, the duodenum was divided at the junction of the horizontal and vertical portions, the distal end of the duodenum closed blindly, the stomach freed of its attachments except at the cardia, a posterior gastroenterostomy done, and the duodenal end brought up to the cervical region in an anti-peristaltic manner deep to the skin of the thorax. In sixteen the stomach was placed anterior to the thorax isoperistaltically according to the technic of Kirschner; *i.e.*, the stomach was divided just below the cardia, the lower end of the œsophagus anastomosed with a loop of jejunum, the stomach mobilized

and placed subcutaneously anterior to the thorax up to the cervical region. In one patient reported by Kümmell,<sup>42</sup> in 1921, the lower end of the œsophagus was not anastomosed to the jejunal loop as suggested by Kirschner, but was closed blindly. Kümmell thought this to be permissible because of a complete impermeable stricture in the œsophagus. A leakage of the œsophageal suture line resulted in a fatal peritonitis. In the twenty-two cases in which a gastro-œsophagoplasty was done there were eight males and five females, and nine in which the sex was not stated. The etiology of the stenosis was as follows: lye stricture, five; carcinoma, six; benign stricture, cause not stated, cardiospasm, and congenital stricture, each, one case. In five instances the cause of the obstruction was not stated. In thirteen cases in which the age was stated, the oldest was sixty, the youngest was eleven, the average 38.7 years. Of the five patients with lye stricture, the oldest was fifty-five, the youngest eleven, the average thirty-seven. Of the six patients with carcinoma, the oldest was sixty, the youngest forty-six, the average 50.5. The greatest number of operations required in any one case was six, the least one, the average 1.6. Ritter and Roith were able to complete the gastro-œsophagoplasty according to the technic of Kirschner in one stage. In both instances, however, the patient died shortly after the operation. Roith prefers a colo-œsophagoplasty to a gastro-œsophagoplasty because the latter procedure must be done in one stage, whereas the former can be done in several stages. Henschen,<sup>43</sup> in his second case, performed an anterothoracic gastro-œsophagoplasty, apparently in one stage, although the details are not given. The œsophagus functioned well, but the patient died six weeks later of a miliary tuberculosis. In the cases in which the duration of symptoms before operation was stated, the longest was thirty-two years in a patient with a congenital stricture, the shortest two months, the average 3.95 years. Results were given as regards the recovery following the operation in twenty-one of the twenty-two cases. Seven (33.3 per cent.) recovered, whereas fourteen (66.6 per cent.) died. Of the twenty-two cases, ten (45.4 per cent.) were completed and twelve (54.5 per cent.) were not completed. The end-result as regards function was stated to be good in six, 28.5 per cent. of those in which the operation was attempted and 60 per cent. of those in which the operation was completed. The mortality rate in the isoperistaltic gastro-œsophagoplastic group (Kirschner) was the same (66 per cent.) as in the antiperistaltic gastro-œsophagoplastic group (Fink). The operation was completed in 50 per cent. of the latter group, whereas in the former it was completed in only 43.7 per cent. of the cases. Of the cases in which the type of operation was stated the function was good in 3.3 per cent. of those done by the Fink technic and in 25 per cent. of those done by the Kirschner technic. It is only fair to state that of the ten fatal cases operated upon by the Kirschner technic, in five the obstruction was carcinoma which undoubtedly had a great deal to do with the high mortality rate.

In addition to the above types of operation described in the literature there were eight cases of anterothoracic œsophagoplasty (3.3 per cent. of the entire

## ŒSOPHAGOPLASTY FOR STRICTURES OF ŒSOPHAGUS

series) reported in which the type of operation was not stated. The details in this group of cases are very meager. In one of the cases the obstruction was stated to follow lye ingestion. In another, the cauterizing agent was sulphuric acid. In the remaining instances the etiological agent was not mentioned. The results as regards recovery were stated in six and not in two. Of the six, four (66.6 per cent.) recovered, whereas two (33.3 per cent.) died. In six the statement was made whether the operation was completed. In two (33.3 per cent.) the operation was completed, whereas in four (66.6 per cent.) the operation was incomplete at the time of the report. The function was stated to be good in only two of the cases; whereas in the others no statement was made concerning the outcome.

*Formation of a Skin Tube.*—Of the various plastic operations in which a segment of colon, a tube from the stomach or the entire stomach were used in the reconstruction of the œsophagus, in only fourteen instances in which sufficient data were given was a skin tube unnecessary to complete the œsophagus. In 124 instances, however, it was definitely stated that a skin tube was used either alone or as an adjunct in the formation of the anterothoracic œsophagus. In thirty-seven cases in which formation of a skin tube was contemplated, the tube could not be used because the operation was not completed. Undoubtedly, in many more, skin tubes were also employed but data were not given. Also in a very large number of instances the anastomosis between the mobilized intestinal segment and œsophagus and also between the skin tube and intestinal segment were accomplished by means of skin flaps. The largest single group of patients in which only a skin tube was used was that reported by Braizew.<sup>44</sup> This author, in 1929, reported seven cases with completed dermato-œsophagoplasties operated upon between 1925 and 1927. One case with an obstruction at the gastrocutaneous junction subsequently died of otitis media. In another there was some stenosis at the dermato-œsophageal junction. In the remaining five cases the result was excellent.

The tube in the majority of instances is formed from full thickness skin by making parallel incisions of the desired length and mobilizing the skin flaps on either side, preferably eccentrically as was done in our case in order that the suture line does not lie immediately below the suture line in the skin covering the tube. A sufficiently wide base is left attached to insure adequate blood supply to the flaps. By mobilizing the edges and approximating the skin edges an epithelial lined tube is produced (Fig. 3). Esser, on the other hand, advocated the production of a skin tube by tunneling under the skin of the anterior thorax and placing in the tunnel so constructed, Thiersch inlay grafts over a mold. He reported two cases so treated, only one of which was apparently completed. Kirschner in his first case attempted to bridge the defect between the œsophageal and the gastric fistulæ by means of a skin tube constructed according to the technic of Esser. This was unsuccessful, however, due to the suppuration of the wound. He emphasizes the importance of waiting a period of time and employing measures to

“toughen” the Thiersch graft tunnel before anastomosing the œsophagus and the stomach to it. In order to prevent a regurgitation of the gastric contents which might destroy the less resistant Thiersch grafts, he constructed a valve-like mechanism which consisted of a sac made of a pedicle flap, which became filled during regurgitation and would compress the lower end of the tube. The majority of authors are agreed at the present time that a Thiersch grafted tube is not sufficiently viable for use in an œsophagoplastic operation. As a matter of fact, the consensus of opinion is that the anastomosis of an even full thickness skin tube directly with the stomach is not desirable because of the digestion of the skin tube by regurgitated gastric contents.

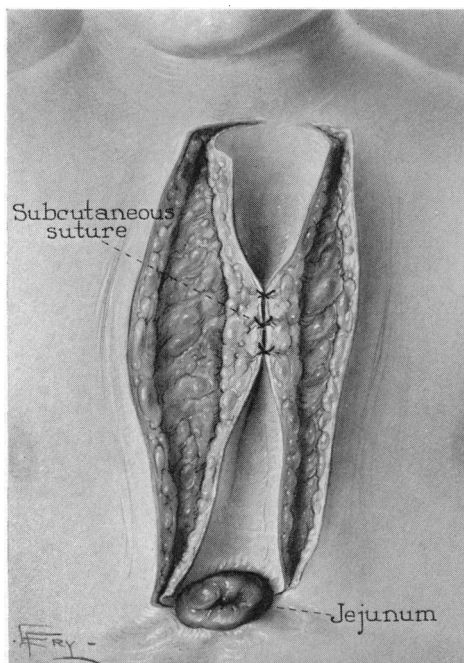


FIG. 3.—Drawing showing formation of cutaneous tube by means of parallel incisions through the skin of the anterior thorax. The skin flaps so mobilized are sutured in such a way that the cutaneous surface lines the tube on the inside. At the lower portion of the drawing, the upper end of the jejunal loop is visible.

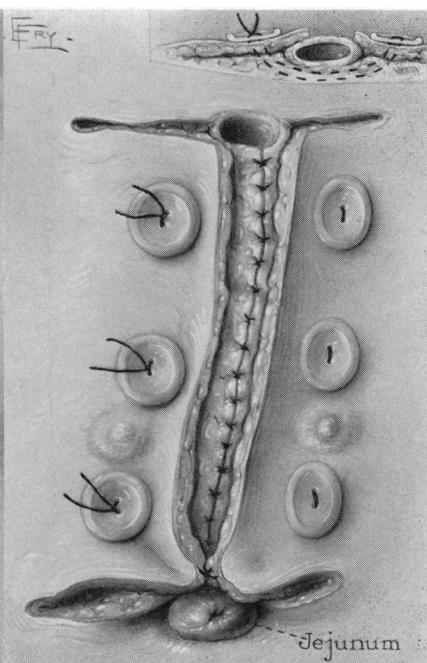


FIG. 4.—Drawing showing the covering of the skin tube by mobilization of the lateral skin edges on either side. Retention sutures are placed over buttons, the sutures passing deep to the œsophagus in order that pressure on the œsophagus is not exerted. Closure of the skin covering the newly formed skin tube. The upper end of the jejunum is visible.

In order to prevent this regurgitation of gastric contents into the newly formed œsophagus, Lotheissen advocated the formation of a valve-like mechanism at the lower end of the jejunal tube. Braizew attempted to secure the same result by means of a sling-like valve mechanism constructed from the fibres of the rectus muscle around a conus of the stomach brought out of the abdomen.

The construction of the skin tube offers little or no difficulty, and it is probably of little advantage to form it over a rubber tube as has been sug-



## ŒSOPHAGOPLASTY FOR STRICTURES OF ŒSOPHAGUS

gested. It is imperative, however, as shown by many cases that if a rubber tube is used as a mold over which the skin tube is constructed the tube should not be left *in situ* post-operatively, because of the danger of producing necrosis at the suture line (Stieda,<sup>45, 46</sup> Fromme<sup>47</sup>). Following construction of the skin tube, the tube and the area from which the flaps are obtained must be covered in some way. Preferably this is done by mobilizing the skin of the thorax on either side well toward the anterior axillary line (Fig. 4). In some instances this mobilization may be accomplished without any difficulty and without the use of relaxing incisions. In the majority of instances, however, it is necessary to make liberal relaxing incisions on one or both sides. The error was made in our case that at the time of the production of the skin tube, the relaxing incisions were not sufficiently large to produce enough relaxation. As a result the tension was so great that the overlying skin and the upper portion of the tube gave way. There must be no tension on the suture line which may be relieved by means of retention sutures, preferably employing buttons on either side to distribute the pressure over the wide area. These retention sutures should be passed deep to the newly formed œsophageal tube in order not to exert too much pressure on the tube itself (Fig. 4). There is no general agreement concerning the time at which the skin tube should be produced. We feel that because of the greater possibility of asepsis the skin tube should be produced before the œsophageal fistula is performed. Blauel and Lotheissen, on the other hand, believe that the first stage of the œsophagoplasty should consist of an œsophageal fistula as in this way it will give sufficient time for the correction of the dermat-œsophageal stenosis while the other stages are completed. In addition, if a patient has an œsophageal fistula, it is possible for him to eat normally by connecting the œsophageal and gastric fistulæ with a rubber tube. In this way the general condition of the patient can be markedly improved because of the better mastication of food and the utilization of the salivary secretion. That such a procedure is not absolutely necessary is demonstrated by the excellent condition of our patient obtained by proper gastric tube feeding.

The majority of investigators are agreed that a preliminary gastrostomy should always be done for two reasons: (1) because occasionally a cicatricial stricture, apparently impermeable, put at rest by the use of a gastrostomy will become permeable, and the œsophagoplastic operation be unnecessary; (2) these patients, because of their inability to secure adequate nourishment, are invariably in poor condition and unable to withstand a formidable operation. Through the gastric fistula it is possible for the patient to be fed pre-operatively and prepared for operation. Lotheissen is a staunch advocate of a preliminary gastrostomy. He states that two patients were sent to him with supposedly impermeable benign œsophageal strictures for œsophagoplasty which became permeable after a gastrostomy had been performed. Many of the patients, as in our own case, are admitted to the hospital with a gastrostomy, but if such is not the case a preliminary gastrostomy should always be done. Kirschner is of the opinion that a gastrostomy is not necessary, but

believes that patients can be fed through the gastric opening in the mobilized stomach. He feels that the presence of the gastrostomy makes the œsophago-plastic operations more difficult. Hirsch advocates that a jejunostomy should be done rather than a gastrostomy so that the anterior surface of the stomach is free for the development of a gastric tube. Lotheissen does not subscribe to this view, because he believes it is unnecessary and also because a jejunostomy does not permit retrograde bouginage. In the present series gastrostomy was done in 115 instances, was not done in twenty-three instances and in 104 it was not stated.

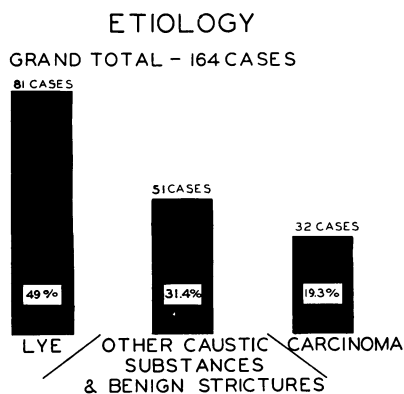
*Mobilization of Œsophagus.*—There is considerable disagreement among authors concerning the method of handling the cervical œsophagus. In the majority of instances the œsophagus has been mobilized through an incision along the anterior border of the sternocleidomastoid, as in this way it is possible to mobilize the œsophagus well into the mediastinum. Madlener,<sup>48, 49</sup> however, prefers the Kocher collar incision. In the present series in which it was stated, the cervical œsophagus was divided transversely in fifty-six and a lateral anastomosis was made in thirty-four. In six the œsophagus was resected for carcinoma. In twenty-three the operation was not completed to the stage of mobilization of the œsophagus and in the remaining cases it was not stated what type of operation was used on the cervical œsophagus. There are distinct advantages and disadvantages of each method. Theoretically, the ideal procedure seems to consist of the transverse division of the œsophagus and blind closure of the lower end with axial anastomosis of the upper end with either the skin tube, colon, jejunum, or stomach, as in this way the current of food is carried from the cervical œsophagus directly into the newly formed œsophagus. In case the œsophagus is not divided but an opening made in the lateral wall for anastomosis with the new œsophagus, ingested material passes into the anterothoracic œsophagus only after the blind pouch of the original œsophagus distal to the anastomosis has filled. The ingested material then spills over into the new œsophagus. Stagnation, putrefaction, ulceration, and even perforation, are apt to occur in the blind pouch. Following lateral anastomosis perforations of the blind pouch with resulting mediastinitis have been reported by Nicolaysen<sup>50, 51, 52</sup> and Blauel. Transverse division and blind closure of the distal portion of the œsophagus is also not without danger. Contamination of the mediastinum from the retracted distal segment may result fatally as in the case of Hauck. Denk<sup>53</sup> warns against the blind closure of the distal segment because of the danger of increased mucous secretion and possible perforation. Ideally, if the œsophagus can be mobilized down to the point of stricture and divided at that point and closed, little or no trouble should be encountered. Lotheissen reports a case, however, in which this was done, the lower end not being ligated. The fistula became patent and the patient developed a purulent mediastinitis. There is some danger if the lower end is closed blindly of the development of a cyst, as reported by Heyrovsky.<sup>54, 55</sup> This is due to the accumulation and retention of secretion in the blind segment of œsophagus.

## ŒSOPHAGOPLASTY FOR STRICTURES OF ŒSOPHAGUS

The lower end of the œsophagus if closed blindly should be brought out either at the lower end of the cervical wound or in a wound posterior to the sternocleidomastoid muscle, as suggested by Schreiber, Esser, and Bornhaupt. In this way, if any leakage should occur, it will escape to the outside. In order to prevent accumulation of mucus in the distal portion of the transversely divided œsophagus, Heyrovsky anastomosed the lower end of the œsophagus with the side of the skin tube. Because this anastomosis became stenotic, however, a large cyst of the œsophagus developed in the mediastinum. The operation was not successful. The danger of stenosis in the axial anastomosis is much less than in the lateral anastomosis. Axhausen<sup>56, 57, 58</sup> and Blauel, however, believe that the tendency toward stenosis in a lateral œsophageal anastomosis can be obviated by suturing the opening in the lateral wall of the œsophagus to skin flaps in order that there is no tension between the œsophageal mucosa and the skin. They are of the opinion that the tendency toward stenosis at the dermato-œsophageal junction is due entirely to the tension on the suture line. In the present series the lower end of the œsophagus was closed blindly in thirty-seven instances, in four instances it was left open, and in 136 instances no statement was made. The lower end of the œsophagus has been closed blindly by Herzen, Exner,<sup>59</sup> Frangenheim, Ranzi,<sup>60</sup> Marwedel,<sup>61, 62</sup> and in our case. The advocates of the lateral anastomosis are Lexer, Frangenheim, Rehn, Stieda, and Blauel. Hirschmann<sup>63, 64, 65</sup> and Blauel are convinced that the anastomosis between the œsophageal fistula and the remaining portion of the œsophagus should not be made until the mucocutaneous junction at the œsophageal fistula has well healed, as only in this way can the tendency toward stenosis which has been observed so frequently be obviated.

*Mobilization of the Jejunal Loop.*—In the construction of the jejunal loop there is some controversy concerning the length of the loop which can be chosen and also the way in which it should be brought into the upper abdomen. Although it is ideal to have a sufficiently long loop of bowel, as first suggested by Roux, to reach from the stomach to the cervical region so that a direct anastomosis of the œsophagus and the jejunum might be accomplished, this procedure usually is not feasible because of the high incidence of gangrene in the distal portion of the jejunal loop (22.2 per cent. in the present series). At no time should a sufficiently long loop of bowel be chosen which will jeopardize the nutrition of the loop. That a long loop of jejunum can at times be successfully mobilized without danger of circulatory failure is shown by the results obtained by Jankovski,<sup>66, 67</sup> Axhausen, Leischner,<sup>68</sup> and Riesenkauff.<sup>69</sup> These authors successfully mobilized jejunal loops 40 centimetres, 60 centimetres, and 75 centimetres in length, respectively. Of sixty instances in which it was stated, in fifty-three the mobilized jejunal loop and its attached mesentery were brought up through the lesser sac, passing first through the transverse mesocolon and then through the gastrocolic omentum. In five instances, the technic as originally suggested by Roux; *viz.*, the bringing of the mobilized segment of gut around the trans-

verse colon was used. That the former is to be preferred to the latter is quite obvious, because of the greatly diminished danger of interference with the blood supply to the loop of bowel by preventing the compression of the mesentery by the transverse colon. Frangenheim believes that the Roux procedure is permissible in children. As emphasized by Axhausen, Hirschmann, Blauel, and Bornhaupt, it is of importance in mobilizing the loop of bowel to secure a loop only long enough to serve as an intervening tube between the stomach and the skin tube. At no time should a sling or dependent loop be allowed to remain within the abdomen in which stagnation of food may occur. Wullstein's suggestion of not completely dividing the jejunal loop, but leaving it attached and allowing the ingested food to enter directly into the jejunum is not practiced at the present time. The technic of the Y-anastomosis; *viz.*, the bringing up of the jejunal loop through the



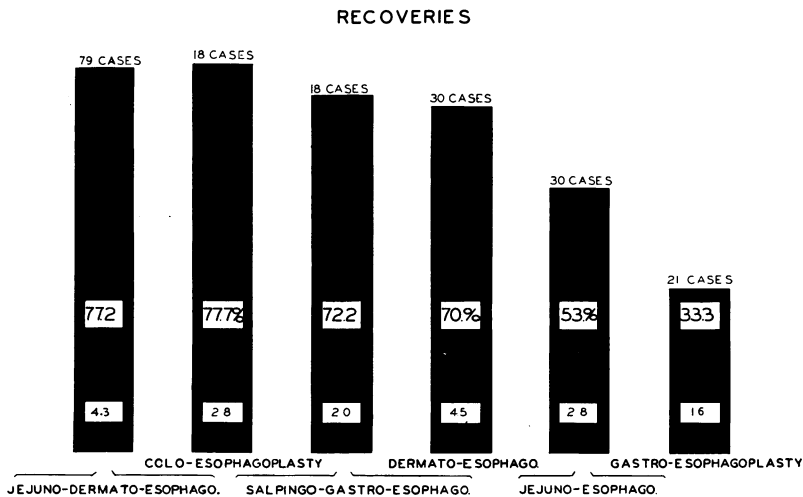
GRAPH II.—Graph showing etiological factors in the production of œsophageal stricture and stenosis.

lesser sac anterior to the stomach and the anastomosis of the oral segment into the distal portion permits a possible two-stage operation and allows the first stage to be shortened considerably. At a subsequent stage the jejunum is divided just below the stomach, the lower end closed blindly, and the upper end anastomosed either end-to-side or side-to-side with the anterior wall of the stomach. The advantage of the two-stage procedure is that each operation is less formidable. The disadvantage, however, is that the second operation; *viz.*, the division of the jejunum and the anastomosis of the upper end with the stomach is made considerably more difficult because of the dense adhesions which form between the first and second operations. Blauel believes that if the second stage is done within a relatively short period of time after the first, adhesions will offer little difficulty. He and Wiedemann<sup>70</sup> maintain that ideally the abdominal operation should be completed in one stage. Blauel does not agree with von Hacker that colon is to be preferred to the small bowel, because the former has less tendency to develop adhesions than the latter. In order to prevent pressure on the mobilized segment of bowel as it passes through the abdominal wall, Axhausen and Denk suggest removing an elliptical portion of the fascia on either side. Whereas the majority of authors are agreed that the jejunal loop can be brought up anterior to the thorax in a tunnel formed under the skin, Slawinski,<sup>71</sup> Grekow,<sup>72</sup> and Wiedemann are of the opinion that this should not be done, but rather that an incision with mobilization of flaps on either side should be accomplished. Slawinski concludes this because the dragging of the jejunum through a skin tunnel resulted in necrosis of the jejunal loop in one of his cases. Syring<sup>73</sup> warns against the placing of a jejunal loop antiperistaltically

## ŒSOPHAGOPLASTY FOR STRICTURES OF ŒSOPHAGUS

as he did in one case. There was continued regurgitation of gastric contents through the loop which subsequently required multiple operations. Excision of the loop was advised. The patient refused and died. He does not agree with Frangenheim that it makes little difference whether the loop is placed isoperistaltically or antiperistaltically, or with Kümmell that a loop of bowel placed anterior to the thorax loses its normal peristaltic activity. He feels also that the reconstruction of the gastric tube from the greater curvature, according to the Beck-Jianu-Halpern method and the placing of the entire stomach anterior to the thorax according to the Fink method is not justified, because of the possibility of reversed peristalsis and the emptying of gastric contents to the outside.

In the 240 cases included in the present series the cause of the obstruction was stated in only 164 (Graph II). In eighty-one of these (49 per cent.)

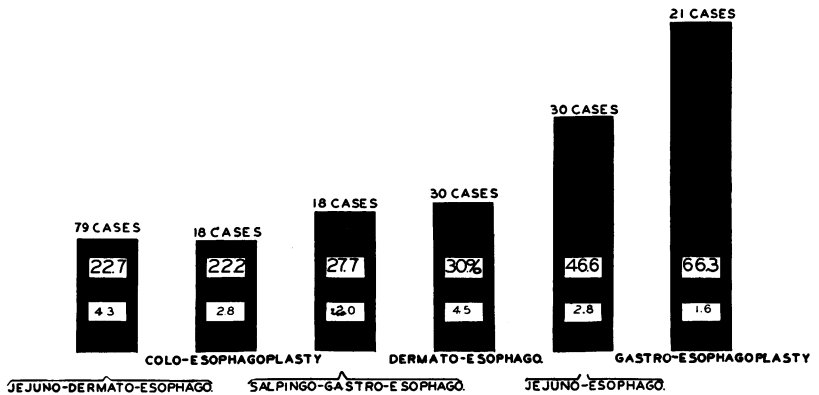


GRAPH III.—Graph representing the recoveries resulting from the various types of operative procedures in performing an anterotheracic œsophagoplasty.

lye was stated as being the caustic substance ingested which was responsible for the obstruction. Other caustic substances and benign strictures were responsible in fifty-one cases, or 31.4 per cent. These fifty-one cases were divided as follows: benign stricture, the cause not stated, twenty-four cases; congenital, two cases; cardiospasm, one case; sulphuric acid, four cases; acetic acid, two cases; ammonia, three cases; hydrochloric acid, ten cases; chloric acid, silver nitrate, potassium permanganate, œsophageal fistula following empyema, and formalin, each, one case. There were thirty-two (19.3 per cent.) cases in which the cause of obstruction was carcinoma. This high percentage of œsophagoplasties performed for a malignant lesion indeed does not speak well for the surgical indications in the particular cases. We agree heartily with Blauel and Bornhaupt that an œsophagoplasty should be done in those cases of carcinoma only when the malignant lesion has been completely extirpated. The operation, an anterotheracic œsophagoplasty with

its numerous procedures, is not justified in a patient with carcinoma who can be made comfortable the remaining days of his life by gastrostomy feeding. We also agree with Lotheissen and others that the œsophagoplasty is not

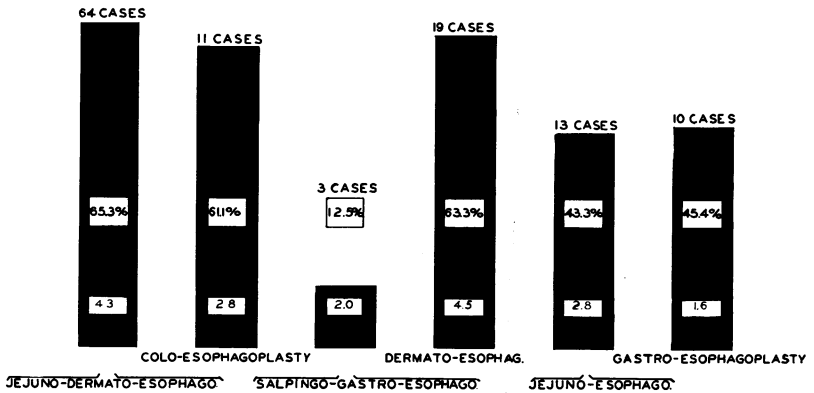
MORTALITY



GRAPH IV.—Graph representing the mortality percentages resulting from the various types of operative procedures done in performing an anterothoracic œsophagoplasty.

justified in cases of benign stricture unless the stricture is impermeable and feel that with few, if any, exceptions the proper treatment of the original cauterization of the œsophagus by early and persistent bouginage will pre-

COMPLETED OPERATIONS



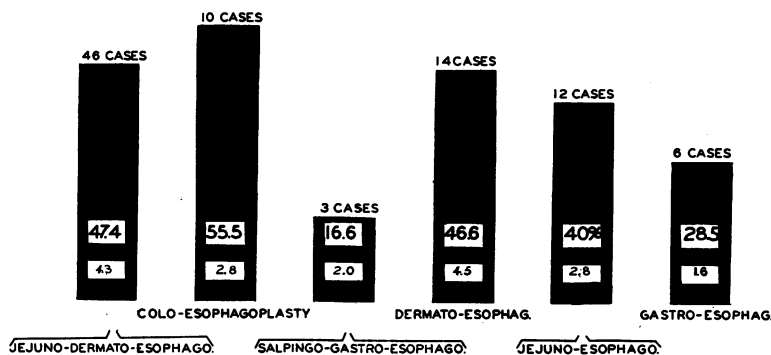
GRAPH V.—Graph representing the completed operations according to the various types performed.

vent an impermeable stricture from developing. Lotheissen recommends a chemical test which consists of letting the patient drink 15 to 20 cubic centimetres of a 2 to 5 per cent. solution of ferric lactate. The gastric contents are then aspirated from the gastrostomy opening and determination of the presence of iron in the stomach is made.

## ŒSOPHAGOPLASTY FOR STRICTURES OF ŒSOPHAGUS

As mentioned above, occasionally an apparently impermeable stricture will open up after putting the œsophagus at rest by the production of a gastrostomy. This is due to the fact that the inflammatory œdema subsides. Sauerbruch<sup>74</sup> reports a case in which he started an œsophagoplasty, but which was not completed because the thoracic œsophagus again became patent. In a

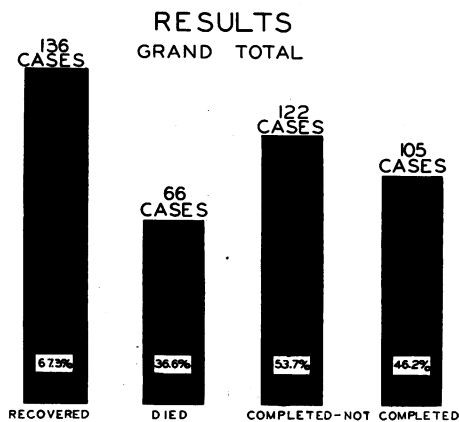
### PERCENT OF GOOD FUNCTION OF THOSE STARTED



GRAPH VI.—Graphic representation of percentage of good function resulting from the various operative procedures performed in those cases started.

case operated upon by von Hacker,<sup>75, 76, 77, 78, 79, 80, 81</sup> the thoracic œsophagus also became patent and the patient subsequently swallowed through both œsophagi. Such, obviously, should never be allowed to occur.

In seventy-one patients with stricture following lye cauterization in which the age was given the oldest patient was fifty-five years, the youngest three, the average 20.9 years. Of sixteen patients with a malignant obstruction in which the age was given, the oldest was sixty-eight, the youngest forty-one, the average 51.5 years. Of the 240 cases there were 152 in which the sex was stated, of which there were seventy-six males and seventy-six females. In eighty-eight the sex was not stated. Of the 242 operations which were done, in fifteen no statement was made whether the operation was completed. In the remaining 227, these data were given. In 122 (53.7 per cent.) the operation was completed, whereas in 105 (46.2 per cent.) the operation was incomplete at the time of the report (Graph VII). Of the 240 cases, in thirty-eight instances



GRAPH VII.—Graphic representation of results following operative procedures for œsophageal strictures.

Of the 240 cases, in thirty-eight instances

no mention was made as to whether the patient recovered. In the remaining 202 cases, 136 (67.3 per cent.) recovered and sixty-six (32.6) died. Of the entire 242 operations performed in the series in only ninety-five was the result stated. In ninety-three of these the result was considered to be good; in two it was considered to be poor.

The mortality rate of 32.6 per cent. in this collected series is high. When one realizes that this is based upon the cases done during the stage of development of œsophagoplastic procedures and that a number of operations are frequently necessary to complete an anterothoracic œsophagoplasty, the figure is not as prohibitive as it would seem at first. The highest mortality rates occurred in those groups in which either the entire stomach or a long loop of small bowel was used in the reconstruction of the œsophagus, being 66.3 per cent. and 46.6 per cent., respectively. The lowest mortality rates occurred in those series in which the colon was used or a combination of small bowel and skin tube, being 22.2 per cent. and 22.7 per cent., respectively. The highest percentage of completed operation was in the jejuno-dermato-œsophagoplastic group. Next in frequency was the dermato-œsophagoplastic group in which only skin was used to construct the new œsophagus, the percentages being 65.3 and 63.3, respectively. The lowest percentage of completed operations was in that group in which a tube was formed from the stomach, it being 8.3 per cent. Of all the cases in which the operation was started and in which the end-result was stated, the highest incidence of good function was obtained in the colo-œsophagoplastic group (55.5 per cent.), followed in frequency by the jejuno-dermato-œsophagoplastic group (47.4 per cent.).

The following case of anterothoracic œsophagoplasty is reported :

CASE REPORT.—Patient, aged four, white female, admitted to Charity Hospital, July 12, 1927. C.C.—Vomiting and inability to retain food. P.I.—About three months ago patient drank some lye water. She was taken immediately to a doctor, who performed a gastric lavage, only twenty minutes elapsing between time of ingestion until she was seen by physician. Patient apparently was making satisfactory progress until seven weeks later, when she developed measles. During the period between the time she ingested the lye and the onset of measles she had lost little weight, during the measles, however, she lost considerable. Shortly after this she began to vomit and was able to retain no food. The vomiting grew progressively worse, but was associated with no fever. There has been a chronic cough since the onset of the measles. P.H.—The general health of the patient had been good. She has had whooping cough and measles. No history of any other serious illness. F.H.—Father living and well. The mother is living and has leprosy. A twin sister in good health. P.E.—Patient is a small, fairly well developed, but poorly nourished white child. Definitely underweight and showing signs of extreme emaciation. Weight, 20 pounds.

On July 1, 1928, otolaryngological consultation disclosed the œsophagus gradually closing, the stricture almost complete, and only a small amount of liquids being retained. General condition fair. Patient unable to swallow string because of lack of coöperation. Aug. 1.—A small bougie passed following which several cups of water were swallowed and retained. The patient responded well to this dilatation, and showed signs of marked improvement, but developed a bronchopneumonia from which she recovered. On November 3, a second dilatation was done, without reaction. Weight, 30 pounds.



## ŒSOPHAGOPLASTY FOR STRICTURES OF ŒSOPHAGUS

Jan. 22, 1929.—Readmitted. Has lost considerable weight. Now 23 pounds, 4 ounces. Examination of chest reveals a chronic bronchitis with a slightly productive cough, temperature 99°. She continued to improve and gain weight and on Nov. 5, a third œsophageal dilatation was done, since which she has been making satisfactory progress, being fed entirely through a gastrostomy tube. Discharged, Nov. 21, 1929. Readmitted Feb. 17, 1930, for an œsophageal dilatation, which was repeated on Sept. 1.

Sept. 6, 1931.—Readmitted. Weight, 37 pounds. Patient unable at this time to drink any fluids whatever, is taking all nourishment through gastrostomy tube. On Sept. 12 an unsuccessful attempt made to pass a sound through the œsophagus. A second attempt to pass a sound with the aid of the endoscope also unsuccessful, as was an attempt at retrograde bouginage, which was again unsuccessful on Nov. 22, and the patient was discharged as being impossible of dilatation. Patient in a debilitated condition, with progressive expectoration. Weight 37 pounds 4 ounces. June 18, 1933.—Readmitted to Charity Hospital, on Surgical Service. Her condition is good, although complexion is

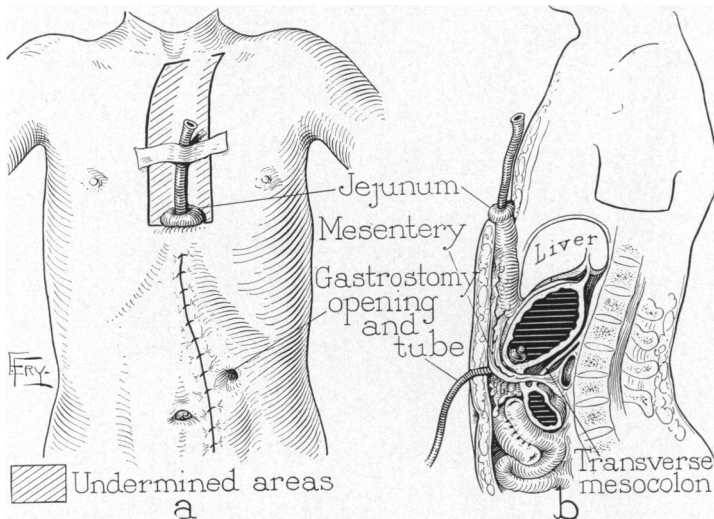


FIG. 5.—Diagrammatic drawing showing the incision used in the formation of the skin tube from the skin of the anterior thorax. As is seen in the figure on the left, the flap on the right side is undermined for a greater distance than on the left. In this way the suture line does not lie directly above. On the right, the production of the jejunal tube, the mesentery of which is brought up through the lesser sac. Jejunal tube is anastomosed with the stomach, and its position beneath the skin of the lower portion of the thorax is demonstrated.

sallow. Has gained steadily in weight, but still unable to take anything through the œsophagus.

*First Stage of Œsophagoplasty Performed.*—June 27, 1933.—Under ether anæsthesia a left rectus incision was made, abdomen explored and jejunum isolated. The jejunal loop 12 inches distal to the ligament of Treitz divided. Both ends of the jejunum closed blindly by purse-string sutures. The mesentery of the jejunum distal to the division divided close to its root for a distance of about 6 centimetres, the vessels being severed only after it was seen that compression did not produce any change in the color of the loop of bowel. An opening was made in the avascular area of the transverse mesocolon and the proximal end of the distal portion of the divided intestine brought through the transverse mesocolon into the lesser sac and through the gastrocolic omentum. The distal end of the proximal loop of divided intestine was then anastomosed to the jejunum by a side-to-side anastomosis, approximately 10 inches distal to the proximally divided end. The jejunum proximal to the jejunostomy was next divided and the distal end turned in as in the

## OCHSNER AND OWENS

previous procedure, and the proximal end anastomosed to the anterior wall of the stomach by an end-to-side anastomosis in the region of the lesser curvature about its midportion. The upper end of the free jejunal loop was brought through the end of the abdominal incision and placed in a subcutaneous tunnel extending for a distance of about 5 centimetres upward. The upper end of the loop emerging through a transverse incision at the upper end of the skin tunnel, was sutured to the skin (Fig. 5b).

July 2.—Sudden rise and persistent septic type of temperature. Patient received glucose and saline infusions and several transfusions of whole blood. On July 6, while

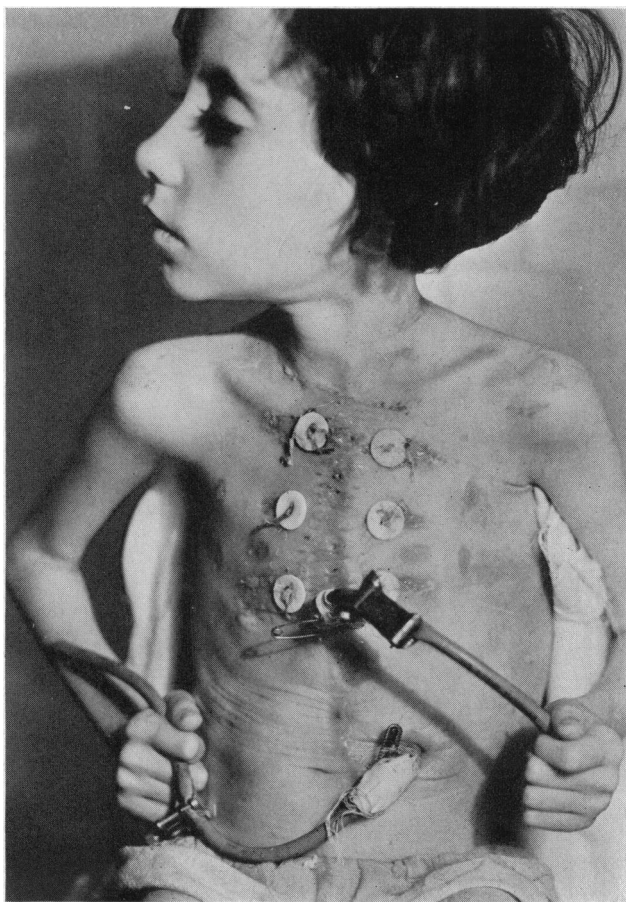


FIG. 6.—Photograph of patient, September 25, 1933, following the second stage oesophagoplasty. The lower tube is a gastrostomy tube. The upper tube is inserted in the jejunum. The buttons used as retention sutures are plainly visible.

attempting to administer milk through a catheter supposed to be inserted into a loop of jejunum, the catheter was forced along the line of cleavage just outside the jejunal loop downward into the peritoneal cavity. About one quart of milk was introduced through this tube and into the peritoneal cavity instead of being poured into the stomach as was intended. Following this the patient went into extreme shock, pulse 160, respiration 26, temperature 98.6°. At 2:00 P.M. the pulse was 140, temperature 99, respiration 22. The pulse remained elevated for the next four days, ranging between 140 and 100, and the temperature between 99 and 102. On July 18, patient shows signs of toxicity, with evi-

## ŒSOPHAGOPLASTY FOR STRICTURES OF ŒSOPHAGUS

dence of an abdominal wall abscess. This was incised and drained. A thin, sour-smelling pus was evacuated. A small cavity was found between the fascia and the abdominal wall, and the same material seen to be coming from the depth of the wound, which, after exploration and dilatation, was found to extend into a large intraperitoneal abscess extending down midway between the symphysis and umbilicus, from which approximately 100 to 150 cubic centimetres of fluid, apparently containing milk, was evacuated. The cavity was temporarily packed with thin gauze.

*Second Stage Œsophagoplasty.*—Sept. 12.—Two parallel incisions about  $2\frac{1}{2}$  inches apart, extending from the jejunal loop up to the left sternoclavicular articulation, were made so that they were somewhat to the left of the mid-line. Skin flaps undermined, the right for a distance of approximately one inch and the left for a distance of only  $\frac{1}{2}$  inch. Transverse incisions were made through the skin at the upper and lower limits of the parallel incision above described (Fig. 5b). The tube

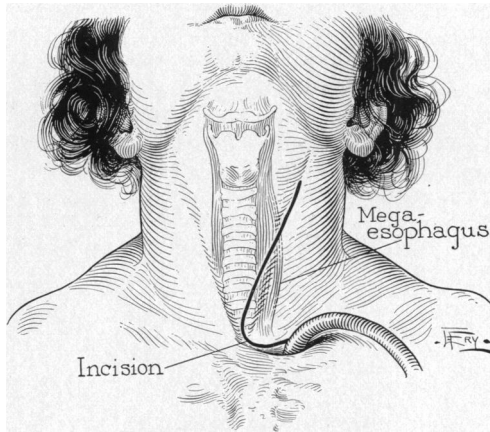


FIG. 7.—Drawing showing the upper end of the completed skin tube at the sternoclavicular junction and the incision used in the third stage œsophagoplasty to expose the œsophagus. The incision is curved at its lower end in order to produce a flap, which is used to cover over the œsophageal cutaneous anastomosis. The dilated œsophagus is shown in the background.

was then constructed by means of interrupted sutures of o catgut, being placed in the dermis but not passing through the epidermis (Fig. 3). A second row of interrupted o catgut was placed in the subcutaneous tissue, thus completing the tube. The tube so constructed was covered by undermining the lateral skin flap from either side and approximating them by means of interrupted tension sutures of silkworm gut, being placed so that they were situated underneath the newly formed skin tube. The tension sutures were drawn through buttons (Fig. 4). After tightening the tension sutures and with the aid of lateral relaxation incisions, it was possible to approximate the skin edges over the tube by means of interrupted paraffinized silk sutures, which were placed without tension. The patient made an uneventful recovery and was up in a wheel chair Sept. 17 (Fig. 6).

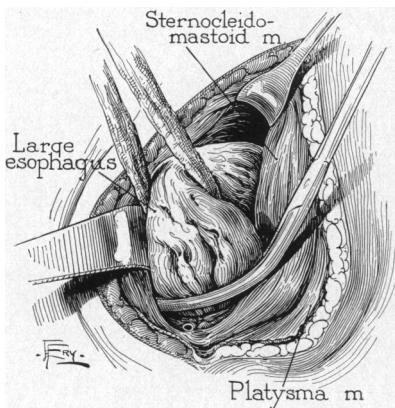


FIG. 8.—Mobilization of the œsophagus. A tape has been placed around the hugely dilated œsophagus after the œsophagus has been carefully separated from the surrounding structures. This mobilization has extended down well into the mediastinum. A right angle clamp is being placed on the œsophagus in its lower portion. Similarly another clamp will be placed above this.

laxed by two lateral incisions running obliquely outward from a point just below the clavicle toward the anterior axillary line. These were about 7 centimetres in length. The skin between the relaxation incisions and the skin tube was thoroughly undermined. Following this procedure it was possible to approximate the edges of the skin which

*Third Stage Œsophagoplasty.*—Nov. 14.—The upper end of the skin tube, which had separated following the last operation was closed. The reformed tube was made by suturing the edges which go into the formation of the lining of the tube with 000 catgut, the sutures being tied inside. The skin previously had been relaxed

went into the formation of the roof of the skin tube with little difficulty. The anterior covering of the skin tube, which was formed by attaching the two skin borders of the skin immediately overlying the inner lining of the skin tube, was sutured with end-on mattress sutures of 0000 silkworm gut. The denuded areas caused by separation of the skin edges at the point of relaxation incision were grafted by Thiersch grafts taken from the right thigh. An impression of these areas was first taken with a stent made of dental compound. The Thiersch grafts were placed over the stent and inserted into the wound where they were held in place by pressure applied to an overlying sea sponge, fluffy gauze, and a bandage. Patient recovered from this procedure very rapidly and with no difficulty.

*Fourth Stage Oesophagoplasty.*—Jan. 1, 1934.—Curved linear incision made beginning in the region of the hyoid bone and following along the anterior border of the

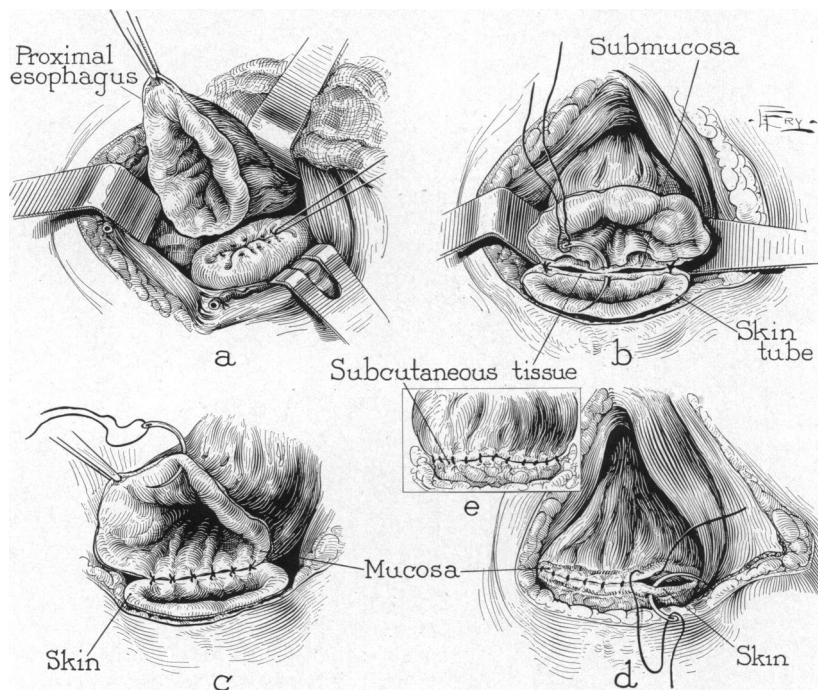


FIG. 9.—Drawing showing the method of treating both ends of the oesophagus. (a) The distal end has been closed by means of a purse-string, and following this is allowed to sink into the mediastinum. The upper end is seen to be markedly dilated. (b) Anastomosis of the upper dilated end to the oesophagus with the skin tube. Because of the disproportion in the two ends, some difficulty was encountered in accomplishing this. By using the interrupted sutures, however, it was accomplished as shown in (c), (d), and (e). As shown in (b) the first line of sutures passed through the submucosa and the subcutaneous tissue, whereas the second line of sutures passed through the epidermis and the mucosa.

sternocleidomastoid muscle, extending obliquely downward and medially to approximately 1 centimetre above the clavicle where the incision was then turned laterally beyond the opening of the previously opened skin tube, being about 1 centimetre above this level (Fig. 7). The anterior jugular vein was ligated; the sternomastoid muscle retracted laterally, thus exposing the deep cervical fascia overlying the carotid sheath. This fascia was incised longitudinally, exposing the carotid sheath which was retracted laterally. The trachea and left recurrent laryngeal nerve were retracted medially, care being taken not to injure the left inferior thyroid artery in order to conserve as much of the blood supply to the oesophagus as possible. The oesophagus was isolated by sharp and blunt dissection and it was found to be enormously dilated just above the point of stricture,

## ŒSOPHAGOPLASTY FOR STRICTURES OF ŒSOPHAGUS

being approximately 4 centimetres in diameter. In separating the œsophagus anteriorly it was found that numerous dense adhesions were present around its entire circumference and in attempting to free some of these an opening was inadvertently made in it. There was an immediate escape of stagnant œsophageal material which contained nuts and food particles. The opening was grasped with forceps and sutured with 00 catgut. The wound quickly aspirated and the head of the patient lowered to an extreme degree in order to effect as much drainage as possible toward the mouth. In freeing more of the dense fibrous adhesions encircling the œsophagus another perforation was made. It seemed impossible to find any line of cleavage whatsoever and in freeing one of the very dense adhesions on the anterior surface of the œsophagus, the trachea was opened in its posterior aspect. This was sutured with interrupted 00 catgut. The œsophagus was mobilized well into the superior mediastinum. An umbilical tape was used to bring the freed mega-œsophagus into the wound (Fig. 8).

About 8 centimetres below the level of the suprasternal notch, within the thorax, two crushing right angle kidney pedicle clamps were applied to the œsophagus, and it was divided between these clamps. Over the lower clamp a continuous suture of No. 1

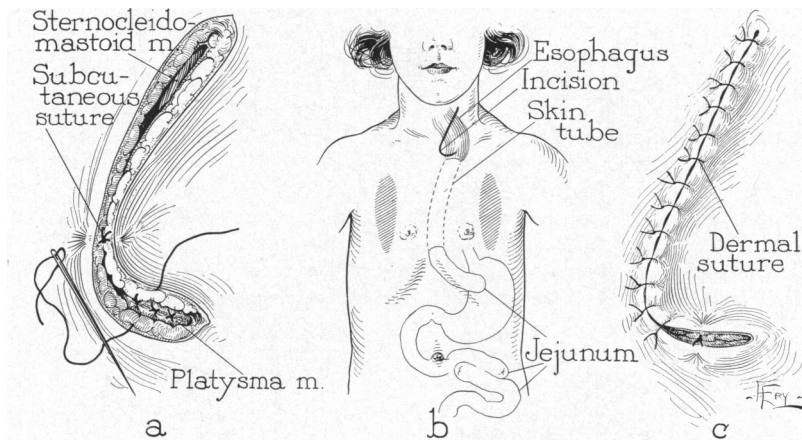


FIG. 10.—Showing the closure of the cervical wound after the œsophageal-cutaneous anastomosis. The flap produced by the incision permits the covering of the anastomosis very satisfactorily. (b) Diagrammatically shows the reconstruction of the new œsophagus, the upper portion of the œsophagus, the mid-portion of skin, and the lower portion of the jejunum.

chromic catgut was placed. The ligated stump inverted by means of a purse-string suture (Fig. 9a). The distal end of the proximal portion of the œsophagus anastomosed to the upper end of the skin tube. The anastomosis was accomplished by placing a row of submucosal and subcutaneous sutures posterior in such manner that the ends of the two tubes were approximated (Fig. 9b). Following this, the mucosa and the skin posteriorly were sutured by interrupted silk in the same manner (Fig. 9c). Anteriorly the mucosa and the skin sutures were applied in such a manner that the knot was tied within the lumen. Over this the submucosal and the subcutaneous tissues were sutured by means of interrupted silk. Because of the great disproportion in size of these two tubes this was accomplished with some difficulty, but apparently satisfactorily. A rubber dam drain was placed in the posterior mediastinum behind the inverted œsophageal stump and brought out through the upper end of the wound. The flap was again replaced in position over the œsophagus and subcutaneous sutures of 00 plain catgut were taken. Following this the skin was sutured with interrupted silk (Fig. 10a and c).

On Jan. 2.—Patient shows some toxicity. Wound red; a serous discharge which was foul-smelling, typical of a spirochetal infection; Vincent's organisms were demonstrated; 0.075 Gm. of neoarsphenamine given intravenously. On Jan. 12, temperature 100. The

secretions very quickly lost the foul-smelling odor which was first noticed and the wound looks better. Wound entirely healed with the exception of a small fistulous opening, and no infection present on Jan. 16. By Mar. 10, patient's progress satisfactory. Had gained in weight up to 51 pounds, and was up and about the ward; she was taking viosterol and liver daily.

*Fifth Stage Œsophagoplasty.*—Apr. 17.—Excision of scar tissue from the skin over the junction of the œsophagus and skin tube down to the connection of the œsophagus with the skin tube. A circular incision was made completely around the œsophagus above, cutting through the dense scar tissue in its entirety. This incision freed the œsophagus from its scar tissue attachment, thus mobilizing it to a fair degree. The same procedure was used in mobilizing the proximal end of the skin tube below. Following this the œsophagus and the skin tube could be brought into approximation with little difficulty and with not too much tension. A layer of interrupted 00 chromic sutures was taken, passing through the submucosa of the œsophagus and through the subcutaneous layer of the skin tube in such manner that the œsophagus and skin tube were approximated without causing too much tension on the suture line.

The mucosa of the œsophagus and the epidermis of the skin tube were sutured. These sutures were made with considerable difficulty because the circumference of the œsophagus was considerably larger than that of the skin tube and consequently there was a marked redundancy of the œsophagus. This condition made the correct approximation of the œsophagus with the epidermis of the skin tube quite tedious. There was considerable dead space lying beneath the œsophagus after completion of the anastomosis, so that two small pieces of rubber dam were placed one on either side of the œsophagus and brought out through the angle of the wound. The skin wound was closed with interrupted sutures of 0000 silkworm gut. Patient reacted from this operative procedure quite satisfactorily. 0.075 Gm. of neosalvarsan given intravenously.

April 18.—Wound red and œdematous. Hot, moist applications started. Wound treated with application of 5 per cent. nearsphenamine in glycerine and also applications of gentian violet. Patient permitted to swallow three times daily one ounce of 1:10 Fowler's solution. This latter procedure was done with impunity as the solution merely rinsed the œsophagus and skin tube, emptying itself outside the body into the dressings at the lower end of the skin tube. The wound responded nicely and there was never at any time the suggestion of the foul-smelling odor typical of spirochetal infection which had been present following the original anastomosis of the œsophagus with the skin tube. On May 10 a catheter was inserted up through the skin tube past the junction of the œsophagus and the skin tube. This catheter conducted all secretions from the mouth, and no leakage was observed at the small fistulous opening in the neck. There was, however, almost a constant flow of saliva coming out the distal end of the catheter. Each time the patient swallowed a small amount of saliva was forced out through the lower end of the catheter. Patient made satisfactory progress and continued to improve and gain weight.

*Sixth Stage Œsophagoplasty.*—May 24.—A plastic closure of the space between the upper jejunal loop and the skin tube was accomplished by means of a skin pedicle flap. The skin flap was sutured to the lower anterior  $\frac{3}{4}$  of the circumference of the skin tube. This particular type of flap was chosen in order to avoid having a suture line at the inferior border of the flap which would, if present, be situated in a particularly vulnerable position, as any fluid passing from the œsophagus above would come in contact with this suture line with more force than if it were situated in the upper arch of the closure. An incision was made around the anterior  $\frac{3}{4}$  of the circumference of the skin tube and a small cuff of this portion of the skin tube raised and turned downward in preparing it for its attachment with the flap below. The junction of the edge of the flap beneath was sutured to this cuff of the anterior skin tube. This formed the anterior portion of the wall of the newly formed œsophagus at the point of the junction between the skin tube and the jejunal loop. The closure was made by a continuous suture of 00 chromic gut in

## ŒSOPHAGOPLASTY FOR STRICTURES OF ŒSOPHAGUS

such a manner that the edges were slightly inverted and approximated on the inside. This was reinforced by a second row of interrupted 00 chromic catgut sutures. The closure of the skin over the roof of the anastomosis thus formed was effected by undermining the skin on either side of the defect, and this was aided by two relaxing incisions, 10 centimetres in length, which were placed about the level of the seventh rib in the anterior axillary line. Following this the skin was sufficiently freed and relaxed to approximate the newly formed roof of the œsophagus. The closure of the skin edges was done by the aid of tension sutures of silkworm gut placed through buttons. After the tension sutures of silkworm gut were placed, other interrupted sutures of fine dermal were taken. At the completion of the operation patient was in shock, but recovered following infusions and a transfusion. On the following day condition excellent. May 26, patient's condition is quite good. Temperature, pulse, and respiration normal. The wound shows some increased redness. May 29, 1934, patient's general condition is excellent. The wound still shows some redness. About one-half dram of pus expressed from the upper border of the wound. No definite fistula has apparently formed, although this may be a forerunner of one.

### DISCUSSION AND CONCLUSIONS

Based on our own personal experience in the reported case and the review of the literature, we feel that the procedure of anterotheracic œsophagoplasty should be used only in cases of absolutely impermeable benign stricture of the œsophagus or in cases of carcinoma in which the tumor has been extirpated. We also feel that if cases of cauterization of the œsophagus are adequately treated from the beginning few, if any, cases will develop an impermeable stricture. It is conceivable, however, that a case with a massive necrosis of the œsophagus may develop a stenosis which cannot be satisfactorily dilated. These are indeed exceptional. In a review of the cases which have been operated upon it is evident that the best results have been obtained in two groups of cases; *viz.*, those in which the operation has been accomplished by using a segment of colon and those in which a newly formed œsophagus has been constructed out of a loop of jejunum and a skin tube. Whereas the results obtained in making a colo-œsophagoplasty are equally as good as those obtained by a jejuno-dermato-œsophagoplasty it seems to us that, in spite of the many more operations required, the latter procedure is to be preferred. As shown by many of the reports in the literature even though the colon can be used for the reconstruction of the œsophagus, stasis within the newly formed œsophagus is apt to occur with the formation of a ruminating stomach. It should be emphasized that in mobilizing a jejunal loop the attempt should never be made to secure a loop of such length that the blood supply of the bowel will be in jeopardy. Undoubtedly, this has been responsible for the high incidence of failure and fatalities in the jejuno-œsophagoplasties in which an attempt was made to form the œsophagus entirely from the jejunum. Based on our study of the literature and on the difficulties encountered in our own case, we feel that the first stage of the jejuno-dermato-œsophagoplasty should consist of the mobilization of the jejunal segment. This should be brought up through the lesser sac, completely mobilized, and the distal end anastomosed to the stomach, care being taken

not to have a dependent loop. The proximal end should be brought up through a skin tunnel anterior to the thorax. The upper end of the jejunum which is brought out through a small transverse incision is sutured to the skin edges without opening up the bowel. The second stage should consist of the formation of the skin tube and the immediate completion of the junction between the skin tube and the jejunum in a way depicted in Fig. 11. This is accomplished by extending the lateral incision for the formation of the skin tube down and around the jejunal opening. In this way a flap is produced which can be mobilized upward to be anastomosed to the skin tube,

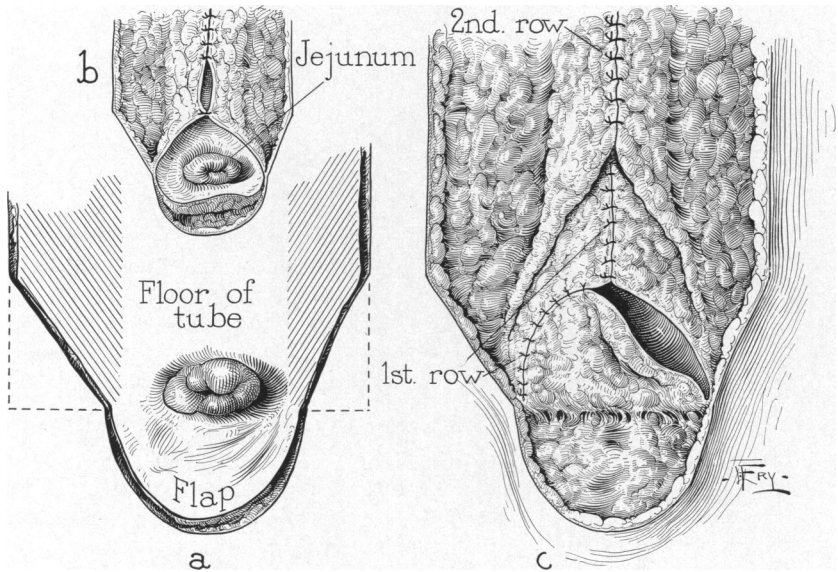


FIG. 11.—(a) Represents the skin incision used for the formation of a skin tube which includes a skin flap below the anastomosis of the jejunal loop with the skin. (b) Represents the manner in which the skin tube is formed by inverting the edges of the lateral skin flaps and approximating their borders with intradermal skin sutures. This also demonstrates the manner in which the lower flap is folded upward and approximated with the lower borders of the lateral skin flaps. When the above procedure is completed, one will see that a skin tube is formed, which completely encloses the anastomosis of the jejunum with the skin. (c) Represents the manner in which the lateral and the lower skin flaps are approximated in the formation of the skin tube. All sutures are intradermal.

covering over the opening of the jejunum. The advantage of this procedure is that the suture line is in such a position that there is relatively little tension on it, and also because the anastomosis with the jejunum is surrounded by a floor of normal skin. Following this, the newly formed skin tube, the anastomotic site, and the defects produced by the mobilization of flaps are covered by mobilizing skin flaps on either side. Relaxing incisions are necessary. Sufficient time is allowed to elapse between completion of this stage and the third stage of the œsophagoplasty for the wound to heal completely, as in this way there will be less danger of infection from the contaminated mouth secretions. As a third stage the cervical œsophagus is mobilized after making a curved incision as described in the drawings, the incision passing along the anterior border of the sternocleidomastoid to a point just above the



## ŒSOPHAGOPLASTY FOR STRICTURES OF ŒSOPHAGUS

clavicle and then coursing laterally. The œsophagus is mobilized well into the mediastinum. The upper end of the previously formed skin tube is freshened by a transverse incision, and the skin forming the lining of the tube is separated from the skin covering it. The œsophagus is mobilized well down into the mediastinum, doubly clamped by means of right-angled clamps and divided transversely. The lower end is closed blindly by means of inverting sutures. The upper end is brought up into the wound and the distal segment of the upper end is invaginated into the upper end of the

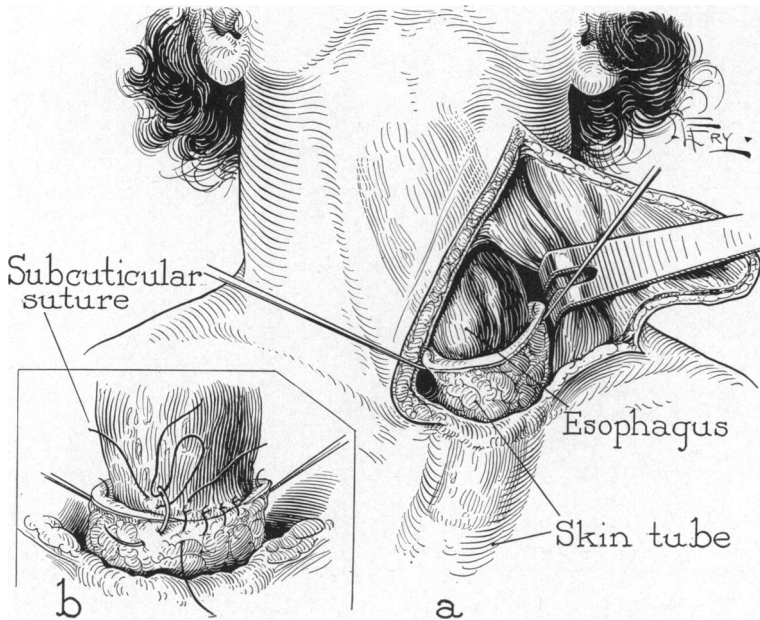


FIG. 12.—Represents the incision used for the formation of a triangular skin flap over the lateral surface of the neck through which the œsophagotomy is performed. The upper end of the previously formed skin tube is pared by a transverse incision and the skin forming the lining of the tube is separated from the skin covering the tube. The œsophagus is then sectioned at a point sufficiently low to permit one to insert the distal end of the oral segment well down into the skin tube. Salivary drainage through this portion of the œsophagus will then go directly into the stomach without contaminating the site of anastomosis between the œsophagus and the upper end of the skin tube. (b) Represents the manner in which the approximation sutures are taken through the outer portion of the œsophagus and through the subcutaneous portion of the skin tube, care being taken not to penetrate either the œsophageal wall or the epidermis of the skin tube. Following this procedure the triangular flap is then brought over the point of anastomosis of the œsophagus and the skin tube, and the wound closed.

skin tube (Fig. 12). The suture of the œsophagus with the skin tube is accomplished by interrupted sutures passing through the subcutaneous tissue of the skin tube and barely catching the wall of the œsophagus, care being taken not to penetrate into the lumen of the œsophagus or to pass through the epidermis of the skin tube. In this way salivary secretions are discharged into the lumen of the skin tube without any danger of their coming in contact with the suture line. The possibility of a fistula is thus greatly minimized. The skin flap is then replaced over the suture line, after placing a drain into the mediastinum.

Because of the possibility of mouth contamination, it is well, if the patient shows any evidence of infection, to look for the possibility of Vincent's infection; and even if such is not found, it seems advisable to give nearsphenamine as a prophylactic procedure. It is obvious that a patient with an impermeable stricture with accumulation of saliva in a blind pouch might have spilling over into the trachea from time to time and that this may be a predisposing factor in the development of bronchiectasis. Undoubtedly, the spirocheal infection which we had in the cervical wound of our patient was the result of a bronchiectasis, and we are of the opinion that this complication occurs more frequently than has been recognized. In such infections we have found it of distinct benefit to combine the intravenous administration of nearsphenamine with the topical application of arsphenamine and gentian violet.

## BIBLIOGRAPHY

- <sup>1</sup> Bircher, Eugen: Ein Beitrag zur plastischen Bildung eines neuen Oesophagus. *Zentralbl. f. Chir.*, vol. 34, p. 1479, 1907.
- <sup>2</sup> Bircher, Eugen: Zur Oesophaguschirurgie. *Cong. Soc. Internat. de Chir., Rap.*, vol. 1, p. 535, 1932.
- <sup>3</sup> Wullstein, L.: Ueber antethorakale Oesophago-jejunostomie und Operationen nach gleichen Prinzip. *Deutsche med. Wchnschr.*, vol. 30, p. 734, 1904.
- <sup>4</sup> Roux: L'oesophago-jejuno-gastrostomie, nouvelle operation pour retrecissement infranchissable de l'oesophage. *Semaine med.*, vol. 27, p. 37, 1907.
- <sup>5</sup> Hirsch, M.: Plastischer Ersatz des Oesophagus aus dem Magen. *Zentralbl. f. Chir.*, vol. 38, p. 1561, 1911.
- <sup>6</sup> Jianu, A.: Gastrostomie u. Oesophagoplastik. *Deutsch. Ztschr. f. Chir.*, vol. 118, p. 383, 1912.
- <sup>7</sup> Beck, Carl, and Carrell, A.: Demonstration of Specimens Illustrating a Method of Formation of a Prethoracic Esophagus. *Ill. Med. Jour.*, vol. 7, p. 463, 1905.
- <sup>8</sup> Halpern, J. O.: Zur Frage von der Speiserohrenplastik. *Zentralbl. f. Chir.*, vol. 40, p. 1834, 1913.
- <sup>9</sup> Fink, F.: Ueber plastischen Ersatz der Speiserohre. *Zentralbl. f. Chir.*, vol. 40, p. 545, 1913.
- <sup>10</sup> Kirschner: Ein neues Verfalwen der Oesophagoplastik. *Arch. f. klin. Chir.*, vol. 114, p. 606, 1920.
- <sup>11</sup> Kelling, G.: Oesophagoplastik mit Hilfe des Querkolon. *Zentralbl. f. Chir.*, vol. 38, p. 1209, 1911.
- <sup>12</sup> Roith, O.: Die einzeitige antethorakale Oesophagoplastik aus dem Dickdarm. *Deutsche Ztschr.*, vol. 183, p. 419, 1923-1924.
- <sup>13</sup> Esser, J. F. S.: Sogenannte totale Oesophagusplastik aus Hautlappen nach Thiersch ohne Verwendung von Darmschlinge. *Deutsche Ztschr. f. Chir.*, vol. 142, p. 403, 1917.
- <sup>14</sup> Herzen, P.: Eine Modifikation der Rous'schen Oesophago-jejunogastrostomie. *Zentralbl. f. Chir.*, vol. 35, p. 219, 1908.
- <sup>15</sup> Wullstein, L.: Zur plastischen Bildung eines neuen Oesophagus. *Zentralbl. f. Chir.*, vol. 35, p. 222, 1908.
- <sup>16</sup> Lexer: Oesophagoplastik. *Deutsche med. Wchnschr.*, vol. 34, p. 574, 1908.
- <sup>17</sup> Lexer: Vollstandiger Ersatz der Speiserohre. *Munch. med. Wchnschr.*, vol. 58, p. 1548, 1911.
- <sup>18</sup> Lexer: Vollkommener Ersatz der Speiserohre. *Verhandl. d. deutsch. Ges. f. Chir.*, vol. 40, p. 119, 1911.

## ŒSOPHAGOPLASTY FOR STRICTURES OF ŒSOPHAGUS

- <sup>19</sup> Lexer : Quoted by Frangenheim : *Ergeb. der Chir. u. Orth.*, vol. 5, p. 406, 1913.
- <sup>20</sup> Rehn, E. : *Oesophaguschirurgie*. Jena, Gustav Fischer, 1914.
- <sup>21</sup> Hübler, O. : Die Verätzungen der Speiseröhre durch K O H in Kindesalter. *Wien. med. Wchschr.*, vol. 76, p. 255, 1926.
- <sup>22</sup> Schreiber, J. : Zur experimentellen Pathologie und chirurgie des Schluckapparates (Oesophagoplastik). *Mitt. a. d. Grenzgeb. d. Med. u. Chir.*, vol. 24, p. 356, 1911-12.
- <sup>23</sup> Frangenheim, P. : Zur Frage der Oesophagusplastik. *Arch. f. Klin. Chir.*, vol. 95, p. 684, 1911.
- <sup>24</sup> Frangenheim, P. : Oesophagoplastik. *Ergeb. der Chir. und Ortho.*, vol. 5, p. 406, 1913.
- <sup>25</sup> Frangenheim, P. : Oesophagoplastik. *Zentralbl. f. Chir.*, vol. 48, p. 1193, 1921.
- <sup>26</sup> Frangenheim, P. : Oesophagusplastik, Methodik und Erfolge. *Munch. med. Wchschr.*, vol. 69, p. 303, 1922.
- <sup>27</sup> Zaaïjer, J. H. : Erfolgreiche intrathorakale Oesophagus Operation. *Zentralbl. f. Chir.*, vol. 40, p. 1883, 1913.
- <sup>28</sup> Zaaïjer, J. H. : Surgery of the Esophagus. *Lancet*, vol. 1, p. 909, 1929.
- <sup>29</sup> Zaaïjer, J. H. : Surgery of the Esophagus. *Nineteenth Cong. Soc. Internat. Chir.*, vol. 1, p. 485, 1932.
- <sup>30</sup> Sampson, H. H. : Reconstructive Esophagoplasty. *Brit. Jour. Surg.*, vol. 20, p. 447, 1932-33.
- <sup>31</sup> Blauel, K. : Zur totalen Oesophagusplastik. *Verhandl. d. deutsch. Gesellsch. f. Chir.*, vol. 43, p. 1, 1914.
- <sup>32</sup> Blauel, K. : Zur totalen Oesophagoplastik. *Beitr. z. klin. Chir.*, vol. 104, p. 46, 1916-17.
- <sup>33</sup> Blauel, K. : Zur antethorakalen Oesophagoplastik mittels Haut-Darmschlauchbildung. *Zentralbl. f. Chir.*, vol. 46, p. 326, 1919.
- <sup>34</sup> Ritter, C. : Zum Ersatz der Speiseröhre durch Dunndarmtransplantation. *Deutsche Ztschr. f. Chir.*, vol. 112, p. 559, 1919.
- <sup>35</sup> Ritter, C. : Discussion of Lexer's Case. *Verhandlung. d. Deutsche Gesellsch. f. Chir.*, vol. 40, p. 122, 1911.
- <sup>36</sup> Ritter : Discussion of Petersen's Case. *Zentralbl. f. Chir.*, vol. 48, p. 521, 1921.
- <sup>37</sup> Hübler, O. : Antethorakale Oesophagusplastik. *Zentralbl. f. Chir.*, vol. 55, p. 2638, 1928.
- <sup>38</sup> Grigorjev, A. : Bildung einer kunstlichen Speiseröhre nach Halpern. *Vracebnoe delo Ja.*, vol. 9, p. 400, 1926. *Ab. Zentralorgan f. Chir.*, vol. 37, p. 104, 1927.
- <sup>39</sup> Lotheissen, G. : Zur Behandlung der Speiseröhrenstrikturen. *Zentralbl. f. Chir.*, vol. 40, p. 1969, 1913.
- <sup>40</sup> Lotheissen, G. : Ueber plastischen Ersatz der Speiseröhre, insbesondere aus dem Magen. *Beitrage, z. klin. Chir.*, vol. 126, p. 490, 1922.
- <sup>41</sup> Lotheissen, G. : Discussion of Albrecht's Case. *Zentralbl. f. Chir.*, vol. 53, p. 1693, 1926.
- <sup>42</sup> Kümmell, H. : Zur Operation des Kardiospasmus und des Oesophaguscarcinoms. *Arch. f. klin. Chir.*, vol. 117, p. 193, 1921.
- <sup>43</sup> Henschen, C. : Zur Operationsmethodik der antethorakalen Oesophagoplastik. *Schweiz. med. Wchschr.*, vol. 54, p. 66, 1924.
- <sup>44</sup> Braizew, W. R. : Erfahrungen mit der antethorakalen Dermato-Oesophagoplastik. *Arch. f. klin. Chir.*, vol. 154, p. 320, 1929.
- <sup>45</sup> Stieda, A. : Zur Frage der Oesophagusplastik. *Arch. f. klin. Chir.*, vol. 102, p. 904, 1913.
- <sup>46</sup> Stieda, A. : Discussion of Brandt's Paper. *Zentralbl. f. Chir.*, vol. 56, p. 2990, 1929.
- <sup>47</sup> Frome, A. : Ueber totale Oesophagoplastik. *Beitr. z. klin. Chir.*, vol. 115, p. 222, 1919.
- <sup>48</sup> Madlener, M. : Ueber den Ersatz der Speiseröhre durch antethorakale Schlauchbildung. *Deutsche Ztschr. f. Chir.*, vol. 155, p. 410, 1920.
- <sup>49</sup> Madlener, M. : Ueber totale Oesophagusplastik. *Beitr. z. klin. Chir.*, vol. 122, p. 299, 1921.

- <sup>60</sup> Nicolaysen, J.: Ein Fall von gelungener Oesophagusplastik. Zentralbl. f. Chir., vol. 46, p. 922, 1919.
- <sup>61</sup> Nicolaysen, J.: Antethorakale Oesophagusplastik. Norsk. magaz. f. laegevidenskaben, vol. 85, p. 905, 1924.
- <sup>62</sup> Nicolaysen, J.: Extrathoracic Esophagoplasty. Acta chir. Scandinav., vol. 58, p. 421, 1925.
- <sup>63</sup> Denk, W.: Ueber den Ersatz der Speiserohre durch antethorakale Plastik. Wein. med. Wchnschr., vol. 76, p. 582, 1926.
- <sup>64</sup> Heyrovsky, H.: Plastische Ersatz des Brustteiles der Speiserohre. Wien. klin. Wchnschr., vol. 27, p. 89, 1914.
- <sup>65</sup> Heyrovsky, H.: Discussion of Albrecht's Case. Treie Vereinigung der Chir. Wien., January 21, 1926; Zentralbl. f. Chir., vol. 53, p. 1695, 1926.
- <sup>66</sup> Axhausen, G.: Zur totalen Oesophagoplastik. Berl. klin. Wchnschr., vol. 53, p. 54, 1916.
- <sup>67</sup> Axhausen, G.: Die Technik der antethoracalen Totalplastik der Speiserohre. Beitr. z. klin. chir., vol. 120, p. 201, 1920.
- <sup>68</sup> Axhausen, G.: Technic of Esophagoplasty. Arch. f. klin. Chir., vol. 139, p. 645, 1926.
- <sup>69</sup> Exner, A.: Ein Fall von Oesophagoplastik. Wien. klin. Wchnschr., vol. 27, p. 775, 1914.
- <sup>70</sup> Ranzi, E.: Ueber totale Oesophagoplastik. Wien. klin. Wchnschr., vol. 32, p. 247, 1919.
- <sup>71</sup> Marwedel, A.: Oesophagusoperationen. Zentralbl. f. Chir., vol. 40, p. 1884, 1913.
- <sup>72</sup> Marwedel, A.: Discussion of Frangenheim's Case. Zentralbl. f. Chir., vol. 48, p. 1194, 1921.
- <sup>73</sup> Hirschmann, C.: Die Bedeutung und Technik des antethorakalen Speiserohrenersatzes bei den impermeablen Strikturen. Therap. d. Gegenw., vol. 60, p. 368, 1919.
- <sup>74</sup> Hirschmann, C.: Zu dem Aufsatz v. Hacker's in Nr. 1 des Zentralbl. f. Chir., 1919; Zur antethorakalen Oesophagoplastik mittels Haut-Darmschlauchbildung. Zentralbl. f. Chir., vol. 46, p. 264, 1919.
- <sup>75</sup> Hirschmann, C.: Komplikationen bei der totalen Oesophagoplastik. Arch. f. klin. Chir., vol. 122, p. 553, 1922.
- <sup>76</sup> Jankovski, J.: Ueber totale Oesophagusplastik. Eesti arst., vol. 1, p. 246, 1922.
- <sup>77</sup> Jankovski, J.: L'oesophagoplastie totale; ses resultats fonctionnels. J. de Chir., vol. 25, p. 633, 1925.
- <sup>78</sup> Leischner, H.: Ueber antethorakale Oesophagoplastik. Deutsche Ztschr., f. Chir., vol. 225, p. 77, 1930.
- <sup>79</sup> Riesenkampf, O.: Ein Fall von totaler Oesophagoplastik. Deutsche Ztschr. f. Chir., vol. 153, p. 116, 1925.
- <sup>80</sup> Wiedemann, H.: Ein Beitrag zur Frage der antethorakalen Oesophagoplastik nach Roux-Herzen-Lexer. Arch. f. klin. chir., vol. 150, p. 563, 1928.
- <sup>81</sup> Slawinski: Ein Versuch von Plastik der Speiserohre aus dem Darm nach Herzen. Przegl. chir. i. ginek., vol. 4, p. 165, 1911; Ab. Jahresber. U. d. Fortschr. a. d. Geb. d. chir., vol. 27, p. 280, 1911.
- <sup>82</sup> Grekow, J. J.: Zur Behandlung der Oesophagusstrikturen, insbesondere der narbigen. Westnik chir. i. pograntschnych oblastej, vol. 1, p. 109, 1922.
- <sup>83</sup> Syring: Klinisches und Experimentelles zur Oesophagoplastik. Deutsche Ztschr. f. Chir., vol. 128, p. 260, 1914.
- <sup>84</sup> Sauerbruch: Discussion of Madlener's Case. Munch. med. Wchnschr., vol. 67, p. 824, 1920.
- <sup>85</sup> Hacker, V.: Ueber Resektion und Plastik am Halsabschnitt der Speiserohre, insbesondere beim Carcinom. Arch. f. klin. chir., vol. 87, p. 257, 1908.
- <sup>86</sup> Hacker, V.: Discussion of Lexer's Case. Verhandl. d. Deutsch. Gesellsch. f. chir., vol. 40, p. 120, 1911.
- <sup>87</sup> Hacker, V.: Ueber Oesophagoplastik im allgemeinen und über den Ersatz der Speiserohre durch antethorakale Haut-Dickdarmschlauchbildung im besonderen. Arch. f. klin. chir., vol. 105, p. 973, 1914.

## ŒSOPHAGOPLASTY FOR STRICTURES OF ŒSOPHAGUS

- <sup>78</sup> Hacker, V.: Zur antethorakalen Oesophagusplastik mittels Haut-Darmschlauchbildung. Zentralbl. f. chir., vol. 46, p. 1, 1919.
- <sup>79</sup> Hacker, V.: Zur antethorakalen Oesophagusplastik mit Verwendung des Dickdarms. Zentralbl. f. chir., vol. 53, p. 29, 1926.
- <sup>80</sup> Hacker, C., and Lotheissen, G.: Antethorakale Oesophagoplastik. Neue Deutsche chir., vol. 34, p. 192, 1926.
- <sup>81</sup> Hacker, V., and Lotheissen, G.: Chirurgie der Speiseröhre. Handb. d. prakt. chir., vol. 2, p. 454, 1924.

DISCUSSION.—DR. CARL EGGERS wished to report briefly on a patient who was recently operated upon, on account of gradually developing symptoms of œsophageal obstruction. He had been kept under observation for some time, and in spite of everything we did and notwithstanding a gastrostomy which was performed to put the œsophagus at rest and allow the lesion a chance to heal, the obstruction became total.

Several biopsies failed to give positive evidence of carcinoma, but the reports of the röntgenologist and endoscopist were in favor of carcinoma and it was decided to operate. We resected the œsophagus according to the method described by Doctor Torek. When the specimen was examined we found an ulcer, two and one-half inches in length, and involving almost the entire circumference of the œsophagus. On microscopical examination it was reported to be a chronic ulcer.

We were naturally somewhat upset by this finding as we had anticipated an early carcinoma, since it has been our experience that a patient who presents gradually developing obstruction as the principal symptom eventually has usually been proven to have a carcinoma. The important point is that the patient recovered. He was recently presented before the New York Surgical Society and will be reported in detail in its transactions. The patient has now a rubber œsophagus connecting the upper œsophagus stump and the gastrostomy. It permits him to masticate and swallow food normally. The muscles of deglutition are sufficiently powerful to send all fluid foods down into the stomach without difficulty. With solids there is at times a little stagnation, even though an extra quantity of fluid is taken to wash them down. To overcome this one of our assistants has interposed a rubber bulb into the rubber œsophagus which permits slight pressure to be made and facilitates the passage of food. The patient is now able to eat almost anything.

The question arises whether we shall be satisfied with present conditions or whether an attempt at plastic reconstruction of the missing portion of œsophagus shall be made. The patient is somewhat over forty years of age. He has an œsophagus stump buried in a subcutaneous channel on the upper left chest wall. He likewise has a Janeway gastrostomy. Both tubes are lined with mucous membrane and it has seemed to us that the formation of a subcutaneous skin tube to connect the œsophagus with the gastrostomy, similar to the operation described by Doctor Ochsner, might be attempted in this case after he has regained his normal weight.