

## FIBROUS OSTEOMA OF THE JAWS

DALLAS B. PHEMISTER, M.D. AND KEITH S. GRIMSON, M.D.

CHICAGO, ILL.

FROM THE DEPARTMENT OF SURGERY OF THE UNIVERSITY OF CHICAGO, CHICAGO, ILL.

TUMORS of the jaws have to be considered apart from tumors of bone in general. In the first place, many of them are of dental origin which precludes their occurrence in other bones. In the second place, the jaws belong to the group of bones preformed in membrane which differ considerably in growth, repair, and tumor formation from the bones preformed in cartilage.

*Embryologic Considerations.*—The maxilla and mandible as well as other bones of the face and cranial vault are derivatives of the scaly armor, dermal bone, or exoskeleton which appears first in the early fishes in the scale of evolution.<sup>1</sup> In higher forms this sinks beneath the skin, articulates with the endoskeleton or cartilage preformed bone and forms in the human the bones that ossify in membrane. Even the mandibular articulation is not related to the earlier cartilaginous gill bars but is rather a secondarily formed diarthrosis between two of these membrane bones.

The maxilla ossifies in membrane from three centers on each side, the maxilla proper, the premaxilla, and the prevomer. During its ossification a cartilaginous mass develops in the malar process which, according to Fawcett,<sup>2</sup> probably is either an accessory cartilage or the anterior end of the palatopterygo-quadrato cartilage. Membranous ossification of the maxilla extends from these three fused centers laterally to include this cartilage, and medially to incorporate part of the lateral wall of the cartilaginous nasal capsule. Thus, while cartilage is present in the field in the embryologic stages, none of the bone of the maxilla appears to be laid down by ossification of it.

The mandible ossifies from one center on either side. This center represents the dentale, a dermal bone present in lower vertebrates. Intramembranous ossification spreads from it to form the body and ramus of the mandible. There are two types of cartilage which develop in the embryonic mandible and become incorporated in the spreading membrane bone. The first is a remnant of Meckel's cartilage. This is an important structure in lower vertebrates. In the newborn infant, however, it is represented only by a small connective tissue cord, the sphenomandibular ligament, and by a scanty cartilaginous remnant extending along the dental canal to a position just back of and below the incisor teeth. The second type of cartilage to be incorporated into the mandible is the so called accessory cartilage that develops at the articulation, along the posterior edge of the ramus and the anterior edge of the coronoid process, and at the symphysis. Sections through these cartilaginous areas in the newborn show signs of growth by a somewhat atypical enchondral ossifi-

---

Submitted for publication September 8, 1936.

cation. Benign tumors that contain cartilage and ossify through cartilage may arise in the jaws. Five such, four benign and one malignant, have been studied by us. They probably originate in connection with remains of these embryonic cartilages, since the relative amount of cartilage present is great.

Repair of fractures and of defects in the mandible and maxilla is by the formation of callus which is fibrous in its first stage and which ossifies usually by direct metaplasia without the appearance of cartilage. However, experiments by Schaffer,<sup>3</sup> Greve<sup>4</sup> and others to be published by one of us (K. S. G.) demonstrate that in the later stages of ossification of the callus and especially when fracture fragments are separated, hyaline cartilage in small amounts may appear and be replaced by new bone by enchondral ossification similar to the callus of a bone preformed in cartilage.

That the great majority of benign ossifying tumors of the jaws are free from cartilage and consist almost entirely of fibrous tissue and bone is to be anticipated from the fact that these bones grow normally by membranous ossification. The findings in the cases to be reported and in those reviewed from the literature substantiate these views. They have been variously designated in the literature as fibrous osteomata or ossifying or osteofibromata, usually according to whether bony or fibrous elements predominate in the particular tumor.

Thirteen cases presenting this lesion, four in the maxilla, eight in the mandible, and one in both bones, have been studied. Two others of the maxilla previously reported by Montgomery<sup>5</sup> are briefly reviewed and illustrations of their pathology included.

#### A. FIBROUS OSTEOMATA OF THE UPPER JAW

**Case 1.**—M. S., white, female, age 15, was admitted with the history of a growth that had been noticed on the external surface of the right maxilla above and in the region of the first two molars for two years. Examination revealed essentially normal findings with the exception of a swelling of the anterior and anterolateral portion of the right maxilla and a thickening of its entire alveolar margin. Figure 1 shows the roentgenologic appearance at that time. There is a dense shadow occupying the inferior and lateral half of the right antrum and expanding the walls of the maxilla laterally and inferiorly.

At operation the mucous membrane over the tumor was incised and soft spongy bone comprising the tumor was removed with the exception of portions at the orbital margin, about the roots of the teeth, and in the region of the malar bone. The tumor was found to fill about one-half of the region of the antrum. No unossified areas were found.

Microscopic sections (Fig. 2) consist of trabeculated bone with cancellous spaces filled by immature fibrous tissue. Practically no hemapoietic cells were present. There are rows of osteoblasts along some of the trabeculae. The diagnosis was fibrous osteoma.

The patient received postoperatively 510 roentgen units in divided doses over three months. Six and one-half years later there is no evidence of progression of the tumor and the face is symmetrical.

**Case 2.**—W. P., white, male, age 11, had had a gradually increasing enlargement of the anterolateral region of the left maxilla for three years. Examination revealed no abnormalities other than a bony hard tumor in the anterior and lateral portion of the maxilla and including the alveolar process.

The patient was operated upon by Dr. Frederick Moorhead February 4, 1920. A longitudinal incision was made in the mucous membrane of the gum of the left maxilla

and the underlying bony tumor was exposed and chiseled and curetted away. The cavity was packed with gauze.

The specimen consisted of numerous small and large fragments of spongy bone.

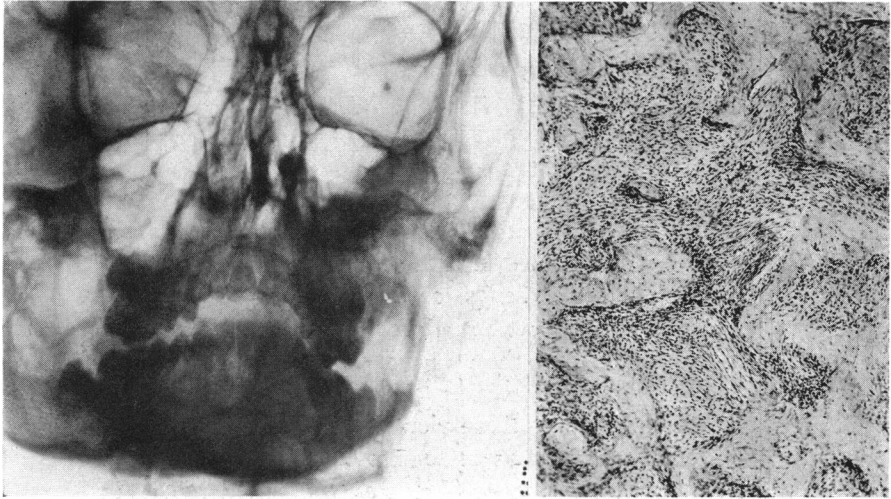


FIG. 1.—(Case 1.) Roentgenogram of the tumor of right maxilla.

FIG. 2.—(Case 1.) Photomicrograph of tissue removed.

Microscopic examination (Fig. 3) shows the tissue to be composed of fine bony trabeculae and of a fibrous marrow. The relative amounts of marrow and trabeculae vary in different regions, but nowhere are large islands of purely fibrous tissue seen. Newly forming



FIG. 3.—(Case 2.) Photomicrograph of tissue removed showing spongy bone, fibrous marrow and giant cells.

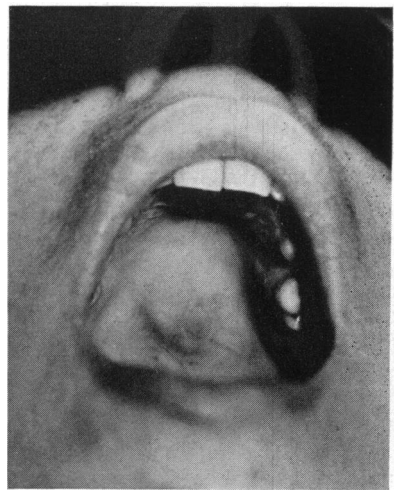


FIG. 4.—(Case 3.) Photograph of the osteoma of hard palate at seat of palatine torus.

trabeculae are numerous. Scattered throughout the sections are numerous large foreign body giant cells. There are no evidences of mitosis. The diagnosis was fibrous osteoma.

This tumor is almost identical with that in Case 1 except for the scattered areas containing giant cells. About ten years after operation the growth had remained controlled.

## FIBROUS OSTEOMA OF THE JAWS

**Case 3.**—J. McM., white, female, age 29, was admitted with the history that five years ago she first noticed a swelling of the hard palate (Fig. 4). During the last three months the overlying mucosa had become slightly ulcerated. There had been no period of rapid growth.

Examination revealed a bony hard tumor 2 cm. in diameter bulging down from the posterior portion of the middle of the hard palate, a distance of 1 cm., and a small superficial ulcer in the mucosa. A roentgenogram revealed an oval shadow of increased bone density in the region of the swelling.

Under local anesthesia a  $2\frac{1}{2}$  cm. incision was made through the mucosa of the palate and the oval protruding tumor was chiseled off sufficiently to give the palate its normal contour.

Microscopic examination showed a dense cortical bone with small marrow spaces

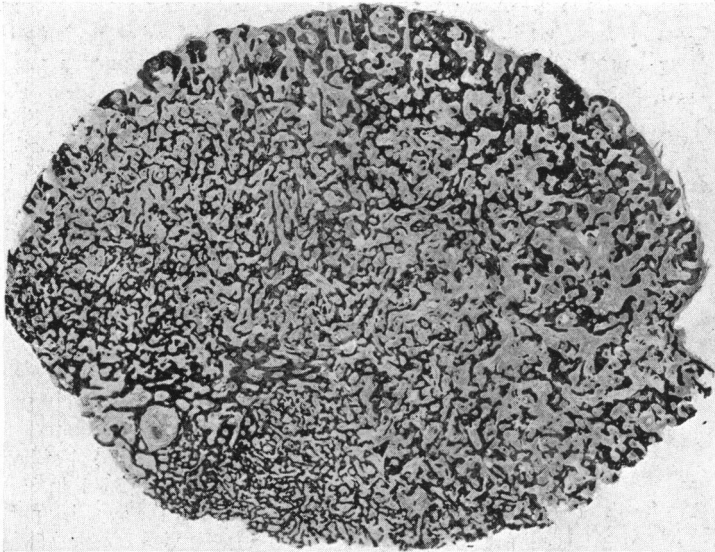


FIG. 5.—(Case 4.) Photograph of a section at middle of excised tumor.

containing partly fibrosed and partly fatty and hematopoietic marrow. Beneath this cortex was a loose cancellous bone with large irregular marrow spaces that contained a fatty marrow in which a sparse sprinkling of hematopoietic cells was present. This cancellous bone was penetrated by one broad and one narrow band of more compact spongy bone. The trabeculae of the latter stained heavily with hematoxylin and were separated by a richly cellular completely fibrous marrow.

This lesion was at the site of occurrence of the palatine torus and might be regarded as an unusually large hyperostosis but the presence of much fibrous marrow in the cancellous bone makes it seem more logical to classify it as an osteoma. H. C. Greve<sup>9</sup> is of the opinion that large tori are osteomata.

**Case 4.**—M. B., white, female, age 28, had noticed a small lump on the maxilla adjacent to the left side of the nose eight years previously. It had enlarged very slowly. Examination was essentially negative except for the bony hard swelling which bulged forward from the maxilla just beneath the mesial orbital margin and measured about  $2\frac{1}{2}$  cm. in diameter at its base. The Wassermann was positive.

In July, 1913, an oval bony tumor  $2 \times 2 \times 2\frac{1}{2}$  cm. was removed. Microscopic examination of a section taken through the middle of the entire tumor (Fig. 5) showed it to be made up of fairly dense cancellous bone containing a fibrous marrow which was richly cellular in some regions and markedly collagenous in others. There was a thin

irregular cortex along the external surface. There was a very small amount of fatty and hematopoietic marrow present. The trabeculae in several large areas were more slender, more continuous, and more closely adjacent. There were no areas of active new bone formation and no large areas of fibrous tissue. The marrow spaces were filled with fibrous tissue that was quite mature, with areas in which the cells were separated by numbers of collagen fibers. No areas of fatty or hematopoietic bone marrow were present. Diagnosis: Fibrous osteoma of maxilla.

We have had occasion to study the pathology of Cases 2 and 3, reported by Montgomery, and are reviewing them with the inclusion of illustrations which were not in his publication.

*Montgomery's Case 2.*—A male, age 66, had had a tumor removed from the right maxilla 12 years before, but it had recurred in the posterior alveolar region where there was a large oval protruding mass which was bony in its anterior portion and soft posteriorly. A roentgenogram (Fig. 6) shows dense bony shadow in the region of the antrum.

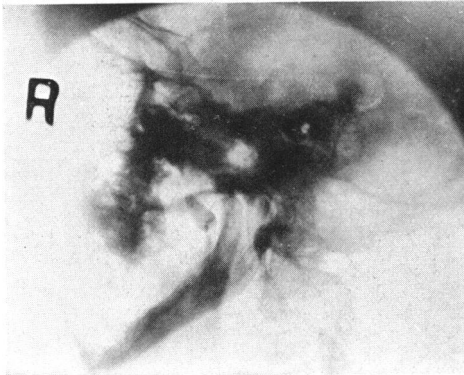


FIG. 6.—(Montgomery's Case 2.) Roentgenogram of the tumor of maxilla, partly ossified. Unossified portion displaces tooth backward.

At the posterior limits of the maxilla is a shadow of a tooth obliquely placed but with absence of a bony shadow between it and the antrum. Above and anterior to the dense shadow in the region of the antrum is the shadow of a second tooth. There are no shadows of any of the other teeth in the upper or lower jaws.

The maxilla, including the tumor, was resected. The specimen was sectioned sagittally. Its anterior and superior portions consisted of bone. There was a tooth imbedded in the anterior portion and in the superior portion there was a yellowish dense calcified area. The posterior and inferior two-fifths,

which had grown recently, consisted of soft tumor covered inferiorly and laterally by mucous membrane. There was a tooth imbedded in its posterior portion.

Microscopic examination of the ossified portion showed it to consist of dense cancellous bone. The marrow spaces in the regions that bordered on the soft tumor were filled with fibrous marrow, while some of those more remotely situated contained fatty and hematopoietic marrow. The dense yellow area in the superior part of the specimen consisted of calcified connective tissue which was undergoing bony replacement at its periphery (Fig. 7). Sections of the soft tumor consisted for the most part of immature connective tissue with wavy collagen fibers and oval to spindle shaped cells. There were mucoid regions in which collagen fibers and cells were few. At the junction of the ossified and unossified portions there were newly formed trabeculae extending into the soft tumor. The diagnosis was ossifying fibroma or fibrous osteoma with areas of calcification and mucoid degeneration.

*Montgomery's Case 3.*—A male, age 62, had a hard inverted tongue like projection of 18 years' duration from the hard palate into the mouth. The tumor was removed. It was reported by Montgomery. We have had occasion to study the pathology of the tumor and are presenting illustrations of it here. Figure 8 is a photograph and Figure 9 is a roentgenogram of the excised tumor. More than one-half of the tumor consisted of soft tissue. The superficial portion was fibrous with a covering of mucous membrane but

its deeper portion consisted of bone which extended into the tumor and sprang from the maxilla.

Microscopic examination (Fig. 10) showed that the soft portion consisted of fibrous tissue which in most of its extent was rich in irregularly coursing strands of collagen

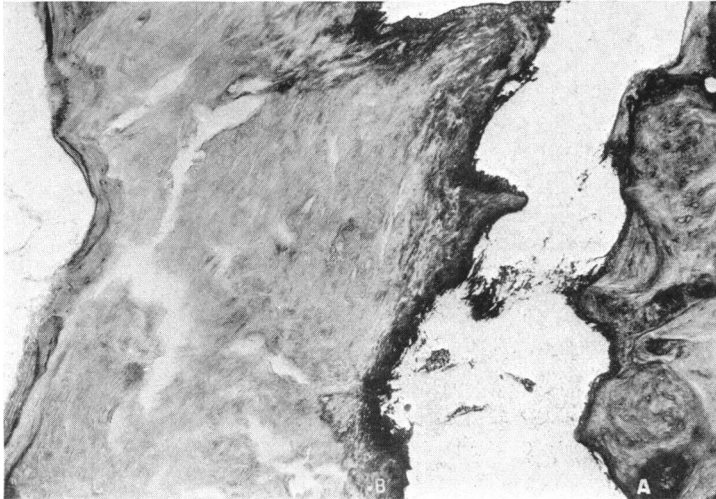


FIG. 7.—(Montgomery's Case 2.) Photograph of tumor removed showing fibrous area partly calcified. (A) Bone; (B) Calcified area; (C) Fibrous area.

fibers and contained a variable number of spindle shaped nuclei. In other places there were large mucoid spaces that were poor in collagen fibers and contained scattered branching and pyramidal nuclei. The base of the tumor contained dense mature bone with fibrous marrow from which irregularly branching rays of bone extended into the soft parts.

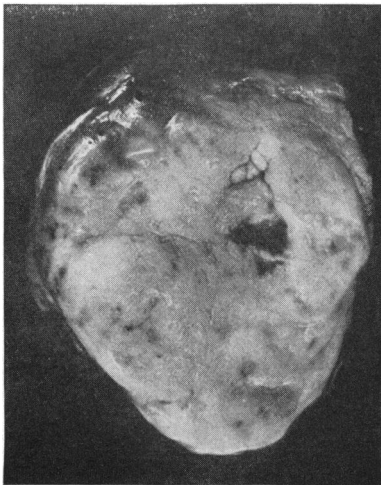


FIG. 8.—(Montgomery's Case 3.) Photograph of buccal surface of tumor removed.

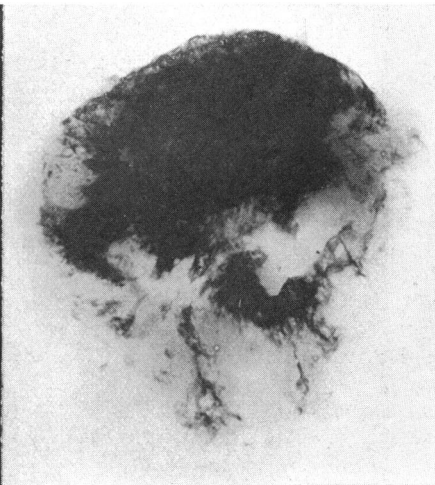


FIG. 9.—(Montgomery's Case 3.) Roentgenologic appearance of the tumor removed (Fig. 8).

Diagnosis: Because of the predominance of fibrous tissue in the case the term "ossifying myxofibroma" is more appropriate than fibrous osteoma, although eventually the entire tumor might have ossified.

B. FIBROUS OSTEOMATA OF LOWER JAW

**Case 5.**—A female, age 29, was admitted with the history that at the age of 12 she had first noticed a tumor of the left side of the body of the mandible. Several teeth were then removed from the involved area.

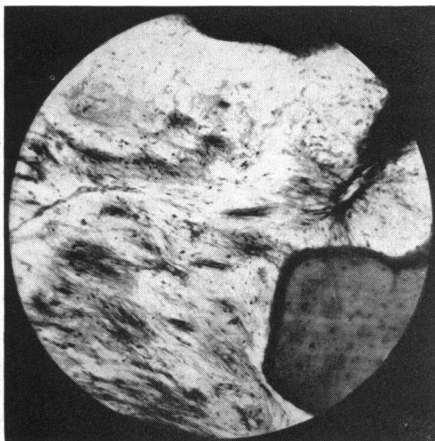


FIG. 10.—(Montgomery's Case 3.) Photomicrograph of the tissue at junction of bone and soft part of tumor shown in Figure 8.

At 16 the tumor was partially excised. Sections obtained of the tissue (Fig. 11) showed trabeculated bone with the cancellous spaces filled with richly cellular fibrous marrow. There are scattered giant cells and rows of osteoblasts along the trabeculae.

The tumor had slowly enlarged. Examination at the time of admission was essentially negative except for an oval swelling of the left half of the mandible which extended from the left angle of the jaw forward to the symphysis. There was a loss of sensation in the mucocutaneous distribution of the mental nerve. The mass bulged lingually about 1 cm., buccally about 2½ cm., and dentally about .5 cm. It extended above the level of the remaining lower teeth, and in places showed the im-

pressions of the upper teeth. Serum calcium and inorganic phosphate were respectively 10.06 and 4.42 mg. per cent.

A roentgenogram (Fig. 12) showed an oval expansion of the bony shadow of the entire left half of the body of the mandible of fairly uniform density. The cortical shadow

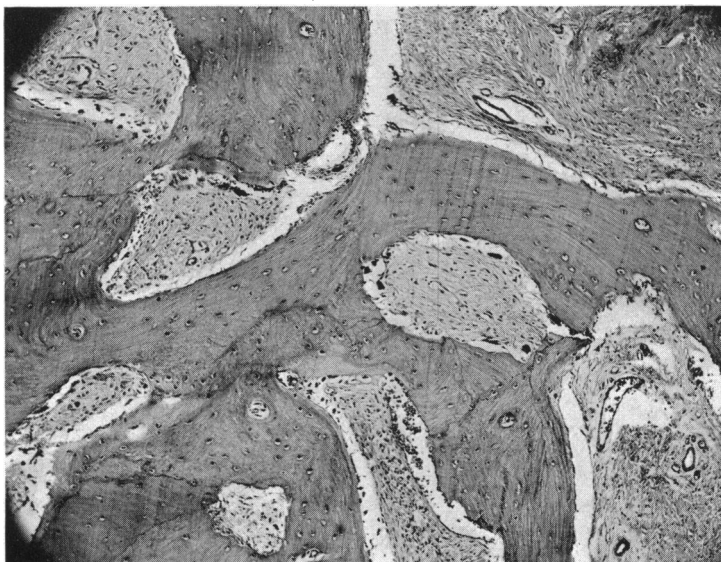


FIG. 11.—(Case 5.) Photomicrograph of tissue removed.

was greatly thinned. An incision was made along the lateral alveolar margin and the periosteum and soft parts reflected downward to expose the bony enlargement. Thirty-five grams of dense spongy tumor bone were chiseled away from the lateral surface to

restore the normal external contour of the mandible. The cortex varied in thickness, being very thin in some places. The tumor removed consisted uniformly of very dense spongy bone. No areas of softening were found.

Microscopic sections showed the same type of spongy tumor bone with fibrous marrow, osteoblasts and scattered giant cells as that removed at the first operation. Diagnosis: Fibrous osteoma. The patient made an uneventful recovery. Four months later there had been no recurrence of the swelling.

**Case 6.**—A female, white, age 12, was admitted to Presbyterian Hospital with the history that six years previously a bean sized tumor of the gum of the right side of the mandible had been excised. It recurred and ten months later had grown to the size of a hen's egg. Treatment with cautery and radium had failed to stop its growth. At the

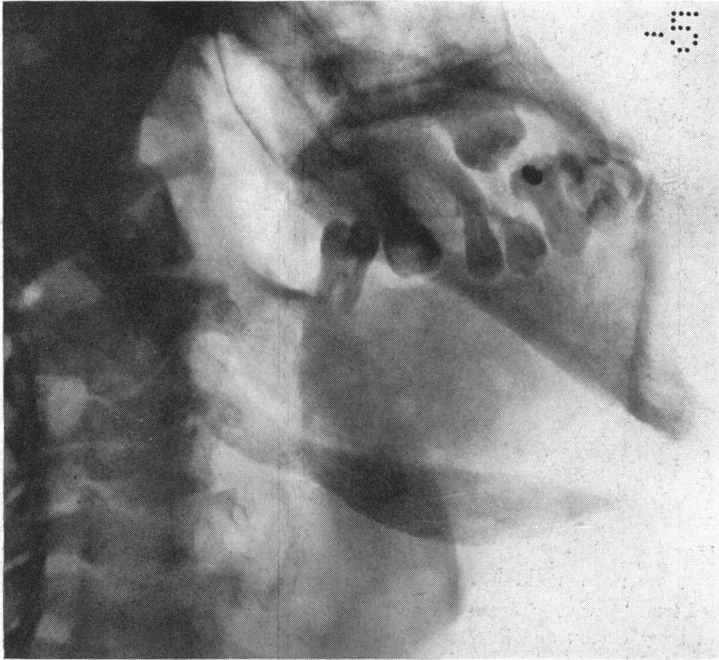


FIG. 12.—(Case 5.) Roentgenogram of the jaw 13 years after partial excision of tumor.

time of admission there was an enormous, firm, oval swelling of almost the entire body of the mandible on both sides. On the right side all the teeth but the last molar had been extracted, while the five remaining teeth on the left side were markedly displaced.

A roentgenogram (Fig. 13) showed loss of the normal shadow of the body of the mandible except about the left angle. There were radiating streaks of faint bony density extending outward into the faint shadow of the tumor which replaced the body. There were two shadows of radon seeds in its anterior portion.

At operation the entire tumor was removed en masse by Doctor Gatewood. Figure 14 is a photograph of the superior surface and Figure 15 of the cut surface of the excised specimen. The tumor consisted of firm, gray, soft tissue containing scattered radiating trabeculae of bone (Fig. 16).

Microscopic examination (Fig. 17) showed it to consist of loose fibrous and myxomatous tissue containing a few radiating spicules of bone. There were no signs of mitosis. Along the periosteal surface, at a point where bony spicules came to the periphery, there was a very thin layer of calcified cartilage which was being replaced by bone and appeared to be formed from the distended periosteum. This was the only



region in which cartilage was seen in the tumor. Two explanations for the presence of this cartilage have to be considered. One is that the tumor arose in bone that was preformed in Meckel's cartilage. By far the more probable explanation is that the tumor arose from membrane, and that in the process of rapid growth a small amount of cartilage appeared in the process of ossification similar to that frequently seen in tumors and proliferative processes in the long bones and occasionally in the healing of fractures of the mandible. Since the fibrous element greatly predominated over the bony, the most appropriate name for the lesion would be ossifying fibroma.

The operative defect was repaired by a curved rib transplant and the chin was subsequently built up by a series of plastic operations. There has been no recurrence of the tumor in the nine year interval following the operation. However, the deformity is still

severe and the case illustrates the necessity for avoidance of extensive resection of bone when possible.

**Case 7.**—A report of this case has been previously published.<sup>7</sup> A résumé with illustrations is given here.

M. O'N., white, female, age 18, had a hard oval swelling in the left antero-lateral surface of the body of the mandible that had been gradually increasing in size for four years (Fig. 18). On examination the tumor was of bony hardness. Within the mouth it extended from the second left molar anteriorly and around to the right bicuspid. It also extended upward into the alveolar process about the base of the teeth.

A roentgenogram (Fig. 19) revealed the shadow of a large oval swelling of the mandible with a thin dense cortex and a faint mottled interior. The tumor was removed through an inframaxillary incision and the defect was repaired with a horse-

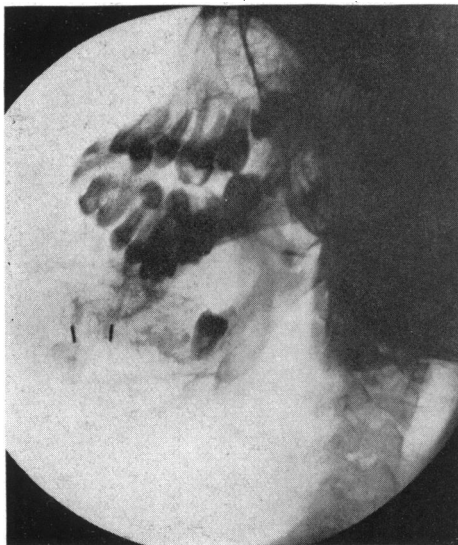


FIG. 13.—(Case 6.) Roentgenogram of the tumor showing it replacing the mandible and containing faint radiating bone; also two radon seeds.

shoe shaped transplant cut transversely from the upper end of the tibia. On section there was a thin bony cortex and interior filled with firm soft tissue throughout which were scattered small islands of bone.

Microscopic examination showed it to consist of a richly cellular immature fibrous tissue scattered throughout which were islands of spongy new bone. Diagnosis: Ossifying fibroma. Figure 20 shows the cosmetic result 16 months afterwards. There had been no recurrence of the tumor three years postoperatively.

**Case 8.**—E. B., female, white, age 37, had noticed a swelling of the gum of the right side of the mandible eight months before admission, since which time it had very slowly increased. Four months previously a biopsy was taken which showed a mozaic pattern of bony trabeculae and fibrous marrow.

Examination was essentially negative except for a hard, smooth, oval swelling involving both sides of the body and part of the ramus of the mandible on the right side. The body measured 3 cm. in thickness. The teeth were slightly irregularly displaced. Serum calcium and serum inorganic phosphate were respectively 9.89 and 3.34 mg. per cent.

A roentgenogram (Fig. 21) showed diffuse reduction in density with mottling of the shadow of the body and ramus of the right half of the mandible, and a thinning of the shadow of the cortex which was enlarged ovably along the inferior margin.

An incision was made in the buccal mucosa extending from the angle of the jaw forward slightly past the midline. The soft parts were reflected and a strip of the thin

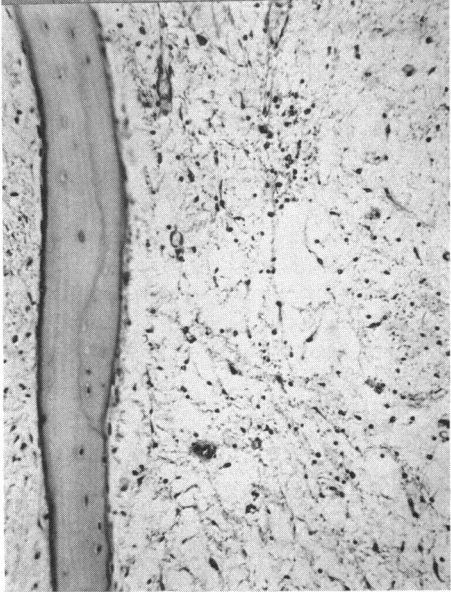
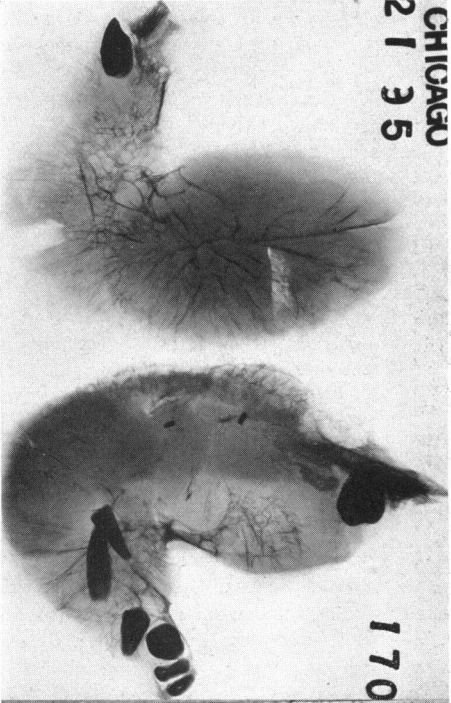
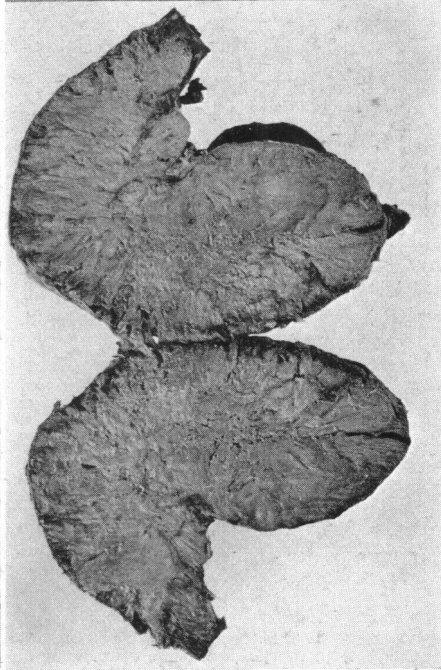
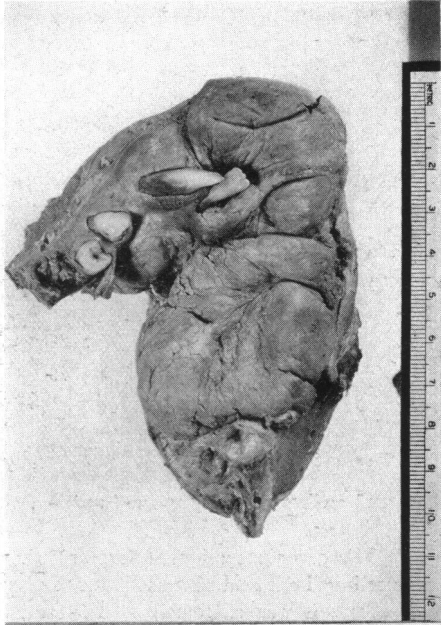


FIG. 14.—(Case 6.) Resected mandible as seen from above.  
FIG. 16.—(Case 6.) Roentgenogram of bisected specimen.

FIG. 15.—(Case 6.) Horizontal section of specimen.  
FIG. 17.—(Case 6.) Photomicrograph of ray of bone and soft tumor.

cortex running the entire length was removed. The spongy bone of the interior was curetted out exposing the roots of the teeth in places and damaging the mandibular nerve and artery. The overlying mucosa was sutured and a gauze drain inserted.

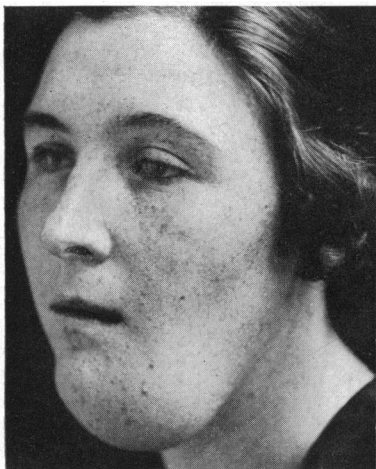

FIG. 18.—(Case 7.) Photograph of patient preoperatively.

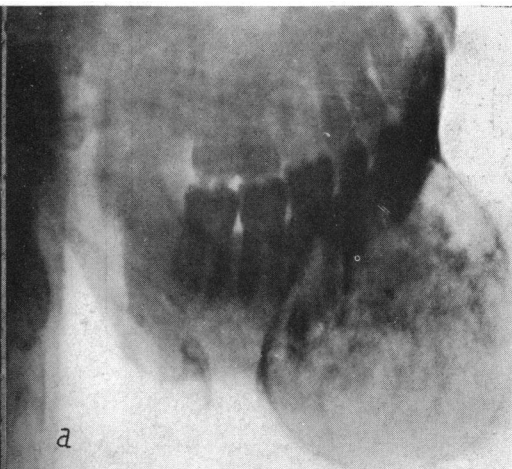


FIG. 19.—(Case 7.) Roentgenogram of jaw.

Microscopic sections (Fig. 22) show the tumor to be composed of a mixture of cancellous bone and fibrous tissue. In some places the bone was dense and mature, while in others it was extremely spongy and immature. The unossified portions consisted of spindle cells with bands of collagen fibers in many areas and numerous small vascular spaces. Giant cells were frequent in some places. There is no evidence of cell division. Diagnosis: Fibrous osteoma.



FIG. 20.—(Case 7.) Photograph 16 months postoperative, showing the cosmetic result obtained by the bone transplant after removal of the tumor.

The wound healed with little inflammatory reaction. The patient then received 1,465 roentgen units to the region of the right half of the mandible in divided doses. Ten months after operation there was no sign of recurrence of the tumor.

The wound healed with little inflammatory reaction. The patient then received 1,465 roentgen units to the region of the right half of the mandible in divided doses. Ten months after operation there was no sign of recurrence of the tumor.

**Case 9.**—A. G., female, white, age 41, was admitted with the history that nine years previously a dentist extracted several teeth and told her that she had a tumor of the mandible. It was then operated upon and subsequently had very slowly enlarged.

Examination at the time of admission was essentially negative except for the right mandible. The molars and second premolars were absent. The right side of the body of the mandible was enlarged from the region of the first premolar backward about 4 cm. Its width was about 2½ cm. The enlargement involved the inner and outer surfaces of the jaw about equally.

Serum calcium and inorganic phosphate determinations were respectively 10.04 and 4.21 mg. per cent.

## FIBROUS OSTEOMA OF THE JAWS

A roentgenogram (Fig. 23) revealed a large oval area of reduced density in the middle portion of the right body of the mandible with a jagged circular area of greater density in its central portion. No tooth shadows are in the involved region.

At operation an incision was made near the alveolar margin on the buccal and lingual

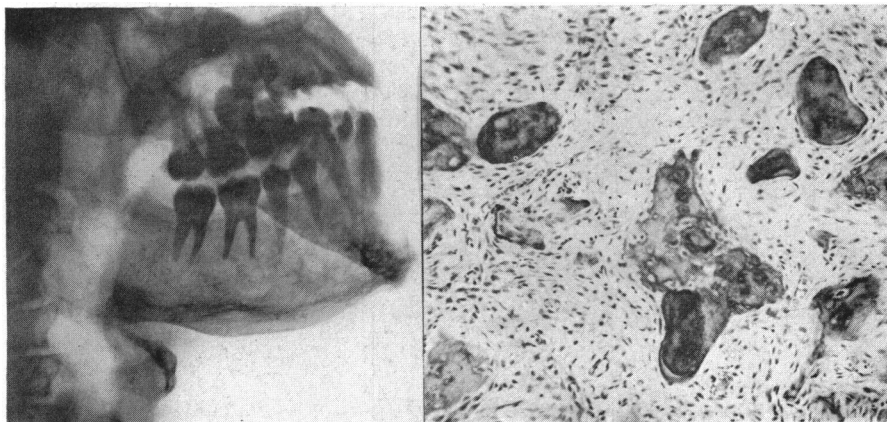


FIG. 21.—(Case 8.) Roentgenogram of the tumor of body of mandible.

FIG. 22.—(Case 8.) Photomicrograph of the tissue removed.

sides of the involved region and enough of the tumor was removed to give the bone its normal contour.

Microscopic examination (Fig. 24) revealed a dense mature bone with fibrous marrow which partitions irregular islands of partly fibrous and partly ossified tumor tissue. The ground substance of the spongy tumor consisted of an abundance of spindle cells arranged in whorls and bands among various numbers of collagen fibers. Scattered through most

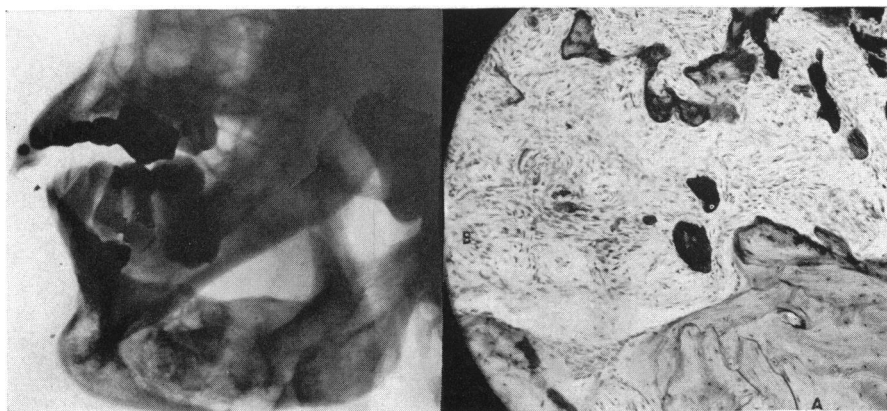


FIG. 23.—(Case 9.) Roentgenogram of the tumor in body of mandible.

FIG. 24.—(Case 9.) Photomicrograph showing (A) Dense tumor; (B) Partly ossified tumor.

of its extent were fine irregular bony trabeculae which stained deeply with hematoxylin. In other regions there were islands of osteoid tissue staining faintly with eosin. Giant cells and hematopoietic cells were absent. Diagnosis: Fibrous osteoma.

The patient recovered uneventfully. 618 roentgen units were then given over the involved area and five months subsequently there had been no change in size of the bone.

**Case 10.**—J. A., female, age 31, had had a tumor of the inferior border of the right mandible that had been present for the past 18 years. Examination was essentially nega-

tive with the exception of the scars from an old osteomyelitis of the right tibia and a smooth, hard, small, rounded tumor protruding from the inferior border of the right mandible.

Roentgenologic examination (Fig. 25) revealed a small dense semicircular shadow projecting downward from the lower border of the cortex of the body of the mandible opposite the first molar tooth.

The tumor was chiseled off under local anesthesia. It was found to consist of a dense bone with no plane of separation between it and the cortex of the mandible.

Microscopic examination of a section through the entire tumor showed a small piece of mandibular cortex included with the base of the tumor. Lamina of mature bone that were continuous with the cortex bulged outward to form the tumor base. The marrow spaces of this cortical bone were small and contained a few spindle cells but no fatty or hematopoietic bone marrow. Peripheral to this was a zone of younger and more

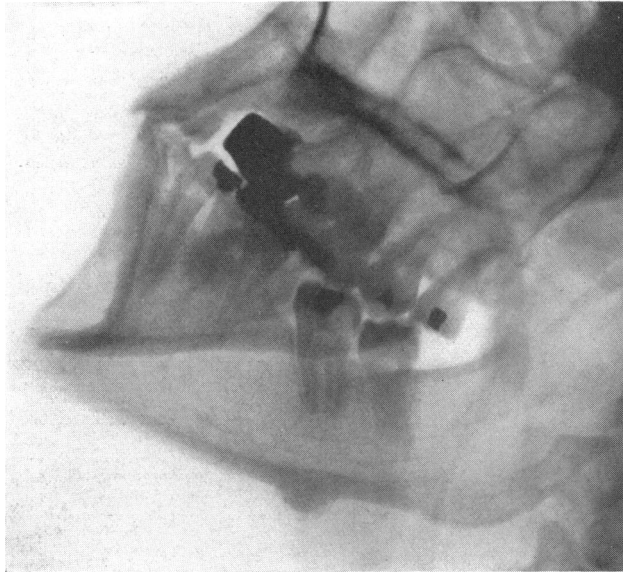


FIG. 25.—(Case 10.) Roentgenogram of the tumor of lower margin of mandible.

irregularly distributed lamina and trabeculae of bone with also small partly fibrous marrow spaces. Between this zone and the cortex was a spongy bone layer with fine trabeculae and large marrow spaces that were partly empty and partly filled with fibrous tissue. The cortex was thin and irregular. In several places osteoclasts were attacking it from the inside. Diagnosis: Fibrous osteoma.

The patient recovered uneventfully and three years later there was no evidence of recurrence.

**Case 11.**—This was similar to Case 10 and was associated with a fibrous osteoma of the frontal bone.

J. S., age 9, was admitted to the hospital because of a slowly growing bony swelling in the left lateral supra-orbital region of two years' duration, which bulged both anteriorly and into the orbit. Through an incision in the line of the eyebrow the anteriorly protruding portion of tumor was removed. One thousand five-hundred roentgen units were given in six doses during the next three months. Six months later there had been no further growth of tumor, but the portion protruding into the orbit was chiseled away because of the deformity which it produced. Three and one-quarter years after the first admission the patient was readmitted because of a pea sized hard bony swelling, of three months' duration at the lower margin of the right mandible opposite the bicuspid tooth. There

had been no further growth of the supra-orbital tumor, although roentgenograms showed slightly increased density of the remaining bone. A roentgenogram showed an oval, even bony shadow protruding from the lower mandibular surface opposite the right bicuspid tooth. At operation six weeks ago it was found to be superficially located and was chiseled off.

Microscopic examination of the half oval shaped section showed it to consist of dense spongy bone with marrow, some of which was fibrous and some fatty and hematopoietic. There was active new bone formation along the surface which was covered by a layer of osteoblasts resembling the cambium layer of the periosteum in infancy.

The occurrence of the lesion in association with an osteoma of the frontal bone is good evidence of its benign neoplastic nature and contradicts the view held by some that it is an osteodystrophy or a hypertrophy. Also, the failure of recurrence of tumor after postoperative roentgen therapy of the unremoved portion of frontal osteoma is a point in favor of this procedure for all incompletely removed fibrous osteomata.

**Case 12.**—C. T., male, age 50, was admitted with the history that six months previously he had noticed a small lump on the lateral side of the alveolar margin just anterior to the angle of the mandible. He believed that it had enlarged slightly.

Examination was irrelevant except for the left body of the mandible. All the teeth had been removed. In the region previously occupied by the last premolar and first molar teeth the alveolar margin and upper half of the body of the mandible were expanded by a hard painless tumor which protruded about 6 Mm. buccally and 2 Mm. dentally. The overlying mucosa was intact.

A roentgenogram reveals a slight elevation of the alveolar margin of the body of the mandible about 1 cm. forward from its junction with the ramus. The cortical shadow is destroyed. Beneath this in the upper half of the body of the mandible is an irregular area of reduced density. A small irregular area in its center has a density similar to the uninvolved portion of the body of the mandible.

The tumor was exposed through an incision in the overlying mucous membrane and removed. It involved the entire thickness of the mandible and consisted of a dense spongy bone. The patient made an uneventful recovery.

Microscopically the tumor consisted partly of regions of dense bone with fibrous marrow and partly of regions of spongy bone with a marrow that was partly fibrous and partly hematopoietic. The lesion appeared to be stationary and of long standing. Diagnosis: Fibrous osteoma.

### C. FIBROUS OSTEOMA OF BOTH JAWS

**Case 13.**—White, male, age 8, entered the hospital with the history of a swelling in the right maxilla noticed by his parents for three and one-half years. A month before his admission three deciduous teeth at the site of the tumor had been removed and a biopsy taken. Examination was irrelevant aside from the jaws. There was a bony hard enlargement of the entire right maxilla which protruded in the infra-orbital alveolar and palatal regions. No change was observed in the other maxilla or in the mandible. Roentgenologic examination (Fig. 26) showed a dense radio-opaque shadow in the region of the enlarged maxilla and filling out the antrum. There was slight thinning of the shadow of the cortex of the right half of the body of the mandible with slight expansion at the angle of the jaw and an area of circumscribed reduction in density 1 cm. in diameter beneath the permanent premolar tooth.

Under ether anesthesia the mucous membrane along the alveolar margin of the maxilla was incised and a spongy bony mass was thus exposed involving the whole enlarged maxilla and extending into the border of the malar bone. The wall was cut away and the interior of the maxilla curetted out leaving a thin shell. Three permanent teeth were removed. No antrum was present. There was a spherical mass of soft myxomatous tissue about 1 cm. in diameter in the vicinity of the premolar teeth. The remainder of the

tumor consisted of soft spongy bone. No cysts were present. Figure 27 shows the trabeculae of bone and the fibrous tissue filling the marrow spaces. A section of the soft mass showed it to be composed of myxomatous tissue (Fig. 28). No giant cells or

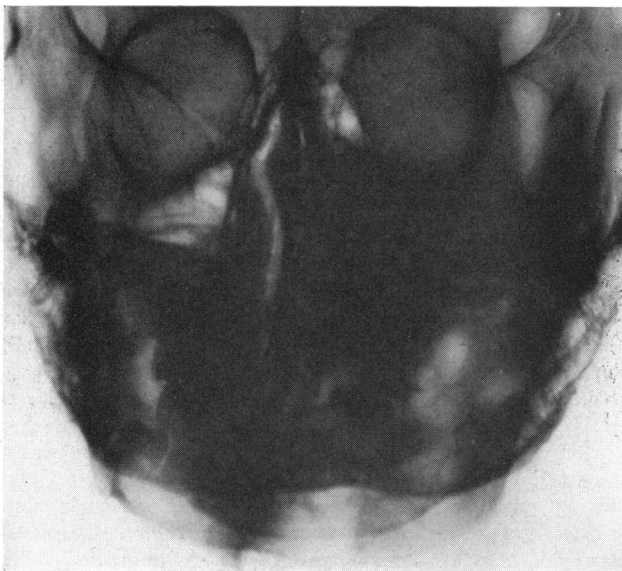


FIG. 26.—(Case 13.) Roentgenogram showing dense tumor of right maxilla, and a beginning tumor in right side of mandible.

mitotic figures were seen. Diagnosis: Fibrous osteoma of maxilla containing one myxomatous area.

Because some of the tumor about the walls was left behind it was decided to administer

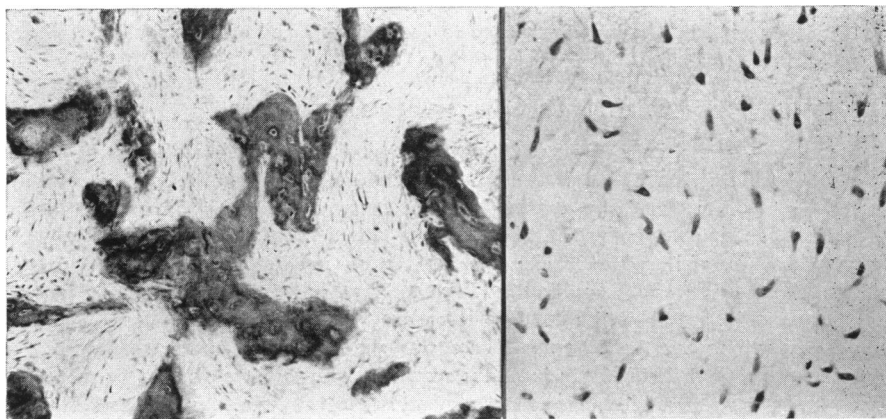


FIG. 27.—(Case 13.) Photomicrograph showing spongy bone with fibrous marrow.

FIG. 28.—(Case 13.) Photomicrograph showing an area of myxomatous degeneration.

roentgen therapy in an endeavor to restrain its further growth. During the next 15 months the patient received 3,883 roentgen units to the maxilla and recent examination six years after operation revealed only slight progression in the form of a pea sized nodule on the anterolateral aspect of the maxilla.

A year and one-half after the operation on the maxilla some enlargement was noted

## FIBROUS OSTEOMA OF THE JAWS

of the right half of the body of the mandible. During the next two months it was given 824 roentgen units but the overgrowth continued slowly during the next four years and it extended into the right ramus slightly past the midline anteriorly (Fig. 29). A roentgenogram (Fig. 30) showed a marked expansion of the shadow of the entire right half and the mental portion of the left half of the mandible. The cortical shadow was thin

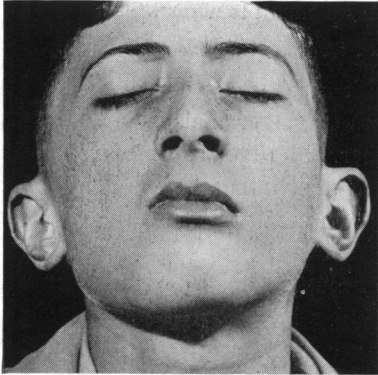

FIG. 29.—(Case 13.) Photograph five years after removal of tumor of right maxilla. The mandible is now the site of tumor formation.

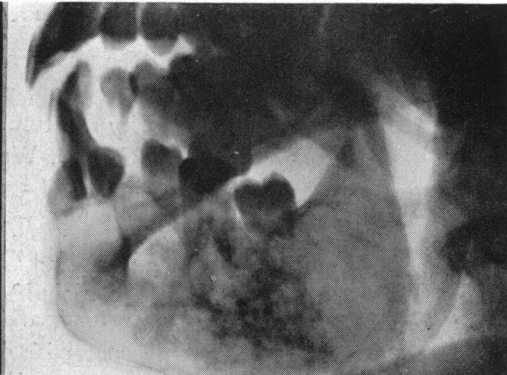

FIG. 30.—(Case 13.) Roentgenogram made at time of photograph shown in Figure 29.

and the interior faint and mottled with two large areas of greatly reduced density along the inferior margin in the premolar to bicuspid region. Operation was performed for removal of the tumor and restoration of normal contour of the mandible. Serum calcium was 10.08 mg. An incision was made along the inferomesial border of the right half of the mandible and the periosteum reflected to expose the lateral and inferior surfaces of the

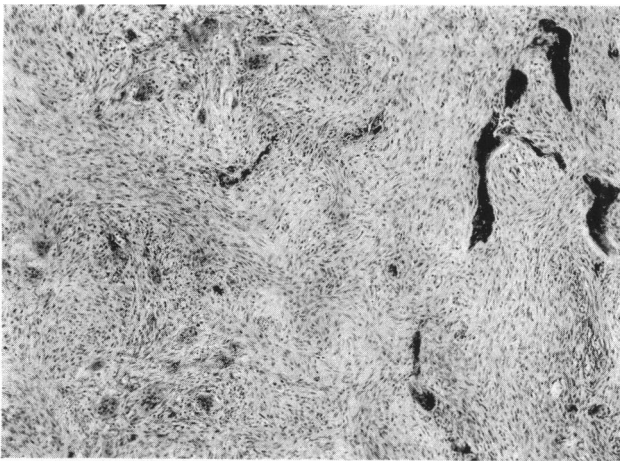


FIG. 31.—(Case 13.) Photomicrograph of the tissue contained in the tumor of the mandible, showing bony and fibrous areas and many giant cells ( $\times 125$ ).

enlarged bone. Approximately two and one-half centimeters of the lateral surface and two centimeters of the under surface of the mandible were chiseled away. The mental nerve was exposed and preserved. There were two large oval areas of soft tissue which upon microscopic examination proved to be composed of myxomatous tissue of a mature type containing areas of fibrous tissue and areas of calcification and bone formation.



Microscopic examination showed the remainder of the tumor to be more or less extensively ossified. The bone was cancellous and the marrow consisted of cellular fibrous tissue. There were scattered areas of fibrous tissue in which there was no ossification but in some places there were clusters of giant cells simulating the picture of benign giant cell tumor (Fig. 31).

Thirteen months after the operation there was practically no further growth of the mandible and the facial configuration had become restored almost to normal.

DISCUSSION.—Osteomata of the membrane bones in general are frequent, and the literature, old and new, is replete with cases, most of which are incompletely reported. The majority are tumors of the cranial vault and walls of the accessory nasal sinuses. Carl O. Weber,<sup>8</sup> in 1856, reported that in a total of 95 cases, 43 were of the jaws and 52 of the skull and remaining bones of the face. Sjoberg<sup>9</sup> reports a total of 19 osteomata of the maxillary sinus in the literature up to 1935 and adds two more cases.

It is a common experience of dentists to encounter small osteomata on the lingual surface of the alveolus of the mandibular bicuspid which necessitate removal because of their interference with dentures. According to Partsch<sup>10</sup> this lesion is often symmetrical and Greve<sup>11</sup> refers to it as symmetrical mandibular tori. Also a small osteoma or hyperostosis, the palatine torus, is not infrequently observed in the posterior midline of the hard palate that is too small to call for surgical removal.

Numerous medical and dental text-books and journals contain brief and incomplete accounts of cases similar to the 13 here reported. Furedi has recently given incomplete descriptions of 14 cases involving maxilla. A considerable number of cases have also been reported in detail. They have been variously designated as osteofibroma, ossifying fibroma, osteoma, fibrous osteoma, exostosis, localized osteitis fibrosa, osteodystrophia fibrosa localizata, localized Paget's disease, "intra-osseous epulis," and hypertrophic localized osteitis. A summary is given of 30 detailed reports by Hildebrand,<sup>12</sup> Gangnieri,<sup>13</sup> Hippel,<sup>14</sup> Uyeno,<sup>15</sup> Menzel,<sup>16</sup> Mauclair and Maurel,<sup>17</sup> Monnier,<sup>18</sup> Montgomery,<sup>19</sup> Moorehead,<sup>20</sup> Kindler,<sup>21</sup> Potts,<sup>22</sup> Konjetzny,<sup>23</sup> Kriegsmann,<sup>24</sup> Renner,<sup>25</sup> Axhausen,<sup>26</sup> and Dechaume.<sup>27</sup> Twenty-four of these tumors began between the ages of eight and 32. The oldest age of onset was 54. Only three of the reported cases were followed more than a year. Seven years was the longest postoperative period of observation. Nineteen occurred in either maxilla and seven in the body of either side of the mandible. One reference was found to a tumor of the maxilla and the mandible on one side in the same patient.

No cases were reported to have undergone sarcomatous change. One lentil sized cyst was reported near an antrum in one tumor, and small cyst like spaces 2 to 5 Mm. in diameter were reported in another. Giant cells in small numbers were described in five, and myxomatous areas in one. Trabeculae of new bone in a mosaic pattern and fibrous marrow spaces characterized all the reports.

A history of trauma was emphasized as an etiologic factor in two cases,

a history of caries of the teeth and extraction in 11, and pharyngeal infection in three. Blood calcium had been analyzed in only one case and it showed a moderate hypocalcemia. A positive statement of the remaining skeleton in ten cases described no other bone pathology.

The first available detailed description of this type of tumor was published by Menzel in 1872. It had been noticed in the mandible at the age of ten and had grown in the next 25 years to the size of a fetal head. It was then removed because of threatened obstruction to the air and food passages. The gross and microscopic diagnosis was a benign osteofibroma.

Many years later the histologic resemblance between these localized tumors and the marrow fibrosis with new bone formation of osteitis fibrosa generalisata (von Recklinghausen's disease) was emphasized by numerous surgeons. From this period up to the time of the discovery by Collip,<sup>28</sup> in 1925, of the parathyroid hormone, and the demonstration of its relationship to osteitis fibrosa generalisata by Jaffe, Bodansky, and Blair,<sup>29</sup> in 1930, these jaw tumors were considered by many to be directly related to von Recklinghausen's disease.

In the cases in this study no abnormalities of blood calcium and phosphorus or of the remaining skeleton have been found. Also cysts have been absent and giant cells infrequent. Although the etiology of these tumors is undetermined there seems to be little indication to relate them to osteitis or osteodystrophia fibrosa generalisata or localizata, and similarly they do not resemble Paget's disease or epulis. It appears that, in a general manner, these tumors have a relationship to membrane preformed bone parallel to the relationship that benign cartilaginous tumors and exostoses have to cartilage preformed bone. This view is substantiated by their tendency to begin in childhood and to grow slowly or not at all in adult life as is the case with cartilaginous exostoses.

A study of the histology of this group of tumors brings out the great variability in the amount of fibrous and osseous tissue. Some tumors are composed of rather mature bone trabeculae with partly fibrosed marrow. Others have islands of fibrous tissue undergoing varying degrees of ossification and calcification. There may also be areas of myxomatous tissue and giant cells. In a few the tumor is chiefly fibrous tissue with small amounts of ossification. The terms fibrous osteoma, osteofibroma, and ossifying fibroma are often used more or less interchangeably. The more mature tumors with extensive ossification are probably better called fibrous osteomata, while those in which fibrous tissue and immature bone predominate justify the terms osteofibroma or ossifying fibromata. Round cell infiltration and other inflammatory changes were, in general, conspicuous by their absence.

Symmetrical osteomata have rarely been described, most of the symmetrical jaw tumors being reported as fibromata of the gums (Perthes,<sup>30</sup> Rosenstein,<sup>31</sup> Koblin<sup>32</sup>).

*Treatment.*—The treatment of this condition, as detailed in the literature, has been varied. Eleven of the older cases were treated by complete resection, one by partial excision and roentgen therapy, two were biopsied and received

roentgen therapy, and three received no treatment after biopsy. The early treatment by massive resection was very disfiguring and carried a high mortality. In view of the benign nature of the lesion it is no longer justified. Biopsy should certainly be performed as soon as the tumor is noticed, since it is, usually, otherwise impossible to establish its benign nature definitely. The decision not to interfere with a tumor may be justified in some instances in view of the very slow rate of growth and slight disfigurement. The majority of authors agree, however, that the tumors should be operatively removed as thoroughly as possible without too great destruction of the jaw bone. It must be emphasized, however, that one operation does not necessarily cure the patient. The condition may recur and require further partial or total resection.

Irradiation has not been generally used in these tumors of the jaw. Six of the cases here reported with incompletely excised tumors received roentgen therapy. One was markedly, and another moderately, benefited, although the process continued slowly in the other jaw despite irradiation, and four were too recently treated to warrant an expression of opinion. In one recent case a frontal bone osteoma that had been partly removed three years previously and then treated by roentgen therapy has been held in check. The experience in treatment of these patients makes it appear that roentgen therapy is beneficial in controlling portions of the tumor not removed at operation. Authors report benefit from radium treatment but also point out the danger of bone necrosis and slough following its use.

SUMMARY.—Thirteen cases of fibrous osteoma of the jaws are reported and the pathology of two other recorded cases discussed. The bone was formed by the process of fibrous or membranous ossification, cartilage being seen in a minute trace in only one case. In 12 cases the tumor consisted largely of cancellous bone and fibrous marrow. In three it consisted largely of fibrous tissue in varying degrees of maturation, and ossification was proceeding slowly. There was also myxomatous tissue present in three cases and occasional small islands rich in giant cells in two. Microscopic signs of inflammation were rarely present.

#### CONCLUSIONS

In general, the tumors are slowly growing, and when starting in childhood tend to become stationary in adult life. No case has been recorded which has become malignant. Blood calcium and phosphorus were determined in four cases and found to be normal. The lesion appears to be a true neoplasm and not a form of osteitis fibrosa, hyperostosis or chronic inflammation. The treatment consists in complete operative removal when the lesion is small and circumscribed. But in cases with diffuse involvement of the bone the operation should, as a rule, be limited to partial removal in order to avoid defects in the jaws and extensive disfigurement. Repeated operations may be necessary. Roentgen therapy was found to retard growth of the unresected portion of tumor for long periods in two cases.

REFERENCES

- <sup>1</sup> Romer, A. S.: Man and the Vertebrates, 1933.
- <sup>2</sup> Fawcett, E.: The Development of the Bones Around the Mouth. Great Britain Dental Board, **1**, 23, 1924.
- <sup>3</sup> Schaffer, J.: Arch. f. mikr. Anat., **32**, 266-377, 1888.
- <sup>4</sup> Greve, Karl: Deutsche Zahnh., **67**, 1-64, 1927.
- <sup>5</sup> Montgomery, A. H.: Arch. Surg., **15**, 30-44, 1927.
- <sup>6</sup> Greve, H. Christian: Deutsche Monatschrift f. Zahnheilkunde, **37**, 203, 1919.
- <sup>7</sup> Phemister, D. B.: Surg. Clinics, Chicago, **1**, 203, 1917.
- <sup>8</sup> Weber, Carl O.: Die Exostosen u. Enchondrome. Bonn, 1856.
- <sup>9</sup> Sjoberg, Arne: Acta oto-laryng., **23**, 157-166, 1935.
- <sup>10</sup> Partsch.: Chirurgische Erkrankungen der Mundhöhle, der Zehne u. Kiefer. Wiesbaden, 1917.
- <sup>11</sup> Greve, H. Christian: *loc. cit.*
- <sup>12</sup> Hildebrand, Quoted by Hippel: Lehrbuch der Allgemeinen Chirurgie, 345, 1909.
- <sup>13</sup> Gangnere: Thèse de Paris, 1910.
- <sup>14</sup> Hippel: Ztschr. f. Mund und Kieferchirurgie, **1**, 110, 1915.
- <sup>15</sup> Uyeno: Beitr. z. klin. Chir., **65**, 301, 1909.
- <sup>16</sup> Menzel, A.: Arch. f. klin. Chir., **13**, 212, 1872.
- <sup>17</sup> Mauclair and Maurel: Bull. et mém. Soc. anat. de Paris, **88**, 113, 1913.
- <sup>18</sup> Monnier, L.: Paris chir., **5**, 842, 1913.
- <sup>19</sup> Montgomery, A. H.: Arch. Surg., **15**, 30-44, 1927.
- <sup>20</sup> Moorehead, F. B.: S. Clin. North America, **7**, 517-523, 1927.
- <sup>21</sup> Kindler, W.: Ztschr. f. Laryng., Rhin., Otol., **25**, 54-59, 1934.
- <sup>22</sup> Potts, H. A., and Hatton, E. H.: J. A. M. A., **81**, 2015-2017, 1923.
- <sup>23</sup> Konjetzny, G. E.: Arch. f. klin. Chir., **121**, 567-634, 1922.
- <sup>24</sup> Kriegsmann, G.: Archiv. fur Ohren, Nasen, und Kehlkopfheilkunde, **137**, 31-36, 1933.
- <sup>25</sup> Renner, C.: Arch. f. klin. Chir., **175**, 388-408, 1933.
- <sup>26</sup> Axhausen, G.: Arch. f. klin. Chir., **174**, 434-446, 1933.
- <sup>27</sup> Dechaume, M.: Presse méd., **42**, 1124-1126, 1934.
- <sup>28</sup> Collip, J. B.: J. Biol. Chem., **63**, 395-438, 1925.
- <sup>29</sup> Jaffe, H. L., Bodansky, A., and Blair, J. E.: Klin. Wchnschr., **9**, 1717-1719, 1930.
- <sup>30</sup> Perthes: Die Verletzungen u. Krankheiten der Kiefer. Stuttgart, 1907.
- <sup>31</sup> Rosenstein, P.: Symmetrische Geschwülste der Mundhohle. Deut. Monatschr. f. Zahnheilkunde, **30**, 321, 1912.
- <sup>32</sup> Koblin, H. A.: Zur Ursache der Symmetrischen Schwellungen der Zahnfartsatze. Virchow's Arch. f. path. Anat., **283**, 631, 1932.