# RUPTURE OF THE LUMBAR INTERVERTEBRAL DISK

## AN ETIOLOGIC FACTOR FOR SO-CALLED "SCIATIC" PAIN

WILLIAM JASON MIXTER, M.D.

BOSTON, MASS.

FROM THE SURGICAL SERVICES OF THE MASSACHUSETTS GENERAL HOSPITAL, BOSTON, MASS.

SCIATICA is a common complaint. We believe we can show that an unknown but probably a small percentage of cases of intractable "sciatic" pain are caused by rupture into the spinal canal of a lumbar intervertebral disk, that the lesion can be accurately demonstrated and that operative treatment will effect a cure.

In preliminary communications[1, 2] we have traced the earlier literature concerning rupture of the intervertebral disk. Notable among these contributions are those of Goldthwait,[3] Middleton and Teacher,[4] Dandy,[5] and Schmorl.[6] We linked with these the reports of so-called enchondroma of the intervertebral disk especially emphasized by Elsberg[7] and Stookey[8] and reported Barr's[1] recognition of the fact that these two lesions usually were one and the same, and not separate entities. True enchondroma of the spine does occur, but it is rare.

Since our last observations,[2] certain other reports have been published relative to this condition, notably those by Hampton and Robinson[9] concerning the roentgenologic findings in these cases, that by Love,[10] from The Mayo Clinic, and that by Barr.[11]

While most of the cases reported here have been operated upon by me, I wish to thank Dr. John S. Hodgson and Dr. James C. White for allowing me to include their cases. I also wish to thank the neurologic, orthopedic and roentgenologic departments. Without their coöperation this work could not have been accomplished.

We have been particularly interested in those cases in which one or the other of the two lower lumbar disks were affected. They are by far the most common and we believe that many have been overlooked in the past.

Extrusion of a small disk fragment into the spinal canal usually causes none of the signs that we associate with lesions of the cauda equina. In common with several well-known diseases such as lumbosacral strain, sacroiliac strain, *etc.,* this condition is characterized chiefly by pain. This pain is of the type referred to for many years as sciatica. If, as occasionally happens, the extruded disk fragment is large, the signs are similar to those found in cases of tumor of the cauda equina.

About 60 per cent of these cases will give a history of trauma at, or shortly before, the onset. The one outstanding feature is pain, starting in the back, streaming down the thigh and the outer side of the leg to the ankle. The pain is severe, lancinating in character, is brought on by bending or lifting and is usually lessened by lying down and sometimes by strapping. The pain

comes in attacks and there may be long remissions. There is limitation of motion in and flattening of the lower back. Frequently there is a list to the side of the lesion. Ability to raise the leg in extension is limited. This is the one positive, objective sign present in all cases but is of little diagnostic significance because of the frequency with which it occurs from other causes. In some cases raising the good leg will cause pain in the bad one. Neurologic signs are few. The one that we have come to expect is absence or diminution of the ankle jerk on the affected side. Even this sign is absent in at least 40 per cent of our cases. Roentgenologic examination of the lumbar spine occasionally shows narrowing of the intervertebral disk but this is not common enough to be of diagnostic significance. In those cases where there is gross compression of the cauda equina we find much more outspoken signs and symptoms but, as stated above, these are rare.

It is apparent that a diagnosis of ruptured disk cannot be made on such meager evidence, but such evidence is enough to arouse suspicion.

Unless conservative orthopedic treatment brings relief in a reasonable length of time, every case presenting this picture of intractable sciatic pain, splinting of the back and limited straight-leg raising should have a lumbar puncture performed. The needle is inserted into the fifth space or if this is impossible, into the fourth, and the first few drops of fluid withdrawn are set aside for determination of the total protein. The usual routine manometric and laboratory examinations are made but are usually uniformly negative. The one important test is the determination of the total protein in the first fluid withdrawn. This is important, as the fluid higher up in the lumbar portion of the spinal canal may show a normal protein content even if that low down is abnormal.

We may assume that a total protein content of 40 or 45 mg. per cent is the upper limit of normal and that any figure above this level is highly suggestive of some pathologic condition. If this is the case, examination of the spinal canal with lipiodol is indicated. As 15 per cent of proven cases showed a total protein of below 40, the presence of a normal spinal fluid will not rule out ruptured disk. Lipiodol examination is indicated in cases with normal protein content before major orthopedic operations such as lumbosacral or sacro-iliac fusion are performed.

The final diagnosis of ruptured disk rests almost entirely on the roentgenologic examination following the injection of 5 cc. of lipiodol into the lumbar portion of the spinal canal. It is not necessary to go into the technic of this examination. It has been well described by Hampton and Robinson.[9] In order to obtain accurate information this technic must be carried out very carefully. It includes careful fluoroscopic examination on the tip table, the lipiodol being run up and down repeatedly in the spinal canal and spot plates taken when the defect is demonstrated.

We know that lipiodol seldom gives any lasting symptoms but it is never absorbed and therefore should not be employed unless the indications are clear.

I believe it should be reserved for those cases with an elevated total protein, those in which adequate and prolonged orthopedic treatment has been unsuccessful, and in which some other definite cause of sciatic pain cannot be found.

The causes of a total protein content above normal limits need further investigation. We have records of 21 unoperated cases that were subjected to lipiodol examination with negative findings. In four the total protein was below 40 and in 17 the elevated protein content has not been explained satisfactorily.

It is uncertain whether rupture of an intervertebral disk is entirely the result of injury or whether there may be an underlying weakness in the disk

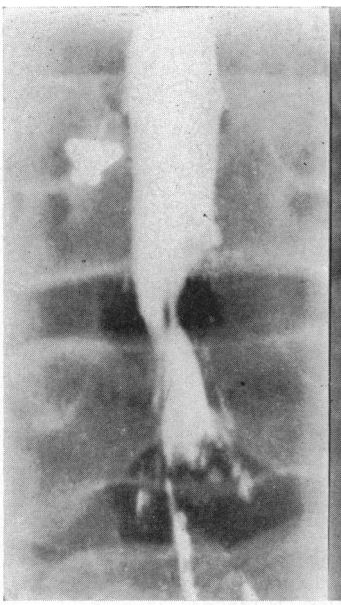

FIG. 1.—Rupture fourth lumbar disk. Large lateral defect in lipiodol column.

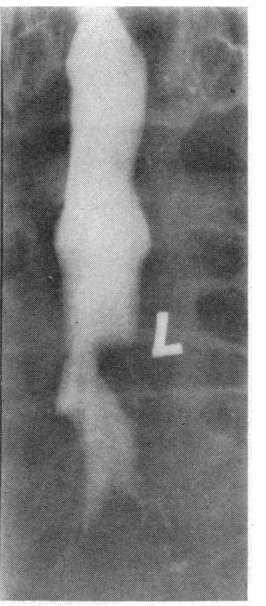


FIG. 2.—Rupture fourth lumbar disk. Moderate sized defect. (New England Jour. Med., August 29, 1935.)

itself. It is certain that we find this lesion in a few individuals who deny specifically ever having had any serious back injury.

The lesion commonly found at operation is a definite break in the annulus with protrusion into the spinal canal of a portion of the annulus accompanied by some of the nucleus pulposus (Fig. 3). The extruded fragment usually lies anterior to the dura and the posterior longitudinal ligament and is compressed into a hemispherical mass by these structures. The fragment is irregular, appears to have been torn and frequently has no attachment to the rest of the disk. A definite opening in the annulus can be demonstrated leading down into the nucleus.

We believe that this lesion tends to permit increased mobility between the vertebral bodies. Therefore, we have planned our operative procedure with

this in mind. It is unnecessary to perform an extensive laminectomy as long as the exposure is accurately planned. Let us take, for example, a rupture of the fourth lumbar disk. The laminae are exposed as usual, the spinous processes being preserved attached to the muscles on one side. The lamina of the fourth lumbar vertebra on the affected side is resected. The other side is left long, only a portion of it being removed. The lower edge of the lamina above and the upper edge of the one below are removed, care being taken not to remove the whole of either (Fig. 4). It is now possible to palpate the spinal canal and the protruding fragment can be felt in most cases. If the lesion is far out at the side of the disk or cannot be recognized the exposure

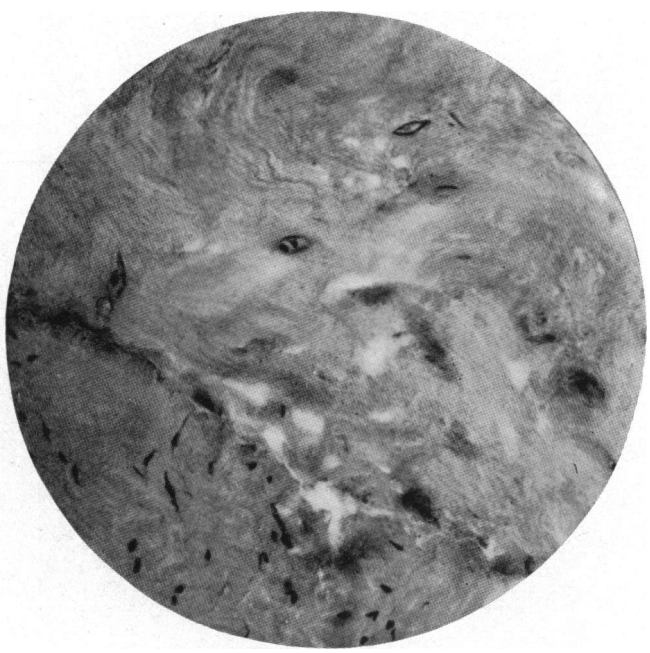

FIG. 3.—Photomicrograph from specimen obtained at operation. Material from annulus on the left, and from nucleus on the right.

is widened by removing the articular process of the fourth entirely. It will then be seen that the anterior border of the facet of the fifth and the ligamentum flavum overlie the fifth root sheath. It is usually necessary to cut these two structures away even if the mass can be felt. It probably is wise to do so anyway as the articular facet is the structure against which the fifth root is pressed by the disk fragment which lies in front of the root. The lumbar portion of the card is then drawn over toward the midline, either above or below the root sheath according to the position of the mass (Fig. 5). This exposes the posterior longitudinal ligament which is incised and the fragment removed (Fig. 6). It usually lies free and can be teased out without difficulty. The opening running down to the nucleus pulposus can then be demonstrated.

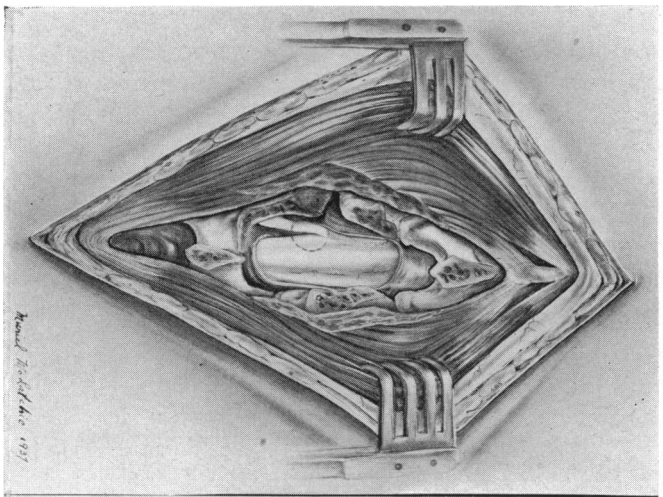

FIG. 4.—Dura exposed. Mass can be palpated through the dura.

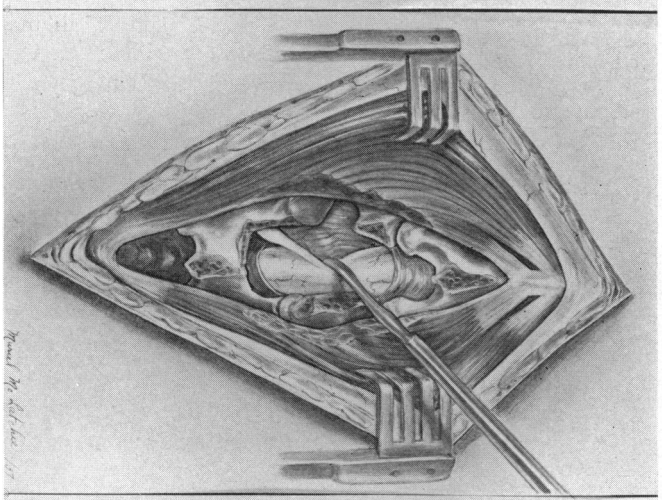

FIG. 5.—Lumbar portion of the cord drawn aside. Mass showing through the posterior longitudinal ligament.

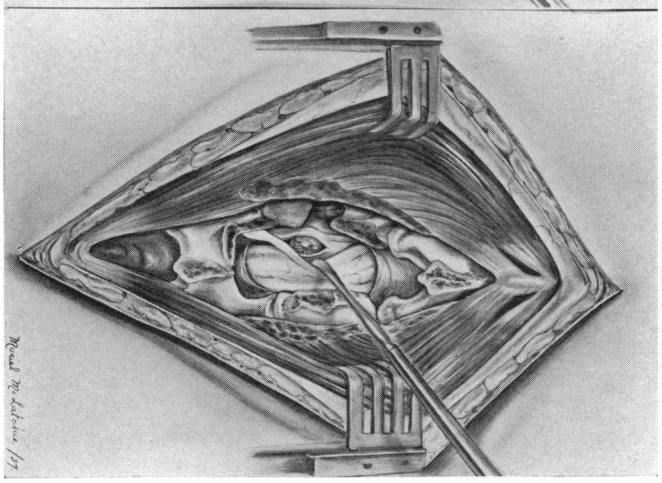

FIG. 6.—Posterior longitudinal ligament incised exposing the extruded fragments.

Sometimes it is easier to remove the fragment by incising the dura posteriorly and again anteriorly and in many instances we have opened the dura simply to remove the lipiodol. If this is done the root or roots riding over the fragment can be inspected. It will be seen that the compressed root is distinctly reddened and edematous, unlike the rest of the cauda equina. In a few cases instead of a frank rupture with an extruded fragment we have found a general bulging of the whole edge of the intervertebral disk (Fig. 7). It is as though the disk had been compressed and had mushroomed backward. Usually we have trimmed off some of the protruding disk where it seemed to compress the fifth root. In others we have contented ourselves with removing the edge of the facet. These cases are not as satisfactory as those in which there is a frank rupture.

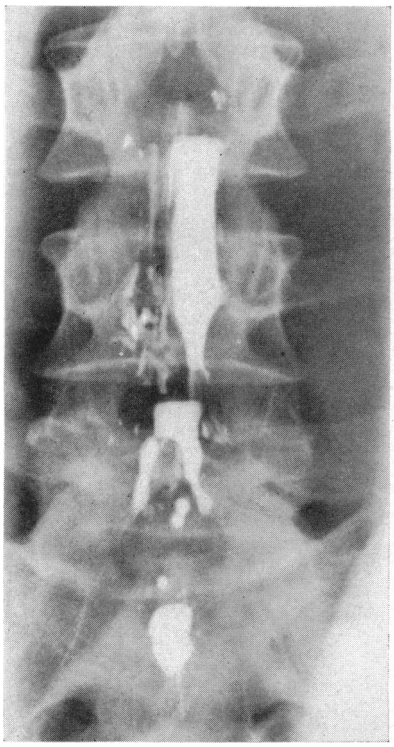

FIG. 7.—General posterior bulging of the disk margin. That on the right is the most marked.

We have felt that any laminectomy must further weaken a spine already weakened by rupture of the disk. For this reason we have felt that some form of fusion is advisable in many instances. This is particularly true in patients who do heavy work. If fusion is indicated it is carried out by a member of the orthopedic department as soon as the fragment has been removed.

A surprising phenomenon that one notes in handling a group of these cases is the immediate relief obtained. Many times the patient will tell you that the pain in his leg is completely relieved as soon as he recovers from the effect of the anesthetic.

In all, we have operated upon 58 cases of rupture of one or another of the lumbar disks.

During the investigation of this subject, seven cases have been operated upon in which no abnormality of the disk was demonstrable. In three, chronic arachnoiditis was found and in four, no lesion within the spinal canal could be seen. In only two of these cases did the roentgenologic findings suggest a ruptured disk. In all the rest of these cases it was thought advisable to perform a lumbosacral fusion anyway and exploration of the spinal canal was the first step in the fusion operation.

This paper was written in order to present a group of cases suffering from intractable sciatic pain without paralysis or outstanding neurologic signs. The results obtained in this series, leaving out those with frank compression of the cauda equina, are summarized in Table IV.

TABLE I

SEX AND AGE INCIDENCE

| | Cases | Per Cent | | |
|---|---|---|---|---|
| Female | 13 | 22.6 | Youngest | 20 |
| Male | 45 | 77.4 | Oldest | 53 |
| | | | Average | 37 |
| Totals | 58 | 100 | | |

TABLE II

LOCATION OF LESION

| | | |
|---|---|---|
| Disk between second and third lumbar vertebrae | 1 | |
| Disk between third and fourth lumbar vertebrae | 4 | |
| Disk between fourth and fifth lumbar vertebrae | 35 | 60% |
| Disk between fifth lumbar and first sacral vertebrae | 17 | 30% |
| Disk between first and second sacral vertebrae | 1 | |
| Total | 58 | |

TABLE III

RESULTS IN ALL CASES

| | |
|---|---|
| Well | 32 |
| Improved | 14 |
| Unimproved | 2 |
| Died, result of operation | 1 |
| Died, unimproved, urinary sepsis | 1 |
| Too recent to evaluate | 8 |
| Total | 58 |

TABLE IV

CASES OF SCIATIC PAIN WITH MINOR NEUROLOGIC SIGNS

| | | |
|---|---|---|
| Ruptured intervertebral Disk | | 48 |
| Well | 29 | |
| Improved | 10 | |
| Unimproved | 1 | |
| Too recent to evaluate | 8 | |
| Localized arachnoiditis | | 3 |
| Negative explorations | | 4 |
| Deaths | | 0 |
| Total | | 55 |

CONCLUSIONS

Rupture of a lumbar intervertebral disk into the spinal canal, particularly the fourth or fifth, is a definite cause of sciatic pain.

This is one of the few causes of sciatic pain in which compression of a nerve root can be demonstrated.

The diagnosis can be made with great accuracy.

The results of operative removal of the fragment are highly satisfactory.

## REFERENCES

[1] Mixter, W. J., and Barr, J. S.: Rupture of the Intervertebral Disc with Involvement of Spinal Canal. New England Jour. Med., **211**, 210–215, 1934.

[2] Mixter, W. J., and Ayer, J. B.: Herniation or Rupture of the Intervertebral Disc Into the Spinal Canal. New England Jour. Med., **213**, 385–393, 1935.

[3] Goldthwait, J. E.: The Lumbo-sacral Articulations; an Explanation of Many Cases of "Lumbago," "Sciatica" and Paraplegia. Boston Med. and Surg. Jour., **164**, 365–372, 1911.

[4] Middleton, G. S., and Teacher, J. H.: Injury of the Spinal Cord Due to Rupture of an Intervertebral Disc During Muscular Effort. Glasgow Med. Jour., **76**, 1–6, 1911.

[5] Dandy, W. E.: Loose Cartilage from Intervertebral Disc Simulating Tumor of Spinal Cord. Arch. Surg., **19**, 660–672, 1929.

[6] Schmorl, G.: Die gesunde und kranke Wirbelsaule im Rontgenbild: Pathologisch-anatomische Untersuchungen. Fortschr. a.d. Geb. d. Rontgenstrahlen, Erganzungsband **43**, Georg Thieme, Leipzig, 1932.

[7] Elsberg, C. A.: Diagnosis and Treatment of Surgical Diseases of the Spinal Cord and Membranes. W. B. Saunders Company, Philadelphia, 1916, p. 238.

[8] Stookey, B.: Compression of Spinal Cord Due to Ventral Extradural Cervical Chondromas; Diagnosis and Surgical Treatment. Arch. Neurol. and Psychiat., **20**, 275–291, 1928.

[9] Hampton, Aubrey O., and Robinson, J. Maurice: The Roentgenographic Demonstration of Rupture of the Intervertebral Disc Into the Spinal Canal After the Injection of Lipiodol. Amer. Jour. of Roent., **36**, 782–803, December, 1936.

[10] Love, J. G.: Protrusion of the Intervertebral Disc (Fibrocartilage) Into the Spinal Canal. Proceedings of the Staff Meetings of the Mayo Clinic. **11**, No. 34, August 19, 1936.

[11] Barr, Joseph S.: "Sciatica" Caused by Intervertebral Disc Lesions. A Report of Forty Cases of Rupture of the Intervertebral Disc Occurring in the Low Lumbar Spine and Causing Pressure on the Cauda Equina. Jour. Bone and Joint Surg., **19**, No. 2, 323–342, April, 1937.

DISCUSSION.—DR. HOWARD C. NAFFZIGER (San Francisco): Doctor Mixter deserves great credit for clarifying our ideas as to the cause, pathologic changes in and treatment of a considerable number of patients who suffer from low back pain and sciatica. Previous to Doctor Mixter's work, most neurologic surgeons probably had had the experience of operating occasionally for what had been diagnosed as an intraspinal neoplasm, and encountered instead a cartilaginous mass of one type or another. The underlying pathologic changes in these patients were not realized. Since Doctor Mixter called our attention to it, my associates and I have been greatly interested in the subject and have operated upon some 30 patients with this type of disturbance.

The material found and removed at operation is not pure cartilage, but fibrocartilage, usually stringy in appearance and much like chewed up chalk. The gradation of tissue between the nucleus pulposus and the annulus fibrosus is indefinite, and apparently circulatory changes in the intervertebral disk may occur at very early ages. Degenerative changes undoubtedly play an important part. Our patients have shown a little wider variation in age than Doctor Mixter's, the youngest being 18 and the oldest 63 years of age.

We have been greatly impressed that such a high percentage of the patients whom we have investigated for the cause of low back pain, or sciatica, or both, have proved to have organic changes—usually fibrocartilaginous of the disk, but sometimes alterations in the ligamentum flavum. In this group of patients with chronic severe symptoms, proved pathologic changes in the spinal canal

were found in more than one-half. I believe that we investigated no patients except those who had had prolonged treatment and, frequently, many recurrent attacks. Almost all of them had had strapping, manipulations, physiotherapy of various kinds, traction, casts, braces, *etc.*

The industrial aspects of patients in this group will have to be thought of shortly. Not all of the patients have a history of a single severe trauma; some have had repeated lesser trauma, as from riding horse back, jumping, *etc.* There is, in addition, still a question as to what proportion of patients, who have had a low laminectomy or hemilaminectomy, will require fixation of the spine by bone graft. Perhaps there will be a considerable number, but certainly not all of these patients will have persisting disability, even for heavy work.

In our experience, the clinical picture varies greatly. In some instances there has been complete compression of the dural sac with involvement of all fibers passing from the dura below that level. Commonly there has been some pain in the back, but sciatica has been the leading feature. Frequently there is evidence of involvement of the fourth or fifth lumbar root with subjective or objective sensory alteration over the outer side of the leg in its lower two-thirds and extending over on to the dorsum of the foot. Muscles supplied by the external popliteal nerve also frequently show weakness and occasionally there is a disproportionate weakness of one or another muscle in this group. Often the extensor proprius or the tibialis anticus may seem disproportionately weak by comparison with the other extensors. It is a matter of considerable interest that complete remissions in the signs and symptoms of back pain and sciatica may occur and yet, ultimately, rupture of the intervertebral disk is found.

At operation, the cartilage is usually in a lateral position, slightly anterior to one of the nerve roots. Often they can be felt more readily than seen. Occasionally they are found in bizarre places. I recall one case in which a large mass of fibrocartilaginous material had herniated around the lateral side of the dura and had come to lie immediately beneath the lamina where it compressed the dural canal. Continuation of this mass around the dura led one to the opening in the intervertebral disk from which it originated. In another recent instance, a cartilage had penetrated the ventral surface of the dura and had come to lie inside it as a pedunculated mass.

Even after the laminae are removed, it is not always easy to recognize immediately these small protrusions of cartilage—and very small ones indeed may compress a root sufficiently to give severe symptoms. I am sure that we should have missed a considerable number if extradural exploration, which was negative, had not been followed by wide opening of the dura with careful retraction of the filaments of the cauda equina and inspection of the inner surface. In a considerable number we have thus located the rounded protrusion pushing into the dura, and usually there are minute telangiectases altering the appearance of the dura at that spot. Frequently the nerve root is compressed and often it is considerably swollen. We have removed a number of these cartilages by the transdural route, which oftentimes is easier than the extradural removal and is less vascular.

In several instances in which disease or injury of the intervertebral disk was suspected, we found instead alterations—thickening or fibrosis—in the ligamenta flava. One of my associates, Doctor Brown, recently operated upon a patient who had a complete transverse obstruction of the dural canal from such a cause.

Complete blockage of the canal is, of course, infrequent and small herniations compressing the root may give severe symptoms without noticeably

affecting the flow of lipiodol as seen under the fluoroscope. Unless the roentgenograms are taken in such a direction as to bring the indentation of the column of lipiodol into profile, the condition may be missed. Repeated studies are not infrequently necessary. We feel greatly dependent upon the roentgenologist.

Doctor Mixter's work has reduced the number of patients who have been treated unsatisfactorily in the past for conditions vaguely considered as lumbosacral or sacro-iliac disorders and has made the pathologic changes clear in a large proportion of them. In most of these patients the diagnosis is not difficult and the treatment is highly satisfactory.

Dr. Kellogg Speed (Chicago): Among the last 100 patients I have seen with complaint of back, thigh and leg pain, well described by Doctor Mixter, practically all with the history of trauma, five have continued to complain in spite of palliative treatment extending in some instances over a period of three years. One patient had a trisacral fusion. None had compression or other fracture of the spine. Three of these five patients were given lipiodol spinal injection after puncture, and all showed defects in the roentgenogram suggesting cartilage protrusion.

No xanthochromia or increased pressure of spinal fluid was found. Protein content varied from 20.2 to 34.8 mg. Cell counts were low or zero, and sugar determinations varied from 65 to 75.6 mg. There were no neurologic findings of cord tumor.

My experiences after such a low percentage of persisting symptoms leads me to believe that these patients with back and "sciatic" pain should be offered ordinary nonoperative treatment, including correction of focal infections, and injections with normal salt solution into the sacral plexus, followed by wearing a back brace for a while before lipiodol is injected intradurally. This oil may never absorb, and probably should not be injected unless it is to be abstracted later by open operation. I evaluate lasting atrophy of the thigh muscles along with pain as an indication for lipiodol injection.

Disk injury, or protrusion, concomitant with compression fracture, but not necessarily at the same level, may account for many of the long standing instances of back pain after compression fracture of the body of the vertebra, although hyperextension of the spine and a chance to recover bony support may be given. Mechanical analysis of the ordinary compression injury of the spine by flexion or direct pressure of the superimposed body weight, however, does not seem to explain a posterior protrusion of the intervertebral disk at the fracture level at the time of the fracture. The possibility of the congenital nature of these protrusions must be kept in mind, whether into the corpus of the vertebra, or posteriorly into the spinal canal, later to be aggravated by trauma.

Most of these patients have flat lumbar areas, or even lumbar kyphosis of years' duration. When a displaced disk is roentgenologically proven, it should be removed and a spinal fusion covering the defect caused by the operative approach for the removal and at least one segment of the spine above and below must be included.

Dr. William Jason Mixter (Boston), closing: Doctor Speed has spoken of his fear of the use of lipiodol. I also feel definite hesitation in using it, unless the indications seem clear. I believe that if these patients do not recover under palliative orthopedic treatment, the use of lipiodol is indicated. I have seen no permanent bad results from the use of lipiodol; there have been some cases of neuralgic pain reported following its use, but I do not think they are common.

It seems to me that the lesion of which we are speaking this morning is seldom associated with fracture of the vertebra, and that probably the cause is a different kind of trauma than that which causes a compression fracture of the vertebra.

I like to theorize that it may be a direct pushing together of the two vertebral bodies rather than a bending crush. Some of our histories have pointed to that.

Fusion, I think, should be used in most of the industrial cases, because we are expecting to return them to heavy work. I think most patients who do not work hard can probably get along perfectly well without fusion.

The lateral view is of very little value, as Doctor Speed has said. Remember that the fifth root is compressed by the fourth disk, not the fourth root by the fourth disk. Always open the dura if you cannot find the mass outside.