

EXPERIMENTAL LYMPHEDEMA OF THE INTESTINAL TRACT AND ITS RELATION TO REGIONAL CICATRIZING ENTERITIS*

FREDERICK LEET REICHERT, M.D. AND MARY E. MATHES, M.D.

SAN FRANCISCO, CALIF.

FROM THE LABORATORY OF EXPERIMENTAL SURGERY, STANFORD UNIVERSITY SCHOOL OF MEDICINE,
SAN FRANCISCO, CALIF.

THE anatomic, physiologic and embryologic studies of the lymphatics during the past 300 years have firmly established them as a definite part of the vascular system. The clinical importance of this system of vessels and nodes has only recently been realized as new methods have been developed for the study of its physiologic functions and pathologic alterations.

Investigators learned, as had been ascertained previously for the blood vascular system, that the lymphatics grew into new tissues, that they regenerated and developed a collateral circulation, that they became inflamed, sclerosed and thrombosed. Recently it was found that lymphatics could be obliterated in an extremity resulting in a chronic lymphedema or elephantiasis. This same method may be applied to the lymphatics of other parts of the body and to various organs. We became interested in the effect of obliteration of the intestinal lymphatics in localized portions of the bowel after observing somewhat unusual lesions in clinical cases in which the appearance of the bowel, after the possibility of malignancy was eliminated, suggested a chronic lymphatic obstruction.

Resected bowel from three such cases, seen on the surgical service, was classified as cicatrizing regional enteritis and its pathologic study revealed a marked edema and fibrosis of the wall and engorgement of the lymphatics. We felt this picture resembled in many details that of chronic lymphedema or elephantiasis, as seen in the extremities. The two dominant features of the intestinal lesion seemed to be a low grade chronic infection with a concomitant chronic lymphatic obstruction and edema.

Fortunately for us the work of Drinker, Fields and Homans¹ on the experimental production of lymphedema and elephantiasis in the limb of dogs had been just published. Some years ago one of us,² at the suggestion of the late Professor Halsted, had attempted to produce elephantiasis in animals but the work reported by Homans, Drinker and Fields³ presented a satisfactory experimental method of obtaining chronic lymphedema which we have applied in the study of this condition in the intestinal tract of dogs.

METHOD.—Drinker and Fields developed an elaborate method of tying a fine quartz cannula into the lymphatic vessel through which a 2½ per cent solution of quinine hydrochloride combined with a suspension of crystalline silica dust was slowly injected. By repeated injections of the irritating and

* Aided by a grant from the Fluid Research Fund of the Rockefeller Foundation.

sclerosing materials the lymphatic vessels and nodes were injured and became obliterated by a fibrosis, producing the condition of chronic lymphedema.

During previous experimental work on the lymphatics,⁴ under Doctor Sabin, a technic for lymphatic injection was developed, using fine hypodermic needles, gauge 27 and 28, attached to a tuberculin syringe. We found this method well adapted for the direct injection of the mesenteric lymphatics as well as of the subserosal lymphatics of the bowel, without interfering in any way with the intestinal blood vascular network, thereby allowing the study of the isolated effect of lymphatic occlusion in the intestinal tract and the end-results of lymphatic fibrosis produced by irritating and sclerosing materials. Adjacent bowel with undisturbed lymphatic drainage to uninvolved lymph nodes was used as a control in these studies.

The material used for lymphatic injections included crystalline silica (200) mesh, Hill's bismuth oxychloride mass, as modified by Poth⁵ for lymphatic injection, rose aniline dye in the form of indelible lead, or sodium morrhuate added to the bismuth mass as a sclerosing material. In some instances appendiceal contents were added to the bismuth mixtures before injection and in others a suspension from 24 hour broth culture of *B. coli* was given intravenously one to three hours before the lymphatic injections. One, two or three reinjections were made in a number of animals at intervals from several weeks to months after the preceding treatment.

Subserosal lymphatic injections in the stomach and pylorus were difficult to effect, but subserosal and mesenteric lymphatics could be injected readily in the duodenum, distal ileum and proximal large bowel. The mesenteric lymphatic vessels of the ileum were filled easily and, at times, these were the only injections made at the first operation, with mesenteric and subserosal injections made at subsequent explorations (Fig. 1). The present report will be confined to the results of lymphatic obstruction in the ileum and colon.

A paralysis or dilatation of the intestinal lymphatics was noted when intravenous bacteria had been given an hour before operation, and the lymphatic dilatation was particularly remarkable in three animals made sensitive to foreign protein by seven intravenous injections of horse serum during the previous six weeks. In these animals a final injection of serum was given just before operation. Evidence of anaphylactic shock was apparent by the cold skin and the cold intestines, which were pale, relaxed and showed no peristalsis on irritation. The arteries and veins were contracted, but the lymphatics and lacteals were found to be dilated or paralyzed, were easily injected and appeared as large vessels in the mesentery, subserosa and between the muscle layers.

The experiments were concluded by sacrificing the animals under ether anesthesia. The most satisfactory procedure for fixation was to remove the whole gastro-intestinal tract, to separate any adhesions or matted loops of bowel under warm saline and then to fill partially the lumen with warm saline. When all of the intestines were completely relaxed they were quickly put into formalin, thus insuring simultaneous contraction and fixation of all

parts of the tract. Areas of the treated and normal bowel were excised later for microscopic study.

EXPERIMENTAL RESULTS.—No free peritoneal fluid was ever seen upon opening the abdomen for subsequent reinjection, or when the animal was sacrificed, but adhesions about the injected mesentery and between the omentum and loops of treated bowel were encountered frequently. The treated

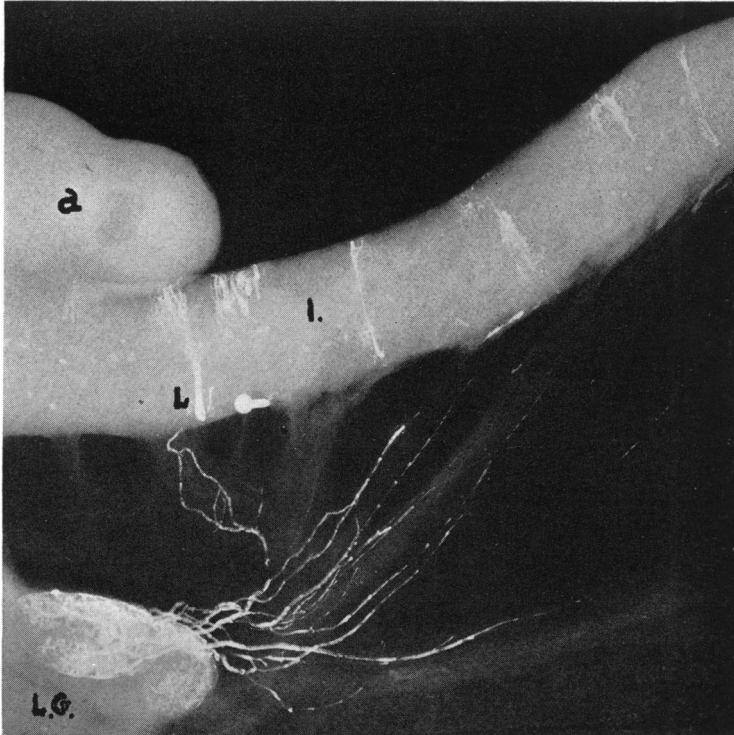


FIG. 1.—Roentgenogram of normal ileum and mesentery in which the lymphatics were injected directly with bismuth oxychloride (26 per cent) in an acute experiment. (a) Tip of appendix. (I) Ileum. (L.G.) Regional lymph node filled partially with bismuth from mesenteric lymphatic and subserosal lymphatic injections. (L) Lacteal filled from subserosal injection.

segment felt thickened, and some of the mesenteric lymphatics were dilated while others were sclerosed. The regional lymph nodes were enlarged and firm, and the involved mesentery frequently scarred. In only one animal did the injections fail to produce chronic pathologic changes persisting for months to a year.

Specimens were studied from 19 dogs in which there were intestinal lymphatic injections. Bismuth oxychloride (26 per cent) alone was used in three injections, bismuth oxychloride and sodium morrhuate (5 per cent), equal parts, were used in 15 injections, while the mixture of bismuth and rose aniline dye was employed seven times. Silica and rose aniline dye were used only twice because the silica interfered with the smooth movement of the plunger of the syringe. Bacteria mixed with the bismuth and rose aniline

dye were used twice, and intravenous injections of *B. coli*, followed in one to three hours by lymphatic injections with bismuth and the dye or sodium morrhuate, were used four times.

ACUTE LYMPHEDEMA.—Six animals died or were sacrificed at intervals

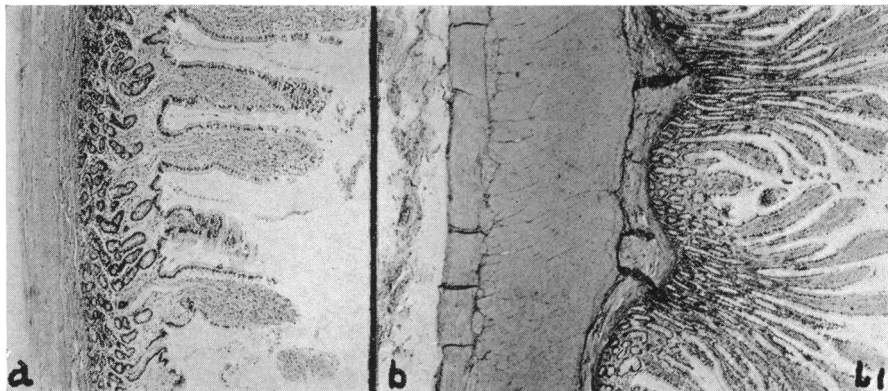


FIG. 2.—L 1. Four and one-half week specimen. (a) Normal ileum ($\times 34$). (b) Ileum ($\times 34$), mesenteric lymphatics injected with bismuth oxychloride, showing muscle layers edematous and thickened four to five times more than normal. Lacteals engorged. Submucosa thickened and infiltrated.

from a few days to two weeks. The histologic picture varied with the length of survival. The thickened bowel wall showed inflammation and thickening of the serosa and edema of the circular and longitudinal muscles, with the lacteals in the intermuscular septum distended with fluid and lymphocytes.

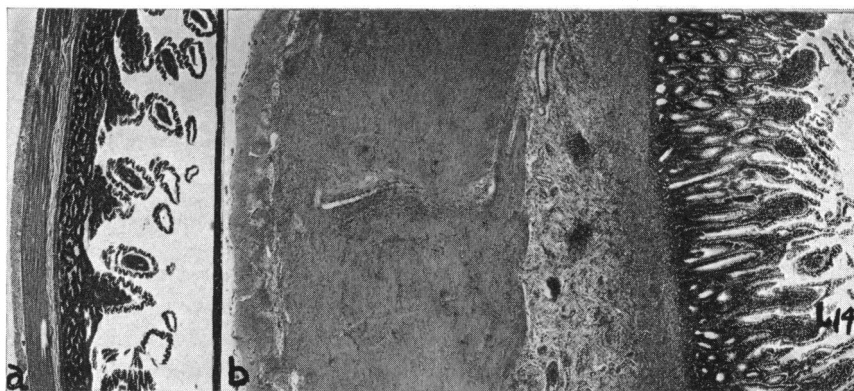


FIG. 3.—L 14. Nine and one-half week specimen. (a) Normal ileum ($\times 20$). (b) Ileum ($\times 20$). Intravenous injection of *B. coli*, followed in three hours by mesenteric and subserosal ileac lymphatic injections of bismuth and rose aniline dye. Inner circular and outer longitudinal muscles edematous and eight times normal thickness. Lacteals engorged and thrombosed. Submucosa greatly infiltrated, 15 times normal thickness.

The submucosa was swollen and infiltrated with leukocytes and its lymphatics were engorged with cells. The mucosa seemed a little swollen but there were no ulcerations.

Between two and four weeks after injection the lymphatics were noticeably

filled with very large pale cells containing large pale nuclei, and the vessels seemed thrombosed and sclerosed, so that a chronic stage had developed.

CHRONIC LYMPHEDEMA.—In 13 animals the lymphatic injections had been

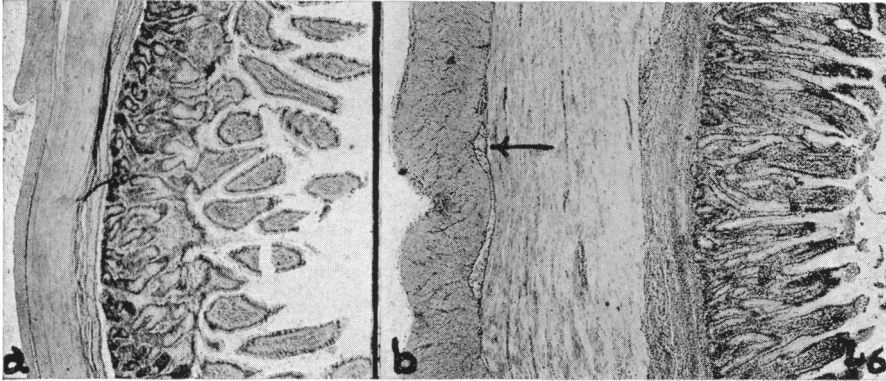


FIG. 4.—L 6. Twelve month specimen. (a) Normal ileum ($\times 18$). (b) Ileum ($\times 18$). Twelve and ten months previously, ileal mesenteric and subserosal lymphatics injected with equal parts of 26 per cent bismuth oxychloride and 5 per cent sodium morrhuate. Serosa thickened and infiltrated. Muscles edematous and four times normal thickness. Arrow indicates an engorged and thrombosed lacteal (Fig. 5). Submucosa thickened by edema, lymphocytic infiltration and fibroblasts. Lymphatics engorged and thrombosed.

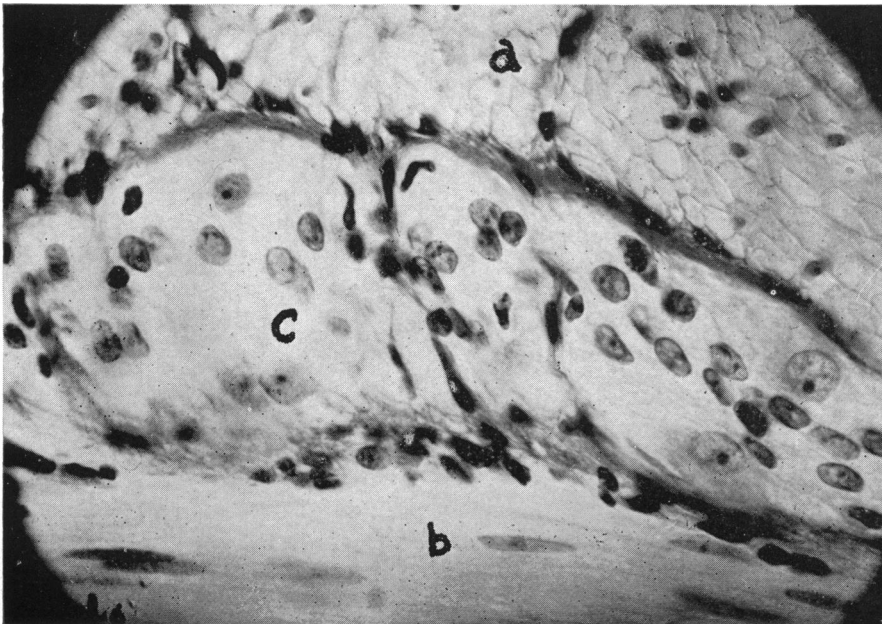


FIG. 5.—L 6. High power ($\times 650$), of intermuscular thrombosed lacteal (c), engorged with large pale mononuclear cells. The adjacent outer longitudinal (a) and inner circular (b) muscles are pale and edematous.

made one month or longer before death and all except one showed definite gross and microscopic alterations in the involved bowel. Of the 12 dogs that had developed a chronic lymphedema three were injected only once, six

were injected twice, two were injected three times and one was injected four times. Yet all had the same characteristic histologic changes.

That chronic pathologic changes which persisted, without subsidence, for months should develop after even a single injection of irritating and sclerosing substances into the intestinal lymphatics was striking and unexpected.

The main differences between the acute and the chronic changes following the injections were found to be in the lymphatics and in the submucosal and muscular layers. With subsidence of the acute phase the signs of inflammation disappeared, and only round cells and lymphocytes were to be seen. The edema of the tissues persisted, since the submucosal lymphatics and the lacteals lying between the muscular layers had been obliterated by sclerosis or thrombosis, and were now filled with firm trabeculations and packed with very large, pale cells containing large, lightly staining nuclei (Fig. 5). The greatest change was a thickening of the longitudinal and circular muscles and

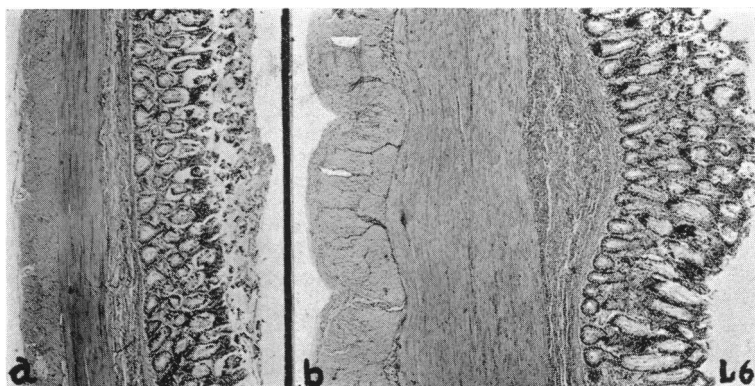


FIG. 6.—L 6. Twelve month specimen. (a) Normal colon ($\times 24$). (b) Colon ($\times 24$). Twelve and ten months previously subserosal lymphatics injected with equal parts of 26 per cent bismuth oxychloride and 5 per cent sodium morrhuate. Serosa thickened and fibrinous. Muscles edematous and two to three times normal thickness, with lacteals engorged and thrombosed. Submucosa thickened, infiltrated and fibrosed.

in the submucosa, these being two to eight times thicker than normal; and due to the chronic edema present the muscle fibers were found to be swollen and indistinct (Figs. 2, 3, 4, 5 and 6). Edema, fibrin and fibrosis persisted in the submucosa, and usually the serosa was somewhat thickened (Figs. 4 and 6). No ulcerations of the mucosa were seen.

These pathologic changes were seen in all the 12 specimens, and no appreciable differences were found following injections of bismuth in conjunction with sodium morrhuate (Figs. 4, 5 and 6) or rose aniline dye, and of silica in conjunction with the aniline dye. Bismuth alone (Fig. 2) produced definite alterations, but the most marked chronic lymphedema occurred when *B. coli* was given intravenously shortly before the lymphatic injections of bismuth and rose aniline dye (Fig. 3).

The end-result of sclerosing and obliterating the lymphatics to a segment of intestine was to produce a bowel thickened from chronic lymph stasis with the lymphedema most marked in the submucosal and muscular layers. This

characteristic pathologic picture (Figs. 2, 3, 4 and 6) was found in 12 specimens, although the number of injections ranged from one to four, although several different sclerosing materials had been used and although one to ten months had elapsed between the injections and the autopsy.

PROTOCOLS

Since the number and location of the lymphatic injections, the substances used for lymphatic sclerosis, and the gross pathologic observations at reoperation or autopsy have been summarized, it will not be necessary to give the details in all of the experiments. The reports of three experiments, with photomicrographs, are presented briefly to illustrate the findings in chronic lymphedema of the ileum and colon.

L-1.—On October 24, 1934, the mesenteric lymphatics were directly injected close to the ileum with 26 per cent bismuth oxychloride. The white bismuth filled these lymphatics and finally filled the regional lymph node, draining about 12 to 15 inches of the terminal ileum. No subserosal lymphatic injection was made.

November 11, 1934. Three weeks later an exploration was made. The ileum was bound down by adhesions, and the injected lymph node was quite large. One distended ileac mesenteric lymphatic was reinjected.

On November 26, 1934, four and one-half weeks after the first injection, the dog was sacrificed. No free fluid or distended loops of bowel were seen. A large mass of matted loops of small bowel in the cecal region with shortened and thickened mesentery was dissected free. A large ileal lymph node was surrounded by fibrous adhesions. The intestinal tract was partially distended and fixed in formalin for one hour, then incised longitudinally at the antimesenteric border and wrapped loosely on a plate of glass for further fixation. The terminal six inches of ileum were thickened but no mucosal ulcerations were seen.

Microscopic Findings.—The section from the injected ileum (Fig. 2 b) showed the serosa very thick and infiltrated.

The inner circular and outer longitudinal muscles were four to five times thicker than the normal ileum (Fig. 2 a) and were edematous, with slight round cell infiltration and with the lacteals engorged with so called plasma cells and very large, pale cells. The submucosa was thickened and infiltrated with engorged lymphatics. The mucosa was intact.

L-14.—On August 1, 1935, at 12:30 P.M., three-fourths of a cubic centimeter of a 24 hour broth culture of *B. coli* was given intravenously. At 2:30 P.M., five ileal mesenteric lymphatics were injected with bismuth oxychloride, which was colored a deep purple by adding a piece of indelible lead (rose aniline dye). Four subserosal lymphatics were injected in the ileum, two in the appendix and one in the proximal colon three inches from the ileocecal valve.

On October 7, 1935, nine and one-half weeks after injection, the animal was sacrificed. No free fluid or adhesions were seen. Definite thickening of the terminal ileum was felt. The intestinal tract was removed, partially filled with warm saline and, when entirely relaxed, put into formalin.

Microscopic Findings.—Section of the injected ileum (Fig. 3 b) showed the serosa edematous and slightly infiltrated. The muscles, especially the inner circular, were markedly thickened to eight times that of the normal ileum (Fig. 3 a) and showed edema and slight round cell infiltration with engorged and thrombosed lacteals. The submucosa was greatly infiltrated with dense areas of round cells and engorged lymphatics, and was 15 times thicker than in the control section. The mucosa was intact. The nor-

mal ileum (Fig. 3 a) showed a single layer of serosal cells with the muscle fibers distinct and the lacteals containing only lymph. In the submucosa the lymphatics were small.

L-6.—On December 13, 1934, the distal 12 inches of the ileal mesentery had the lymphatics injected, and four subserosal ileal lymphatics were also injected with equal parts of bismuth oxychloride (26 per cent) and sodium morrhuate (5 per cent). Subserosal lymphatic injections were also made on the proximal three inches of large bowel.

On January 28, 1935, six and one-half weeks later, reinjection of lymphatics was done. Only a few omental adhesions were seen. The ileum was thickened. Many subserosal lymphatics in the distal ten inches of ileum were readily injected and filled the deeper enlarged lacteals. The colon was thickened. Three subserosal lymphatics in the proximal colon were injected.

On November 7, 1935, nearly 12 months after the first, and ten months after the second injection, the animal was sacrificed. After mesenteric adhesions of the ileum were divided, definite thickening of ileum, appendix and proximal colon was felt.

Microscopic Findings.—In the sections of the injected ileum (Fig. 4 b), the serosa was thickened and contained dilated, thrombosed lymphatics. The inner circular muscle was edematous with the muscle fibers swollen and lacking detail (Fig. 5 b). Some wandering cells were seen. The longitudinal muscle showed the same edematous condition (Fig. 5 a). The muscle layers were four times thicker than in the normal ileum. Engorged lacteals (arrow in Fig. 4, and Fig. 5 c) were filled with large pale cells and showed thrombosis and, in some areas, cannulization. In the submucosa some round cell infiltration was seen just beneath the mucosa and there were frequent fibrin deposits and marked fibrosis causing this layer to be twice as thick as in the section of normal ileum (Fig. 4 a). Engorged and thrombosed lymphatics were numerous. The mucosa was intact. The section of the normal ileum (Fig. 4 a) showed the muscle fibers to be sharp and distended. The lacteals were not thrombosed, and they contained an occasional large pale cell. The serosa was composed of a single layer of cells.

In the section of the injected colon (Fig. 6 b) the findings were similar to those in the ileum with the serosa thickened and fibrinous. The muscles were two to three times thicker than normal, and were edematous. The lacteals were engorged and thrombosed. The submucosa was thickened, infiltrated and fibrosed. Five or six layers of lymphocytes were seen beneath the musoca, instead of two or three layers in the normal colon (Fig. 6 a).

REGIONAL CICATRIZING ENTERITIS.—In these experiments the constant pathologic changes, grossly and microscopically, that became chronic and persisted for months after regional sclerosis and obstruction of the intestinal lymphatics to a portion of the ileum or colon, resembled in many respects the pathologic picture in clinical cases of regional cicatrizing enteritis. Many recent reports of cases showing this clinical entity have been published so that the symptoms, signs, and diagnosis of this disease need not be considered in this paper, although a short description of the pathologic findings obtained from the literature and studied in three of our clinical cases will be given.

When Crohn, Ginzburg and Oppenheimer,⁶ in 1932, separated a subgroup from the benign, nonspecific granulomata and described regional enteritis as a pathologic and clinical entity, they stated that the etiology of the process was obscure. They felt that this disease of the terminal ileum was characterized by a subacute or chronic necrotizing and cicatrizing inflammation of all the coats of the ileum, which frequently led to stenosis of the lumen and was often associated later with fistulous formation and a palpable tumor in the right lower quadrant.

ETIOLOGY.—In the Stanford clinic, in September, 1933,⁷ a unique and original observation was made in a case of presumed regional ileitis in a child aged six, all previous observations having been made in adults. In this patient, the lesion was completely excised, including the terminal ileum and four inches of the cecum. The mucosa of the ileum, appendix and colon was everywhere intact but characterized by an extensive diffuse edema which involved also the mesentery and regional lymph nodes. An extensive fibrosis accompanied this edema producing the localized mass. It was inferred from these observations in a child that the process was primarily a lymphadenitis and that ulceration of the mucosa, when present, was secondary to the lymphatic obstruction and infection.

Bell,⁸ in 1934, reported that he was unable, by interference with the blood supply of the intestinal tract in animals, to produce a cicatrizing enteritis, ulceration of the mucosa or any lesion simulating this condition, and concluded that the pathologic process in this disease was not one of inadequate blood supply. Bell raised the question whether the etiologic factor was infection in the mucosa spreading to the intestinal wall with edema of the mesentery from inadequate lymphatic drainage, or whether it was an infection starting in the lymphatics as a lymphangitis, and extending to the wall of the bowel.

Bockus and Lee⁹ stated that any primary inflammatory mucosal disease in the terminal ileum might in the end resemble the entity of regional ileitis. Ginzburg and Oppenheimer,¹⁰ for instance, suggested a disturbance in the vascular mechanism, as found in self-reducing intussusception or recurrent partial volvulus, as a possible rôle in this disease, and Homans and Haas,¹¹ Erb and Farmer,¹² and others suggest primary appendiceal disease as an etiologic agent with secondary involvement of the mesentery and, finally, the terminal ileum. Bockus and Lee⁹ conceive the possibility of a lymphangitis and surrounding inflammation which might encroach upon or infect the blood supply, producing a slow devitalization of the terminal segment of ileum, resulting in terminal ileitis. Felsen¹³ offers evidence that a great majority of cases of chronic, nonspecific, ulcerative colitis and ileitis, and nonspecific granuloma are the chronic stages of acute bacillary dysentery.

Clinical Pathologic Reports.—The description of the clinical entity involving the terminal ileum was made in 1932, but subsequent reports have been made of similar pathologic conditions which involve the jejunum, ileum, cecum and colon, so that the term chronic cicatrizing enteritis, as suggested by Harris, Bell and Brunn,¹⁴ is more comprehensive.

Crohn and his associates studied specimens obtained from patients who had been ill for at least a year. Ulceration of the mucosa with blunting of the villi from edema, marked inflammatory, hyperplastic and exudative changes in the submucosal and muscular layers, and thickened, fibrotic serosa produced an enormously thickened intestinal wall which encroached upon the lumen. The mesentery was greatly thickened and fibrotic. Histologically, various degrees of acute, subacute and chronic inflammation were shown by

the presence of polymorphonuclear, round cell, plasma cell and fibroblastic elements. In some cases the presence of giant cells was striking. Near them were inclusion vegetable cells which had apparently resulted in the formation of the giant cells. After careful study they found no evidence of tuberculosis, syphilis, actinomycosis, Hodgkins' disease or lymphosarcoma.

An important contribution to the clinical study of this disease was the presentation of an early stage as reported by Erb and Farmer,¹² who gave an account of four children with acute ileocolitis simulating appendicitis and characterized by edema of the ileocecal region and mesenteric nodes. They felt that the disease they described was closely related to regional ileitis, or chronic cicatrizing enteritis or benign granuloma of the intestines. The pathologic finding in their fourth case—of a child two and one-half years old, ill for six days—was almost identical with the findings observed in the acute cases described by Crohn¹⁵ where the terminal ileum was found to be thickened, soggy, and edematous, the serosa a blotchy red and the mesentery greatly thickened and containing numerous hyperplastic nodes. Histologically the mucosa was ulcerated and covered with a thick layer of exudate. The lymphoid tissue had undergone marked necrosis. Extensive fibrin formation was seen, and many large mononuclear cells interpreted as endothelial leukocytes were present in the intestinal wall. They noted a sparsity of polymorphonuclear cells. The edema led to a marked increase in thickness of the bowel wall and involved the muscular layers and particularly the submucosa.

CASE REPORTS

Case 1.—It was this specimen of chronic ileitis (Fig. 7) resected by Dr. G. Nagel from a man (E. D.), aged 27, that suggested to us a picture resembling chronic lymphedema and led to the experimental production of chronic intestinal lymphedema herein reported. In the photograph a match stick indicates the sinus from the cecum that had persisted for two years subsequent to an appendectomy.

The greatly thickened terminal ileum when cut showed the serosa thickened by areolar and fibrous tissue which had a heavy perivascular infiltration of round cells (Fig. 8). The muscles were greatly thickened, edematous and the inner circular muscle layer was heavily infiltrated with fibroblast and round cells adjacent to the submucosa, which likewise showed marked fibrosis and infiltration. The thrombosed lacteals were engorged with the large pale cells and the submucosal lymphatics were thrombosed and distended with the same large mononuclear cells. The mucosa was ulcerated in places, and elsewhere it was heavily infiltrated with lymphocytes, and leukocytes. Lymphoid tissue and clusters of lymphocytes were frequently seen beneath the mucosa and the serosa.

Case 2.—In Holman's⁷ discussion of Bell's⁸ paper, he reported the boy, aged six (C. L.), who had symptoms of appendicitis for only one day, but in the preceding two years had had occasional abdominal pain. At operation the expected appendiceal abscess was found to be a firm mass, involving the terminal ileum, cecum and base of the appendix which was resected. The mesentery was short and thick, and had enlarged lymph nodes.

Our pathologic study of the tissue showed the terminal ileum and appendix to be edematous and thickened with the ileal mucosa studded with lymphoid masses and numerous petechial hemorrhages but no ulceration. The submucosa was thickened and showed thrombosed lymphatics and scattered round cell infiltration. The muscle layers

were greatly thickened and distorted, showed moderate lymphocytic infiltration and their edematous condition was seen by the indistinct outlines of the muscle fibers (Fig. 91). The lacteals were engorged with large pale cells which some writers have described as

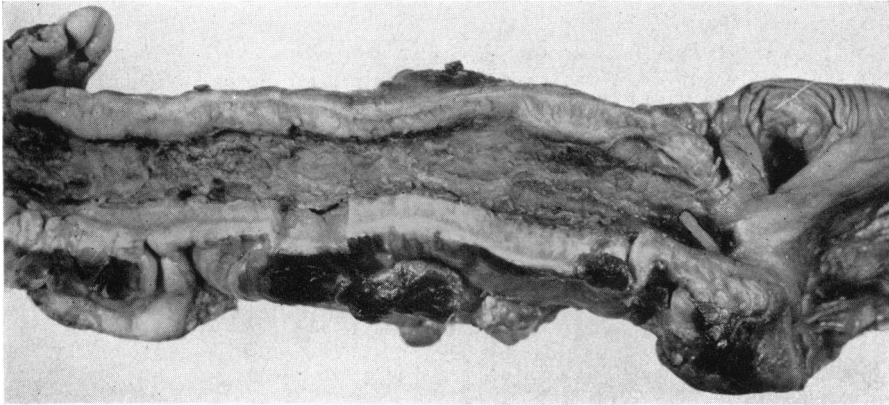


FIG. 7.—Case 1. ($\times\frac{1}{2}$.) Specimen of chronic ileitis showing ulcerations of mucosa and greatly thickened and edematous wall. Match stick indicates sinus from cecum persisting after appendectomy.

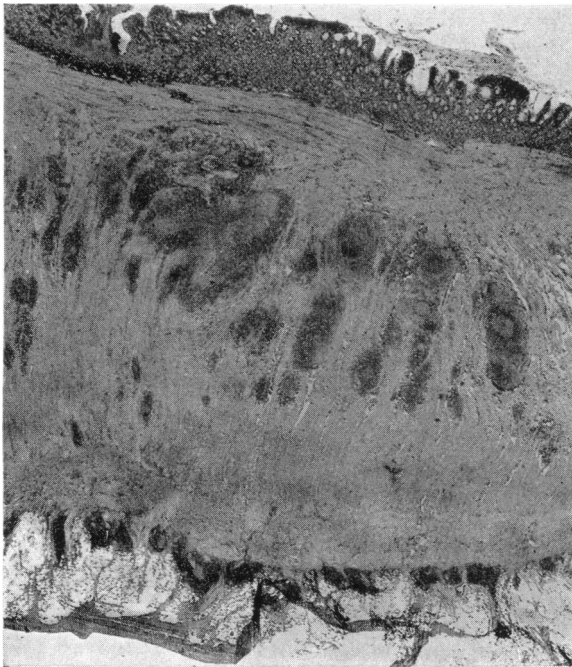


FIG. 8.—Case 1. ($\times 7$.) Serosa thickened by areolar and fibrous tissue. Muscles greatly thickened by edema and inner circular layer heavily infiltrated with fibroblasts and clusters of lymphocytes. Lacteals and submucosal lymphatics thrombosed and engorged with large pale mononuclear cells.

large mononuclear cells without identifying their location in lymphatic vessels. The serosa was thickened, fibrinous, and infiltrated with round cells.

Case 3.—A man (M. P.), aged 40, suffered a severe blow on the abdomen from

the steering wheel of his automobile. Two weeks later occasional severe abdominal cramps developed, frequently associated with vomiting and diarrhea. Two months later the cramps were occurring day and night and, on admission, visible peristaltic waves were seen, and a mass in the left lower quadrant was felt. On operation for intestinal obstruction, one of us (F. L. R.) found an area of ileum, which had apparently been traumatized at the time of the accident, bound down by fibrinous adhesions and kinked. Proximally the small bowel was hypertrophied for a short distance, so that some 12 inches were resected. The mesentery was very short, boggy and thick, and at one point in its root a small mass of dark colored material, either fecal material or old unabsorbed blood pigment, was found.

Pathologic study of the resected ileum showed the mucosa to be intact (Fig. 9p) with a heavy lymphocyte infiltration at its base extending into the submucosa which was greatly thickened and edematous, with fibrin deposits, clusters of lymphocytes and

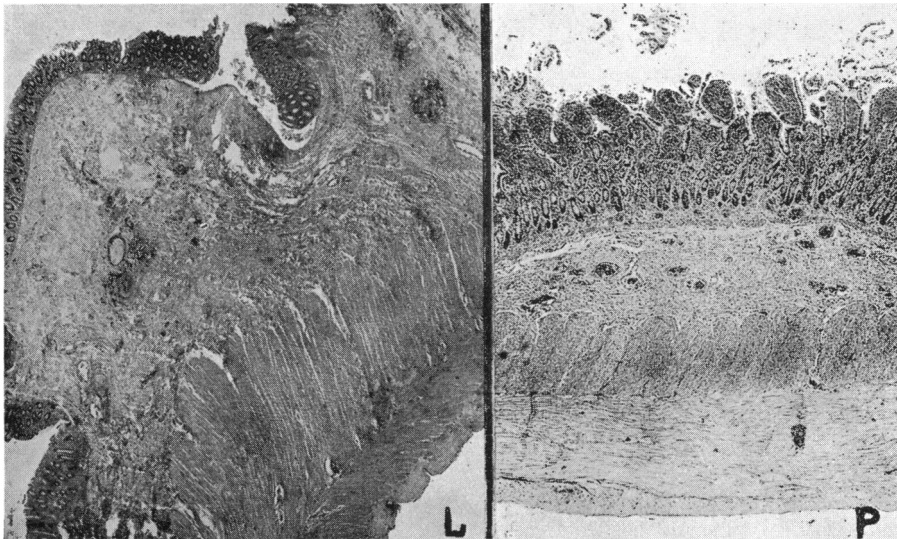


FIG. 9.—Case 2. L ($\times 12$). Chronic ileitis. Submucosa edematous and infiltrated with lymphocytes. Muscle layers greatly thickened and distorted with edema. Moderate lymphocytic infiltration. Serosa fibrinous and infiltrated with round cells. Lacteals engorged and many submucosal lymphatics thrombosed. Case 3. P ($\times 20$). Chronic ileitis. Submucosa greatly thickened and edematous, with clusters of lymphocytes and with engorged and thrombosed lymphatics. Muscles thickened and edematous. Lacteals engorged, with many thrombosed.

engorged and thrombosed lymphatic vessels. The muscles were quite edematous and thickened with infiltration by round cells and lymphoid tissue. The engorged lacteals between the muscle layers were prominent and many were thrombosed. The serosa was thickened by a heavy infiltrated fibrinous coat.

DISCUSSION.—From a careful gross and microscopic study of the specimens of regional enteritis and the specimens of chronic intestinal lymphedema produced experimentally, a definite and close similarity was seen. Although the pathologic changes were more pronounced in the human cases, yet, in both the clinical material and in the material experimentally produced by chronic lymphatic obstruction, the resemblance was marked in the pathologic alterations seen in the submucosal and muscular layers and in their lymphatic

vessels. No such resemblance had been obtained by Bell⁸ when he interfered with the blood supply of the intestinal tract in animals.

In our experiments the sclerosing material was injected only into lymphatics, and we feel that the pathologic changes resulting from such injections were due entirely to the lymphatic sclerosis and obstruction, since we found no evidence of blood vascular thrombosis in the microscopic sections.

The appearance of the gross specimens of regional enteritis and of experimental intestinal lymphedema, although varying in the degree of involvement, show the same thickened, edematous walls and microscopically greatly thickened muscular and submucosal layers which are edematous and have engorged and thrombosed lymphatics and lacteals.

The more extensive stenosis and mucosal ulceration seen in the human specimens might be attributed to the persistence of a chronic low grade bacterial infection. Our greatest thickening of the intestinal wall (Fig. 3) was secured when bacteria had been given intravenously shortly before the lymphatic injection.

It was surprising to find that months after such a lymphatic obstruction, although the animals appeared healthy, the pathologic alterations should persist and show no evidence of subsidence. Some of the animals, however, were sacrificed because of emaciation, or signs of obstruction due to the thickening of the injected bowel, or to adhesions kinking the bowel.

The surgical treatment of regional enteritis by resection of the involved portion of bowel is rational, since in the animal with chronic lymphedema, but without evidence of chronic infection, the pathologic alterations are apparently permanent.

SUMMARY.—Chronic lymphedema was experimentally produced in various regions of the gastro-intestinal tract.

This present report deals only with chronic lymphedema of the ileum and colon which was secured by injections into the mesenteric and subserosal lymphatic vessels of irritating and sclerosing materials.

Such lymphatic injections produced sclerosis and thrombosis of the lymphatics, which led to a chronic lymphedema.

Chronic intestinal lymphedema was secured by one injection, or by repeated injections.

Thickening and edema of the intestinal wall occurred and were most marked in the submucosal and muscular layers where the thrombosed lymphatics and lacteals were engorged with large pale mononuclear cells.

The injection of bacteria intravenously in conjunction with lymphatic injections produced the greatest thickening of the intestinal wall.

Intestinal lymphedema was found to persist for ten months without any evidence of subsidence and the pathologic changes appeared to be permanent.

In regional cicatrizing enteritis the thickening and edema were most marked in the submucosal and muscular layers, where engorged and thrombosed lymphatics and lacteals were found.

We believe that there is a close resemblance in the pathologic changes

seen in chronic regional enteritis and in experimental intestinal lymphedema.

The more extensive stenosis and mucosal ulceration in regional enteritis might be attributed to the persistence of a chronic low grade bacterial infection.

The two dominant features of regional cicatrizing enteritis seemed to be a low grade chronic infection with a concomitant chronic lymphedema.

The surgical treatment of chronic regional enteritis by resection has a rational basis, since experimental chronic lymphedema of the ileum and colon apparently is a permanent pathologic alteration.

REFERENCES

- ¹ Drinker, C. K., Fields, M. E., and Homans, John: The Experimental Production of Edema and Elephantiasis as a Result of Lymphatic Obstruction. *Am. Jour. Physiol.*, **108**, 509, June, 1934.
- ² Reichert, F. L.: The Recognition of Elephantiasis and Elephantoid Conditions by Soft Tissue Roentgenograms with a Report on the Problem of Experimental Lymphedema. *Arch. Surg.*, **20**, 543, April, 1930.
- ³ Homans, J., Drinker, C. K., and Fields, M.: Elephantiasis and the Clinical Implications of Its Experimental Reproduction in Animals. *ANNALS OF SURGERY*, **100**, 812, October, 1934.
- ⁴ Reichert, F. L.: On the Fate of the Primary Lymph-sacs in the Abdominal Region of the Pig, and the Development of Lymph Channels in the Abdominal and Pelvic Regions. *Contrib. to Embryol. No. 58*, 1921, Carnegie Inst. of Wash, **276**, 17.
- ⁵ Poth, E. J.: A Modification of Hill's Radiopaque Mass for the Injection of Lumina. *Jour. Lab. and Clin. Med.*, **19**, 1241, August, 1934.
- ⁶ Crohn, B. B., Ginzburg, L., and Oppenheimer, G. D.: Regional Ileitis—A Pathologic and Clinical Entity. *Jour. Am. Med. Assn.*, **99**, 1323, October 15, 1932.
- ⁷ Holman, E.: Discussion of Bell, H. G. *Calif. and West. Med.*, **41**, 239, October, 1934.
- ⁸ Bell, H. G.: Chronic Cicatrizing Enteritis. *Calif. and West. Med.*, **41**, 239, October, 1934.
- ⁹ Bockus, H. L., and Lee, W. E.: Regional (Terminal) Ileitis. *ANNALS OF SURGERY*, **102**, 412, September, 1935.
- ¹⁰ Ginzburg, L., and Oppenheimer, G. D.: Non-specific Granulomata of the Intestines. *ANNALS OF SURGERY*, **98**, 1046, December, 1933.
- ¹¹ Homans, J., and Haas, G. M.: Regional Ileitis: A Clinical, Not a Pathological Entity. *New England Jour. Med.*, **209**, 1315, December, 1933.
- ¹² Erb, I. H., and Farmer, A. W.: Ileocolitis: Acute Ileocolitis Simulating Appendicitis and Characterized by Edema of the Ileocecal Region and Mesenteric Glands; Its Relation to Regional Ileitis or Chronic Cicatrizing Enteritis. *Surg., Gynec. and Obst.*, **61**, 6, July, 1935.
- ¹³ Felsen, J.: New Clinical Concepts of Bacillary Dysentery: Its Relationship to Non-specific Ulcerative Colitis, Distal Ileitis and Non-specific Granuloma. *Am. Jour. Digestive Dis. and Nutrition*, **3**, 86, April, 1936.
- ¹⁴ Harris, F. I., Bell, G. H., and Brunn, Harold: Chronic Cicatrizing Ileitis: Regional Ileitis (Crohn)—A New Surgical Entity. *Surg., Gynec. and Obst.*, **57**, 637, November, 1933.
- ¹⁵ Crohn, B. C.: The Broadening Conception of Regional Ileitis. *Am. Jour. Digestive Dis. and Nutrition*, **1**, 97, April, 1934.

DISCUSSION.—DR. JOHN HOMANS (Boston, Mass.).—The experimental observations of Reichert and Mathes are particularly interesting to me because they have made use of what might be called physiologic methods in studying an important system of the body, namely, the lymphatic system,

particularly in its relation to a rather mysterious and interesting disease. As Doctor Reichert has stated, investigators have studied the blood-vascular system in similar ways for many years, but have neglected the lymphatics which, though we hear very little about them, are, after all, intimately concerned with drainage and detoxification of the tissue fluids in many parts of the body. Since a damming up of these fluids is very likely to lead to fibrosis, is it not reasonable that a peculiar state of swelling sclerosis and ulceration should be studied from the standpoint of lymphatic occlusion? Just as Cecil Drinker's methods of cannulating and destroying lymphatics have thrown new light on elephantiasis, or these experiments of Reichert's have suggested that regional enteritis, or whatever one chooses to term it, is dependent, in form, at least, upon lymphatic obstruction. Doctor Reichert has followed up his training with the late Doctor Halsted and with Doctor Sabin in a most ingenious way. I doubt whether others less skillful can produce similar results.

He has certainly shown how very readily edema and sclerosis of the bowel can be brought about by filling the lymph vessels of a region with a sclerosing medium. It is unfortunate that animals, particularly dogs, are so resistant to pyogenic bacteria. This resistance may retard the further verification of an hypothesis which Doctor Reichert has so modestly put forward, though of course he has shown how the presence of bacteria may fortify his results. In any case, he has done mechanically what nature probably does through the intestinal bacteria. Pathologically, regional enteritis is not an entity. Its variations may be due to a changeable exciting factor, for which Doctors Reichert and Mathes have supplied the anatomic background.

DR. ALFRED BLALOCK (Nashville, Tenn.).—I should like to speak very briefly of some experiments which I think corroborate the findings that have just been reported by Doctor Reichert. These studies were performed by Dr. R. S. Cunningham, Dr. C. S. Robinson and myself.

We were attempting to produce traumatic asphyxia, and we ligated the superior vena cava of a dog. Much to our surprise, nothing happened immediately. About ten days later the dog became short of breath. He died the following day, and at autopsy 900 cc. of milky fluid were found in the pleural and pericardial cavities. We thought possibly it was an accident and repeated the experiment on approximately 50 animals, and chylothorax resulted in more than one-half of them. We then wondered if we could produce lymphatic occlusion without venous obstruction. Complete lymphatic obstruction was produced in three of more than 50 animals studied, by a variety of procedures which included ligation of the ducts on the right and left sides of the neck, ligation of the thoracic duct in the chest, destruction of the cisterna chyli in the flank, and in some cases direct attacks upon the mesenteric lymphatics.

As was stated, we produced complete occlusion in three dogs. The evidence was this: The dogs lost weight. The eosinophils and the lymphocytes disappeared from the blood stream. Chemical studies revealed an abnormality in the absorption of fat. The dogs died, and at autopsy striking changes were observed.

In part of the intestinal tract from one of these three animals, the entire wall was perfectly white. Enormous lymph vessels were observed everywhere. Although the peritoneal cavity was not entered in this experiment, this condition resulted.

In a section of the omentum, large lymph vessels were seen. These were much more marked at the time of autopsy. In addition, there was a pooling of lymph in many of the tissues; for example, in the pancreas. The same

was true of the entire intestinal tract, and even occurred beneath the epicardium of the heart.

A section from a second experiment showed the lymphatics filled with coagulated material. Again the peritoneal cavity was not entered, showing that the same condition which Doctor Reichert can produce by a direct attack can be caused by operating elsewhere.

In the experiments in which complete obstruction was not produced, collateral lymph channels were demonstrated at autopsy. Most of these communications were with the inferior vena cava near the orifices of the renal veins.

DR. FREDERICK L. REICHERT (San Francisco, Cal.) closing.—Answering Doctor Homans' question about the acute cases of enteritis, I feel that certainly a number of them must recover from the condition without any symptoms, just as that last animal did, living for ten months without any symptoms whatever. Many of our cases probably do recover, but there are others, just as in this series of dogs, in which the thickening continued, some of them having obstruction and others developing adhesions and kinking and shortening of the mesentery. In none of our animals did we find any free peritoneal fluid.

Doctor Blalock's work is excellent. He too has produced thrombosed lymphatics and he has applied this method to the lymphatic system of the entire body. I will expect to hear a great deal more from him.