

ANNALS OF SURGERY

VOL. 110

SEPTEMBER, 1939

No. 3



SURGICAL MANAGEMENT OF THE PATENT DUCTUS ARTERIOSUS*

WITH SUMMARY OF FOUR SURGICALLY TREATED CASES

ROBERT E. GROSS, M.D.

BOSTON, MASS.

FROM THE CHILDREN'S HOSPITAL, THE PETER BENT BRIGHAM HOSPITAL, AND THE SURGICAL LABORATORY OF THE HARVARD
MEDICAL SCHOOL, BOSTON, MASS.

DURING FETAL LIFE the incomplete expansion of the lungs produces a high resistance to blood flow in the pulmonary vascular bed. It is necessary, therefore, to have a compensatory mechanism whereby blood can be short-circuited around the lungs. Nature provides this shunt in the form of the ductus arteriosus which diverts blood from the pulmonary artery directly into the aorta. When the fetus is born and the lungs expand, the ductus normally closes and all of the blood passes through the lung bed to be aerated. If this vessel fails to close, a reversal of flow takes place within the ductus because pulmonary artery pressure is reduced and aortic pressure is increased. Blood then passes from the aortic arch into the lesser circulation (Fig. 1) and the patient possesses what is essentially an arteriovenous aneurysm (Holman¹⁴).

There is considerable difference of opinion regarding the time when the ductus Botalli ceases to function. Patten²⁰ has pointed out that degenerative intimal changes begin in the latter part of fetal life, and it is his concept that increasing amounts of blood flow through the lungs even before birth. The histologic findings in the closing ductus resemble those of endarteritis obliterans, according to Schaeffer's²⁴ studies, and the diminution in size of the vessel is a gradual process requiring many weeks before occlusion is completed (Scammon and Norris²³). Christie⁵ studied a large series of routine postmortem specimens from babies to determine the time at which the ductus was normally obliterated. As older and older subjects were examined, the number of open ducti diminished to 44 per cent at one month, 12 per cent at two months, and 2 per cent at eight months of age (Chart 1). Following this, there was a small group of individuals in whom the vessel remained open permanently. At what age, then, can the persistence of the vessel be considered as pathologic? Arbitrarily, we might say that the ductus Botalli which is still open after the first year of life should be regarded as abnormal.

The child or youth who possesses a patent ductus faces an uncertain future. He may live in relatively good health till old age, or his life might be quickly terminated by some complication arising from his long existing lesion. Like

* Read before the American Surgical Association, Hot Springs, Va., May 11, 12, 13, 1939.

Damocles, he leads a precarious existence, never knowing when he might be cut down by the danger which menaces him. The causes of death in these individuals may be listed as rupture of the ductus, thrombosis of the ductus with subsequent embolism, bacterial endocarditis or endarteritis, and cardiac decompensation resulting from the arteriovenous communication.

In 1907, Munro¹⁹ first suggested that the surgeon might undertake the task of obliterating the ductus by operative means. So far as I am aware, O'Shaughnessy²² and Strieder⁹ have been the only ones to attempt perform-

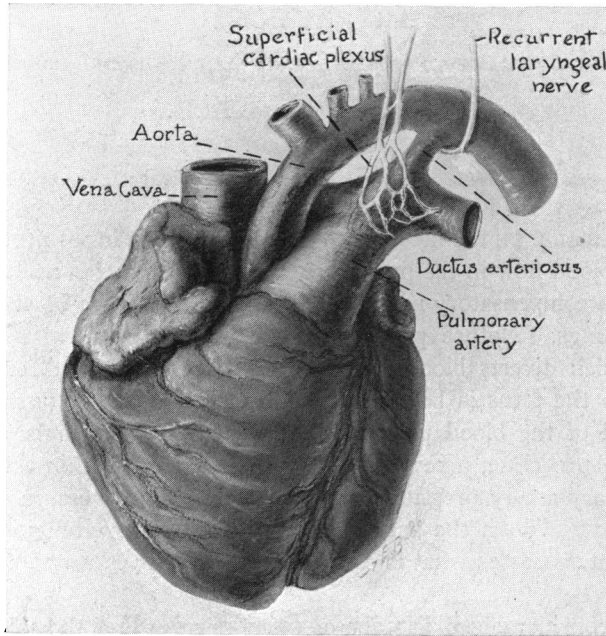


FIG. 1.—Drawing of heart and great vessels from a four-week-old child showing position of the ductus arteriosus and its communications with the pulmonary artery and aorta. The left recurrent laryngeal nerve curves around the aortic arch lateral and posterior to the ductus. The superficial cardiac plexus which lies between the arch and pulmonary artery is joined by small nerves from the vagus and cervical sympathetics which lie in front of the arch and medial to the ductus.

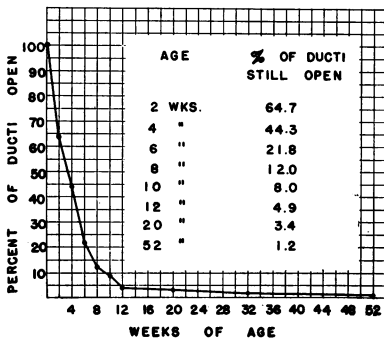


CHART 1.—Showing time of closure of the ductus arteriosus as found by examination of routine autopsy material. (From Christie.⁵)

ance of this feat. In O'Shaughnessy's patient, the diagnosis was incorrect and the ductus was found obliterated. In Strieder's case, technical difficulties prevented complete closure of the vessel and the patient succumbed a few days later. My attention was first directed to the problem several years ago by Dr. Elliott Cutler, but the present work had its greatest impetus from the enthusiastic support of Dr. John Hubbard who presented Case 1 for study and subsequent operation. The cases herein reported are the first and only ones which have ever been

successfully operated upon. There is much to be learned concerning the best method of obliterating the ductus, but the work here presented amply demonstrates that the ductus can be explored with safety and that it can be ligated in most instances without mortality. The degree of success thus far encountered makes it important to recognize these patients—and not merely classify and treat them as “congenital heart disease”—because in properly selected cases surgical therapy has much to offer.

Etiology of the Persistent Ductus Arteriosus.—The embryonic shunt between the pulmonary artery and the aortic arch may persist into postnatal life as a compensatory mechanism. Thus, if there is obstruction at the aortic valve from bicuspid or stenotic leaflets, or if there is coarctation of the aortic arch, the ductus may remain open and allow blood to escape from the pulmonary artery to the aorta. Such a combination is rare, and when it does occur it is necessarily accompanied by some degree of cyanosis. A second compensatory mechanism is concerned with stenosis or atresia of the pulmonary valve or hypoplasia of the pulmonary artery, wherein the direction of blood flow through the ductus must be from aorta to pulmonary artery. In this latter type of case there are usually other associated anomalies, the most frequently encountered combination being the tetralogy of Fallot in which there are stenosis of the pulmonary valve, a defect of the interventricular septum, hypertrophy of the right ventricle, and a right-sided aorta.

While it is true that the open ductus may often represent a compensatory mechanism, it may also exist without any other abnormality. In a series of 242 cases reviewed and studied by Abbott,¹ there were 92 hearts in which there were no other cardiovascular lesions. In short, about two-thirds of patients with a patent ductus have some other abnormality and about one-third of them have no other pathologic finding.

In those cases in which the open ductus is the sole lesion, there is no adequate explanation for the continued patency of the vessel. There are, however, three things which must be considered as possible etiologic factors. The first of these is concerned with the anatomic position and direction of the vessel. If one examines postmortem material of infants who have died in the first few months of life, the ductus, or its obliterated remnant, sweeps backward and to the left with a gradual curve to run alongside the aorta and then to enter it at a rather acute angle. The nature of this angle of entrance into the aortic arch in the fetus obviously has the function of directing the oxygen-deficient blood from the right ventricle downward in the aorta so that it might be distributed to the hypogastric arteries and thence to the placental circulation. The sharpness of this angle must serve another purpose, namely, to help obliterate the ductus in postnatal life. At birth, when the lungs expand and the blood flow through them increases, a diminishing amount of blood is forced from the pulmonary artery into the ductus. When this state of affairs obtains, the arterial blood rushing around and down the aortic arch must now have somewhat of a sucking action on the ductus which enters it so acutely. This sucking action would tend to collapse the vessel.

If, however, the ductus joins the arch at a more obtuse angle or at a right angle, the lumen of the ductus will be subjected directly to the high pressure existing in the aortic arch, and the ductus will thereby be kept distended. Thus, it is probably correct to believe that the principal reason for persistence of a ductus is due to its anomalous position and direction. This idea is certainly sustained by the observations in all four of the cases here reported.

A second possible factor which might contribute to the persistency of a ductus is some defect in its wall. This deficiency may concern the internal elastic membrane, the elastic tissue of the media, or even the smooth musculature. Such deficiencies of the ductal wall would allow the vessel to distend under low internal luminal pressures which would not distend a vessel possessing normal elasticity. Such a consideration is hypothetical, for there is no published account of histologic examination of the wall of persistent ducti as compared with those which are normally closing in the first or second month of infancy. It is certainly true that a thin, inelastic wall is not seen in all cases of persistent ductus, but in one patient (Case 2) the vessel wall was as thin as a vein. That a thin or deficient wall might be a factor in persistency in some instances is also supported by those cases in which the ductus has actually dilated to aneurysmal proportions.

The third factor concerned with the persistency of the ductus is related to its neuromuscular control. The smooth muscle fibers in the ductal wall of some animals have been shown to be under vagus nerve control. Barclay, Barcroft, Barron, and Franklin² have injected radiopaque substances into the vascular systems of lambs delivered by cesarean section and have observed the ductus roentgenologically. It was their belief that the ductus underwent a "functional closure" within a few minutes after birth. However, subsequent autopsy upon such an animal showed the ductus to be still morphologically open. The only way to correlate these findings was to assume that the ductus was *functionally* closed during life by a neuromuscular mechanism which, of course, would not be operative after death. It is not reasonable to assume that the ductus is held in a state of obliteration throughout the newborn period by smooth muscle contraction alone. However, it is probably true that contractions assist in the closure of a ductus and that a deficiency in the neuromuscular apparatus would tend to make morphologic obliteration more difficult.

Pathologic Anatomy.—The length and diameter of the ductus, as well as the thickness of its wall, have considerable bearing on the possibilities of surgically ligating it. Unfortunately, the literature gives but scanty account of desired anatomic facts. In most instances the internal diameter of the lumen is about all that is listed. The following descriptions are gleaned from diverse sources and represent statements from various authors, postmortem observations we have made ourselves, and further findings observed in four operative cases.

The size of the ductus cross-section is variable. An internal diameter of 3 to 4 Mm. is not uncommon, but in many cases this may be as much as 6

to 8 Mm. or more. In one autopsy specimen I have seen, from a man dying at 17 years of age, the ductus was 7 Mm. in diameter in its postmortem state, and, of course, may have been larger when distended during life. In the four cases operated upon, the external diameters of the ducti were 8, 12, 7 and 8 Mm. in individuals who were seven, 11, seven, and 17 years old, respectively. In general, it has been my experience that the ductus was about the same size as the left subclavian artery as it left the aortic arch, but in Case 2 it was considerably larger than this vessel.

The length of the ductus is of great importance, for, if the vessel is very short, dissection between the aortic arch and pulmonary artery may be impossible. In some adults¹⁵ the ductus is so short that a direct communication exists between pulmonary artery and aorta—an anatomic arrangement which would make it practically impossible to close the shunt. In newly born infants the ductus is usually 1 to 1.5 cm. long. In the four operative cases neither of these extremes was found, the length of these vessels being 5, 12, 7 and 5 Mm. respectively. In each of these cases, the first appearance at operative exposure suggested that there was a direct opening from aorta to pulmonary artery, but on careful and slow dissection of fatty and areolar tissue the aorta and pulmonary artery could be separated so as to bring into view a ductus which was long enough to ligate.

The thickness of the ductal wall varies. It is gathered from autopsy descriptions that the vessel is usually about as thick as an artery of similar size. In Cases 1, 3 and 4 this appeared to be so, but making this assumption in Case 2 nearly led to a fatality. In this latter operation, dissection was begun believing that the ductal wall would stand considerable manipulation, only to find that it suddenly tore and copious hemorrhage ensued. The torn wall was then seen to have the consistency and thickness of a vein. This possibility must be remembered when handling the vessel during life.

The swirling and impinging of blood currents against the pulmonary artery wall over a period of years eventually leads to intimal thickening, cholesterol deposition, and formation of typical atheromatous plaques. These changes are primarily found around the pulmonic orifice of the ductus and also on the wall opposite to the opening of the ductus. It is at these sites of intimal damage that subsequent bacterial endarteritis is apt to begin. Matusoff¹⁶ and Schlaepfer²⁵ have summarized the postmortem findings in cases of patent ductus arteriosus with infective pulmonary endarteritis.

Prognosis.—It is largely conjecture to estimate the prognosis for a given individual. Statistics taken from the literature give a false idea of the life expectancy, due to the fact that patients dying of some other cause are apt to go unrecorded, whereas individuals dying from complications of a patent ductus are more likely to be reported. Therefore, a summary of the literature gives a more serious outlook than the lesion probably warrants.

Cardiologists, with any breadth of experience, have examined and cared for adults who have patent ducti and yet lead rather normal lives. There is a general feeling that more of these cases are seen in childhood or adolescence

than are encountered in the latter half of life. One of two things must happen. Either these people grow up and die of their lesion after having been lost sight of, or else they have spontaneous closure of the ductus during middle life. Which of these interpretations is correct is difficult to say, but the net result is that many clinicians have developed the belief that the patent ductus carries a fairly good prognosis.

Opposed to this preceding, rather optimistic view, one finds a darker side when reviewing the literature on the subject. Numerous case reports are encountered describing patients who were known to have a patent ductus without apparent disability throughout adolescence, but who then died of decompensation or subacute bacterial endocarditis.^{15, 21, 27} There is no apparent method of computing the prognosis because the number of people with patent ducti is too small for adequate study. In all probability, the truth lies somewhere between the optimistic and the pessimistic point of view.

Abbott¹ has listed 92 patients with autopsy proof of a persistent ductus without other demonstrable cardiovascular anomaly. Twenty-eight of these died of subacute bacterial endocarditis, 24 died of slow cardiac decompensation, and 16 died of rather sudden cardiac failure. Two died of rupture of the ductus. The remainder died of causes unrelated to the circulatory system. In this series, then, the incidence of death from endarteritis or endocarditis was 30 per cent and the incidence of cardiac decompensation was 43 per cent. The average age of death was 24 years.

The complications attendant to the presence of a patent ductus may be summarized as fourfold: First, the existing shunt diverts sufficient blood from the aortic circuit so that the peripheral blood flow is deficient, and the growing child is thereby deprived of proper nutrition. Second, in rare cases a thinned-out ductal wall may dilate⁶ and rupture.¹⁷ Third, the presence of this vascular abnormality carries with it a high danger of subacute endocardial infection from the *Streptococcus viridans* or acute vegetative endocarditis from other organisms. Fourth, the shunt from the aorta to the pulmonary artery places a great burden on the heart by enormously increasing the total amount of blood which the left ventricle must put out per minute and by increasing the resistance against which the right ventricle must pump blood. The cardiac reserve is thereby reduced and myocardial failure may supervene after one or two decades.

Clinical Signs and Symptoms.—About two-thirds of the patients are females. A retardation in physical development is extremely common. Mental development, however, is usually good. The clinical course with an uncomplicated patent ductus may show little variation from the normal or there may be findings of a profound cardiovascular abnormality.¹⁸ The general run of cases develop but slight cardiac embarrassment in the early years of life. Physical activity is only slightly limited throughout childhood and adolescence, but these youngsters often notice that they tire more easily and become more dyspneic than confreres of their own age or size. Epistaxis may be profuse, particularly in children four to eight years of age. These patients

are usually conscious of a greatly intensified heart beat which is particularly exaggerated by exercise. A "buzz" or "burr" or "hum" in the chest is frequently spontaneously noticed by the individual. At times the mother will volunteer the information that she feels a "buzz" (as she calls the thrill) when dressing, bathing, or otherwise attending her child.

In contrast to this above described rather mild and attenuated course, occasional patients give symptoms of early cardiac embarrassment as is typified in Case 4. This girl experienced little difficulty until the fifth or sixth year of life when there was marked cardiac disability for which she was institutionalized for half a year. She then regained compensation and progressed fairly well until high school age. With the increased activity demanded by this stage of schooling, periods of semi-invalidism occurred during which she had edema of the legs, cough, some orthopnea, and occasional nocturnal dyspnea leading to a restricted or bedridden existence for two or three months at a time.

The physical manifestations of a patent ductus may be entirely wanting in infancy, are apt to be confusing in the first two or three years of life, but are almost always typical after the fourth year. In the first year there may be no murmur, thrill, or cardiac enlargement. In the second and third years some cases show only mild cardiac enlargement and a systolic murmur which is loudest at the base. At this stage one is usually not justified in making a more accurate diagnosis than "congenital heart disease." By the third or fourth year the murmur becomes continuous, develops a "machinery" character, is accentuated during systole, is loudest in the pulmonic area, and becomes accompanied by a systolic or continuous thrill. This progression of signs takes place with varying rapidity, requiring a year in some cases or several years in other individuals.

By the fourth or fifth year the fully developed picture of a patent ductus is present and may be described as follows: The heart action is extremely forceful and overactive and the rate may be increased. There is a loud, rough, continuous murmur with systolic accentuation, heard best in the second or third interspace to the left of the sternum. The quality of this murmur has been described as sounding like "machinery," "train in a tunnel," "mill wheel" or "rumbling thunder." The murmur is transmitted widely over the precordium with only slight diminution, but its quality may be somewhat changed toward the apex. The entire murmur, or only its systolic element, is transmitted to the back, to both axillae—particularly the left—with rather loud intensity, but it is heard only faintly in the neck. There is almost always a precordial thrill which is either systolic or continuous and which is most intense in the pulmonic region. The second sound at the pulmonic area is greatly increased and has a snapping quality. Cardiac enlargement may possibly be made out by percussion. The systolic blood pressure is within the normal range. Bohn³ pointed out that the diastolic level is low (when the ductus is large enough) so that these individuals have a high pulse pressure similar to that seen in regurgitation at the aortic valve. With this high pulse

pressure there is a collapsing type of pulse, possibly a "pistol shot" sound over the large leg and arm arteries, and a visible capillary pulsation in the skin or nail beds. One of the interesting features about the low diastolic pressure is the fact that it becomes lower still during exercise (in contrast to the normal rise during physical exertion).

In rare cases there may be changes in the voice. Schrötter²⁶ described one patient in whom laryngeal examination showed the left vocal cord completely immovable, but no abnormality was made out on the right. The voice was clear. A huge ductus was pressing on the left recurrent laryngeal nerve.

Roentgenologic and Laboratory Findings.—Roentgenologic examination of the heart is usually not necessary to make the correct diagnosis, but it does offer confirmatory evidence in most cases. Wessler and Bass²⁸ early emphasized the importance of roentgenography as a diagnostic aid. In the first year or two of life the picture may be distinctly confusing and contribute little. During this period there may be nothing more than slight cardiac enlargement with a rather globular shape to the organ in the anteroposterior view. After the third or fourth year, however, the roentgenologic findings are apt to be typical in the uncomplicated case. There is mild or moderate cardiac enlargement, particularly of the left ventricle. The pulmonary artery (often incorrectly called the pulmonary "conus") is more prominent than normal, though there are recorded instances in which this was not found. In all four of our patients this vessel was regarded as protruding unduly toward the left (Figs. 4, 9, 11 and 16). The lung fields have increased markings due to the vascular congestion in the lesser circulation. Fluoroscopically, the heart shows a very forceful action and there is increased pulsation in the dilated pulmonary artery. The increased pressure in the smaller pulmonary arteries throughout the lung fields may impart to them a pulsation which is seen as a "hilar dance." This, however, may be quite hard to detect.

In two of our patients there has been an interesting finding in regard to the size of the left auricle. In Case 3, this chamber was distinctly enlarged in the right oblique view. This posterior enlargement of the left auricle in a young child was at first believed to be due to an associated interauricular septal defect. We are now forced to believe that this thin-walled chamber can dilate in the presence of a patent ductus because of the enormous amount of additional blood which enters the pulmonary circuit from the aorta, and which must circulate through the left auricle. The correctness of this tenet was strikingly substantiated by the findings in Case 4, in which the dilatation of the left auricle led to the belief that an associated mitral stenosis was present. Here again there was a striking diminution in size of the left auricle after surgical obliteration of the ductus. (The cause for this dilatation may be appreciated by the fact that blood flow studies on Case 4 showed that 5.8 liters of blood per minute were passing through the right auricle and ventricle—an essentially normal figure—but concurrently, 24.6 liters were flowing through the left auricle and ventricle. Under these circumstances there is

some dilatation of the thick-walled left ventricle and a marked dilatation of the thin left auricle.)

In one case we attempted to outline the interior of the cardiac chambers by injection of radiopaque media into an arm vein. While the studies in this case were not entirely satisfactory, the observations were of value in that no other intracardiac pathology was demonstrated. This examination is useful in order to rule out other associated lesions such as septal defect, pulmonary stenosis, or hypoplasia of the aortic arch.

The electrocardiographic tracings are reported as demonstrating left axis deviation when the work of the left ventricle is great, or right axis deviation when the right auricle must pump blood against an increased pulmonic artery pressure. While both of these findings are possible, none of our cases showed axis deviation (Graph I), and we have come to look upon an abnormal electrocardiogram as possibly indicating some other associated malformation. While the EKG. is of little aid in making the diagnosis, it is of some use in ruling out the presence of other abnormalities such as pulmonic stenosis or atresia.

Compensatory polycythemia does not occur to any important degree and it is rare for the erythrocyte count to be over five or five and one-half million. Blood volume studies have not been extensively performed, but the available data indicate that there is moderate increase in the cellular and plasma elements of the blood. In Case 4 the blood volume was 3,950 cc. as compared to an expected normal of 3,200 cc. for this age and size. The circulation time from arm vein to tongue is normal or prolonged.

Criteria in Selection of Cases for Operation.—In reviewing a number of cases from the Cardiac Clinics of the Children's Hospital and the Peter Bent Brigham Hospital, we have formulated certain criteria for the selection of cases in which operative intervention is to be proposed. An increased experience will probably alter our views somewhat, but for the present the following considerations must be made in evaluating a given case for possible surgical therapy.

Providing the diagnosis of patent ductus is reasonably established, it is essential to rule out other associated conditions, the nature of which would make it dangerous to close the ductus. Such lesions would be stenosis of the aortic valve, hypoplasia or coarctation of the aortic arch, stenosis or atresia of the pulmonary valve, and bacterial endocarditis. Any one of these is a definite contraindication to operation. Systolic or diastolic murmurs over the aortic area which do not appear to be transmitted from the pulmonic area are highly suggestive of aortic stenosis or insufficiency, particularly if accompanied by a left axis deviation in the electrocardiogram. Hypoplasia of the aortic arch can be excluded by proper fluoroscopic examination. Coarctation will show a lower blood pressure in the legs than in the arms, the reverse of normal. Stenosis of the pulmonic valve may be exceedingly difficult to diagnose because the murmurs arising from it are almost identical with those originating from the ductus. However, the patient with an uncomplicated patent ductus has

a loud snapping second pulmonic sound due to the increased pressure within the pulmonary artery, whereas the pulmonic second sound will be absent or diminished if there is an abnormality of the valve. Furthermore, pulmonic stenosis is practically always accompanied by some right-sided hypertrophy in the roentgenogram, by right axis deviation in the electrocardiogram, and by cyanosis due to a right-left shunt of blood through a septal defect. Subacute bacterial endocarditis must be regarded as a contraindication to operation because the friable vegetations around the ductal opening will almost certainly be dislodged and result in embolism or a more severe bacteriemia.

There are several lesions, the presence of which do not necessarily imply that operation should be abandoned. The postoperative results following ligation of a ductus, when there is an associated septal opening or a mild mitral (rheumatic) stenosis, will not be as satisfactory as those obtained when the ductus is the sole lesion. However, a heart which is laboring because of two defects can be improved if one of these is removed. For this reason, we do not regard a septal defect as a contraindication to operation. Likewise, in Case 4 the possibility of a superimposed rheumatic mitral stenosis was raised, but closure of the ductus was recommended.

Confining ourselves now to those cases with a patent ductus and no other demonstrable cardiovascular lesion, the question arises whether all such individuals should be operated upon. The answer is decidedly, "No!" There are without doubt some individuals who have a patency of the ductus in infancy or early childhood and who have later findings indicating that this arterial shunt is spontaneously closing itself. Hence this individual should be left alone and natural processes permitted to continue in the reduction of size or ultimate obliteration of the vessel. When such a person is followed over a period of years, the murmurs have a decreasing intensity, lose their harshness, and may disappear from the diastolic phase of the cardiac cycle. The thrill, likewise, diminishes in intensity and may change from a continuous one to a systolic type. The heart is not enlarged, even though there may be a fulness of the pulmonary artery. The heart is able to maintain adequate peripheral circulation as is indicated by a normal diastolic pressure. In such children we feel that dangers of operation are not warranted when the ductal size is either stationary or is diminishing. In contrast to this, there are other patients in whom the clinical signs point to the fact that the ductus is actually becoming larger or that there are early signs of cardiac embarrassment. When once this trend of affairs is recognized it is reasonable and desirable to propose operation.

The positive criteria for selection of cases for operation may then be enumerated as follows: (1) There must be reasonable assurance that the ductus is patent as is determined by a loud, continuous, machinery murmur in the pulmonic area accompanied by an increased second pulmonic sound and a systolic or continuous thrill which is most intense in the pulmonic region. (2) There should be evidence of congestion in the lung fields by roentgenologic examination. (3) There should be a prominence of the pul-

monary artery roentgenologically—though some cases have been reported in which this has been absent. (4) There should be roentgenologic evidence of cardiac enlargement, particularly in the region of the left ventricle. (5) There should be a peripheral blood pressure which has an essentially normal systolic level, but a definitely lowered diastolic level. In short, one should have an indication that the ductus is enlarging, that the individual is not developing properly, that the danger of bacterial endarteritis is high, or that the heart is carrying an increased burden.

The Operative Exposure and Obliteration of the Ductus Arteriosus.—The ductus can be exposed by an anterior, transmediastinal route, opening through the sternum and viewing the great vessels very much as one does for pulmonary embolectomy. There is little to recommend this approach, for the opening in the chest wall is relatively small and the operator would be working in the bottom of a deep, narrow hole. With such limited exposure it would be exceedingly difficult to carry out any adequate dissection between the aorta and pulmonary artery and to control any bleeding which might be encountered. Furthermore, there would be great danger of injuring the superficial cardiac plexus and the left recurrent laryngeal nerve. In favor of the transmediastinal approach is the fact that the lungs are not collapsed, but in view of general experience with the innocuousness of temporary collapse this advantage cannot be regarded as important.

At the beginning of the present work it was necessary to devise a method by which the ductus region could be exposed adequately, safely, and without great shock. After examining a number of human cadavers, it was apparent that the aortic arch and pulmonary artery could be approached better from the left side than from the front of the chest. Making use of these observations, experimentation was then performed on living dogs, and it was found that an admirable view of the ductus was obtained by entering the thorax through the left pleural cavity and temporarily collapsing the lung during the operation. This operative approach has been treated more fully in another publication (Gross¹⁰) and, as it applies to the human, it may be described as follows:

The patient is placed on his back, with the left arm extended up along the head and with a small sandbag beneath the left shoulder so as to elevate the upper portion of the left side of the chest. A transverse incision, slightly concave toward the patient's head, is made either just above or below the breast tissue, from the sternal margin to the anterior axillary line. This is carried down through the subcutaneous tissues, the pectoralis fascia, and the fibers of pectoral major and minor muscles. (While this incision has been employed in all the cases here reported, a lower incision which turns upward the entire breast and pectoral muscle group would be an acceptable procedure but would not produce quite so good an exposure.) The pleural cavity is entered through the third interspace, carrying the incision from the internal mammary vessels around to the midaxillary line. The internal mammary vessels need not be divided. The third costal cartilage is cut across and, if it

is desired, the second cartilage may also be divided. (In one patient a better opening was made by entering through the second interspace and retracting the second rib upward.) This allows the ribs to separate easily with the aid of a self-retaining retractor. As the lung collapses away inferiorly it is protected by a covering of moist gauze.

With the lung out of the way, the operator now has an excellent view of the lateral aspect of the base of the heart and the superior mediastinum (Figs. 10 and 12). The phrenic nerve is readily seen beneath the thin pleura but the vagus nerve may or may not be clearly discernible, depending upon how much fibro-fatty tissue there is around it. Superiorly, the rounded arch of the aorta is easily identified, and if all the major vessels arising from it cannot be seen, at least the first portion of the left subclavian artery can be viewed. The pleural covering of the mediastinum is now incised from the lung root upward toward the base of the neck to uncover the pulmonary artery and aortic arch. This incision is 7 or 8 cm. in length and should be made 1 to 2 cm. posterior to and parallel to the phrenic nerve. This incision is placed well behind the phrenic nerve in order to avoid injury to the underlying superficial cardiac plexus and the fibers which join it from the sympathetic and vagus systems (Fig. 1). In some individuals the upper one or two left intercostal veins do not drain into the azygos system, but instead form a single trunk which courses medially forward and along the mediastinal surface to flow upward to the left innominate vein. Inasmuch as this vein crosses the cephalic end of the desired pleural incision, it is best to divide it when present.

After the pleura is incised, a fine network of fat and areolar tissue of variable vascularity is found filling in the sulcus between the aortic arch and pulmonary artery. Almost invariably, it first appears that these two great vessels are directly contiguous to one another and that any communication between them must be in the form of a direct opening. However, with great care and patience, it is surprising to find that a plane of cleavage can be located and if followed will lead one deeply between the vessels. The question then arises regarding the exact location of the ductus and where dissection should be made to uncover it. There are three ways to determine the position of this vessel: (1) The ductus lies just opposite to or a little distal to the origin of the left subclavian artery. (2) The ductus may be compressed, and as this is done there will be a temporary disappearance of the thrill over the heart and pulmonary vessel. Thus, by running the finger along the sulcus, between the aortic arch and pulmonary artery, and pressing in various places, that point at which pressure stops the thrill will indicate the ductus site. (3) The left recurrent laryngeal nerve arises from the vagus nerve, courses downward, and then curves around the aortic arch a few millimeters posterior to the ductus. Hence the tracing of this structure will lead one directly to the ductus.

It has been my practice to quickly locate the general position of the ductus by finding the point opposite the origin of the subclavian artery and

then press in various places below the aortic arch until the thrill is temporarily stopped. Careful attention is then turned to the isolation of the recurrent nerve for two reasons (Figs. 1 and 2): First, the entire extent of this structure must be identified in the operative field so that it is in view at all times and can be left uninjured. Second, the following of this nerve is the best way to accurately locate the ductus. I have spent as long as an hour in locating, freeing up, and tracing this nerve, for it is time well spent, and once it is brought into view, the remainder of the dissection seems to be on a safer and surer basis.

The release of tissue around the ductus should be accomplished by blunt dissection. In this way less bleeding is encountered from small veins in the region. The postero-medial aspect of the ductus cannot be visualized completely, but gentle dissection here with a half length or a right-angle clamp will safely separate the underlying left main bronchus. The ductus should not be cleaned off too much, for if a small amount of areolar tissue is left around the vessel it will serve as a padding to prevent cutting-in of the ligature when it is applied. In most cases this entire dissection will be extra-pericardial, but in Case 3 the sac had a very high reflection and was opened into. At this stage haste should be avoided because a too rapid dissection may stir up bleeding and produce ecchymoses through the tissues which obscure the field and hamper the remainder of the operation. The elapsed time of isolating the ductus after the opening of the pleura was in no case less than an hour and in the last patient consumed nearly two hours.

An aneurysm needle carrying the ligature material may now be passed around the ductus. Before permanently obliterating the vessel it is best to make a temporary occlusion for two or three minutes to insure that closure of the vessel will not in any way embarrass the circulatory apparatus. During this period the patient's color, blood pressure, pulse, and cardiac action can be observed for any untoward reactions. This temporary closure may be made by drawing up the thread and holding it with the fingers, or else the thread may be passed onto a Shenstone hilar tourniquet which is drawn up snugly without employing the ratchet (for fear of cutting through the ductus). If no undesirable effects are produced during the temporary observation period, the ductus may be permanently ligated. The ligature material

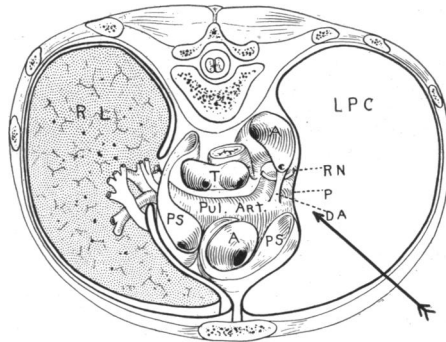


FIG. 2.—Sketch of a horizontal section through the fifth thoracic vertebra, showing route by which the ductus arteriosus may be exposed by an antero-lateral approach through the left chest. If the left pleural cavity (L.P.C.) is opened, the lung collapses toward the inferior part of the chest. The operator can then look directly at the mediastinum and can expose the ductus by incising the parietal pleura (P). (A). Ascending and descending aorta. (DA). Ductus arteriosus. (Pul. Art.). Pulmonary artery. (PS). Pericardial sac. (R.L.). Right lung. (RN). Recurrent nerve. (T). Trachea, at its bifurcation. Arrow shows direction of operative approach through the left second or third intercostal space.

in all cases of the present series was No. 8 heavy braided silk (Gudebrod Company). In two cases only one ligature was employed, but in the other patients two ligatures were used. The latter is unquestionably a better practice, and it might be advisable to inject a few drops of sclerosing fluid into the ductus between the constricted points. It cannot be emphasized too strongly that these ligatures must be drawn up *very tightly* if complete obliteration is to be effected. When a satisfactory closure has been made there is *complete* disappearance of the thrill in the pulmonary artery.

It would be a preferable surgical procedure to divide the ductus rather than ligate it in continuity, but in our series this was impossible because of the shortness of the vessel.

The operative closure can now be completed rapidly. The edges of the mediastinal pleura are approximated with continuous or interrupted sutures. The cut ends of the costal cartilage are anchored to one another with a heavy catgut suture, piercing the cartilage with a sharp needle. The intercostal muscles are approximated with continuous catgut, reexpanding the lung completely with positive pressure before the last suture is drawn up and tied. The pectoral muscle is repaired with continuous catgut to the muscle fasciae and a few interrupted mattress sutures to butt together the ends of the muscle. The subcutaneous fascia must be carefully sutured or there will be a marked tendency for the incisional scar to subsequently spread.

Postoperative Care.—There is remarkably little postoperative reaction. In the first three cases eucupine solution was injected into the intercostal nerves while the chest was still open. The prolonged anesthetic action of the drug appeared to greatly reduce postoperative discomfort in the wound. In the first case, the child was allowed out of bed in a wheel chair on the first postoperative day (Fig. 5) and was walking on the third day (Fig. 6). The wounds all healed per primam. There was some edema for three or four days, but there was no permanent collection of fluid such as was anticipated from cutting across the lymphatics of the breast (Fig. 17). There was a moderate tendency for the skin wounds to spread and become conspicuously wide. There was no difficulty with healing of the transected pectoral muscles after a regimen of immobilizing the upper arm for two or three weeks. In two patients, fluid collected in the left pleural cavity, which was not aspirated and which was resorbed spontaneously in about ten days.

Operative Results.—There have been no important postoperative complications. There has been no mortality in the cases thus far operated upon. In every patient the thrill has disappeared. In Cases 1 and 2 there is still a faint to-and-fro murmur at the pulmonic area, doubtless due to a small leak within the wrinkled spaces of the collapsed ducti. After these experiences, two ligatures were used in Cases 3 and 4 and this change in technic makes us feel certain that these ducti are completely obliterated for all murmurs have disappeared. In every case there has been a restoration of the low, preoperative diastolic pressure to a normal level (Charts 2, 3, 4 and 5). In each case the overactive and forceful action of the cardiac impulse has been

reduced to one of normal intensity. The transverse dimension of the heart in Cases 1 and 2 did not change appreciably, but in Cases 3 and 4 it has decreased 1 cm. and 0.5 cm., respectively. Case 2 had always complained of difficulty in gaining weight, but within four months after operation he has gained nine pounds. Each of these children has returned to school and bids fair to have an improved cardiovascular system.

In Cases 3 and 4 samples of blood (for oxygen content) were taken during operation from the aorta, the ductus, the main pulmonary artery, and the left pulmonary before and after ligation of the ductus. After determining the patient's oxygen consumption, it was then possible to calculate the volume of blood flowing to the periphery, through the ductus, and through the right and left sides of the heart. These studies are reported more fully elsewhere,⁷ but a few of the findings are listed here. In Case 3, the peripheral blood flow was 4.86 liters per minute while the ductus was still open and was increased to 6.12 liters per minute after the ductus was ligated. In Case 4, the peripheral blood flow was 5.8 liters per minute while the ductus was open. Concurrent with this peripheral flow, 18.8 liters of blood per minute passed through the ductus, making a total of 24.6 liters which the left ventricle had to pump per minute in order to maintain the peripheral flow at a normal level. Following ligation of the ductus, the left ventricular output was 5.08 liters per minute, and this entire amount was of course distributed to the periphery. In short, this heart was performing more than four times as much work as was necessary while the ductus was open. It is at once evident that ligation of the ductus greatly increases the cardiac efficiency, the increase in efficiency being dependent upon the size of the ductus which is obliterated. (The above figures all represent conditions with the patients under cyclopropane anesthesia, and while the figures are somewhat higher than in the unanesthetized individual, the general relationships are still true.)

The four patients thus far operated upon at the Children's Hospital and the Peter Bent Brigham Hospital are here presented in summarized form. Preliminary reports of these have been made previously.^{11, 12, 13}

Case 1.—L. S., female, age 7, entered the Children's Hospital, August 17, 1938, for study of her cardiac condition. At one and a half years of age her mother noted that the child was short of breath. At three years, examination, in another hospital, revealed findings of congenital heart disease. After having several epistaxes and episodes of pain in the extremities she was studied at four years of age in a second hospital. No evidence of rheumatic fever was found and there were no objective findings in the extremities. The discharge diagnosis was "patent ductus arteriosus." On entering school the child was bright and active, but often noticed that she could not play as long or as strenuously as did other children of her age. Frequently, she would stand still, have a rather frightened appearance, and would place her hand over her heart. When asked what was the trouble, she would whisper "something wrong inside of here." These apparently represented attacks of palpitation with momentary dyspnea. The mother volunteered the information that she "often heard a buzzing noise in the child's chest" when standing near her. At no time had there been cyanosis.

Physical Examination.—The patient was 49 inches tall and weighed 48 pounds. She was below the average physical development for her age and was moderately undernourished (Fig. 3). Inspection and auscultation showed a heaving, overactive cardiac impulse. There was a loud, to-and-fro machinery murmur accentuated during systole which was loudest over the pulmonic area, but was transmitted widely over the precordium and to a less extent to the axillae and back. A continuous thrill, greatest during systole, was felt along the left border of the sternum, particularly toward the base of the heart. Blood pressure 115/40.

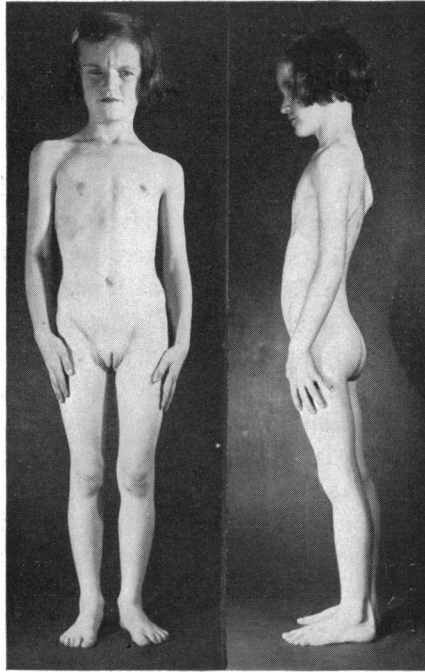


FIG. 3.—Case 1: Seven-year-old patient showing general body contour. Moderate undernourishment noted particularly in the prominence of the ribs.

Laboratory Data.—Red blood count 5,080,000. Circulation time, right elbow to tongue, with Decholin, eight to 10 seconds. Seven-foot heart film (Fig. 4) showed the heart to be enlarged with a transverse diameter of 11.7 cm. compared to an internal chest diameter of 20.0 cm. The enlargement was mainly in the left ventricle, and the pulmonary artery was more prominent than normal. Considerable perihilar congestion was noted. Fluoroscopy demonstrated a definite "hilar dance" in the lung vessels, particularly on the right. Electrocardiograms were normal.

Operation.—Artificial left pneumothorax was first performed to determine whether subsequent collapse of the lung during operation would seriously affect the patient. Inasmuch as there was no important reaction to this procedure, exploration was undertaken two days later.

On August 26, 1938, under cyclopropane anesthesia, an incision was made from the left sternal border to the left anterior axillary line just below the breast. The pectoral muscles were divided and the chest entered through the third left interspace after cutting the third costal cartilage. As the lung collapsed a good view of the heart and lateral aspect of the mediastinum was obtained. A very vibrant thrill was felt over the entire

SURGERY OF DUCTUS ARTERIOSUS

heart and the pulmonary artery. After incising the pleural covering of the mediastinum and carefully dissecting below the aortic arch, a ductus 8 Mm. in diameter and 5 Mm. long was exposed. This was ligated with a single, heavy, braided-silk ligature. The

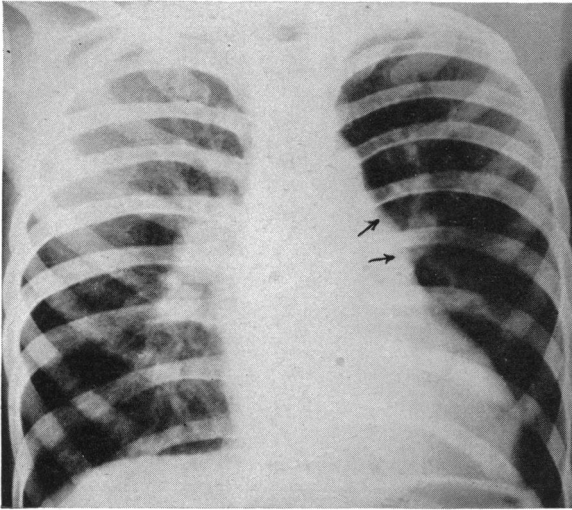


FIG. 4.—Case 1: Preoperative seven-foot heart film. Total transverse dimension of heart 11.7 cm. Internal diameter of chest 20.0 cm. Enlargement of heart, particularly in region of left ventricle. Definite fullness in area of pulmonary artery, indicated by arrows. Increased lung markings from vascular congestion, especially in right lung.




FIG. 5.—Case 1: Photograph taken 24 hours after operation, showing patient out of bed and sitting up in a wheel chair. There was little postoperative reaction.




FIG. 6.—Case 1: Photograph on third postoperative day, when patient was ambulatory, showing early recovery from the operative procedure. Left arm is still immobilized in the dressing.

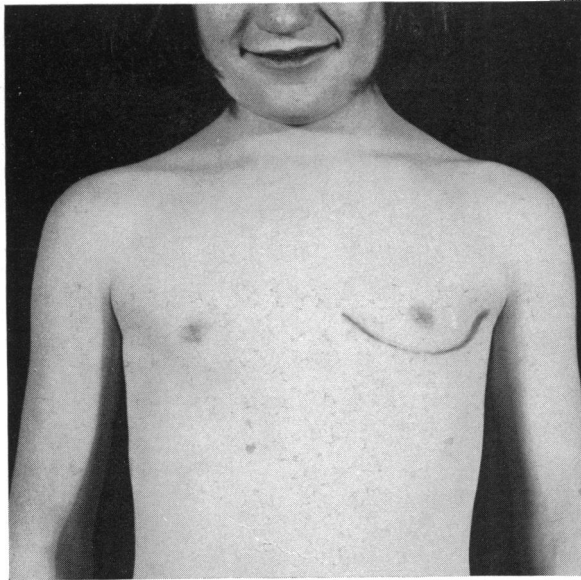


FIG. 7.—Case 1: Photograph two months after operation, showing position of the operative wound. Some weight gain is already seen in the fulness of the chest, compared to the prominent ribs in Figure 3.

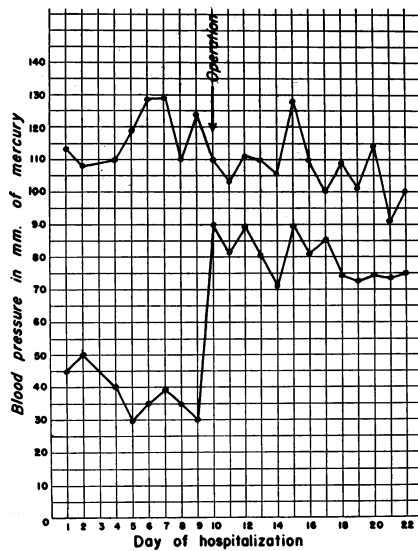


CHART 2.—Case 1: Daily blood pressure chart during hospitalization, showing the low diastolic level prior to operation and the immediate rise of the diastolic pressure following operative ligation of the ductus. Average daily diastolic pressure prior to operation was 38 Mm. of Hg. Diastolic pressure at time of hospital discharge was 73 to 75 Mm. of Hg.

thrill completely disappeared after closing the ductus. The mediastinal pleura was now sutured and, after the lung was reexpanded with positive pressure, the chest was closed.

Postoperative Course.—There was very little postoperative reaction. The child was allowed out of bed and up in a wheel chair 24 hours after operation (Fig. 5) and on the third day she was walking around the ward (Fig. 6). The wound healed well except for some keloid formation (Fig. 7). She was discharged on the thirteenth postoperative day. Examinations of the heart after operation and after hospital discharge showed the thrill to have disappeared. The cardiac action was now of normal intensity in contrast to its previous overactivity. There was a faint to-and-fro, soft murmur at the base, the systolic element of which was transmitted to the apex but not elsewhere. The diastolic

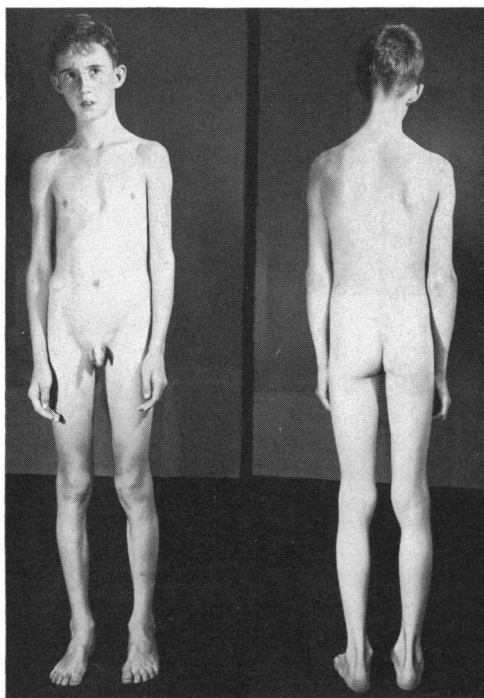


FIG. 8.—Case 2: Eleven-year-old boy with underdevelopment and deficient nourishment. Note the long thin extremities and fingers. Patient had great difficulty in gaining weight despite many years of clinic treatment.

blood pressure rose immediately on ligation of the ductus and has permanently remained normal at about 35 Mm. of mercury above her preoperative level (Chart 2). Electrocardiograms six months after operation show no change. The child has returned to school, is active, and is gaining weight.

Case 2.—R. C., male, age 11, entered the Children's Hospital, September 6, 1938. In the first year of life it was found that he had "heart trouble." Because of failure to gain weight he was first seen in the outpatient department at four years of age, at which time there was considerable malnourishment. At that examination, physical and roentgenologic findings were characteristic of a patent ductus arteriosus. On the present admission the child's chief complaint was that he was "always tired ever since he was big enough to run around." The child had noticed that he could never run and exercise as freely as his playmates. Exercise was never accompanied by cyanosis, but it

always brought on cardiac palpitation. The patient had never been able to gain weight properly in spite of guidance from the clinic.

Physical Examination.—The boy was thin and distinctly undernourished (Fig. 8). He was 58 inches high and weighed 62.5 pounds. The very forceful action of the heart imparted a marked pulsation to the anterior chest wall. A very loud and harsh, roaring continuous murmur, increased during systole, was heard in the pulmonic area. This was transmitted widely over the precordium, but the diastolic element was faint at the apex compared to the rather loud systolic apical murmur. The coarse systolic murmur could be heard in both axillae, particularly the left, over the back of the chest, but only faintly

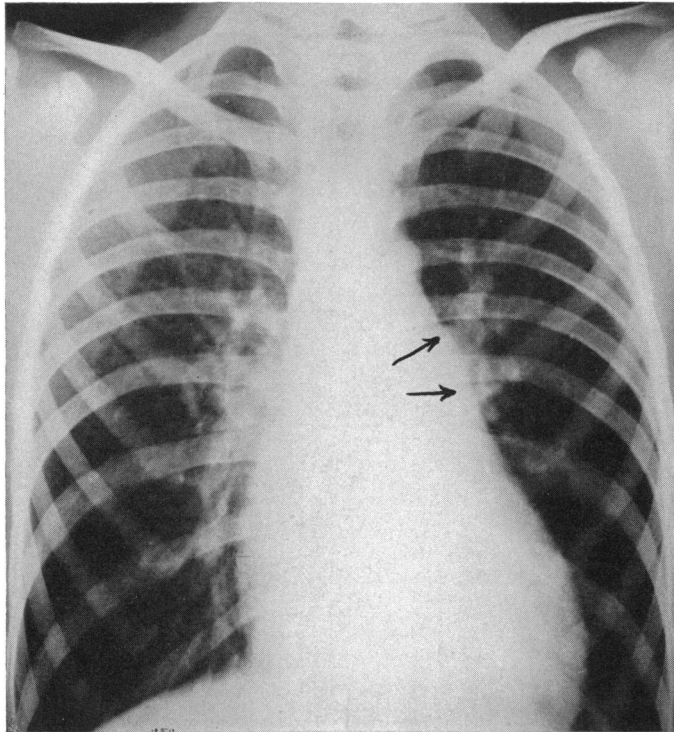


FIG. 9.—Case 2: Seven-foot roentgenogram prior to operation. Cardiac enlargement, particularly in region of left ventricle. Prominence of pulmonary artery indicated by arrows. Total transverse dimension of heart 11.3 cm. Internal diameter of chest 21.3 cm.

over the neck vessels. A vibrant, continuous thrill was felt over the precordium, especially in the left second and third interspaces. The pulmonic second sound was greatly increased. The blood pressure was 115/45. There was a definite Corrigan's pulse and a capillary pulsation in the fingernail beds.

Laboratory Data.—Roentgenologically, the heart was enlarged, the transverse dimension being 11.3 cm. compared to an internal chest diameter of 21.3 cm. (Fig. 9). Most of the cardiac hypertrophy appeared to be in the left ventricle. The pulmonary artery was prominent and the lung markings were increased. Electrocardiogram was normal. Red blood count 5,050,000.

Operation.—September 12, 1938: Under cyclopropane anesthesia, a slightly curved incision, running from the left sternal border to include the left anterior axillary fold, was made just beneath the breast, transsecting pectoral muscles and retracting breast and muscles upward. The thorax was entered in the third interspace, cutting the third costal

SURGERY OF DUCTUS ARTERIOSUS

cartilage. The collapsed lung was protected with a gauze pack and the mediastinum was viewed from its left lateral aspect (Fig. 10). A very coarse thrill was felt over the entire heart and pulmonary artery. This was so marked that it tickled the operator's fingers while working in the region and touching the great vessels with forceps or other instruments. The left recurrent laryngeal nerve was easily exposed. Following this structure forward and medially, an enormous patent ductus, 11 or 12 Mm. in diameter and 12 Mm. in length, was found. Attempts were now made to pass an aneurysm needle around the vessel so that ligatures might be brought into place. In the performance of

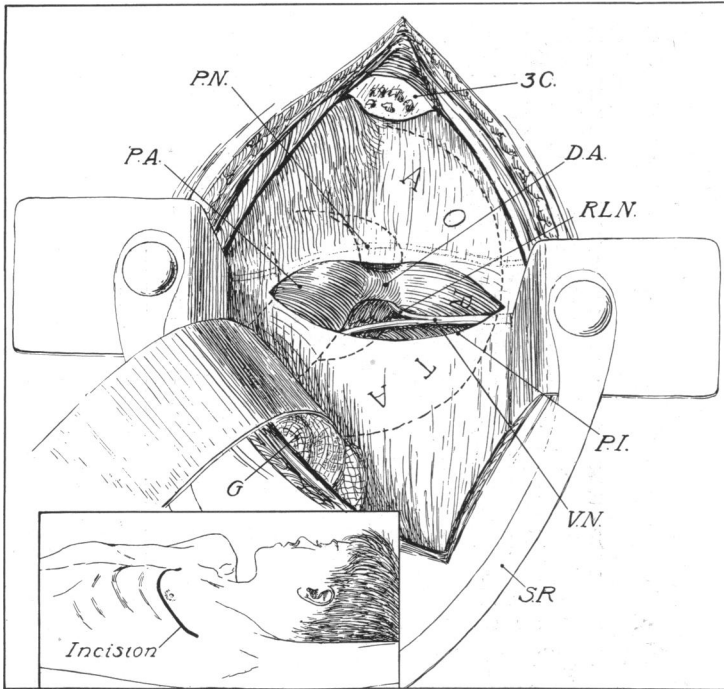


FIG. 10.—Case 2: Sketch of operative exposure of the ductus which was 11 Mm. in diameter. Insert shows position of patient with left arm drawn up along the head and with incision coursing just beneath the breast. Thorax entered through the third interspace. Third cartilage cut to allow upward retraction of ribs. The left lung is held down inferiorly with a gauze pack and malleable retractor. Positions of aorta and pulmonary artery indicated by dotted lines. When the pleural covering of the mediastinum was incised a direct view of the aortic arch, pulmonary artery, and ductus was obtained. (3C). Cut end of third costal cartilage. (DA). Ductus arteriosus. (G). Gauze pack over collapsed lung. (PA). Pulmonary artery. (PI). Pleural incision. (PN). Phrenic nerve. (RLN). Recurrent laryngeal nerve. (SR). Self-retaining retractor. (VN). Vagus nerve.

this task the thin-walled ductus tore and there was a serious hemorrhage which bid fair to end the operation fatally. However, a finger was held over the rent while a transfusion was finished and then with one finger over the hole, dissection was continued until ligature material could be carried around the ductus and tied up tightly. Fortunately, all bleeding was thereby controlled. After reexpanding the lung the chest was rapidly closed.

Postoperative Course.—Except for some discomfort in the wound for several days, requiring sedatives, there was little postoperative reaction. On the fourth day, the patient was allowed out of bed and at the end of a week was walking. He was discharged, September 29, 1938. The greatly accentuated cardiac beat has returned to normal activity. The thrill has disappeared. There is a to-and-fro murmur at the base which is soft, and

at times the diastolic element of this cannot be heard. The diastolic blood pressure has averaged about 30 Mm. of mercury higher after operation, compared to its preoperative level (Chart 3). Roentgenograms of the chest two months after operation show no essential change in size or contour of the heart. The boy's general condition has gradually and definitely improved, there being a weight gain of nine pounds in the first four months after operation.

Case 3.—F. S., female, age 7, entered the Children's Hospital, November 2, 1938. During the first four years of life, she was always under normal weight. At three years of age, there was a loud cardiac murmur and a widespread coarse precordial thrill. These findings, with a blood pressure of 110/40, plus a Corrigan's pulse, led to a diagnosis of aortic stenosis and regurgitation. From the fourth to sixth year of life the child

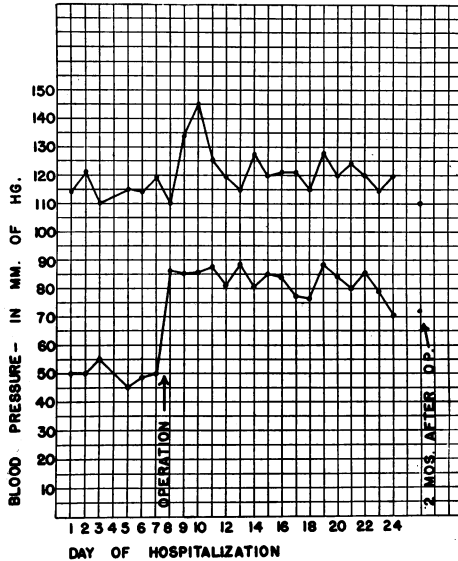


CHART 3.—Case 2: Daily blood pressure during hospitalization. Low diastolic pressure which existed prior to operation was immediately restored to a normal level by ligation of the ductus. This increased diastolic level was maintained as indicated by the reading two months after operation.

was usually unstable, tired easily, had moderate dyspnea and chest pain on exertion, and dilated veins were often noticed over the anterior chest wall. Her general activity, however, was not greatly retarded. There had never been cyanosis.

Physical Examination.—The patient was pale, somewhat thin and underdeveloped. The height was 46 inches and the weight 42.5 pounds. There was no cyanosis or clubbing. There was a marked precordial pulsation indicating a very active heart heat. There was an intense and coarse thrill over the entire precordium, most vibrant in the third left interspace, which was more pronounced in systole but which extended into diastole. A loud rough systolic murmur was heard in the pulmonic area which was transmitted over the entire precordium and with considerable intensity to both axillae and the back. In the pulmonic area there was also an untransmitted diastolic murmur which produced a to-and-fro, continuous murmur at the base. P_2 was greatly accentuated. The blood pressure was 115/50.

Laboratory Data.—Red blood count 5,090,000. Electrocardiograms were negative except for splintering of the QRS. complex in Lead 3 (Graph 1). Roentgenograms and fluoroscopic examination of the heart showed slight enlargement to the left (Fig. 11).

Transverse dimension of the heart 9.8 cm., compared to an internal diameter of the thorax of 18.6 cm. There was a marked bulge in the region of the pulmonary artery and also considerable pulsation of the congested pulmonary arteries. Blood volume was 1,600 cc. as determined by the Gibson⁸ method.

Operation.—November 9, 1938: Under cyclopropane anesthesia, the same general approach as in Cases 1 and 2 was employed, but incision was made above the breast, and the second as well as the third costal cartilages were cut. When the chest was opened in the third intercostal space, a very wide and satisfactory exposure of the heart and superior mediastinum was obtained. The heart had a very forceful impulse and there was a marked thrill over the entire organ and over the pulmonary artery. After considerable time-consuming dissection, which required opening of the superior portion of the

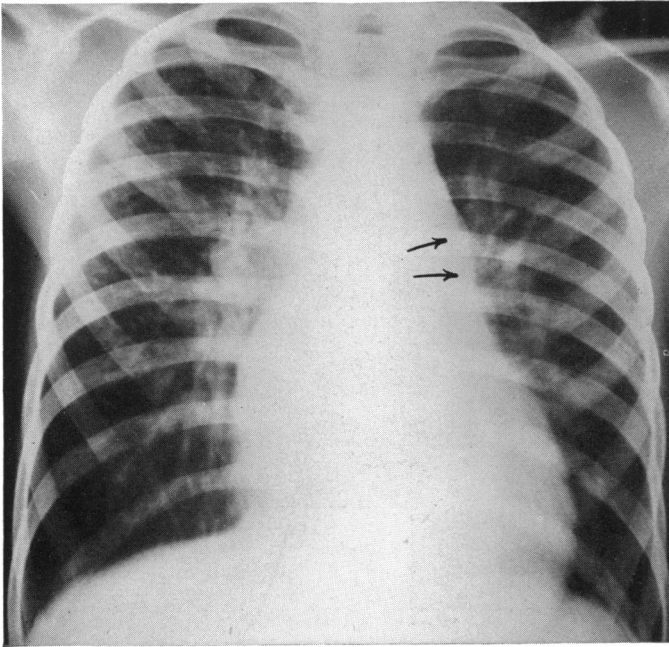


FIG. 11.—Case 3: Seven-foot roentgenogram prior to operation. Moderate cardiac enlargement. Prominence in region of pulmonary artery indicated by arrows. Increased markings in lung fields. Total transverse dimension of heart 9.8 cm. Internal diameter of chest 18.6 cm.

pericardial sac, the underportion of the aortic arch was bared and the ductus was found to be 7 Mm. in diameter and 7 to 8 Mm. long (Fig. 12). After a preliminary pinching-off of the ductus for three minutes, to make sure there would be no deleterious effects, the vessel was permanently obliterated with two heavy braided and waxed silk ligatures. The thrill disappeared immediately, the diastolic pressure in the arm rose greatly, and the heart slowed (within two or three beats) from 100 to 70. This latter very prompt and dramatic response was probably brought about by the raising of pressure in the aortic arch which slowed the heart reflexly by way of the cardiac depressor nerve. The pulmonary artery, which prior to ligation had been quite tense, was distinctly softer after closure of the ductus. Two silver clips were placed on one of the ligatures so that this region might be accurately identified in postoperative roentgenograms (Fig. 14). The lung was then reexpanded with positive pressure and the chest closed.

Postoperative Course.—The wound healed well and the patient was discharged on the thirteenth postoperative day (Fig. 13). Like the other patients operated upon with

this approach, there was no disability from section and suture of the pectoral muscles. The heart, which had been so active prior to operation, now had a beat of normal intensity. The thrill has disappeared and absolutely no murmurs can now be heard. The diastolic blood pressure showed a marked change. Before operation this had varied from 30 to 50, and beats could be heard all the way down to zero. After operation the diastolic pressure was almost constantly at 80 and no beats could be heard below 65 or 70 (Chart 4). Postoperative electrocardiograms showed no change (Graph 1). Reexamination of

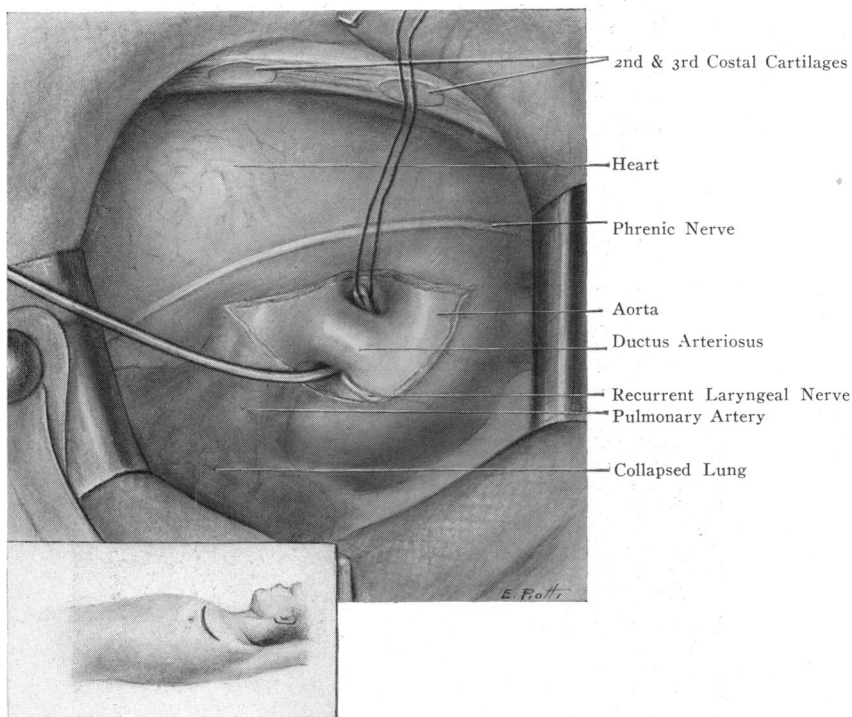


FIG. 12.—Case 3: Operative exposure of patent ductus arteriosus which was 7 Mm. in diameter. Incision of pleura made posterior to the phrenic nerve. After dissecting fatty and areolar tissue from the sulcus between aortic arch and pulmonary artery, the recurrent laryngeal nerve and the ductus were brought into view. The origin of the left subclavian artery is just seen on the aortic arch, opposite to and a little proximal to the ductus opening. Aneurysm needle passed around the ductus. Second and third costal cartilages both cut in this case. Insert shows position of the skin incision which in this patient was made above the breast.

the heart, two months after operation, showed the left auricle to be smaller and there was a diminution in the transverse dimension of the heart of 1 cm. (Fig. 15). Kymograms also showed diminished ventricular excursions after operation. Of particular interest was the pulmonary artery, which had collapsed but little as viewed in the roentgenogram. However, by kymogram, this vessel as well as the aortic knob was seen to pulsate much less than before operation (Graph 2). The child's general condition has been excellent; she has returned to school and in the first two months after operation she has gained three pounds in weight.

Case 4.—M. F., female, age 17, entered the Peter Bent Brigham Hospital, November 28, 1938, for study of her cardiac condition. At the age of three, a cardiac murmur was first discovered. At the age of five, she entered another hospital for treatment of marked cardiac decompensation and at that time was hospitalized for six months.

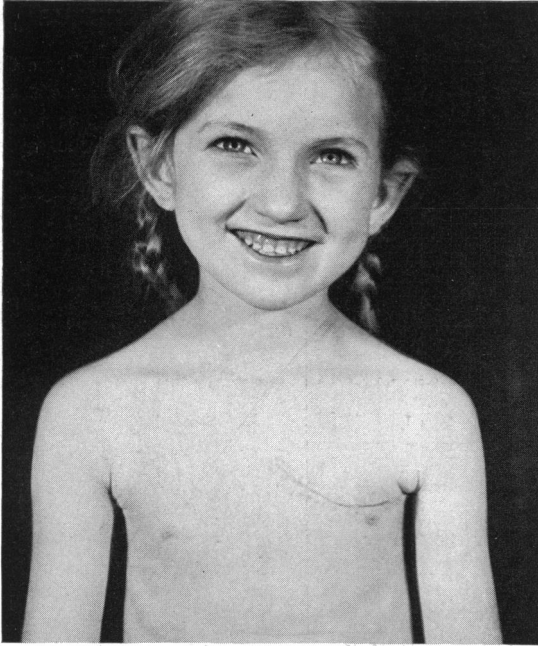


FIG. 13.—Case 3: Photograph showing position and condition of wound on tenth postoperative day.

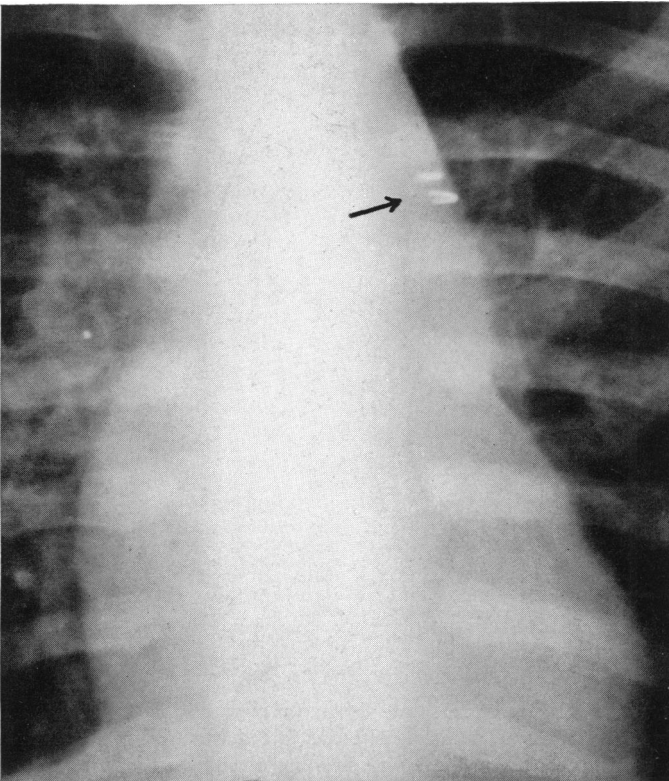


FIG. 14.—Case 3: Roentgenogram of heart following operation to show position of the two silver clips which were placed on the ductus ties to identify this region. The obliterated ductus is a few millimeters medial to these clips.

During that time her general condition gradually improved. From the age of six until 12 there were frequent and very copious epistaxes. Except for occasional dyspnea there was little limitation of her physical activity, but the child noticed that she always tired more easily than her playmates. After entering high school increased physical exertion

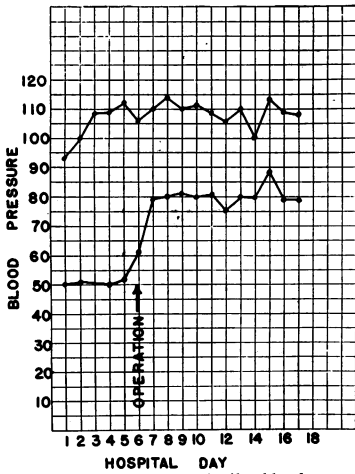
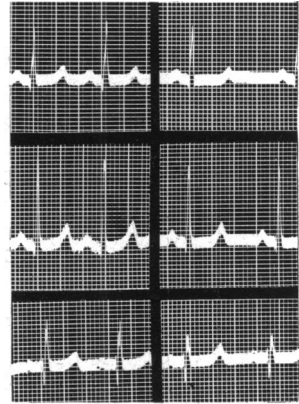


CHART 4.—Case 3: Daily blood pressure chart, indicating marked change in the diastolic level after obliteration of the patent ductus.



GRAPH 1.—Case 3: Electrocardiograms before operation on left, and after operation on right. Normal curves before operation. No important change after operation.

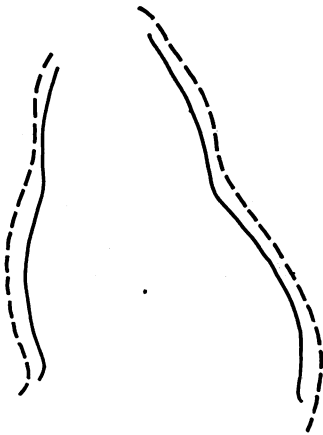



FIG. 15.—Case 3: Outlines of heart before operation (dotted line) and after operation (solid line) as traced from seven-foot heart films, showing reduction in size of heart following closure of the aorto-pulmonary artery shunt. Transverse diameters 9.8 cm. and 8.8 cm. before and after operation, respectively.



GRAPH 2.—Case 3: Tracings taken from preoperative kymogram of heart to compare with postoperative tracing of left cardiac border. Prior to operation there was an increased amplitude of movement in the left ventricular border which is reduced after operation. Prior to operation there was marked pulsation in the aortic knob and pulmonary artery regions which is greatly reduced after ligation of the ductus. (A to B). Region of aortic knob and pulmonary artery. (B to C). Border of left ventricle.

brought recurring episodes of moderate decompensation so that the curricula had to be greatly reduced. On several occasions she was in bed from one to three months. During these periods of incapacitation there was swelling of either or both legs, accompanied by dyspnea. For the year prior to hospitalization formal schooling had to be abandoned, and the patient was kept at home. For two months prior to hospital entry there had been

SURGERY OF DUCTUS ARTERIOSUS

three or four attacks of gripping pain in the left chest which were relieved by rest. During this time there had been moderate orthopnea and frequent palpitation. For several years there had been frequent attacks of tonsillitis and at times the question of rheumatic fever had been raised, though there was no swelling, tenderness, or increased heat of the joints at any time.

Physical Examination.—The patient was a small-framed, thin, somewhat undernourished individual weighing 95 pounds. The general physical condition was good. The tonsils were enlarged and mildly inflamed. The thorax was a little more prominent on the left than on the right. The lungs were clear. The cardiac action was extremely forceful, even during rest in bed. Over the pulmonic area was a loud, coarse, continuous machinery murmur with systolic accentuation. This was transmitted widely over the

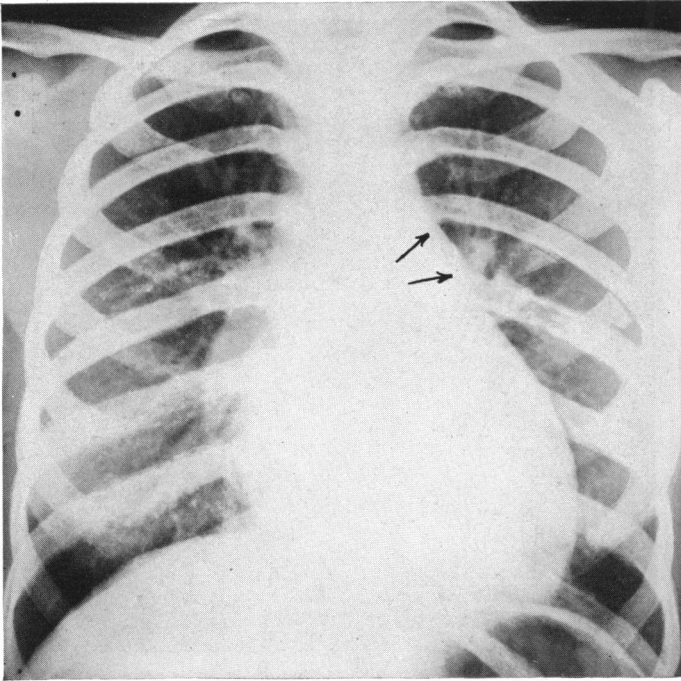


FIG. 16.—Case 4: Seven-foot heart film before operation. Moderate cardiac enlargement. Transverse dimension of heart 12.8 cm. Internal diameter of chest 24.0 cm. Prominence of pulmonary artery indicated by arrows. Just below this is slight fulness in region of left auricle. Vascular congestion throughout lung fields.

precordium, to both axillae and over the back, but was only faintly heard over the neck vessels. At the cardiac apex the systolic element of the murmur appeared to be of the same character as that at the base, but the diastolic component had a different quality. The second pulmonic sound was greatly accentuated. A continuous thrill with systolic accentuation was felt over the pulmonic region. The blood pressure was 124/60.

Laboratory Data.—Roentgenologic examination of the heart showed moderate cardiac enlargement, chiefly left ventricular hypertrophy with slight fulness of the pulmonary artery (Fig. 16). There was considerable enlargement of the left auricle, particularly in its posterior portion. In the hili the pulmonary vessels were slightly dilated. Fluoroscopy showed a very vigorous beat. Transverse dimension of the heart was 12.8 cm. compared to an internal diameter of the chest of 24.0 cm. The vital capacity was 1,800 cc. Venous pressure was 86 Mm. of water. Circulation time, antecubital fossa to tongue,

was increased to 22 seconds. Red blood count 4,940,000. Blood volume by the Gibson technic was increased to 3,950 cc.

There was some question in this case concerning the presence of a complicating mitral stenosis which might be masked by the prominent signs of the patent ductus, but it was felt that the patient's cardiac reserve could be greatly improved by ligating the ductus.

Operation.—December 22, 1938: Under cyclopropane anesthesia, a transverse incision was made just above the breast, dividing the pectoralis major and minor muscles and entering the chest in the second interspace after dividing the second costal cartilage. When the lung was packed away inferiorly an excellent exposure of the aortic arch and pulmonary artery was obtained. After opening the pleural covering of the mediastinum, a vascular and quite dense meshwork of fat and areolar tissue was found in the sulcus between the great vessels. Nearly two hours were consumed in carefully dissecting this

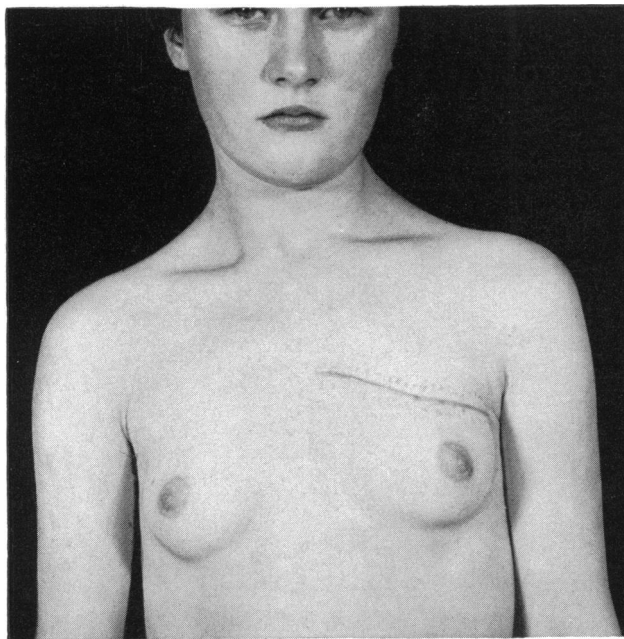


FIG. 17.—Case 4: Postoperative photograph to show position of the operative incision. This transverse section of the supramammary structures and the pectoral muscles does not produce any clinical evidence of impaired lymphatic drainage of the breast.

area in order to avoid hemorrhage. The ductus was finally exposed and was found to be 8 to 9 Mm. in diameter and 5 to 6 Mm. in length. The vessel was firmly occluded with two No. 8 braided silk ligatures. The marked thrill which was previously felt over the entire heart and over the pulmonary artery now completely disappeared. The heart, which had previously been very vigorous and overactive, immediately assumed a quiet and normal pulsation. The diastolic blood pressure immediately increased 25 Mm. of mercury. There were no untoward effects from ligating the ductus. During the operation samples of blood for oxygen content determinations were taken from the aorta and the pulmonary artery before and after ligation of the ductus in order to study the blood flow through the greater and lesser circuits.⁷ The pleural covering of the great vessels was repaired and the chest closed after reexpanding the lung with positive pressure.

Postoperative Course.—There was a mild febrile reaction for four days, following which the temperature was normal. There was some collection of fluid in the left chest which was not aspirated and which disappeared in ten days. The wound healed *per*

SURGERY OF DUCTUS ARTERIOSUS

primam (Fig. 17). The patient was discharged in excellent general physical condition on the sixteenth postoperative day. The cardiac impulse has assumed a normal intensity. The thrill has disappeared. No murmurs can be heard at the apex. A very faint and soft systolic murmur could be occasionally heard over the pulmonic region for three to four weeks, but this has now completely disappeared. The systolic blood pressure has changed very little, but the diastolic pressure has a sustained increase of 25 to 30 Mm. of mercury above the preoperative level (Chart 5). Roentgenologic examination, two weeks after operation, showed a definite decrease in the total transverse diameter of the heart of

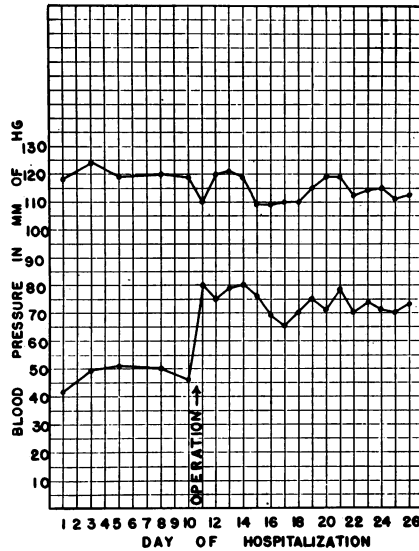


CHART 5.—Case 4: Blood pressure chart during hospitalization. Low diastolic pressure before operation compared to normal diastolic after operation.

0.5 cm. There has been a change in the contour of the heart, with a decrease in the size of the left auricle. There is only slight decrease in the size of the pulmonary artery but the vessel has greatly decreased pulsations on kymographic tracings. The intrapulmonary vessels are definitely smaller and sharper. Reexamination, two months after operation, shows the blood volume to be reduced to a normal value of 3,280 cc., the circulation time to be reduced to a normal of 12 seconds, and the vital capacity to be increased.

SUMMARY AND CONCLUSIONS

The ductus arteriosus has a normal function of shunting blood from the pulmonary artery to the aorta while the lungs are collapsed before birth. If the ductus does not spontaneously close in the first year of postnatal life, the patient is left with a vascular fistula which then permits blood to escape in large quantities from the aorta to the pulmonary circuit. The presence of such a patent ductus is compatible with a long and active life, but it carries with it an increased likelihood of superimposed bacterial endarteritis or of cardiac decompensation resulting from what is essentially an arteriovenous aneurysm.

Surgical obliteration is advocated as a method of avoiding the complica-

tions to which the possessor of a patent ductus is liable. The operative steps for accomplishing this task were studied on postmortem material, were practiced on dogs, and are described herewith. The ductus can be adequately exposed by an approach through the left pleural cavity, entering the superior mediastinum from its left lateral aspect.

The feasibility of this operative procedure is demonstrated by the report of four patients upon whom it was performed without mortality or complications. These results indicate that the ductus can be explored with safety and that it can be permanently ligated in most instances. The success which has thus far been encountered in these surgically treated cases makes it important to recognize the condition, for surgery has much to offer these individuals. When there are no serious complicating cardiovascular lesions, surgical closure of the ductus can be performed with low risk and should ward off the dangers of subacute bacterial endocarditis and cardiac failure.

BIBLIOGRAPHY

- ¹ Abbott, M. E.: Congenital Heart Disease. Nelson's Loose Leaf Living Medicine. Thomas Nelson, New York, 4, 207.
- ² Barclay, A. E., Barcroft, J., Barron, D. H., and Franklin, K. J.: X-ray Studies of the Closing of the Ductus Arteriosus. *Brit. J. Radiol.*, 11, 570, 1938.
- ³ Bohn, H.: Ein Wichtiges Diagnostisches Phänomen zur Erkennung des Offenen Ductus Art. Botalli. *Klin. Wchnschr.*, 17, 907, 1938.
- ⁴ Chester, W.: Patent Ductus Botalli with Subacute Bacterial Endocarditis and Recovery. *Am. Heart J.*, 13, 492, 1937.
- ⁵ Christie, A.: Normal Closing Time of the Foramen Ovale and the Ductus Arteriosus. *Am. J. Dis. Child.*, 40, 323, 1930.
- ⁶ Dry, D. M.: Congenital Aneurysmal Dilatation of Ductus Botalli. *Am. J. Dis. Child.*, 22, 181, 1921.
- ⁷ Eppinger, E. C., Burwell, C. S., and Gross, R. E.: Dynamics of the Circulation in Patients with Patent Ductus Arteriosus. To be published.
- ⁸ Gibson, J. G., and Evans, W. A.: Clinical Studies of the Blood Volume. 1. Clinical Application of a Method Employing the Azo Dye "Evans Blue" and the Spectrophotometer. *J. Clin. Invest.*, 16, 301, 1937.
- ⁹ Graybiel, A., Strieder, J. W., and Boyer, N. H.: An Attempt to Obliterate the Patent Ductus Arteriosus in a Patient with Subacute Bacterial Endarteritis. *Am. Heart J.*, 15, 621, 1938.
- ¹⁰ Gross, R. E.: A Surgical Approach for Ligation of a Patent Ductus Arteriosus. *New England J. M.*, 220, 510, 1939.
- ¹¹ Gross, R. E., and Hubbard, J. P.: Surgical Ligation of a Patent Ductus Arteriosus: Report of First Successful Case. *J.A.M.A.*, 112, 729, 1939.
- ¹² Gross, R. E., Emerson, P., and Green, H.: Surgical Exploration and Closure of a Patent Ductus Arteriosus: Report of Second Successful Case. *Surgery*, in press.
- ¹³ Gross, R. E., Emerson, P., and Green, H.: Surgical Obliteration of a Patent Ductus Arteriosus in a Seven-Year-Old Girl. *Am. J. Dis. Child.*, in press.
- ¹⁴ Holman, E.: Certain Types of Congenital Heart Disease Interpreted as Intracardiac Arteriovenous and Venoarterial Fistulae. Patent Ductus Arteriosus. *Bull. Johns Hopkins Hosp.*, 36, 61, 1925.
- ¹⁵ Mallory, T. B.: Case Records (No. 24222) of the Massachusetts General Hospital—Patent Ductus Arteriosus with Subacute Bacterial Endocarditis. *New England J. M.*, 218, 937, 1938.

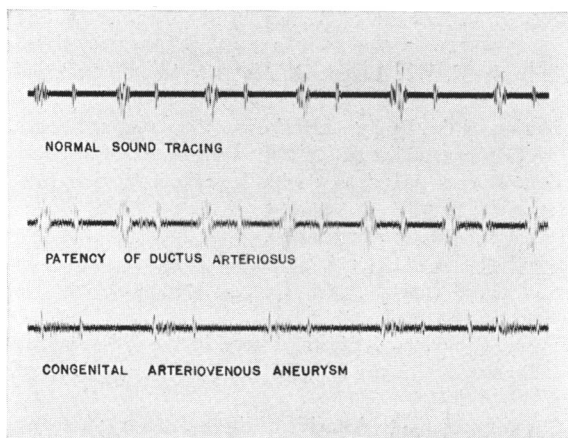
- ¹⁶ Matusoff, I: Congenital Mirror Picture Dextrocardia with Situs Transversus, Patent Ductus Arteriosus and Subacute Bacterial Inflammation. *Am. J. Dis. Child.*, **39**, 349, 1930.
- ¹⁷ Moench, G. L.: Aneurysmal Dilatation of Pulmonary Artery with Patent Ductus Arteriosus: Death from Rupture of Aneurysm into Pericardial Sac. *J.A.M.A.*, **82**, 1672, 1924.
- ¹⁸ Muir, D. C., and Brown, J. W.: Patent Ductus Arteriosus. *Arch. Dis. Child.*, **7**, 291, 1932.
- ¹⁹ Munro, J. C.: Ligation of the Ductus Arteriosus. *ANNALS OF SURGERY*, **46**, 335, 1907.
- ²⁰ Patten, B. M.: The Changes in Circulation Following Birth. *Am. Heart J.*, **6**, 192, 1930.
- ²¹ Perry, C. B.: Patent Ductus Arteriosus; with Superimposed Subacute Bacterial Endocarditis. *Lancet*, **1**, 82, 1933.
- ²² O'Shaughnessy, L.: Personal Communication.
- ²³ Scammon, R. E., and Norris, E. H.: A Statistical Summary of the Data on the Time of Obliteration of the Foramen Ovale, Ductus Arteriosus, and Ductus Venosus in Man. *Anat. Rec.*, **15**, 165, 1918.
- ²⁴ Schaeffer, J. P.: The Behavior of Elastic Tissue in the Postfetal Occlusion and Obliteration of the Ductus Arteriosus (Botalli) in *Sus Scrofa*. *J. Exper. Med.*, **19**, 129, 1914.
- ²⁵ Schlaepfer, K.: Chronic and Acute Arteritis of the Pulmonary Artery and of the Patent Ductus Arteriosus. *Arch. Int. Med.*, **37**, 473, 1926.
- ²⁶ Schrötter, H. von: Über eine seltene Ursache einseitiger Recurrenslähmung, zugleich ein Beitrag zur Symptomatologie und Diagnose des offenen Ductus Botalli. *Ztschr. f. klin. Med.*, **43**, 160, 1901.
- ²⁷ Trimble, W. H., and Larsen, R. M.: A Case of Patent Ductus Arteriosus with Primary Bacterial Pulmonary Endarteritis. *Am. Heart J.*, **6**, 555, 1931.
- ²⁸ Wessler, H., and Bass, M. H.: Persistent Ductus Botalli and Its Diagnosis by the Orthodiagraph. *Am. J. Med. Sci.*, **145**, 543, 1913.

DISCUSSION.—DR. MONT R. REID (Cincinnati, Ohio): I am sure that I voice the feelings of the members of the American Surgical Association when I express my admiration for this splendid and brilliant paper; we are truly grateful to you, Doctor Gross. There can be no doubt that you have made an enduring contribution to the knowledge and art of surgery. That others have thought of and tried unsuccessfully to do what you have reported here to-day, in no way detracts from the careful and painstaking studies you have just recited. That is the common experience of all of us and it is rather to your credit that you were not deterred by the failures of others.

Permit me also to admire the words of caution with which you have surrounded this obvious advance in surgery. If the operation which you have so successfully employed in four cases should for a time become discredited by misuse, it will be no fault of yours. From your laboratory and clinical investigations you have laid down certain rules or standards of procedure which should be our guiding principles until further experience or study warrants a change in them. That changes will come is inevitable, but to have this work discredited by hasty or unwise use would be deplorable.

Having in mind the criteria of operability which you have proposed, I have reviewed the records of 15 living cases of patent ductus arteriosus. Of these, 11 appear to be uncomplicated by other abnormalities; two, to have patent interventricular septa; and two, to have pulmonary stenosis. Of this entire number, only one appears to satisfy fully your requirements for operative intervention. He is a poorly nourished boy, age 11, exhibiting the typical murmur and thrill; the accentuated pulmonary conus; left ventricular enlargement; low diastolic pressure; free of evidence of other cardiac defects; dyspnea;

and no evidence of bacterial endarteritis. There are two other cases which almost meet your criteria of operability. In this series, there is one child, who at the age of six met all of your requirements but who now, at the age of



GRAPH 1.—Sound tracings of a normal heart; a heart with patent ductus arteriosus; and of a congenital cirsioid aneurysm.

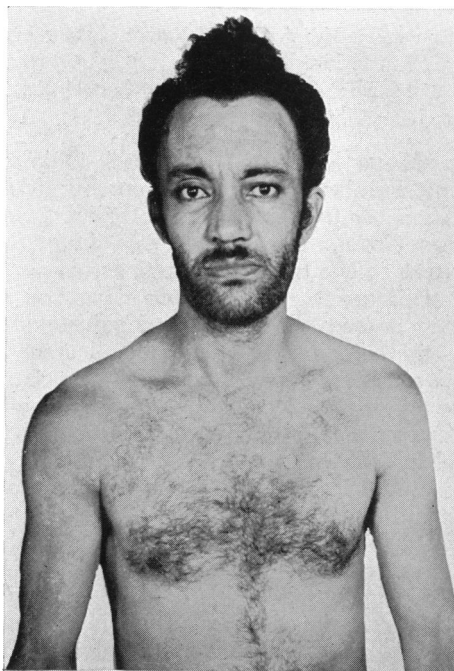


FIG. 1.—A 33-year-old colored man with patent ductus arteriosus, with typical clinical findings, and in apparently excellent health.

15, appears to be perfectly well, although the ductus is open. Should we operate? On the other hand, another patient who, at the age of three, seemed, by your standards, to justify an operation, is now, at the age of seven, dying

SURGERY OF DUCTUS ARTERIOSUS

from bacterial endarteritis. In view of Hamman's experience with a malignant vegetative arteritis at the site of an arteriovenous fistula, I cannot help but question your logic in refusing to operate for a vegetative lesion in association with a patent ductus arteriosus. There seems, undoubtedly, to be a causal relationship between patent ductus arteriosus and the occurrence of vegetative endarteritis, and it appears logical to me to hope that the surgical elimination of the patent duct might have some beneficial effect in promoting the healing of the vegetative lesion.

TABLE I

SUMMARY OF 15 LIVING CHILDREN WITH CLINICAL DIAGNOSIS OF PATENT DUCTUS ARTERIOSUS

	Primary Lesion	Other Complicating Defects	
		Patent Interventricular Septum	Pulmonary Stenosis
No. of cases.....	11	2	2
Age range—1 to 16 years			
Average time followed— 4 years 5 months			
Cyanosis:			
Slight.....	3	0	0
Moderate.....	0	2	1
Exertion dyspnea:			
Slight.....	3	0	1
Moderate.....	2	0	0
Marked.....	0	0	1
Peripheral edema.....	1	0	0
Delayed development.....	2	1	1
Clubbed fingers.....	1	0	0
Precordial bulging.....	1	0	0
Corrigan's pulse.....	0	0	1
Low diastolic pressure.....	4	1	1
Systolic thrill.....	3	1	0
Murmur:			
Typical.....	11	2	1
Systolic.....	0	0	1
X-ray:			
L. V. enlargement.....	8	2	1
Accentuated pulmonary conus.....	4	1	0
Abnormal EKG.....	0	0	2
Restricted activity required:			
Moderate.....	3	2	1
Marked.....	1	0	1
Living.....	10	2	2
Case developed bacterial endocarditis at age seven..	1 (probably dead)	0	0
Cases satisfying criteria for operation:			
Definite.....	1	1	0
Probable.....	2	0	0

In a series of 8,300 autopsies, performed at the Cincinnati General Hospital, there are recorded 489 instances of patent ductus arteriosus. Of these, 231 were noted in stillborn infants and are, therefore, of no significance.

There were, however, 258 cases in which death occurred after birth. Of this number, 176 deaths occurred within one week and all, except one, within eight months. On analyzing the causes of death, I was impressed by the very high incidence of pulmonary atelectasis. This is an interesting observation, although I am not prepared to discuss its significance. There was one girl who died from a brain abscess at the age of 14. The clinical history was typical of a bacterial septicemia, although at autopsy no vegetative endarteritis was noted at the site of the patent ductus.

We now have under observation a colored man, age 33, who has a typical patent ductus arteriosus (Fig. 1). At the base of the heart there is a loud thrill and typical machinery murmur, particularly in the pulmonic area. The sound tracings are typical, though more intense, of a congenital cirroid aneurysm (Graph 1). There is an enlarged pulmonary conus, slight left ventricular hypertrophy. Clinically the patient is a well man. Should he be operated upon?

I cite this case to give Doctor Gross the chance to reemphasize the fact that a diagnosis alone of a patent ductus arteriosus does not warrant an operative procedure.

I wonder if many children who are diagnosed as having heart disease and later "outgrow it" do not really have some congenital defect as patent ductus arteriosus which closes spontaneously.

Finally, there are a few minor statements to which I must take exception. The "very tight" tying of the ligature about the ductus may lead to a rupture of the vascular coats and a subsequent fatal hemorrhage; gentle approximation of intimal surfaces would appear to me to be safer. I cannot subscribe to his belief that a persistence of a to-and-fro murmur means leakage through the wrinkled spaces of a collapsed ductus. It would appear to me that the operation for ductus arteriosus is ideal for the employment of silk ligatures and sutures throughout the procedure. I believe it would lessen the incidence of pleuritic effusions.

These minor disagreements must in no sense be construed to detract from my great admiration of this splendid piece of work.

DR. ELLIOTT C. CUTLER (Boston): It is a privilege to congratulate Doctor Gross on this piece of work as well as to congratulate the Association that a new furrow in the field of cardiac surgery has now been plowed. There are those, I have heard, who think I played a rôle in this work, and I should like to disabuse their minds of that. It is possible that Doctor Gross, since he has been with us a long time, may have known that I did contemplate, in the years when I was active in a new field in cardiac surgery, playing with the idea that the patent ductus might be ligated. But I saw an old man of 72 years of age with a loud machinery murmur and carefully studied him physiologically for some months, and decided that people who had patent ductus might live to adult life and that surgery was unnecessary.

As further evidence of my early interest in this matter is the fact that the first slide shown by Doctor Gross represented the situation in a child I studied in Cleveland and even contemplated operating upon.

Whatever credit there is in this work belongs entirely to Doctor Gross.

It is proper to point out, I think, since we are all interested in the education and training of competent surgeons, the backgrounds which give rise to this form of work, the form of work which your President in his masterful

presentation to the Society this morning pointed out as the type of work which the organizations of learned surgical groups should foster and encourage. This piece of work, as I look upon it, would not have come out unless Dr. W. E. Ladd, of the Children's Hospital, and I had sort of a joint show where we share the same interns and have a joint service that provides for the young man adequate surgical training in children's surgery as well as in adult surgery. Moreover, this work might not have been accomplished, unless in the pediatric service of the Children's Hospital in Boston there had not been competent, wide-awake and courageous young pediatricians, because the surgeon alone, when he enters such a field, must have compatriots to help him. Moreover, it could not have occurred unless he had had at hand a fully equipped surgical laboratory, because one dares not enter into new fields where there are no signposts unless one can gain experience first upon animals. And, naturally, and finally, there must be some kind person to provide the patients.

This type of forward work in surgery represents the things that come from centers where there can be, for the growing young surgeon, all facilities—the laboratory, the intelligent and courageous colleagues in his medical service, and the patients to work upon. Moreover, such a work gives a tremendous stimulus to a great group of people.

The roentgenologist now is stimulated to make the diagnosis by a more competent study of the pulmonic conus. The pediatrician is stimulated to find patients who can be saved, and the surgeon, and the anesthetist, too, are studying better what is the best approach and what is the best anesthetic.

Doctor Gross, I hope, will elaborate upon reasons why the operation is desirable. In my time I had no knowledge of the fact that the majority of children born with patent ductus either die young or succumb early to cardiac failure or endocarditis. I believe he can give us statistical data revealing the natural mortality in this group, a mortality which in view of his experience might be, by surgical means, greatly lowered.

DR. DAVID CHEEVER (Boston): I cannot refrain from adding my congratulations to Doctor Gross for his accomplishment of this remarkable surgical feat, and also to the Association for becoming the vehicle of its transmission to the surgical world.

I want to point out something that is a favorite viewpoint of many of us, all of us, in fact, and that is the transcendent importance of the basic sciences in the performance of such a thing as this—physiology and anatomy.

You noticed how Doctor Gross brought out the essential points in the topographic anatomy, which enabled him to accomplish this procedure with so much safety and precision. Now I admit, of course, that ligation of a patent ductus arteriosus is not likely to be an emergency procedure, so I imagine that anybody would have ample opportunity to look up his anatomy before performing it. I do not believe that Doctor Gross would feel obliged to do that, as a matter of fact, because, of course, it was the good fortune of the Harvard Medical School, where anatomy is still considered important, to be his alma mater.

DR. ROBERT E. GROSS: In answer to Doctor Reid, I do not believe that the best way to obliterate the patent ductus has been found. I think it is a poor surgical procedure to ligate a vessel in continuity. However, in a small place between the great vessels in the mediastinum where space is at a premium, it appears to be impossible to doubly tie and divide the ductus. I had hoped to do it in one case in which the ductus was a little longer than in the other instances, but it appeared to carry with it too much danger.

Double ligatures have been used on the last two cases. It would probably

be a better procedure to doubly ligate, put the ligatures as far apart as possible, and to inject between them some sort of sclerosing fluid so that the intima would be destroyed and the vessel become thrombosed.

It is difficult to estimate the prognosis in individuals with a patent ductus arteriosus, because people who die of this lesion are apt to be reported, whereas others who go through life without any complications are rarely reported in the literature. The only statistics we have available at present are those of Maude Abbott, who collected, among her congenital cardiac cases, 92 individuals who had a patent ductus arteriosus without other lesion. About one-quarter of these lived to an elderly life, without any important complications. About one-quarter of them died of subacute bacterial endarteritis, and almost half of them died of cardiac failure.

I do not believe that all individuals in whom the diagnosis is certain should be operated upon. I think they should be followed for a number of years, because, as Doctor Reid has pointed out, there are individuals who will close off the ductus later in life or who will compensate for a small shunt. I have in mind several youngsters I have seen in the outpatient department who, as we have followed them through a period of years, show a heart which is slowing down, and which is not enlarged; they have no signs of cardiac failure, and they are developing normally in their physical stature. I think this type of individual should be left alone, because he may eventually close off his ductus, and the danger of letting him go untreated is less than the danger of operative intervention.

Regarding the age at which these people die, in Maude Abbott's series of 92 cases, the average age at death was 24 years.

Regarding advisability of operation in some of the cases that Doctor Reid mentioned, it is hard to tell an individual who is getting along fairly well that operation may be an advisable procedure. In the first case that we considered operating upon we ourselves thought the dangers of operation would be too great, and operation was deferred. However, the child was back in the hospital within a few months and died of subacute bacterial endarteritis. Thus, the fact that a patient has lived to 33 years, or one is 18 years of age without any particular trouble, is no indication that such an individual is going through the remainder of life without difficulty.

Regarding Doctor Reid's patient 18 years of age, who does not have endocardial infection, it is possible that such a patient may return later with subacute bacterial endarteritis. I say this because in the last few months I have been consulted in regard to three patients who had lived into the third decade without any evidence of cardiac disability, and all of them now have a fatal bacterial endocarditis.

I originally held the impression that patients who have subacute bacterial endarteritis should not be operated upon, because I felt that the manipulations in the region obviously would dislodge some of these vegetations and produce emboli. But since then, I have come to believe that some individuals with supervening subacute bacterial endarteritis should possibly be explored. I am not quite sure of this stand as yet, but it is possible that if you can close off the shunt you may stop the swirling of blood and the growth of the vegetations. Then, sulfapyridine or sulfanilamide would have a better chance to destroy those bacteria which are present.