

611.25:611.018.86

NERVES AND NERVE ENDINGS IN THE VISCERAL PLEURA OF THE CAT.

BY A. I. G. McLAUGHLIN.

(From the Unit Laboratories, University College Hospital Medical School.)

(Received September 5, 1933.)

THE presence of nerves in the visceral pleura was mentioned by Remak, Bourgerie and by Kolliker about the middle of the last century, but few thorough anatomical studies had been carried out until Larsell began his work on the innervation of the lungs and pleura. Hoffman [1920], in studies on the human pleural membrane, pointed out the marked contrast between the richly innervated parietal pleura and the sparsely innervated visceral pleura but made no reference to nerve endings. Larsell [1921, 1922, 1923, 1928] and his colleagues in the rabbit, dog and pig were able to demonstrate nerves and nerve endings in the visceral pleura by means of an *intra vitam* methylene-blue technique. In these lower animals they found that the nerves from the pulmonary plexuses enter the lung to form two main plexuses, the bronchial and the peri-arterial. From the latter, myelinated nerves pass to the visceral pleura. These fibres run for some distance in the pleural membranes as fairly compact trunks and then break up into smaller branches or into individual fibres. The main trunks follow the margins of the interlobar fissures and the smaller branches do not wander far from this general region. They found that the endings of these nerves are small and simple in the rabbit but larger and more elaborate in the dog. They are seen at the ends of the myelinated fibres in the form of branching twigs which end in knob-like expansions. The myelin sheath extends to within a short distance of the nerve ending. Such endings are found near the margins of the lobes especially near the hilum, and they become fewer and farther apart in proportion to the distance from the hilum. None were found on the costal or diaphragmatic surfaces of the pulmonary pleura. The nerve fibres probably come from the cells of the upper thoracic root ganglia through the white rami communicantes of the corresponding thoracic nerves, the sympathetic trunk, the middle and

inferior cervical ganglia and finally through the pulmonary plexuses. Larsell holds the opinion that the vagus does not have any part in the innervation of the visceral pleura, because with Mason [Larsell and Mason, 1921] he showed that in the rabbit after section and degeneration of the vagus on one side, there remain as many nerve endings (of the type he describes) in the visceral pleura on the affected side as were found on the sound side.

In a more recent communication with Dow [Larsell and Dow, 1933] on the innervation of the human lungs and pleura, Larsell showed that the plexuses and ganglia of the human lung are in general similar to those of the dog and rabbit, but in addition nerve trunks are present in the interlobular septa. Fibres from these nerve trunks reach the visceral pleura especially near the hilum, but no nerve terminations of the afferent type are found. He considers this failure to demonstrate nerve endings to be due to difficulty of staining rather than to their absence.

In my studies of the innervation of the visceral pleura of the cat I used a modification of Larsell's *intra vitam* methylene-blue technique, and I have been able to demonstrate in the pleura nerves and nerve endings which differ markedly in type and position from those which Larsell has described in the dog and rabbit. The nerve endings are of a type which has not been previously described although they bear some resemblance to the smaller encapsulated endings found in the mesentery. They are found in the pleura all round the lobe from the hilum to the apex and are quite as numerous at the apex as they are at the hilum. They are seen in large numbers on the costal and interlobar surfaces of the lobe as well as near the hilum.

The nerve fibres in the pulmonary pleura of the cat are also more numerous than those which Larsell describes in the dog and rabbit. In the cat three different categories of nerve fibres are seen. Again, they are found all round the lobe and not concentrated near the hilum. (a) A fine plexus of unmyelinated nerves (Pl. I, fig. 2 and Pl. II, A) is seen just under the mesothelial surface of the pleura and running parallel with it. The endings about to be described in detail are attached to the nerve fibres of this plexus. (b) Larger bundles of myelinated nerves (Pl. II, B) which appear to be coming from the interlobular septa; when they reach the pleura they run in a diagonal direction across it, but at first more or less parallel with it, finally ending near the mesothelial surface. From the main trunk smaller branches are given off at intervals to form a fairly fine network. So far I have not been able to trace any connection between these bundles of myelinated nerves and the fine superficial

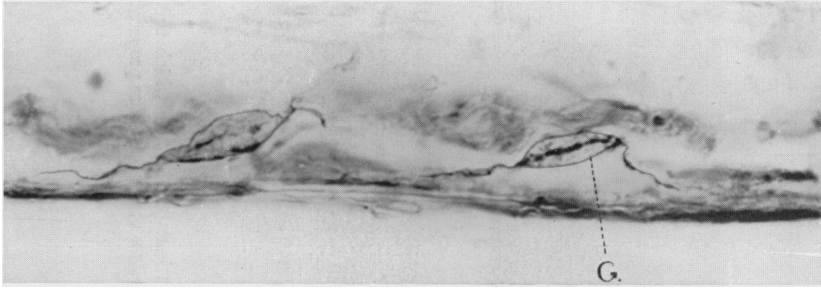


Fig. 1. Photograph of two bulbs with nerve fibres near the epithelial surface of the viscera. pleura. Cat. *Intra vitam* methylene blue. $\times 1312$.

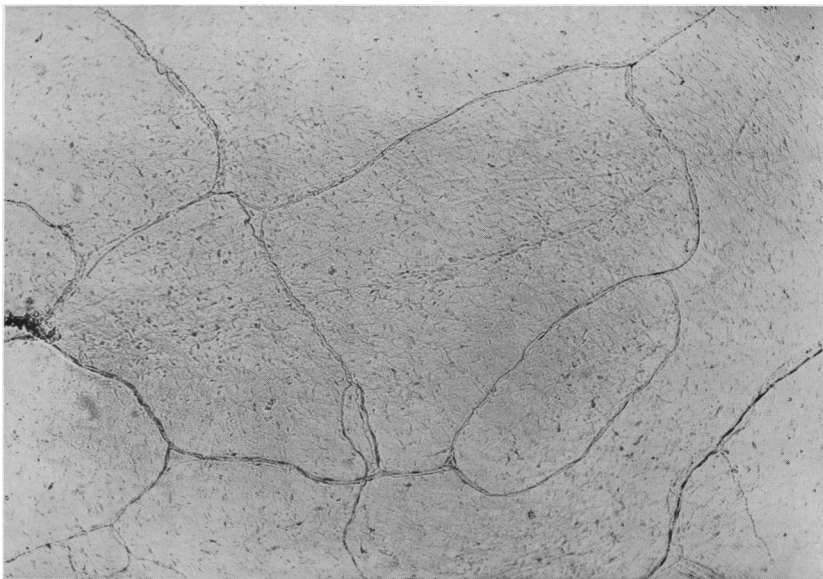
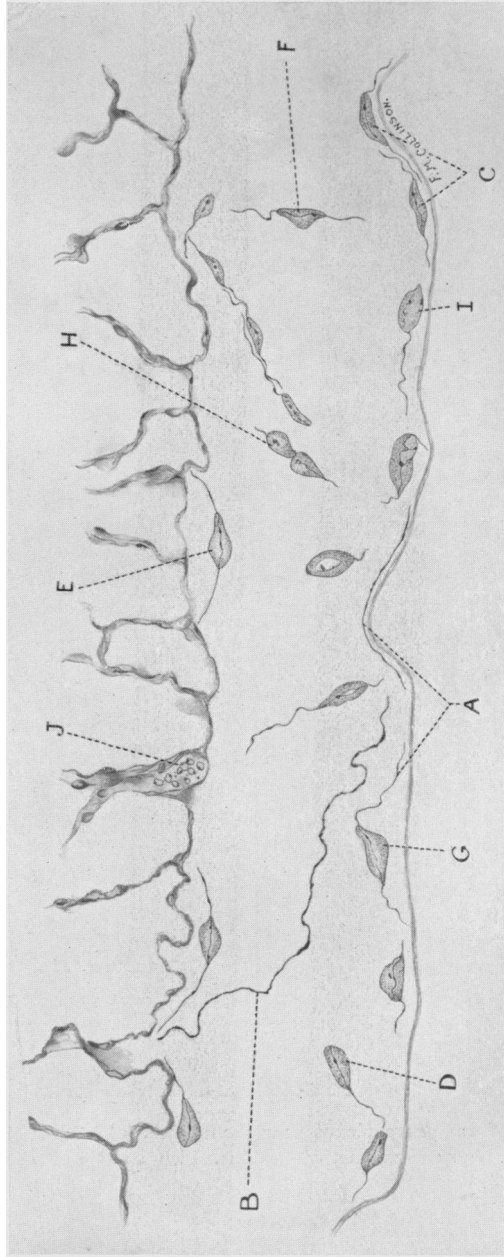


Fig. 2. Photograph of fine nerve plexus near the mesothelial surface of the visceral pleura of the cat. *Intra vitam* methylene blue. Pleura stripped off the lung and mounted flat. $\times 64$.

To face p. 102



Composite drawing of several microscopic fields of the visceral pleura of the cat showing the various positions in which the end corpuscles and nerves are found. (For explanations of letters A-J see text, pp. 2 and 3.) *Intra vitam* methylene blue preparation. Paraffin sections 20-60. \times about 800.

plexus just mentioned. (c) In the third category are the nerves accompanying the small blood vessels found in the pleura, one group running close to and parallel with the vessel and the second group consisting of fine varicose fibrils on the actual vessel wall. Nerve trunks (Pl. II, *J* in cross-section) are present in the interlobular septa.

The nerve endings (see Pl. I, fig. 1 and Pl. II) are leaf-like corpuscles about 15μ long and 7μ wide, most of which are seen lying immediately under the mesothelial surface of the pleura, their long axes being parallel with the surface (Pl. II, *C*). Others, attached to fibres coming from the fine superficial nerve plexus, are seen placed at about an angle of 45° to the surface and deeper in the substance of the pleura (Pl. II, *D*). In the latter instance the corpuscle is wider and not so flattened as those lying just beneath the surface. A few similar corpuscles attached to nerve fibres are found near the pulmonary edge of the pleura (Pl. II, *E*), and occasionally a corpuscle is seen on a fibre running across the pleura with its long axis at right angles to the surface (Pl. II, *F*). Those near the surface are found in groups of three or four all round the periphery of the lobe.

The relationship of the fibres to the corpuscles varies. In some instances the fibre is seen to run parallel with the mesothelial surface, and then swing away into the substance of the pleura, runs through a corpuscle and returns to the surface to run parallel with it (Pl. II, *G*). In other instances the fibre runs through a corpuscle into another placed close to it (Pl. II, *H*), somewhat like the arrangement described by Sheehan [1933*a*] in the Pacinian corpuscles of the mesentery. Finally in many others the fibre appears to end definitely in the corpuscle (Pl. II, *I*).

Each corpuscle is ovoid in shape with pointed ends. The nerve fibre on entering the corpuscle appears to run into a spindle-shaped area and divides into a number of finer fibrils. I have not yet been able to determine whether this central spindle is made up entirely of nerve fibrils or whether it is a capsule enclosing the actual nerve ending. One definite central fibril runs through the centre of the spindle, and on its course is frequently seen a larger deeply staining varicosity placed usually at the junction of the distal one-third with the proximal two-thirds of the length of the corpuscle. Outside the central spindle the corpuscle is packed with large non-staining granules. The outer envelope is thin and sharply defined.

The origin of these nerve endings has still to be determined. At first sight they appear to be afferent sensory endings and they are probably concerned in the reception of afferent impulses for the reflexes of respiration. In structure these nerve endings show a certain resemblance to the

group of encapsulated nerve endings which includes the Vater-Pacinian corpuscles, Golgi-Mazzoni bodies and the corpuscles of Herbst. In the mesentery of the cat the bulbs are of two types [see Sheehan, 1933*b*], the first being the large laminated Pacinian corpuscles which are about $\frac{1}{2}$ -1 mm. in length and can be seen with the naked eye, and the second type being smaller (about 1/100 mm. long) non-laminated bulbs. The end-bulbs in the visceral pleura just described are about 15μ in length and can only be seen satisfactorily with an oil immersion lens. It is clear that if these corpuscles in the visceral pleura are to be placed in the same category of encapsulated nerve endings there is a marked difference in the relative sizes of the mesenteric and pleural end-bulbs in the cat. Those in the pleura are all approximately of the same size. A further communication as to the origin and probable function of these pleural end-bulbs will be made.

SUMMARY.

Nerves and nerve endings in the visceral pleura of the cat are described. Their distribution is more extensive than that previously described in man and the lower animals. The encapsulated endings, which show points of resemblance to those found in the mesentery of the cat, differ from them in that they are smaller and of comparatively constant size. Such encapsulated endings have not been previously described in the visceral pleura.

This work has been carried out with the aid of a grant from the Medical Research Council. I am much indebted to Prof. J. P. Hill and Dr C. J. Hill for advice on histological technique.

REFERENCES.

- Hoffman, V. (1920). *Mitt. Grenzgeb. Med. Chirurg.* **32**, 317.
 Larsell, O. and Mason, M. (1921). *J. comp. Neurol.* **33**, 509.
 Larsell, O. (1922). *Ibid.* **35**, 97.
 Larsell, O. (1923). *North-west Medicine*, Sept.
 Larsell, O. (1928). *Phi Beta Pi Quarterly*, May.
 Larsell, O. and Dow, R. S. (1933). *Amer. J. Anat.* **52**, 125.
 Sheehan, D. (1933*a*). *Lancet*, i, 409.
 Sheehan, D. (1933*b*). *J. Anat.* **67**, 240.