

CEA Monitoring of Palliative Treatment for Colorectal Carcinoma

MIGUEL A. HERRERA, M.D., T. MING CHU, PH.D., E. DOUGLAS HOLYOKE, M.D., ARNOLD MITTELMAN, M.D.

Palliative treatment was applied to 131 cases of unresectable or palliatively resected colorectal carcinoma being monitored with serial CEA determinations. There were 84 instances of disease progression with 67 (80%) of them showing an increase in CEA above pretreatment levels or maintaining high levels, and 17 (20%) showing a fall when compared to pretreatment values or maintaining low initial values. There was a clear-cut regression of the disease in only 9 instances. In all 9, the CEA clearly dropped or maintained low values throughout the period of regression. No patient in regression had a rise or maintained an elevated CEA level. These changes in CEA followed closely the clinical response of our patient to the use of a particular agent, although for the Nitrosourea compounds there may be a tendency to lower the CEA regardless of the patient's tumor response to the drug. This could be due to the fact that the Nitrosoureas produce a diffuse block of cellular activity, both at the nucleus and cytoplasm; while other compounds act as alkylating agents or by inhibition of enzymes involved in the metabolism of nucleic acids (i.e., 5-FU inhibiting thymidylate synthetase). In general, longer survival was found in those patients who had initially lower levels of CEA as compared to those with high initial levels. The patients with a favorable CEA response to the treatment (falling CEA or maintained low value), even in many who did not show a clinical response had a longer survival than the group with rising or stable high levels. The main value in CEA monitoring of patients resides in its correlation with the amount of disease present and then its ability to detect progression of tumor mass which is not clinically measurable.

MEASUREMENT of the level of carcinoembryonic antigen (CEA) in serum or plasma is of value when employed as an adjunctive diagnostic tool in several malignancies, particularly large bowel cancer. In colon cancer, elevation of serum CEA has been found to be related to the mass of tumor present.^{3-5,8,12,14,15} To date, most evidence indicates that this CEA assay is of little

*From the Department of Laboratory Medicine and Surgery,
New York State Department of Health,
Roswell Park Memorial Institute,
Buffalo, New York 14263*

practical value in screening the general population for occult malignancy. However, in our experience, the test appears useful when used to determine prognosis and to monitor patients with resectable colorectal carcinoma for early recurrence.^{2,3,5,6,9-11,17,20} The usefulness of CEA as a monitor in palliative treatment of tumors has been suggested from several studies with breast cancer,^{1,19} and in some series with neuroblastoma¹⁵ and gastrointestinal adenocarcinomas.^{6,7,13,15,17}

Therefore, in this study, we have examined the usefulness of CEA as a monitoring tool in the management of patients under treatment for unresectable colorectal carcinoma. We have investigated the correlation between changes in the CEA value and the clinical response of our patients to palliative therapy.

Material and Methods

One hundred and thirty-one patients with unresectable histologically proven colorectal adenocarcinoma underwent palliative treatment and 103 of these individuals were followed for longer than 3 months with at least two plasma CEA determinations. A total of 1220 CEA determinations was carried out with an average of 9 samplings per patient. When possible, patients were clinically grouped as demonstrating either progression or regression, with some patients having a clinical course that classified them as in progression at one time and as in regression at another. There were some patients in whom any clinical changes which occurred while they were

Submitted for publication February 7, 1976.

Reprint requests: E. Douglas Holyoke, M.D., Department of Surgery, Roswell Park Memorial Institute, 666 Elm Street, Buffalo, New York 14263.

being observed were so subtle that they could not be classified as either showing progression or regression.

We defined progression rigorously as identification of a measurable lesion with at least a 50% increase in size when compared to any previous measurement, either by direct examination of the lesion or by the use of scan or x-ray. The majority of the lesions were confirmed as metastases either by previous exploration or post-mortem examination. The appearance of any new lesion was also called progression of the disease.

In this study, only regression was considered as a positive response to the treatment. The term regression was applied to a more than 50% reduction in size of a measurable lesion by the same standard as for progression. Also a disappearance of lesions of more than 2 cm in diameter was designated regression. A mixed picture with some lesions showing progression and other regression was called progression. Changes in the general condition of the patients, laboratory changes, change in liver size without exploration and/or biopsy confirmation of metastases were not considered as progression or regression. Patients were treated with different modalities of therapy: chemotherapy with 5-FU and Nitrosourea alone or combined with radiotherapy were the principal means of treatment.

Patients treated with 5-Fluorouracil (5-FU) received a loading dose of 12.5 mg/kg/day i.v. for 5 days followed by a weekly i.v. dose of 15 mg/kg. The Nitrosoureas were given orally in a single dose of 175 mg/M² repeated at 6-week intervals, 1-(2-chloroethyl)-3-4-methylcyclohexyl-1-nitrosourea (MeCCNU) and 1-(2-chloroethyl)-3 cyclohexyl-1-nitrosourea (CCNU), or 40 mg/M² i.v. every 6 weeks 1,3 bis(2-chloroethyl)-1-nitrosourea (BCNU).

Radiation therapy consisted of 5,000 to 6,000 rads as the tumor dose, 200 rads/day were given in a split course

of 3,000 and 3,000 rads with a two-week rest interval. Palliative resection usually consisted of removal of the primary lesion and proximal colostomy. CEA values were called initially low when they were below 2.5 ng/ml; elevated between 2.5–10 ng/ml and high over 10 ng/ml.

Results

In our group of 131 patients with unresectable metastatic colorectal carcinomas, palliative therapy was monitored by serial CEA determination. Palliation consisted of: *a*) surgical resection in 36 instances (28 were receiving chemotherapy, radiation therapy or combination of both within 3 months of surgery while in 8, the only treatment consisted of palliative surgery); *b*) 5-Fluorouracil therapy in 75 patients. In this group, 37 had had no other treatment for the previous 3 months, 38 patients had, prior to 5-FU some sort of therapy within three months of being started on 5-FU either before referral to RPMI or here. Eighteen had reductive surgery alone, 20 had reduction surgery plus other method of palliation, (radiation in 13, combination chemotherapy in 6, radiation plus combination chemotherapy in one); *c*) other chemotherapy alone or in combination in 60 patients: Nitrosoureas alone, 17 patients; 6 Thioguanine (6 DTG) alone, 10; B₂ Deoxythioguanosine (B-2 DTC) alone, 7; Multiple forms of combined chemotherapy, 26; and *d*) radiation therapy in 21 individuals, (18 had 5-FU added to the course of radiation therapy while in 3, radiation therapy was the only modality of treatment). Nine instances of documented favorable response to therapy are individually reported. Each of these clinical regressions was accompanied by a fall of (present) pretreatment levels of CEA or the persistence of previously low levels. The observed instances of progression (84) showed stable high levels or a rise in CEA in 67 (80%) while compared to the pretreatment values, but in 17 instances (20%) the CEA values fell or remained low despite evidence of disease progression.

Our data confirm what has been suggested by previous studies from this Institution^{1,2,6,11,15} and by Skarin et al.¹⁶ in their 20 reported cases of colonic malignancy as well as by Mulcare and Lo Gerfo¹³ in another 5 patients.

Chemotherapy

5-Fluorouracil. Seventy-five patients were treated with 5-FU for at least 3 months and followed with at least 2 CEA determinations during the period of treatment (Table 1).

CEA values before treatment were high in 41 patients, elevated in 16 and low in 18 (Table 2). The mean survival of the whole group was 11 months; however, the subgroups of low or elevated pretreatment CEA had a 14-month survival while the group with high CEA had a survival of 8 months.

TABLE 1. Pattern of Change in CEA in 75 Patients with Palliative Treatment with 5-FU for Colorectal Carcinoma

	No. Patients
CEA did not decrease significantly or remained high	48
Elevation immediately after treatment	20
Became elevated after a brief drop	17
Did not change (stayed elevated)	10
CEA did decrease significantly or remained low	28
CEA fell and remained low	12
CEA fell after a brief rise	13
Did not change (stayed low)	3
Total	78

TABLE 2. CEA Response to 5-FU Chemotherapy

Pretreatment* Values	No. Pts.	Survival Entire Group	No. CEA Responders	Survival CEA Responders	Clinical Responders
Low	18	14 mon	12	14 mon	4
Elevated	16	14 mon	2	18 mon	1
High	41	8 mon	15	9 mon	3
Total	75	11 mon	29	12 mon	8

* Low (<2.5 ng/ml); Elevated (2.5 to 10 ng/ml); and High (>10 ng/ml).

CEA fell in response to treatment in 12 of 18 patients with low initial values, in 2 of 16 patients with elevated pretreatment values and in 15 of 41 patients with initial high values. The total number of patients who responded to therapy with 5-FU with a CEA fall was 29 with a survival averaging 14 months for the initially low sub-group, 18 months for the elevated sub-group and 9 months for the high group. Of the 8 clinical responders out of the 75 patients studied, four belonged to the sub-group with initially low values; one had an initially elevated value and 3 had high initial values (Table 2). The 46 patients whose CEA values did not respond favorably to treatment and who have died, survived a mean of 10 months. The 21 patients whose CEA fell, but who demonstrated no clear-cut clinical response and who have died survived a mean of 10 months.

There are 22 patients (22/75) who are still alive and being followed from 4 to 36 months with a mean survival of 14 months. Eleven are in the group of 29 (11/29) "CEA responders", i.e., patients whose CEA plasma levels fell even though there was no clinical regression with a followup from 5 to 36 months with a mean followup of 17 months. Five of the survivors to date are in the group of clinical responders, with followup from 6 to 36 months with a mean of 21 months. There are only 11 patients (11/46) still alive among the 46 patients whose CEA values did not respond favorably to the therapy, followup from 4 to 20 months with a mean of 9 months. From these figures, we can predict that in the future, the survival of the CEA responders will be further prolonged as compared to the non-responders.

Among the 8 patients receiving 5-FU who showed disease regression, 4 received also radiotherapy; 3 were given combination chemotherapy and one patient was given 5-FU by hepatic artery infusion.

Nitrosoureas. Nitrosourea compounds (CCNU, MeCCNU and BCNU) were used as the sole therapeutic agent in 17 patients, usually following a failure to 5-FU treatment.

The pretreatment values were low in 2 patients, elevated in 2 and high in 13 (Table 3). The average survival for the whole group was 5 months; but the patients with a low initial value had a survival of 5 months,

TABLE 3. CEA Response to Nitrosoureas Chemotherapy

Pretreatment Values	No. Pts.	Survival Entire Group	No. CEA Responders	Survival CEA Responders	Clinical Responders
Low	2	5 mon	1	8 mon	None
Elevated	2	12 mon	2	12 mon	None
High	13	4 mon	9	7 mon	1
Total	17	5 mon	12	8 mon	1

the ones with elevated values survived an average of 12 months while initially high values were accompanied by a mean survival of 4 months.

The CEA response to the therapy showed 12 patients maintaining low values or dropping their initial values. The combined survival of the CEA responders was 8 months as compared to the mean of 3 months for the non-responders. There was only one patient who showed a clinical response (regression) and this patient belonged to the group with high initial value with a post-treatment drop of CEA levels and she survived 16 months.

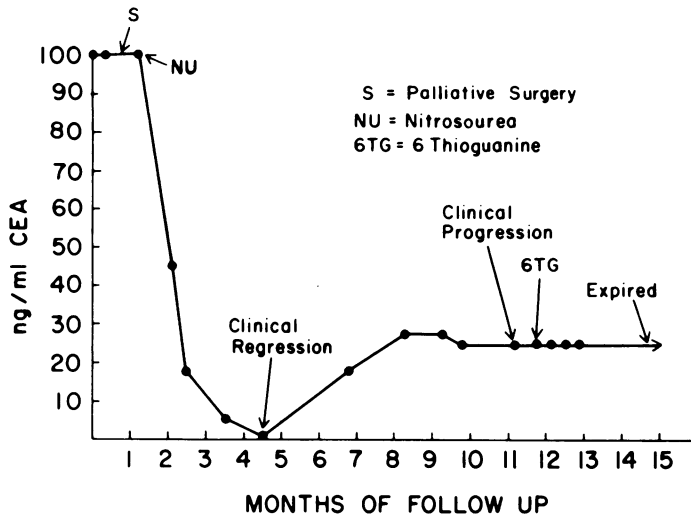
Radiotherapy

Twenty-one patients received radiation therapy for their surgically incurable colorectal carcinoma (Table 4). In 18 of them, 5-FU was added to the radiation course and in 3 radiation was used as the only therapeutic modality. The initial values were low in 7 patients, elevated in 6 and high in 8 with an average survival of 12 months for the whole group. The survival for patients with low initial values was 15 months. For the subgroup with elevated initial values, it was 12 months and for the patients with a high initial value, it was 10 months.

There were 13 CEA responders to radiation, 5 in the subgroup of low initial value; 3 in the subgroup of elevated initial value and 5 in the subgroup of high initial value. The average survivals for the whole group of CEA responders was 14 months; (17 months for the initially low; 14 months for the elevated and 12 months for the initially high CEA subgroup). The 4 clinical responders were among the 13 CEA responders of whom

TABLE 4. CEA Response to Radiotherapy

Pretreatment Values	No. Pts.	Survival Entire Group	No. CEA Responders	Survival CEA Responders	Clinical Responders
Low	17	15 mon	5	17 mon	3
Elevated	6	12 mon	3	14 mon	None
High	8	10 mon	5	12 mon	1
Total	21	12 mon	13	14 mon	4



Patient 1

FIG. 1. Drop in CEA after reductive surgery and chemotherapy CEA levels began to rise prior to clinical evidence of progression.

3 belonged to the initially low subgroup with survival of 12, 20 and 21 months, with the last 2 still alive, and one to the initially high subgroup (alive at 24 months followup visit).

Palliative Resection

In 36 patients in this group of 131 patients, palliative resection was carried out. Most often this consisted of the removal of primary disease in the face of extensive metastases. Perhaps because of the considerable amount of metastatic tumor present, these resections usually did

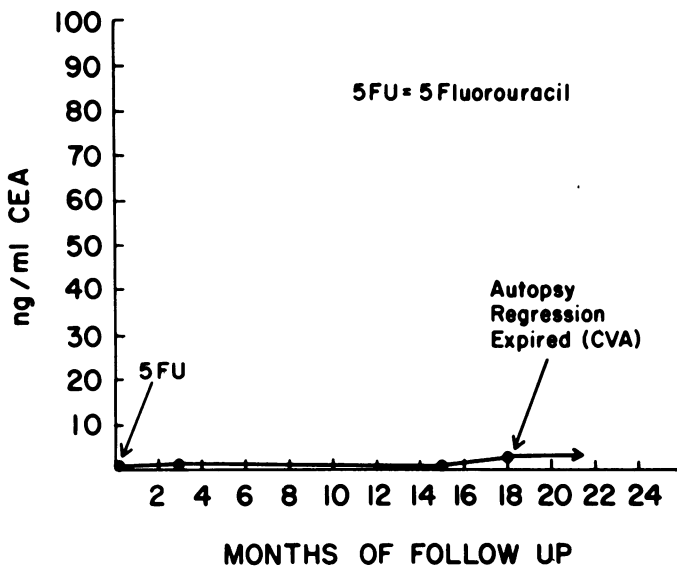


FIG. 2. Flat CEA curve during 5-FU therapy for unresectable liver metastases—no hepatic lesions at autopsy (Patient 2).

not effect measurable changes in CEA as compared to chemotherapy. There was one patient who showed regression of pulmonary metastases after resection of the colon primary and chemotherapy with CCNU and radiation. This patient had a marked drop in CEA values.

Case Reports

Patient 1: A 70-year-old Caucasian woman was admitted for the first time to Roswell Park Memorial Institute (RPMI) in March 1971 with complaints of abdominal pain, weight loss and occasional bloody stools. Work-up revealed a stenosing lesion in the sigmoid colon with pulmonary metastases. One month later, at abdominal exploration, she was found to have extension to the bladder and multiple peritoneal seedings. A palliative sigmoid resection was carried out. Postoperatively, she received radiotherapy to the mediastinum and pelvis and was placed on chemotherapy with Methyl-CCNU. At the seventh month of followup, her pulmonary lesions totally disappeared and she was doing well, still under treatment with Methyl-CCNU. She was again re-admitted 6 months later with partial bowel obstruction which was relieved by nonoperative treatment. At that point, however, her general condition began to slowly deteriorate and she expired at home 16 months after being incorporated to the study.

Comment: The disappearance of her chest lesions was accompanied by an improvement of her general well-being and a fall in her CEA values. CEA rose again when the disease began to progress after her original favorable response to therapy (Fig. 1). Unfortunately, no autopsy was obtained to verify the extent of the tumor present at death.

Patient 2: A 69-year-old Caucasian woman underwent a sigmoid resection in August 1970, for Duke's C adenocarcinoma of the sigmoid colon. Six months postoperatively while first seen at RPMI, she was found to have a positive liver scan and nonresectable liver metastases were found at laparotomy. The biopsy was read as metastatic adenocarcinoma from her previously resected sigmoid primary. She was treated with intravenous 5-FU for the next 18 months with a good clinical response. She developed a cerebrovascular hemorrhage which caused her death in December 1972. Autopsy showed no evidence of any residual liver tumor, but a 1 cm in diameter pulmonary nodule was found which was the only remaining evidence of her original colonic malignancy.

Comment: This patient's CEA remained low throughout the monitored period (Fig. 2).

Patient 3: A 19-year-old Caucasian man was admitted to RPMI in February 1971, 8 months after undergoing a Miles' abdomino-perineal resection for a Duke's C adenocarcinoma of the rectum. He was referred to us because of persistent pelvic pain and a local recurrence in his perineal scar. An ill-defined mass was felt in the suprapubic area on abdominal examination. Exploratory laparotomy during his first RPMI admission disclosed multiple metastatic nodules in the pelvic floor and peritoneal cavity with a tumor mass involving the top of the bladder and left ureter. No resection was attempted and postoperatively, he received radiotherapy and 5-FU intravenously with total disappearance of the previously palpable suprapubic mass within 3 months of therapy, showing improvement of his general condition as well. However, 9 months later, a cystoscopic examination turned out positive

for bladder invasion and the left kidney was hydronephrotic. His disease started to progress and he died in his 11th month of followup; no autopsy was obtained.

Comment: His CEA was initially normal. Later values showed an increase following exploration, radiotherapy and chemotherapy, they became normal again and remained low during his period of response to therapy (Fig. 3).

Patient 4: A 73-year-old Caucasian woman was referred to our Institution in April 1974 with pulmonary and vaginal metastases from an adenocarcinoma of the rectum, diagnosed and treated in 1972 by abdominoperineal resection. Biopsy indicated that the vaginal nodules were metastatic from her previous rectal malignancy and chest x-ray revealed the presence of multiple metastatic nodules in both lung fields. She was promptly started on chemotherapy with intravenous 5-FU and 6-Thioguanosine (6-TG) with a marked improvement in her general condition, total disappearance of the vaginal nodules and disappearance or reduction of more than 50% in size of all her pulmonary nodules within 2 months of the commencement of the treatment. Her response lasted for 8 months, at which time chest x-rays again showed enlarging pulmonary lesions. There was no evidence of vaginal recurrence of tumor. The disease progressed and she expired at 11 months of followup.

Comment: Her originally elevated CEA fell following treatment and coincidentally with clinical regression of her tumor. A rise in CEA was detected before radiographic documentation of tumor progression was made (Figure 4).

Patient 5: A 59-year-old Caucasian man was referred to RPMI in March 1972 with a history of rectal bleeding and tenesmus. His past history included a myocardial infarction, diabetes and a symptomatic hiatal hernia. A rectal mass felt upon examination was biopsied

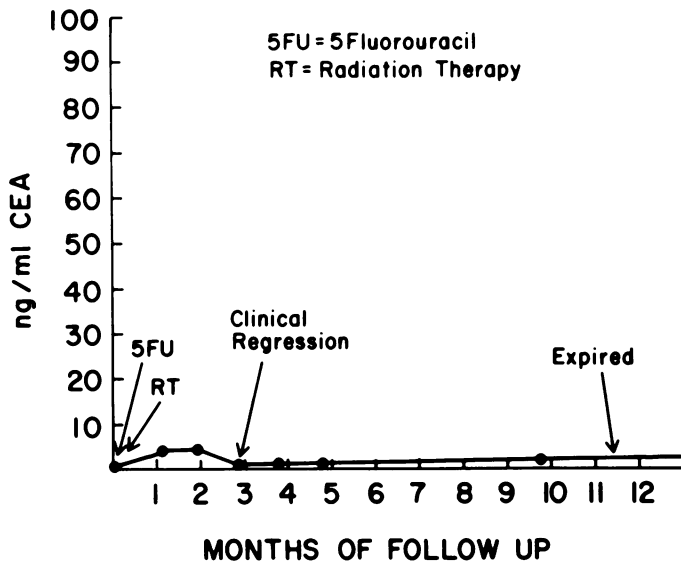


FIG. 3. CEA elevation after surgery, radiation and chemotherapy with maintained low levels and regression of abdominal metastasis (Patient 3).

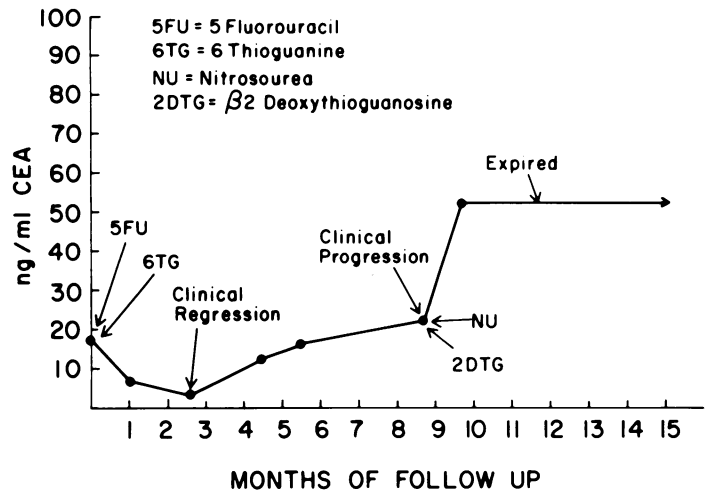


FIG. 4. CEA drop post initiation of treatment with rise preceding later progression. At the CEA nadir, the patient was in clinical regression (Patient 4).

and found to be an adenocarcinoma. He underwent a Miles' abdominoperineal resection for a tumor staged as Duke's B. He was readmitted because of severe pelvic pain. A subsequent work-up histologically demonstrated the pain to be due to metastases from the rectal adenocarcinoma. A course of radiotherapy combined with intravenous 5-FU was given to the patient, resulting in complete relief of pain. He was readmitted 9 months later with bowel obstruction attributed to fibrosis from radiation of his pelvis. Upon abdominal exploration for release of the obstruction, the liver was found normal, the small bowel had formed multiple adhesions to the pelvis which were lysed, but there was no sign of presence of residual tumor. No tumor was found in the presacral area; a biopsy of the area showed fibrosis. A year later, 20 months after initiation of his course of combined radiation and chemotherapy, he has no complaints or evidence of disease.

Comment: His original CEA was abnormally high, but fell to normal values and stayed within this range until his

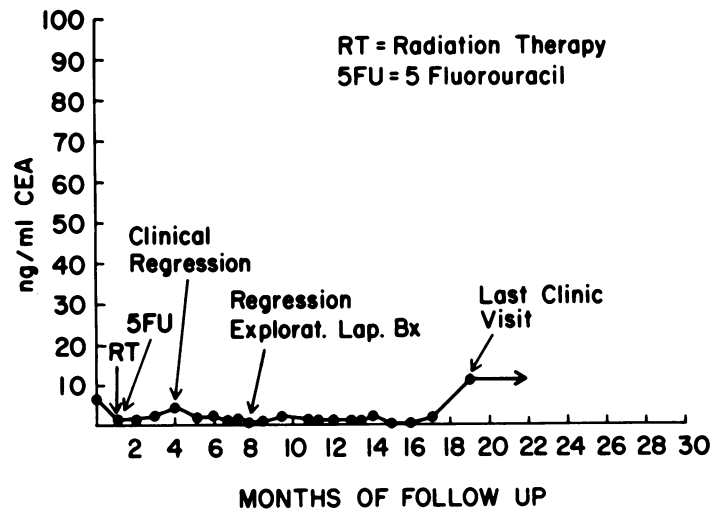


FIG. 5. Fall of CEA coinciding with regression of the pelvic tumor after radiation and chemotherapy (Patient 5).

last clinic visit at which time single elevation was found (Fig. 5). He is now being worked-up for the possibility of recurrent disease.

Patient 6: A 53-year-old Caucasian woman had sigmoid resection for an unstaged adenocarcinoma of the sigmoid colon in August 1971. In March 1973, she had hepatomegaly and a liver scan consistent with liver metastases. She received a course of intravenous 5-FU until July 1973 when, due to the appearance of vaginal metastases, she was referred to our Institute. Vaginal biopsies showed the nodules to be formed by adenocarcinoma consistent with metastases from colonic primary. Exploratory laparotomy showed multiple liver metastases with the same cellular characteristics as the original malignancy. Chemotherapy with intravenous 5-FU and Streptozotocyn was combined with radiation of the perineal lesions. Eleven months later, she was found to have an improved liver scan. Exploratory laparotomy showed several small fibrotic liver nodules which were histologically negative for presence of malignant cells. No evidence of intra-abdominal residual tumor was found. When last seen at 18 months of treatment she had a non-palpable liver and with vaginal nodules of much smaller size, as compared to the initial description at the time of initiating treatment with radiation and chemotherapy.

Comment: This patient presented already under chemotherapy with 5-FU. Her original CEA was normal. Added chemotherapy and radiation produced a clinical response accompanied by persistently low CEA levels except for a single rise during the postoperative period after her abdominal exploration and liver biopsy. These were negative for tumor. At 18 months of treatment, she has small vaginal nodules and persistently low CEA's (Fig. 6).

Patient 7: A 45-year-old Caucasian man had a right hemicolectomy in 1971 for carcinoma of the cecum. Within a year of his resection, he was suspected of having developed liver metastases and was re-

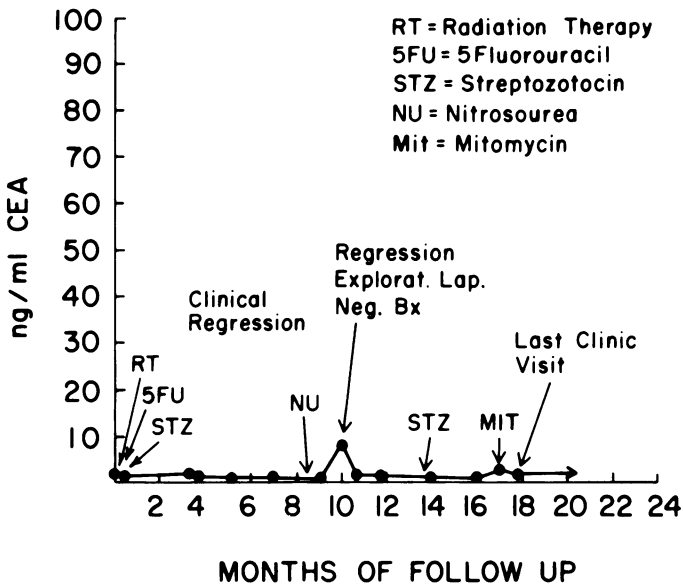


FIG. 6. Low CEA in a patient under multiple chemotherapy and a good clinical response (Patient 6).

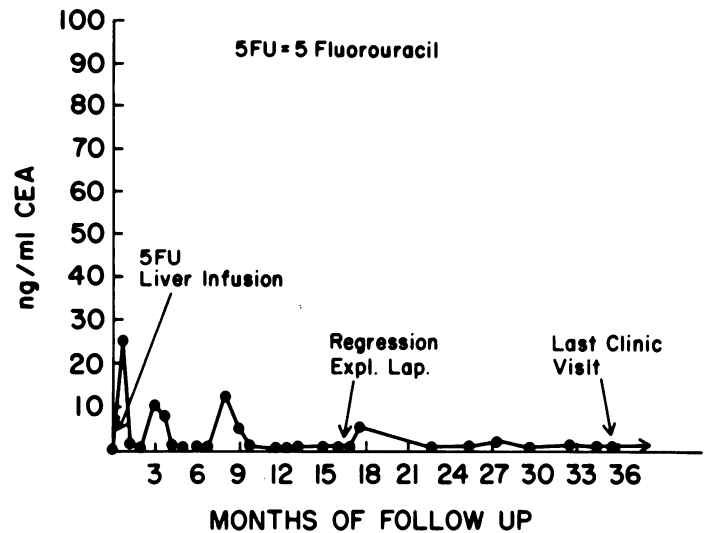


FIG. 7. CEA values decreased after liver perfusion with 5-FU-the patient had a good response to the treatment (Patient 7).

ferred to RPMI. He had a palpable liver with a positive liver scan and an angiogram positive for multiple space-occupying lesions. On exploration, he had multiple metastases in both right and left lobes from a tumor that was histologically consistent with metastases from his previous colonic primary. The hepatic artery was cannulized for infusion of 5-FU combined with oral Coumadin. The 5-FU was changed to the oral route after 3 weeks. At 17 months, his liver scan was reported normal and by 22 months after liver infusion, his liver could no longer be palpated. At the 29 month mark, he was explored and no intra-abdominal tumor could be found. There were no masses or nodules in the liver. He was last seen at 35 months of followup free of residual disease.

Comment: This patient's preoperative CEA was low. It became elevated after hepatic artery cannulation and biopsy, then it remained low except for a transitory elevation after abdominal exploration up until his last visit (Fig. 7).

Patient 8: A 68-year-old Caucasian woman was referred to RPMI with an obstructive low-sigmoid colon carcinoma in March 1973. She was explored and found to have diffuse pelvic carcinomatosis with attachment of the primary tumor to the sacrum and obstruction of the sigmoid colon by the tumor mass. A colostomy was performed and biopsy of her pelvic metastases indicated a well-differentiated adenocarcinoma consistent with colonic origin. The area of tumor was treated with radiation and the patient did well for the next year. An exploratory laparotomy 14 months after the original operation showed multiple adhesions and areas of fibrosis, but no tissue with the appearance of tumor could be found. Biopsy of the presacral area where most of the tumor was present during the previous operation showed fibrosis with total absence of tumor cells. She was last seen at 19 months of followup with no evidence of disease and radiation proctitis as the only abnormal finding of the work-up.

Comment: Her CEA was originally high, but dropped to within normal range within 3 months of the initiation of therapy, with only one isolated elevation occurring

during the postoperative period following her exploratory laparotomy, which was negative for the presence of obvious residual tumor (Fig. 8).

Patient 9: A 52-year-old Caucasian woman was admitted in October 1974 with liver and pulmonary metastases from rectal adenocarcinoma treated with pelvic exenteration in October 1970. Abdominal exploration in May 1971 revealed no evidence of intra-abdominal malignancy. However, in November 1973, her liver scan had been found to be positive. Work-up on admission (October 1974) showed a 50% replacement of her liver by space-occupying lesions and the liver was enlarged and easily palpable. Chest x-ray revealed 3 metastatic nodules. She was started on 5-FU and within 3 months, her liver had decreased in size and the pulmonary nodules disappeared. Her clinical situation has remained improved 6 months after her initiation of 5-FU.

Comment: This patient's pretreatment CEA was extremely high and increased after chemotherapy was initiated, to fall coincidentally with her clinical improvement and the radiological disappearance of her pulmonary metastases.

Discussion

Patients subjected to palliative modality of treatment are generally in inexorable and constant progression with infrequent regression of tumor mass or slowing of tumor growth for a finite period of time.

To define progression or regression in these patients is a vague and difficult task; even in the case of the so-called "measurable" disease. This latter term usually means that a certain unknown portion of the tumor (not necessarily the whole tumor mass) can be measured.

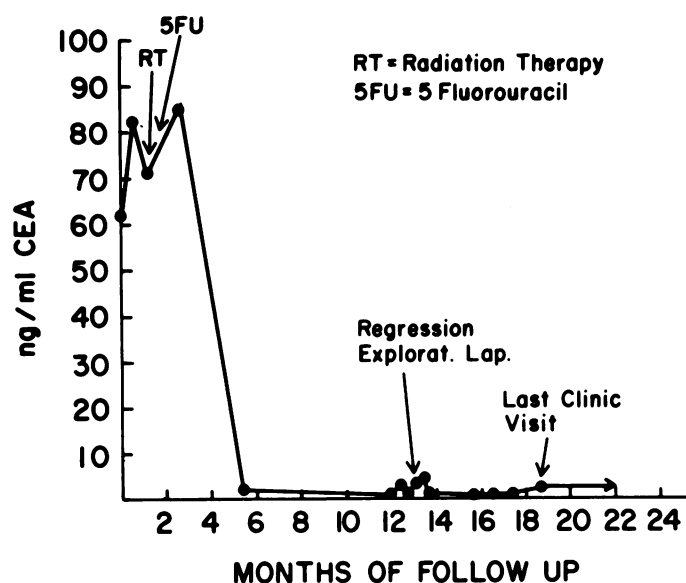


FIG. 8. CEA drop after radiation and chemotherapy. The serum values remained low during the period of observation with the patient in maintained regression (Patient 8).

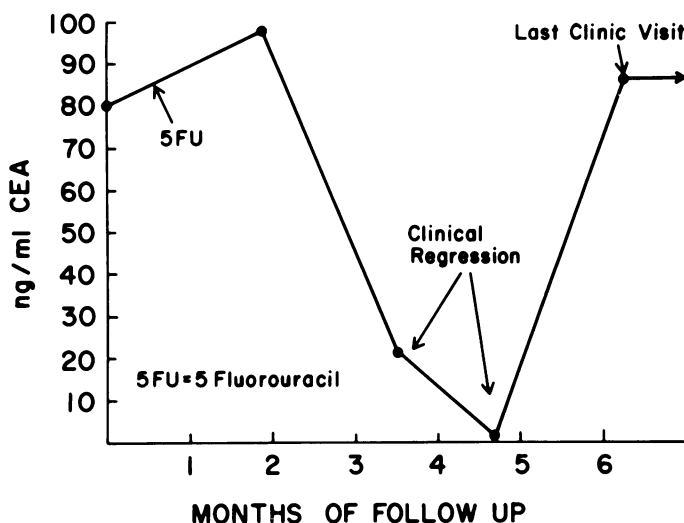


FIG. 9. Patient treated with chemotherapy (Patient 9). He showed a clinical response at which time CEA levels dropped. A later rise is being observed.

This particular "measurable" component frequently lacks histological confirmation and is subjected to changes unrelated to the therapy used, such as biological or anatomical growth limitations producing spontaneous necrosis with formation of hematoma (increasing the size of the lesion) or a chronic ischemia with regional atrophy (decrease in size of the measurable lesion).

In the particular case of colorectal tumors, extension of disease regionally in the pelvis or metastases to lymph nodes, liver or other intra-abdominal organs is very difficult to assess in spite of the sophisticated methods of detection available to the clinician.

For the above reasons, the assignment of a numerical value to the amount of tumor present, if it can be done, is of considerable advantage in treating these patients.

We do know now that CEA does identify 80% of our progressions which are sufficiently marked to be certain, and that it monitors almost all of our regressions. The problem still exists in the fact that a significant percentage of colon cancers do not produce or release CEA. That is some where around 10-15%. There is also a large group of patients who show a decrease in CEA with radiation or chemotherapy which represents either a subclinical response or an unrelated metabolic response. The fact that survival is longer for these CEA responders indicated that there is a tumoricidal effect.

References

1. Chu, T. M. and Nemoto, T.: Evaluation of Carcinoembryonic Antigen in Human Mammary Carcinoma. *J. Nat. Cancer Inst.* 51:1119, 1973.
2. Chu, T. M., Holyoke, E. D. and Murphy, G. P.: Carcinoembryonic Antigen. Current Clinical Status. *New York State J. Med.*, 74:1388, 1974.

3. Dhar, P., Moore, T., Zamcheck, N. and Kupchick, H. Z.: Carcinoembryonic Antigen (CEA) in Colon Cancer. *JAMA*, 221: 31, 1972.
4. Hansen, H. J., Snyder, J. J., Miller, E., et al.: Carcinoembryonic Antigen (CEA). A Laboratory Adjunct in the Diagnosis and Management of Cancer. *Human Pathol.* 5:139, 1974.
5. Herrera, M. A., Chu, M. T. and Holyoke, E. D.: Carcinoembryonic Antigen (CEA) as a Prognostic and Monitoring Test in Clinically Complete Resection of Colorectal Carcinoma. *Ann. Surg.*, 183:5, 1976.
6. Holyoke, E. D., Reynoso, G. and Chu, T. M.: Carcinoembryonic Antigen (CEA) in Patients with Carcinoma of the Digestive Tract. *Ann. Surg.*, 176: 559, 1972.
7. Holyoke, E. D., Chu, T. M. and Murphy, G. P.: CEA as a Monitor of Gastrointestinal Malignancy. *Cancer*, 35:830, 1975.
8. Lo Gerfo, P., Krupey, L., and Hansen, H. J.: Demonstration of an Antigen Common to Several Varieties of Neoplasia. *N. Engl. J. Med.*, 285:138, 1971.
9. Lo Gerfo, P., Lo Gerfo, F., Herter, F., et al.: Tumor-associated Antigen in Patients with Carcinoma of the Colon. *Am. J. Surg.*, 123:127, 1972.
10. Mach, J. P., Jarger, P. H., Bertholet, M. M., et al.: Detection of Recurrence of Large Bowel Carcinoma by Radioimmunoassay of Circulating Carcinoembryonic Antigen (CEA). *Lancet*. 7880:535, 1974.
11. Mc Cartney, W. and Hoffer, P.: The Value of Carcinoembryonic Antigen (CEA) Immunoassay as an Adjuvant to Radiologic Techniques in the Diagnosis of Malignancies of the Colon and Lung. *Radiology*, 110:325, 1974.
12. Moore, T. L., Kupchik, H., Marcon, N. and Zamcheck, N.: Carcinoembryonic Antigen Assay in Cancer of the Colon and Pancreas and Other Digestive Tract Disorders. *Am. J. Dig. Dis.*, 16:1, 1971.
13. Mulcare, R., and Lo Gerfo, P.: Tumor-associated Antigen in the Chemotherapy of Solid Tumors. *J. Surg. Oncol.*, 4:407, 1972.
14. National Cancer Institute of Canada/American Cancer Society Investigation: A Joint Collaborative Study of a Test for Carcinoembryonic Antigen (CEA) in the Sera of Patients with Carcinoma of the Colon and Rectum. *Can. Med. Assoc. J.* 107:25, 1972.
15. Reynoso, G., Chu, T. M., Holyoke, E. D., et al.: Carcinoembryonic Antigen in Patients with Different Cancer. *JAMA*, 220:361, 1972.
16. Schmall, B., Cheng, C. J., Fujimura, S., et al.: Modification of proteins by 1-(2-Chloroethyl)-3-Cyclohexyl-1-Nitrosourea (NSC 79037) in vitro. *Cancer Res.*, 33:1921, 1973.
17. Skarin, A. T., Delwiche, R., Zamcheck, N., et al.: Carcinoembryonic Antigen: Clinical Correlation with Chemotherapy for Metastatic Gastrointestinal Cancer. *Cancer*, 33:1239, 1974.
18. Sorokin, J. J., Sugarbaker, P. H., Zamcheck, N., et al.: Serial CEA Assays: Use in Detection of Recurrence Following Resection of Colon Cancer. *JAMA*, 228:49, 1974.
19. Steward, A. M., Nixon, D., Zamcheck, N. and Aisenberg, A.: Carcinoembryonic Antigen in Breast Cancer Patients: Serum Levels and Disease Progress. *Cancer*, 33:1246, 1974.
20. Zamcheck, N., Moore, T. L., Dhar, P., et al.: Immunologic Diagnosis and Prognosis of Human Digestive Tract Cancer. Carcinoembryonic Antigen. *N. Engl. J. Med.*, 286:83, 1972.