

# The Prevention of Bypass Enteritis After Jejunioileal Bypass for Morbid Obesity

T. BRANNON HUBBARD, JR., M.D., PH.D.

The symptoms of bypass enteritis are disabling sequelae in many patients after jejunioileal bypass. This is a preliminary report of efforts to devise a valve to prevent reflux into the bypassed intestine after jejunioileal bypass. Valve I (42 cases) was formed by dividing the ileum, everting the proximal end as one matures an ileostomy, and inserting this into the distal ileum. Only 12 of these valves were competent. Valve II (six cases) was formed by dividing the ileum and merely inserting the proximal bowel into the distal, allowing it to evert spontaneously as with an unmatured ileostomy. In two cases the valve was competent, but four cases became obstructed and this valve is mentioned only to be condemned. Valve III (19 cases) is similar to an isoperistaltic Kock valve, except that the intussuscepted ileum is first divested of its mesentery. All such valves have been competent. All 33 patients with a competent valve have been free of the stigmata of bypass enteritis, whereas 54% of 156 patients showed the symptoms of enteritis after conventional jejunioileal bypass.

**T**HE RESULTS AND COMPLICATIONS of jejunioileal bypass for morbid obesity have been described by numerous authors, including the recent report by Scott et al.<sup>15</sup> This paper addresses itself to a group of postoperative sequelae which are grouped under the heading of bypass enteritis and are characterized as follows.

There may be excess intestinal gas, frequently malodorous, often with a chronically distended abdomen in spite of weight loss, so that some women complain of appearing pregnant. There may be intermittent explosive diarrhea, as described by Passaro et al.<sup>11</sup> There may be pseudo-obstruction with pain, abdominal distention, fever, and markedly dilated colon as described by Barry et al.<sup>2</sup> This may progress to pneumatosis intestinalis and pneumoperitoneum, as described by Ikard et al.<sup>7</sup> Finally, there may be continual, prolonged malnutrition and hypoproteinemia possibly due to active loss of albumin from the bypassed intestine, as described by Drenick et al.<sup>3</sup>

---

Presented at the Annual Meeting of the Southern Surgical Association, Hot Springs, Virginia, December 5-7, 1977.

Reprint requests: Mercy Hospital, 301 St. Paul Place, Baltimore, Maryland 21202.

Submitted for publication: December 8, 1977.

*From the Department of Surgery of the University of Maryland and Mercy Hospital, Baltimore, Maryland*

---

In a personal experience with 156 intestinal bypass procedures, (end-to-side, 16 cases; end-to-end, 140 cases), followed for 17-60 months, 84 patients (53.8%) complained of intolerable, malodorous gas, of whom 30 (19%) presented with chronically distended abdomens. Thirty-eight patients (24.3%) experienced episodic diarrhea or pseudo-obstruction. Three of these developed pneumatosis intestinalis, one of whom developed pneumoperitoneum.

The problem of malodorous gas has not been stressed in the literature and is elicited as a rule, only by asking a patient specifically about it. Most patients seem reluctant to bring the matter up themselves. However, it is a symptom of no little importance. The personal and marital life of some patients is seriously threatened. Secretaries are reluctant to work in a room with others. Figure 1a shows a patient with chronic bloating 24 months after a bypass. He refuses to go to a movie or restaurant unless he is on a course of antibiotics, due to the odor of the gas. Once an extrovert, he now describes himself as an introvert. Figure 1b is of his abdominal x-ray showing massively dilated large and small bowel. Though occurring daily in this patient, the film may be easily confused with an abdominal catastrophe.

The majority of patients after intestinal bypass are happy with their weight loss, but one wonders why when so many suffer from these symptoms. Although their exact etiology is presently obscure, it appears probable that bacterial overgrowth secondary to reflux and stasis in the bypassed intestine is responsible. This is suggested by the fact that the symptoms usually respond to antibiotic therapy, including Metronidazole. However, over a lifetime after a bypass procedure, it is apparent that continued, repeated antibiotic therapy is an unsatisfactory answer for the patient and

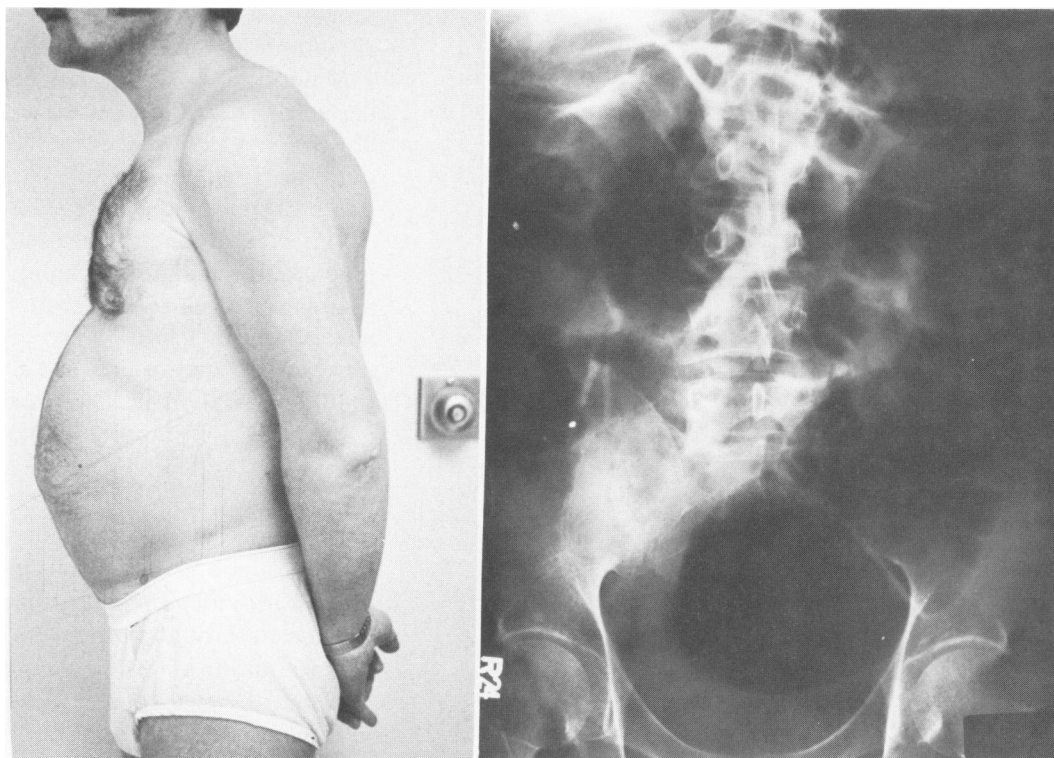


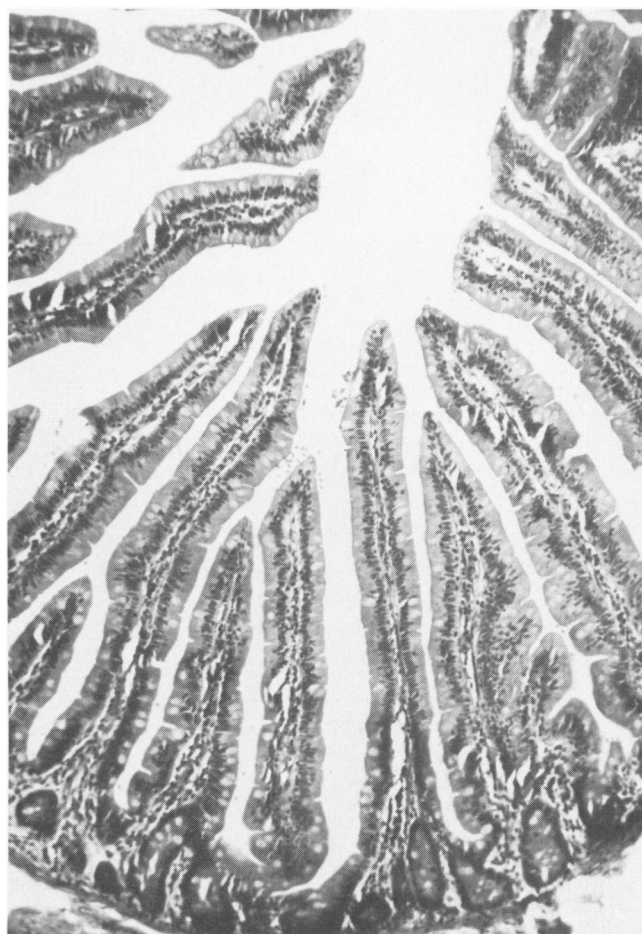FIG. 1. (a) A patient two years after bypass showing chronic bloating. (b) Abdominal x-ray of same patient showing gas filled large and small bowel.

that the continued insult to the bypassed intestine cannot be comfortably tolerated over several decades. Grossly on re-exploration this bypassed bowel is markedly dilated, edematous, and thickened with a cloudy, roughened serosa. Figure 2 depicts the normal ileal mucosa compared to sections of two bypassed ileal segments. The blunted villi, submucosal infiltration, loss of polarity of the mucosal cells, and marked increase in mucin secreting cells is apparent.

That the ileocecal valve acts as a barrier to the bacteriologic flora of the colon is well known. Glassman<sup>4</sup> and Richardson and Griffen<sup>12</sup> have shown that mucosal valves in the intestines of dogs act as bacteriologic barriers. If reflux into the bypassed intestine could be prevented, the above described sequelae of intestinal bypass might not occur. This paper is a preliminary report of the development of an antireflux valve and the short-term results.

### Valve I

Zheng et al.,<sup>17</sup> in 1976 described a competent intestinal valve formed by simply dividing the intestine and telescoping the proximal end into the distal. The tele-



FIGS. 2a-c. Photomicrographs of (a) normal ileal mucosa and (b and c) the mucosa of the ileum of two cases with bypass enteritis. Shortened villi, mucin secreting cells, and submucosal infiltration are apparent. (H & E stain  $\times 100$ ).

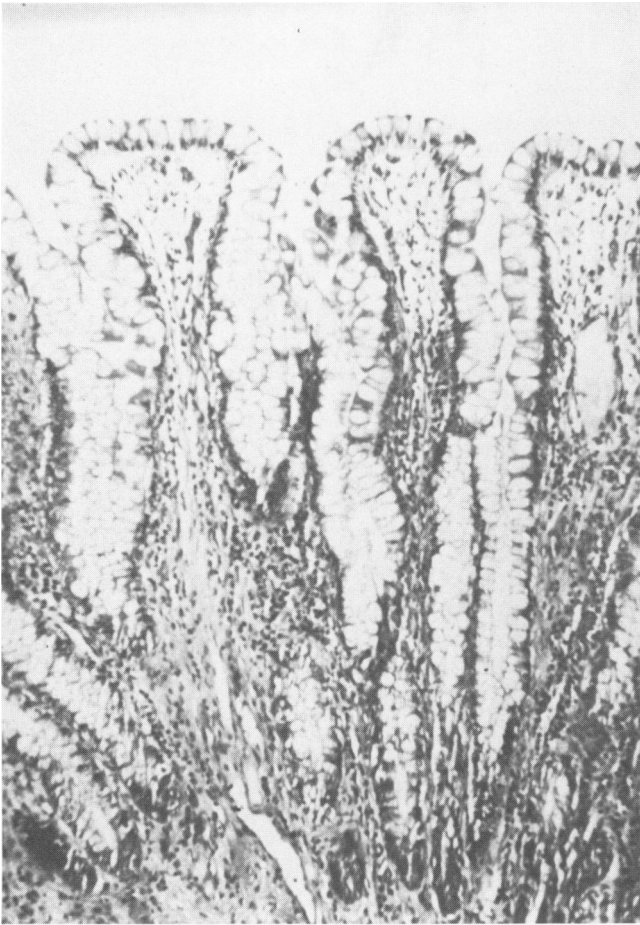

FIG. 2b. See legend for Figures 2a-c.

scoped end was allowed to evert spontaneously just as with an unmaturing ileostomy, (Fig. 3). Shrum<sup>13</sup> in 1964 described a similar procedure as a means of forming an ileocolostomy. Both authors stated that in the dog no obstruction occurred and that clinical application was being considered. We were reluctant to adopt this procedure since in the case of the unmaturing ileostomy one frequently saw stricture formation at the junction of the skin and ileum. We, therefore, utilized a similar procedure except that the valve was matured at the time of surgery. Two centimeters proximal to the site of the future end-to-side jejunioileostomy, the ileum is divided. The proximal end is divested of its mesentery for approximately five centimeters. The serosa of this segment is abraded with the scalpel to promote adhesions and the bowel is everted on itself and secured with sutures of 4-0 dextron between the everted edge and the seromuscular coat of the proximal bowel. Two longitudinal sutures of 4-0 chromic catgut are placed through both layers and tied loosely to prevent retraction of this nipple until adhesions are formed between the two layers. The nipple is then inserted into the distal ileum and secured with 4-0 silk sutures which incorporate the edge of the distal bowel, the edge of the everted bowel, and the seromuscular wall of the proximal bowel. An end-to-side jejunioileostomy is made just distal to the tip of this nipple (Fig. 4). Forty-two such valves have been formed, but only 12 have remained competent on follow-up of five to 18 months.

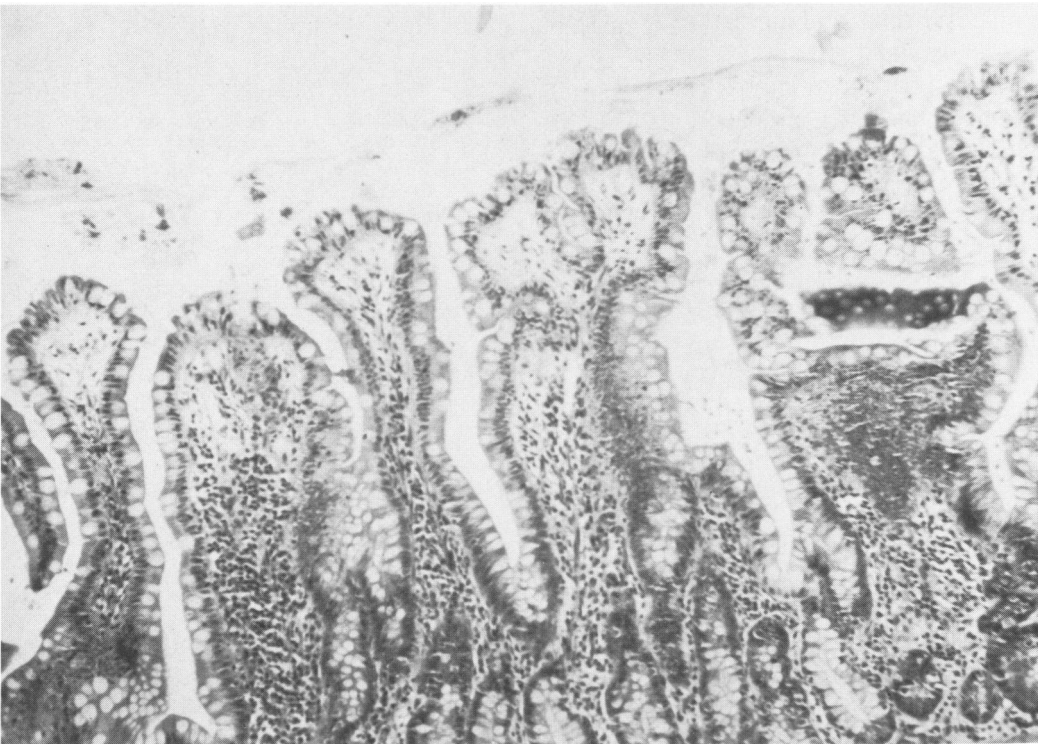


FIG. 2c. See legend for Figures 2a-c.

**Valve II**

The high incidence of incompetency of Valve I seemed to be due to the fact that the nipple, when divested of its mesentery, was necessarily quite short if it were to remain viable after being everted. Therefore, we finally had the temerity and lack of judgment, to form a valve similar to that described by Zheng,<sup>17</sup> foregoing mucosa to mucosa approximation, (Fig. 3). Six such valves were formed. The first two cases were competent and have had no problems. However, the next four cases all became obstructed 15–35 days after surgery, requiring resection of the valve. After this experience, belated correspondence with Shrum, who originally described the procedure, revealed that about 20 such ileo-transverse colostomies had been done clinically, with obstruction in approximately one fourth of the cases.<sup>14</sup> Since it is rare that an idea occurs in only one place, our own experience is reported here with some humility to prevent further trials of this procedure by others.

**Valve III**

The third, and apparently successful valve, is a modification of the Kock valve.<sup>8</sup> Two centimeters proximal to the site of the future end-to-side jejunoileostomy, the ileum is devascularized, staying close to bowel for approximately five centimeters, or until the midportion of the devascularized segment appears very slightly compromised. The serosal surface of this segment is then abraded with bone rasp or cautery. The incision is then made in the ileum for the future jejunoileostomy, and through this incision the midpoint of the devascularized segment is grasped with two sutures and intussuscepted distally. The proximal edge of this nipple is fixed to the adjoining intestine with interrupted sutures of 4-0 Ethiflex and two sutures of catgut are placed through the intussuscepted nipple to promote adherence of the two layers. A number 20F catheter is then passed proximally through the nipple and interrupted 4-0 Ethiflex seromuscular sutures are placed

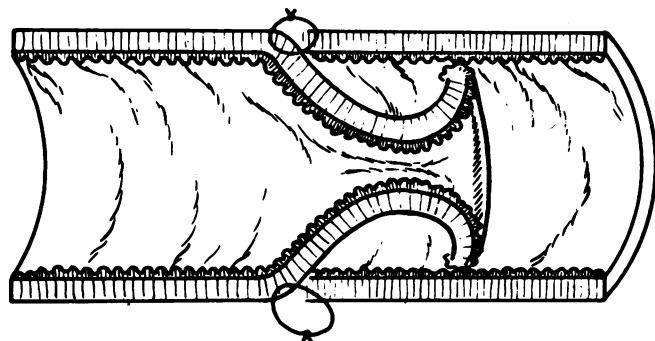


FIG. 3. The intestinal valve described by Zheng. The bowel is divided, intussuscepted, and allowed to evert spontaneously.

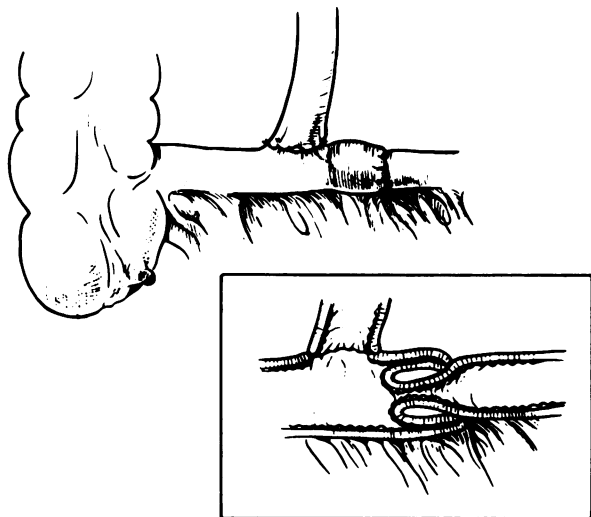
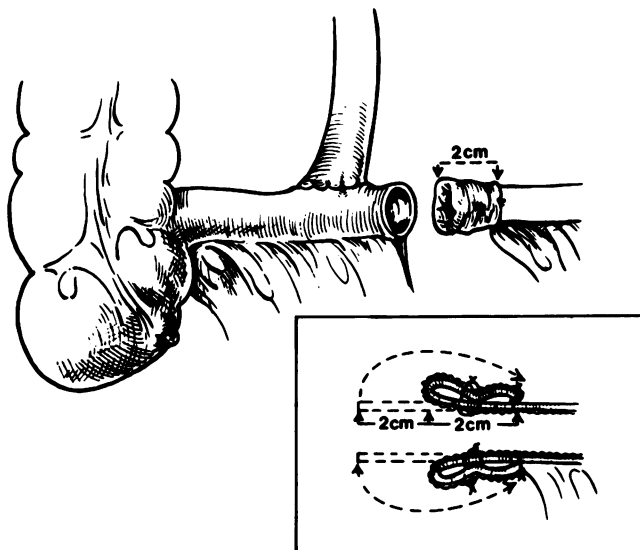


FIG. 4. Valve I (top) The ileum is divided and the proximal end is everted on itself. Valve I (bottom) The everted end is inserted into the distal bowel just proximal to the jejunoileostomy.

transversely to narrow the proximal ileum for a distance of approximately 4 cm to prevent retrograde reduction of the nipple. Approximately 15 cm of proximal ileum are plicated to prevent traveling of the intussuscepted nipple. The end-to-side jejunoileostomy is then performed in the usual way (Fig. 5).

Nineteen bypasses have been formed in this manner and all valves have remained competent on follow-up of four to eight months. Figure 6 is of a small bowel series performed on such a patient. The valve appears as typical intussuscepted intestine.

In addition, three patients who after an end-to-end jejunoileostomy and ileotransverse colostomy suffered from malodorous gas, episodic diarrhea, and bloating have been converted to an end-to-side jejunoileostomy with such a valve. Such conversion was approached

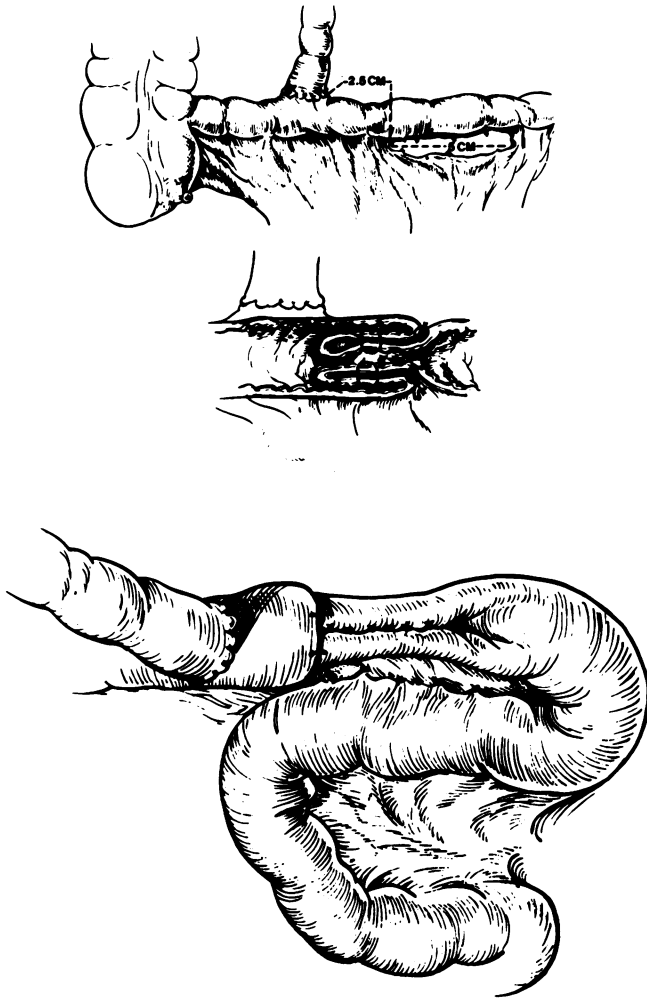


FIG. 5. Valve III (top) The future valve is devascularized and intussuscepted just proximal to the end-to-side jejunioileostomy. Valve III (bottom) The ileum just proximal to the valve is narrowed and an adjacent segment is plicated to prevent progression of the intussusception.

with some skepticism since the dilated, edematous bowel did not seem to lend itself to forming a satisfactory valve. These three patients, however, did not wish to continue as they were, to have their normal bowel continuity restored, or to undergo a gastric bypass. They desired to accept the possibility that the valve might not function satisfactorily. In two cases the valve has been competent, and in one has allowed reflux.

### Results

The 30 patients with an incompetent valve (valve I) and the four patients whose valves were resected (valve II) have all pursued a course similar to the conventional end-to-side jejunioileostomy.

The 33 patients with a competent valve, either types

I, II, or III, have only been followed for from four to 17 months. These results can, therefore, only be considered tentative, but their course has been remarkably asymptomatic. None of them have complained of malodorous gas, bloating or intermittent diarrhea. While losing an average of 4.0 Kg per month during the first year, their attitude and general health have been in marked contrast to the patient who had had a conventional intestinal bypass. Bowel movements after two months have ranged from one to eight per day, with an average of four per day. Serum albumin levels have ranged from 3.8 to 4.4 g per deciliter (average 4.0). Table 1 contrasts the incidence of symptoms of bypass enteritis in 156 conventional bypasses and the 33 cases with competent valves.

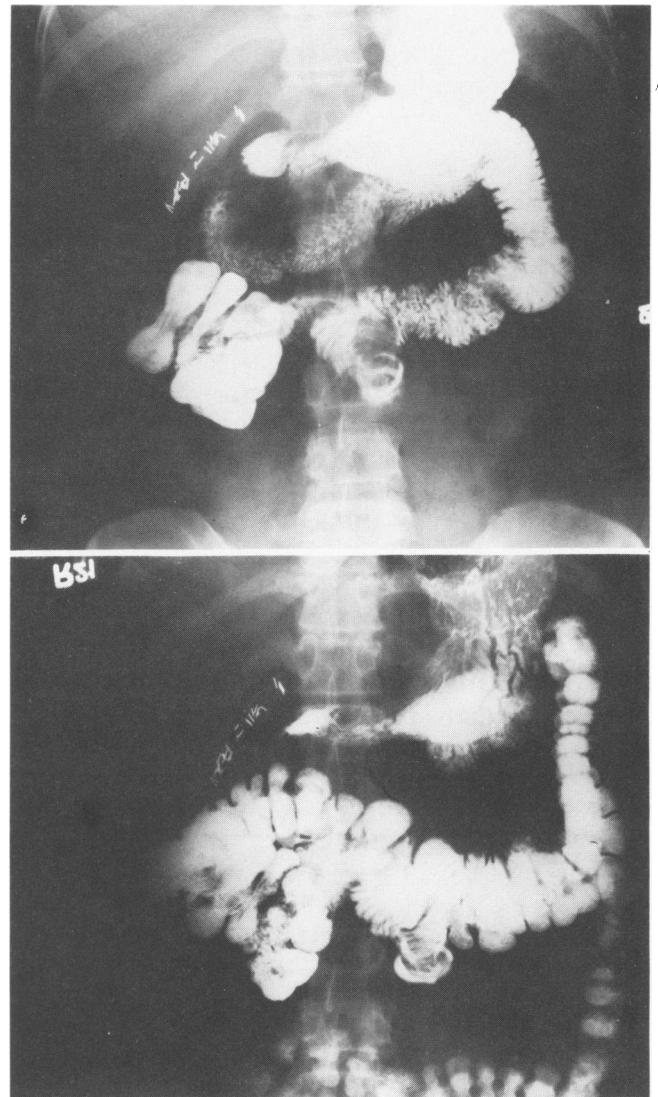


FIG. 6. A small bowel series showing a Type III Valve (top) at 15 minutes; (bottom) at 60 minutes.

One patient, who began drinking heavily after the bypass, developed hepatic dysfunction which necessitated taking down of the bypass. At re-exploration the entire bypassed intestine was small, empty and collapsed, in marked contrast to the dilated, thickened intestine usually seen in the bypassed intestine in its distal portion.

Of the three patients who were converted from an ileotransverse colostomy to a Valve III, the one with an incompetent valve has no change in her symptoms. Two, however, on follow-up of four and five months have had no more bloating, malodorous gas, or episodic diarrhea, and are well satisfied with the results.

### Discussion

The most serious complication of jejunioleal bypass is hepatic failure. It is probable that the primary cause is protein-calorie malnutrition secondary to malabsorption. However, bacterial overgrowth in the bypassed segment could possibly accentuate the problem. O'Leary et al.<sup>9</sup> showed that after jejunioleal bypass dogs treated with Doxycycline retained normal hepatic morphology, whereas nontreated dogs developed fatty livers with centrilobular necrosis. Other studies comparing bypass and resection in dogs by Hyland et al.<sup>6</sup> and in rats by Viddal et al.,<sup>16</sup> showed less disturbance in liver function after resection, though there was no significant difference in liver morphology. Whether intestinal bypass in which there is no reflux into the bypassed segment will minimize the incidence of hepatic failure remains to be seen. However, the occurrence of one such case in these 33 patients suggests that hepatic failure is certainly not totally dependent on reflux into the bypassed segment.

Surgeons have for years searched for a method of simulating the ileocecal valve and it may be that the present valve (Valve III) is an answer. When made in the ileum of the dog, in continuity with the intact intestinal tract, no obstruction has occurred and no dilation of the proximal bowel. This does not mean that free passage of intestinal contents would occur in the human, for the danger of extrapolating results in the experimental animal to man is well shown by our experience with Valve II. The latter unfortunate experience emphasizes once again that in surgery of the intestinal tract, mucosa to mucosa approximation is a sine qua non if stricture is to be avoided.

The making of Valve III on first glance looks like a complicated, unnecessarily extensive procedure. In practice, however, it is not difficult and is probably safer than an end-to-end anastomosis. Most reports of large series of the latter procedure describe at least one case of anastomotic leak or stricture.

The jejunioleal bypass has been placed somewhat

TABLE 1. *The Incidence of the Symptoms of Bypass Enteritis after Conventional Jejunioleal Bypass and after Bypass with a Competent Valve*

	Conventional Bypass (156 Cases)	Bypass with Competent Valve (33 Cases)
Malodorous gas	84 (53.8%)	0
Episodic diarrhea or Pseudo-obstruction	38 (24.3%)	0
Bloating	30 (19.2%)	0
Pneumatosis intestinalis	3 (01.9%)	0

sub judice by the recent reports of Alden<sup>1</sup> and Griffin et al.,<sup>5</sup> comparing the gastric with the intestinal bypass. However, if a jejunioleal bypass is done, we believe that an end-to-side jejunioleostomy with an antireflux valve (Valve III), is the procedure of choice. It apparently prevents the sequelae of bypass enteritis. Its further effects must await longer follow-up.

### References

1. Alden, J. F.: Gastric and Jejunioleal Bypass, A Comparison in the Treatment of Morbid Obesity. *Arch. Surg.*, 112:799, 1977.
2. Barry, R. E., Benfield, J. R., Nicell, P. and Bray, G. A.: Colonic Pseudo-obstruction: A New Complication of Jejunioleal Bypass. *Gut*, 16:903, 1975.
3. Drenick, E. J., Ament, M. E., Finegold, S. M., et al.: Bypass Enteropathy, Intestinal and Systemic Manifestations Following Small Bowel Bypass. *JAMA*, 236:269, 1976.
4. Glassman, J. A.: An Artificial Ileocecal Valve. *Surg. Gynecol. Obstet.*, 74:92, 1942.
5. Griffen, W. O., Young, V. L. and Stevenson, C. G.: A Prospective Comparison of Gastric and Jejunioleal Bypass Procedures for Morbid Obesity. *Ann. Surg.*, 186:500, 1977.
6. Hyland, G., Stein, T. and Wise, L.: Abnormalities of Liver Function Following Extensive Jejunioleal Bypass and Resection in Rats. *Surgery*, 81:578, 1977.
7. Ikard, R. W.: Pneumatosis Cystoides Intestinalis Following Intestinal Bypass. *Am. Surg.*, 43:467, 1977.
8. Kock, N. G.: Intra-abdominal "Reservoir" in Patients with Permanent Ileostomy: Preliminary Observations on a Procedure Resulting in Fecal "Continence" in Five Ileostomy Patients. *Arch. Surg.*, 99:223, 1969.
9. O'Leary, J. P., Maher, J. W., Hollenbeck, J. I., et al.: Pathogenesis of Hepatic Failure after Obesity Bypass. *Surg. Forum*, 25:356, 1974.
10. Payne, J. H. and DeWind, L. T.: Surgical Treatment of Obesity. *Am. J. Surg.*, 118:141, 1969.
11. Passaro, E. Jr., Drenick, E. and Wilson, S. E.: Bypass Enteritis: A New Complication of Jejunioleal Bypass for Obesity. *Am. J. Surg.*, 131:169, 1976.
12. Richardson, J. D. and Griffen, W. O.: Ileocecal Valve Substitutes as Bacteriologic Barriers. *Am. J. Surg.*, 123:149, 1972.
13. Shrum, R. C., Williams, G. S., Allen, M. S., Jr., et al.: Simplified Technique of Ileocolostomy. *Surg. Forum*, 15:299, 1964.
14. Shrum, R. C.: Personal Communication, 1977.
15. Scott, H. W., Jr., Dean, R. H., Shull, J. H., et al.: Results of Jejunioleal Bypass in Two Hundred Patients with Morbid Obesity. *Surg. Gynecol. Obstet.*, 145:661, 1977.
16. Viddal, K. O. and Nygaard, K.: Intestinal Bypass in Rats. *Chir. Gastroenterol.*, 11:213, 1977.
17. Zheng, H., Onishi, S., Tanigawa, N., et al.: Manometric Evaluation of an Artificial Intestinal Valve. *Arch. Surg.*, 111:578, 1976.