

Formation and Fate of Fibrin Clots in the Biliary Tract:

A Clinical and Experimental Study

PHILIP SANDBLOM, VELIMIR MIRKOVITCH, FRÉDÉRIC SAEGESSER

Fibrin clots may form in the biliary tract from hemobilia or in inflammatory disease. There is a wide variation in the clinical course of such clots which is exemplified by 9 patients. They may either dissolve through fibrinolysis, get ejected into the intestine, remain and obstruct the biliary tract, or may even transform into gallstones. In order to elucidate the mechanisms involved, the behavior of blood clots in bile was studied *in vitro*. A model was constructed of the biliary tract and, drained by a T-tube, where human bile circulated with a flow rate resembling that *in vivo*. When a small amount of human blood was injected, it flowed immiscibly to the lowest level, displaced the bile, and formed a clot of pure blood. Even a minor bleeding may thus form a coagulum. This is different from the mixed clot of blood and bile that forms in experiments simulating major hemorrhage. These findings are related to clinical experience and especially to the disappearance of "retained stones" with or without the use of dissolving agents.

IN HEMOBILIA, or bleeding in the biliary tract, the blood will either drain directly into the intestine or it will partially coagulate within the tract. In a series of 355 cases from the world literature²² 70% had biliary colic and 60% had jaundice, indicating that blood clots had formed and were either passing or obstructing the biliary tract. Fibrin deposits may also develop from inflammatory exudation in infectious or traumatic cholangitis. (In the following text the term "clot" will include both blood coagula and fibrin deposits of other origins).

The resultant clots generally produce clinical symptoms. The object of the present paper is twofold — first to illustrate the variation in the clinical course with case histories, and secondly to elucidate certain of the salient features with data obtained from an experimental model *in vitro*.

From the Department of Surgery and the Department of Experimental Surgery, CHUV, University of Lausanne, Switzerland

Clinical Observations

It seems evident that in hemobilia, the formation of clots should be influenced by the character of the bleeding—whether it is profuse or scanty, prolonged or of short duration, continuous, solitary or repeated. It would also be expected that once the clots have formed, they would either dissolve, be expelled into the intestine or remain in the biliary tract.

The following case histories have therefore been selected to illustrate: 1.) The formation of blood clots in different kinds of hemorrhage; 2.) The formation of other fibrin clots; 3.) The fate of the clots, whether dissolved, expelled, diminished and then expelled, or persistent.

Case Reports

Formation of blood clots

In *profuse hemobilia*, the whole biliary tract will generally be rapidly gorged with large clots:

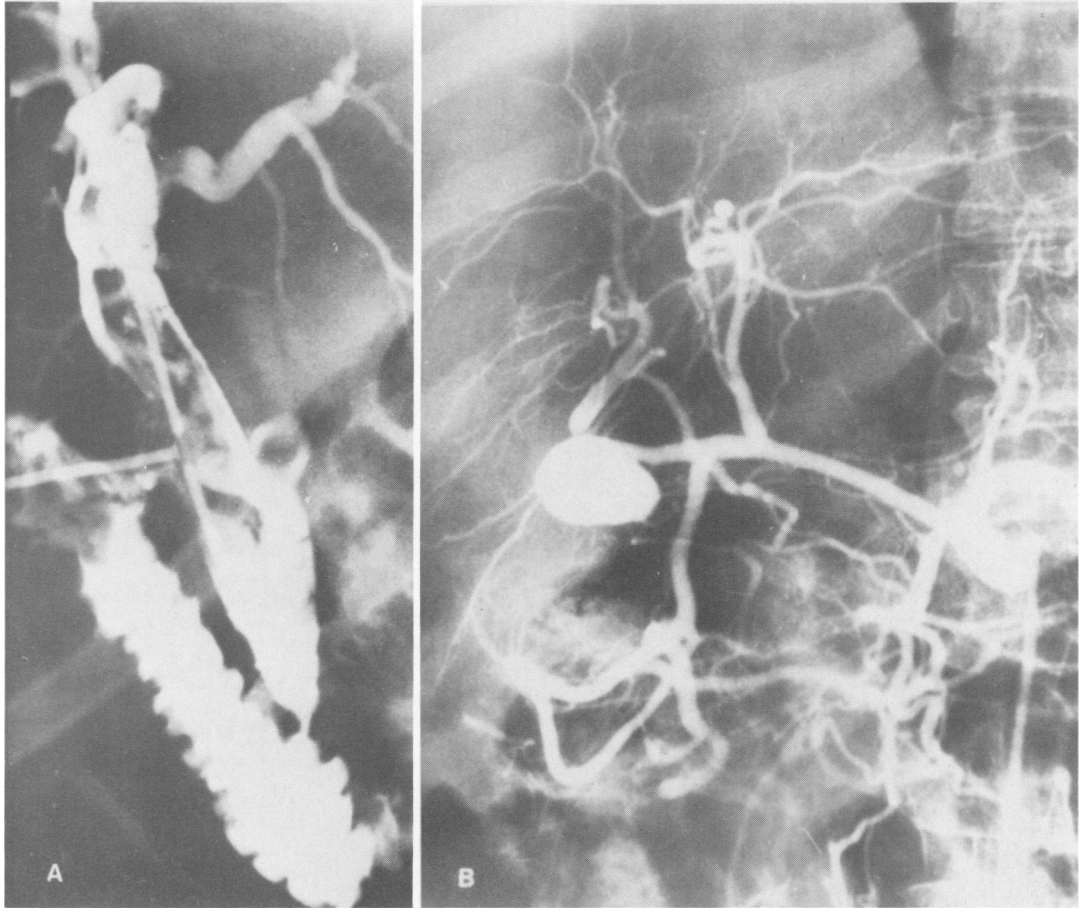
Case 1. (Lund Hospital)²². Two days after a difficult instrumental removal of common duct stones, the patient started to bleed profusely through the T-tube. Cholangiography showed large filling defects due to blood clots (Fig. 1A). Hepatic arteriography revealed the bleeding source, a false aneurysm that had been produced in the right hepatic artery (Fig. 1B). As usual, the extensive coagulation that occurred did not suffice to control the bleeding and after operative removal of the clots, a ligature of the right hepatic artery had to be performed.

A coagulum may form during instrumental exploration of the common duct even from *minor hemorrhage* and may have diagnostic consequences:

Presented at the annual meeting of the Southern Surgical Association, December 6–8, 1976, Palm Beach, Florida.

A discussion of this article by the members of the Southern Surgical Association will appear in May 1977 *Annals of Surgery*.

FIGS. 1a and b. Cholangio- and arteriogram in a patient with an operative lesion of the bile ducts. (a) Postoperative cholangiogram after profuse hemobilia: the large filling defects represent clots. (b) Hepatic arteriogram showing the source of the bleeding: a false aneurysm in the right hepatic artery, caused by instrumental lithotomy. (From Sandblom: Hemobilia, Charles C. Thomas Publ., Springfield, 1972).



Case 2. (Surgical Department, CHUV, Lausanne). Three stones (Fig. 2A) were extracted from a dilated common duct with some difficulty but without any disturbing bleeding. Repeated peroperative cholangiograms through the T-tube (Fig. 2B) showed a filling defect, which was suspected to represent a remaining stone. On re-opening

the duct, it was shown to be due to a fresh coagulum which was extracted. The cholangiogram (Fig. 2C) then became normal.

A blood clot may even form from an entirely *occult hemorrhage*:

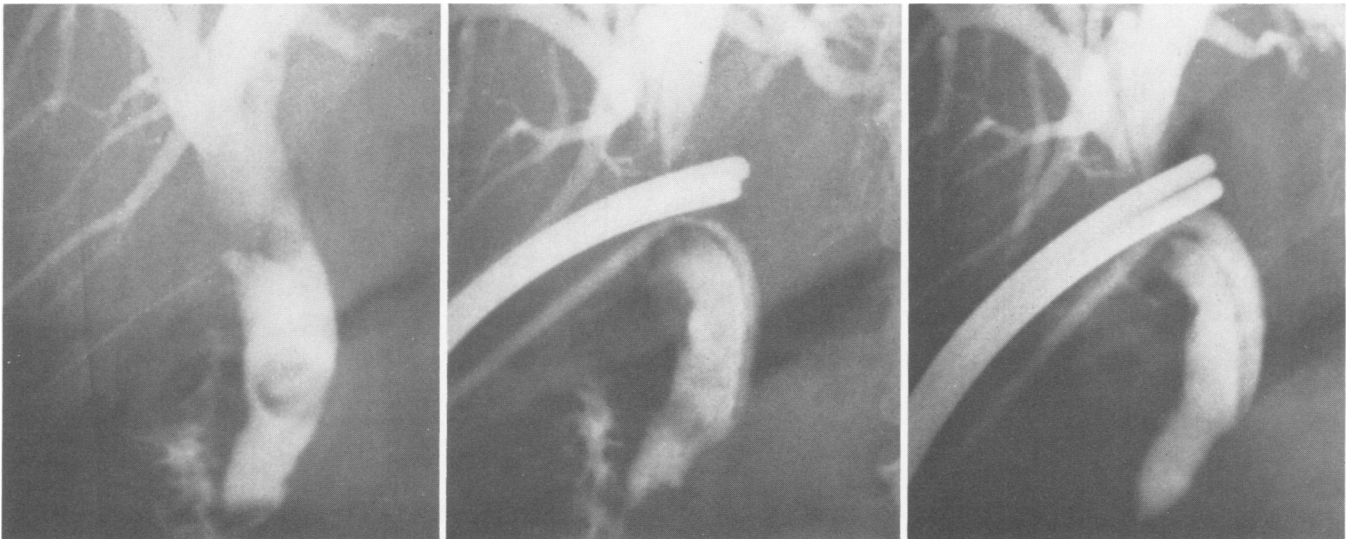


FIG. 2a-c. Operative cholangiograms during choledocholithotomy. (a) Three stones are visible before the duct was opened. (b) Three stones have been extracted; a later cholangiogram shows a defect thought to represent a remaining stone, but it was caused by a coagulum. (c) Normal cholangiogram after extraction of the blood clot.

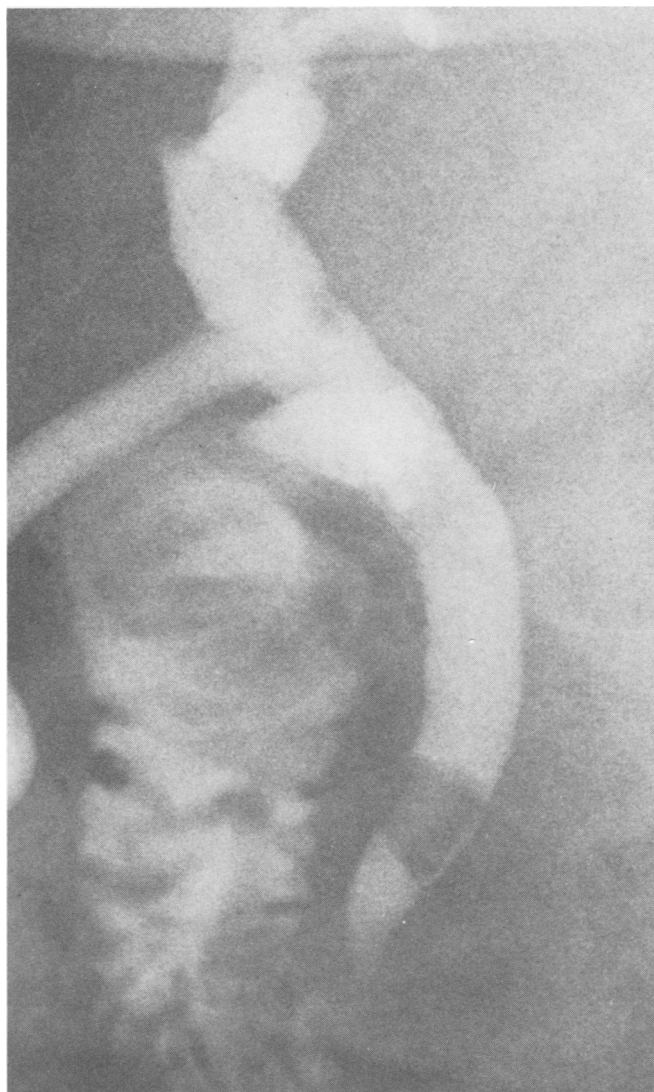

FIG. 3. Cholangiogram 3 weeks after choledocholithotomy. A defect thought to represent a remaining stone is observed; at re-laparotomy a blood clot corresponding to the defect was extracted, whereupon repeated cholangiogram was normal. (From Sandblom *et al.*: *J. Chir.* 109:137, 1975).

Case 3. (Surgical Department, CHUV, Lausanne)²³. During the operation of a woman with gallstones, a common duct stone was extracted and a cholangiogram was performed. This showed free passage to the duodenum and no sign of overlooked stones. A T-tube placed into the common duct drained clear bile for 3 weeks. At this time, a cholangiogram showed a filling defect, which was interpreted as a remaining stone (Fig. 3). At operation, however, it turned out that the defect was caused by a blood clot. This was extracted, whereupon the cholangiogram became normal.

Comment: As no hemobilia had been observed, the finding of a blood coagulum came as a surprise. The T-tube had not been clamped; thus the bile flow was continually diverted away from the clot. In retrospect, it must be said that the characteristics of the filling

defect observed correspond better to those of a fibrin clot than to those of a stone.

Formation of other fibrin clots

Fibrin clots may form, without hemorrhage, from an exudative inflammation of the biliary tract mucosa, either in primary cholangitis (Case 8) or from operative trauma:

Case 4. (Surgical Department, CHUV, Lausanne). A woman had a cholecystectomy for gallstones, and small stones were also retrieved from the common duct, whereupon the cholangiogram became normal. Because some difficulty was experienced in passing a catheter through the papilla, the sphincter was dilated. At repeated cholangiography, three and five weeks later, a filling defect interpreted as a remaining stone was consistently found moving around in the left hepatic duct (Fig. 4). At re-operation, several small

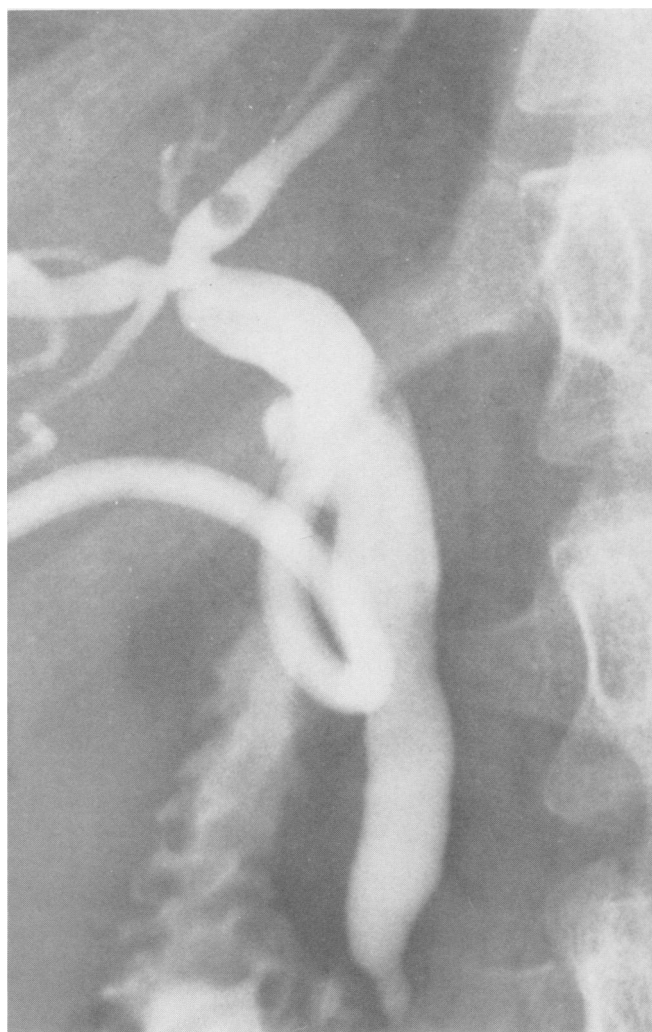


FIG. 4. Cholangiograms 3 and 5 weeks after operative extraction of small stones from the common duct consistently showed a defect in the left hepatic duct, diagnosed as a remaining stone. At re-operation, a fibrin clot corresponding to the defect was removed and the cholangiogram became normal.

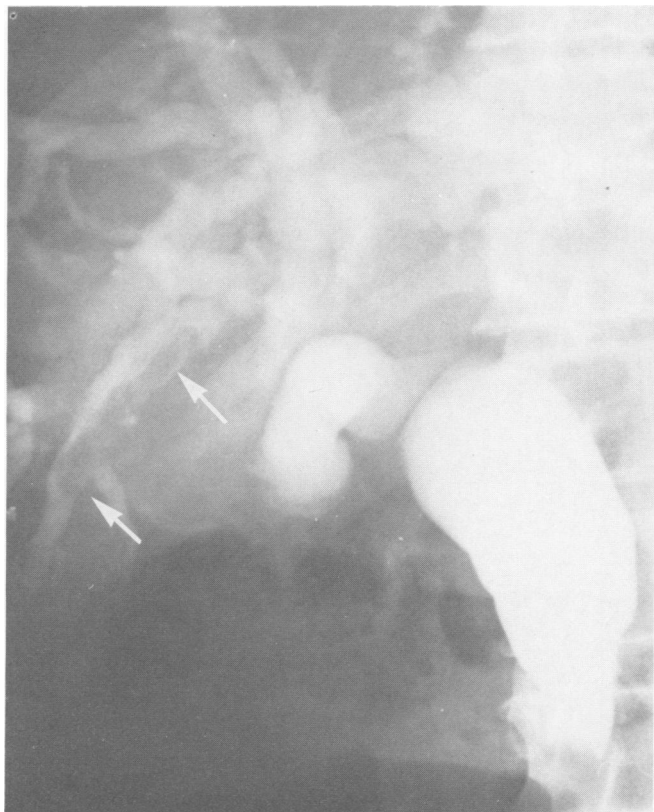


FIG. 5. Transhepatic cholangiogram half an hour after liver puncture in a patient with obstructive jaundice. There is an impacted stone at the ampulla and a four cm long defect in an intrahepatic bile duct representing a coagulum (between the arrows). At operation within 24 hours, it was found that the coagulum had been nearly totally dissolved.

fibrin morsels were found in the biliary tract and a round fibrin clot which corresponded to the defect in the cholangiogram was extracted. Postoperative cholangiography was normal.

Comment: The filling defect in this case was so suggestive of a stone that the finding of a fibrin clot instead came as a surprise. The clot was greyish white and did not look like a blood clot.

Fate of the fibrin clots

Dissolution. Sometimes the clots will have a rather ephemeral existence:

Case 5. (Veterans Hospital, San Diego). A patient with obstructive jaundice had a transhepatic cholangiography. About half an hour after liver puncture, the radiograms (Fig. 5) showed not only a distally impacted common duct stone, but also a 4 cm long filling defect in an intrahepatic duct. This was first suspected to be due to stones, but at operation the following day, it was evident that it had been caused by a blood coagulum, of which only some small red flakes now remained. An operative cholangiogram was normal after extraction of the impacted stone.

Comment: The coagulum could not have been expelled as there was a total obstruction at the papilla.

The rapid diminution in its size, probably because of fibrinolysis, is noteworthy. Even very large clots may disappear in this way. Grevertz^{9a} describes a case where a blood clot filling the entire gallbladder vanished within four months.

Expulsion. Very often the coagula will be ejected into the intestine — either promptly during the hemorrhage or later on, after having caused temporary obstruction.

Case 6. Larghero²² was able to film the actual expulsion through the Papilla of Vater (Fig. 6) after he had opened the duodenum in a case of intense gastro-intestinal bleeding.

Increased use of duodenoscopy will undoubtedly demonstrate on occasions the passage of clots into the intestine.³ Several cases have been reported^{7,10,20} where the patients have, after a bout of hemobilia, vomited clots formed like casts of the biliary tract. These have been described as being very firm and mixed with bile.

Case 7. Kiesewetter²² reported that a child, while being treated for traumatic hemobilia, vomited a long branched coagulum (Fig. 7). It was firm and of a brownish colour, indicating that it had been impregnated with bile pigment.

Combination of dissolution and expulsion. The disappearance of clot-like formations may be due to a combined effect of dissolution and ejection. The clot is

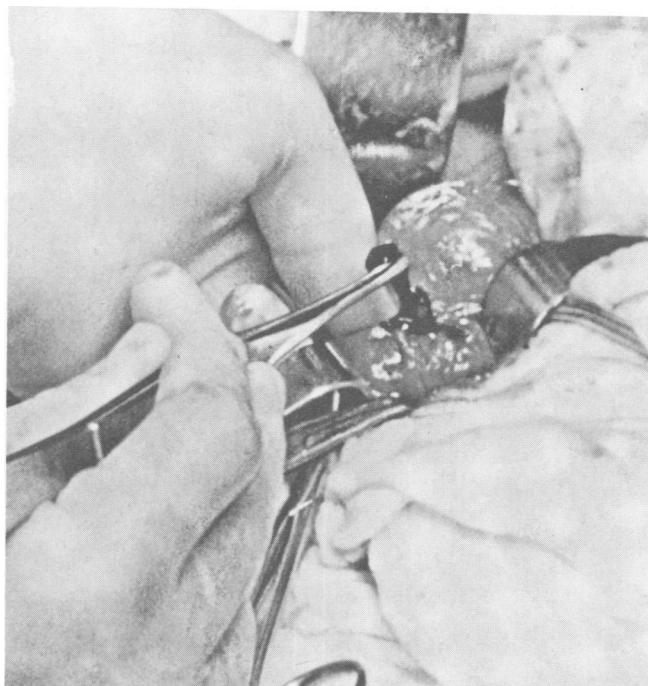


FIG. 6. Expulsion of a blood clot through the Papilla of Vater is seen when duodenotomy had been performed in a case of gastro-intestinal bleeding. The clot is a cast of the biliary tree. (From Sandblom: Hemobilia. Springfield, Charles C Thomas Publ., 1972).

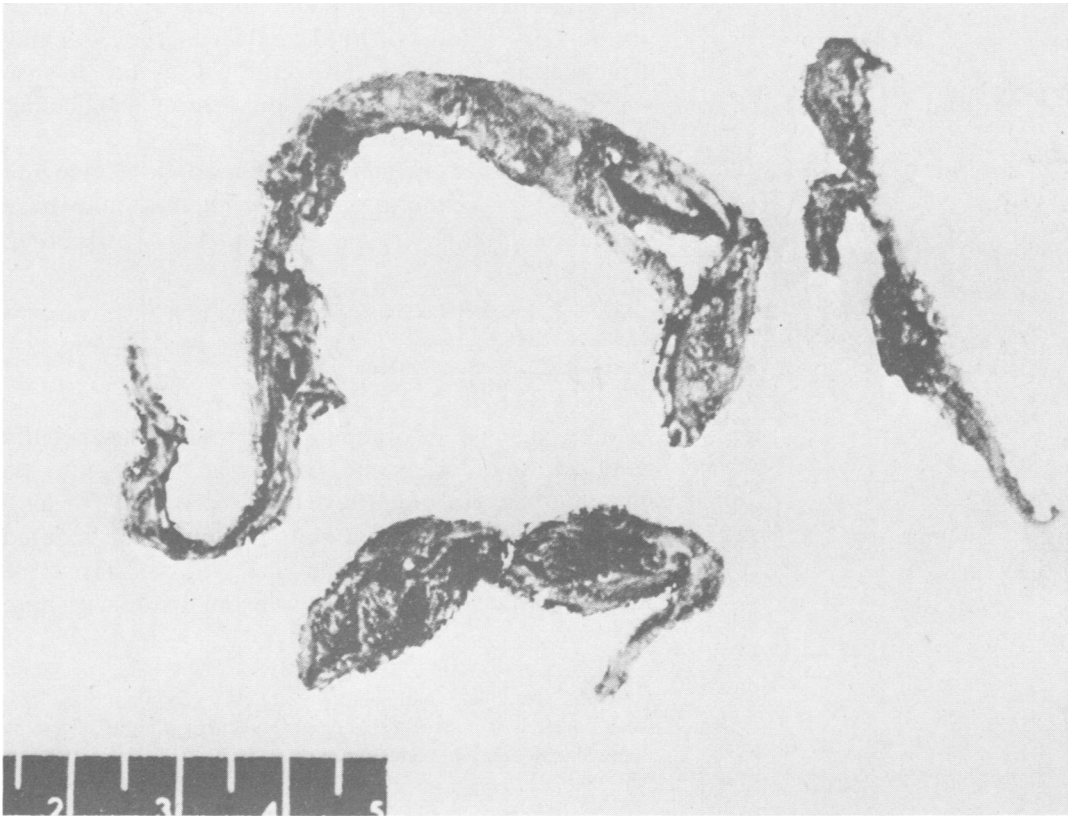


FIG. 7. A long branched coagulum, vomited by a child suffering from traumatic hemobilia. (From Sandblom: Hemobilia. Springfield, Charles C Thomas Publ., 1972).

likely to be expelled as soon as it is sufficiently reduced in size.

Case 8. (Surgical Department, CHUV, Lausanne). A woman with a history of progressive obstructive jaundice and fever had a small stone extracted from her common duct. Some fibrin flakes with

desquamated epithelial cells were retrieved from the portion above the papilla. At cholangiography 2 weeks later, there was an oval defect that moved down into the ampulla (Figs. 8A and B). The radiologist noted that it changed in form during the examination and therefore thought that it represented a clot rather than a stone. After 7 days of heparin infusion, the defect had disappeared (Fig. 8C).

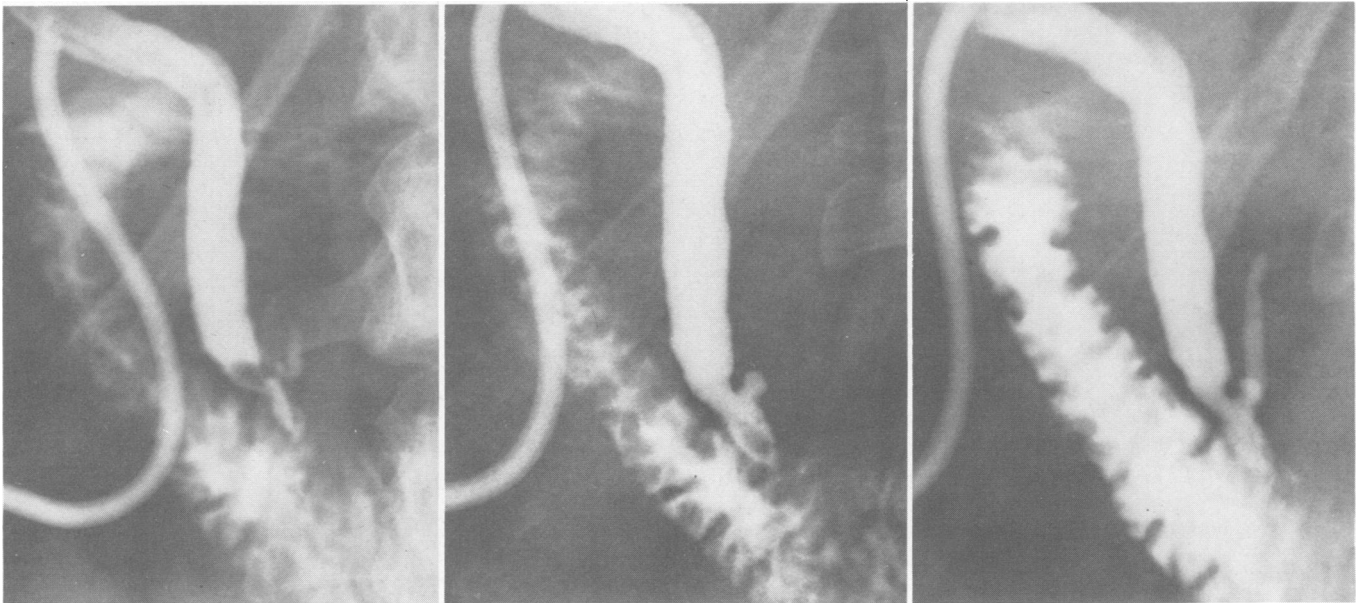


FIG. 8. Cholangiogram in a case of obstructive jaundice. (a and b) Cholangiograms 2 weeks after extraction of small common duct stone and fibrin flakes with desquamated epithelial cells show an oval defect changing in form during the examination, and moving down into the ampulla. (c) Disappearance of the defect after 7 days of heparin perfusion.




FIG. 9. A blood clot which had totally obstructed the common duct of a patient with a stone-filled gallbladder. There had been no signs of bleeding. The clot is a cast of the papillary region. (From van der Linden: *Acta Chir. Scand.* 141:445, 1975).

Comment: Although the nature of the defect was not proven in this case, it was most probably due to a fibrin clot produced by the cholangitis. The rapid disappearance can best be explained by a combination of dissolution and/or expulsion into the intestine. The heparin perfusion might only have had a mechanical effect, as heparin does not dissolve blood clots. Perfusion with a fibrinolyzing agent may add to the dissolving effect of the bile. Ammann^{1a} observed the disappearance of a coagulum following washouts with streptokinase.

Persistent clots. Sometimes the clots will remain in the biliary tract and will then act like gallstones, causing biliary colic and obstructive jaundice or cholecystitis.²² Operative removal is often inevitable (Fig. 10).^{6,11,13,19,-21,26,28} Van der Linden's¹⁴ case is a good example of this group:

Case 9. (Östersund Hospital). A woman was admitted with a 2-day history of biliary colic and jaundice. Tests for occult blood in the stool were negative on several occasions. The jaundice subsided but recurred a few days later. At operation the gallbladder was found to contain stones. In the common duct there was one large blood clot which virtually filled the whole lumen. Clots were removed from its proximal end and bile then started to drip. The part of the clot occupying the distal end was firm and could be removed in toto (Fig. 9). At cholangiography, it was noted that the size and the shape of the common duct were identical with that of the clot.

Comment: The varying quality of the clot at different levels suggests that it had formed gradually. Although tests for blood in the stool were negative, there must have been repeated minor bleedings, probably from hemorrhage into the stone-filled gallbladder. Because of the total obstruction, the coagulum was protected from the bile stream and its fibrinolyzing effect. Clots which remain in the biliary tract will eventually get incrustated with bile salts and pigment. Olsen^{18a} de-

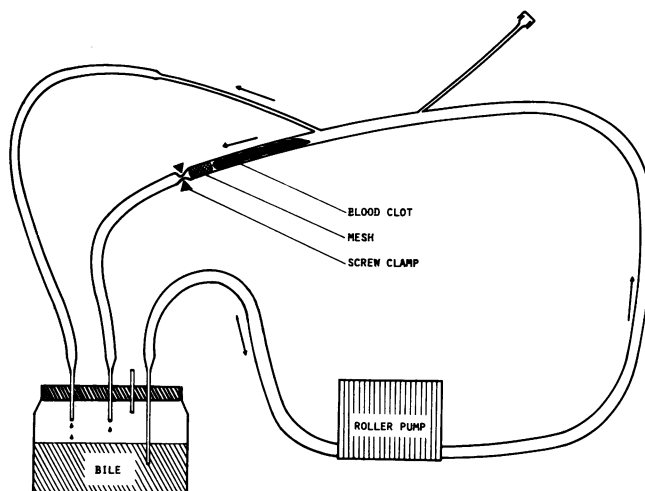


FIG. 10. Polyvinyl chloride tubing model of the extrahepatic biliary tract with the hepatic ducts to the right. The top outlet to the left represents a common duct drain or the cystic duct. The screw clamp represents the Sphincter of Oddi. The mesh represents the mucosal folding of the Ampulla of Vater.

scribes a case of traumatic hemobilia in a fourteen year old boy with radiolucent defects in the gallbladder, presumably due to clots. Initially, these gradually decreased in size, but after two years, they developed radio-opaque halos. Cholecystectomy was performed and the gallbladder was found to contain multiple small pigment stones.

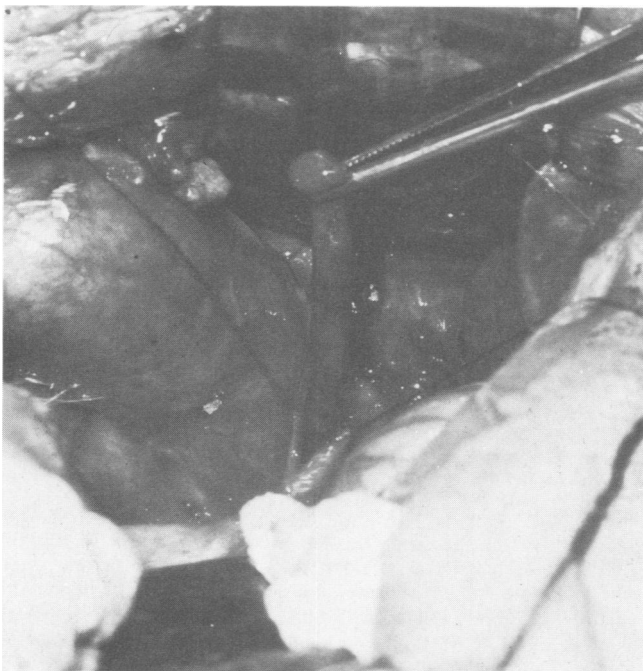

FIG. 11. A blood clot which had caused total obstruction is extracted from the opened common duct. Its firm consistency is evident (From Wilkinson et al.: *Surg. Clin. N. Am.*, 48, 1968).




FIG. 12a-c. Polyvinyl chloride tubing model of the extrahepatic bile ducts. The needle on the left provides an outlet for the bile flow and represents a common duct drain (or the cystic duct). The clamp on the left represents a closed sphincter as depicted in Figure 11. Blood injected into bile streaming through the system flows immiscibly to the lower portion and forms a pure coagulum. This occurs independently of the site of injection, whether high up (top and center) or through the upper wall (bottom).

Experimental Investigations

The cases described show a great variety in the formation and the fate of fibrin clots in the biliary tract and of the clinical events that they cause.

The underlying pathophysiology is partially well known but some circumstances remain obscure. Already 100 years ago, another surgeon, Quincke,²⁰ puzzled by the appearance of long, stringy blood-clots in the stool and in the vomits of a patient with biliary tract hemorrhage, tried to explain their formation experimentally. He failed however as he had the erroneous idea that these clots had formed in the jejunum and injected the blood into the gut of his animals instead of into their biliary tract. The following points needed further investigation: 1) The behavior of the blood when entering the bile stream either in profusion or in small amounts, eventually to coagulate within the ducts. 2) The mechanism of dissolution of these clots in the bile, and the role of the streaming bile in the process.

In order to obtain more precise information about these points, some experiments were performed in vitro. With the use of polyvinyl chloride tubing, a model was constructed to represent the hepatic and the common duct drained by the cystic duct or by a T-tube (Fig. 11). A hemostat or a screw clamp applied to the lower end represented the Sphincter of Oddi. A little piece of plastic mesh was introduced into the lumen above the clamp to represent the mucosal folding of the Ampulla of Vater.

The model was filled with human hepatic bile obtained from otherwise healthy patients with common duct drains. With the aid of a roller pump, this was made to circulate at a rate of 2 ml/min, resembling the normal flow in healthy humans.

When the screw clamp was tightened all the bile flowed through the T-tube; when opened some of it also flowed through the "sphincter". The model is a very crude reproduction of the human biliary tract with its epithelial lining and soft structure. We have refrained from drawing specific conclusions regarding e.g. coagulation time and blood clot structure.

Bleeding into the tract.

Major bleeding. In most cases of profuse bleeding into the biliary tract, as illustrated in Case 1, large blood coagula will promptly form. It would be enlightening to watch what happens when a large amount of blood suddenly enters the bile stream with a pressure corresponding to the arterial blood pressure.

Five milliliters of fresh human blood were injected into the upper end of the system with a speed and at a pressure corresponding to a hemorrhage from one




FIG. 13a-d. A similar type of model, now in two systems where the part representing the common duct drain has been replaced by tubing. (a) (top) The "sphincters" are closed and the bile is evacuated through the "common duct drain". The same amount of blood has been injected in the two systems and has collected in the lowest region. (b) (center) Contraction of the blood clots about one hour after injection of the blood. In the lower system, the "sphincter" is then opened to allow drainage of about 1/10 of the bile flow. (c) (bottom) and (d) (following) 20 hours later the clot in the perfused system has diminished to 1/5 in weight of that where the bile flow has been entirely bypassed.

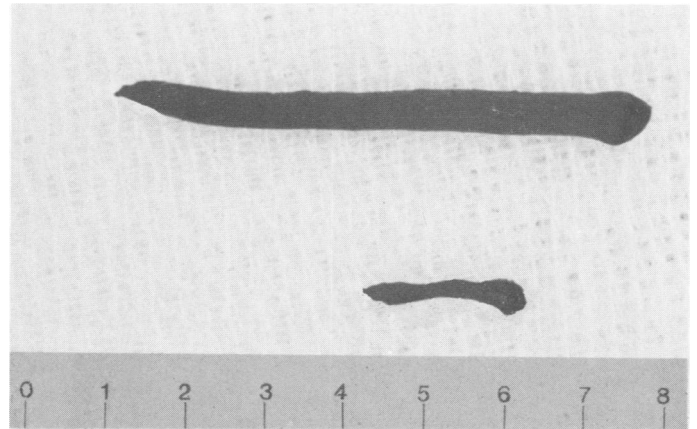


FIG. 13d. (See legend for Fig. 13C.)

of the main hepatic arteries. The blood partly mixed with the bile, partly replaced it. Some of it drained through the "T-tube", some of it collected above the "sphincter". After 20 minutes, this collection was examined. It contained a mushy blood clot in an unclotted mixture of blood and bile, some of it light red, some dark red. The clot did not contract normally and it partly liquified when kept in a humid chamber for 12 hours.

Minor bleeding. 0.25 milliliters of fresh human blood were injected into the uppermost part of the system through a fine needle with a speed and at a pressure corresponding to a hemorrhage from a small artery (Fig. 12). It did not mix with the bile but flowed immiscibly to the bottom of the system (above the "sphincter", bypassing the T-tube) where it collected, and formed a clot of pure blood. This contracted normally and remained solid when kept in a humid chamber for 12 hours.

Comment: It seems that because of the difference in specific gravity (1.055 of the blood and 1.010 of the bile) and in surface tensions of the two fluids (60 dynes/cm of the blood and 40 dynes/cm of the bile), they do not mix easily.

Our findings indicate that a minor or occult hemorrhage suffices to form a clot of pure blood as seen in Case 3.

Dissolution of the clots and the role of the streaming bile

It is known that the bile has a pronounced fibrinolytic effect.^{16,17,18} The rapidity and efficiency of this reaction is well illustrated in Case 5. In a series of our experiments where blood had coagulated in test tubes filled with bile, the coagulum was left in the bile at 37°. One day later it was found, by the method of staphylococcal aggregation, that the bile with its coagulum contained up to 4 times more fibrinogen

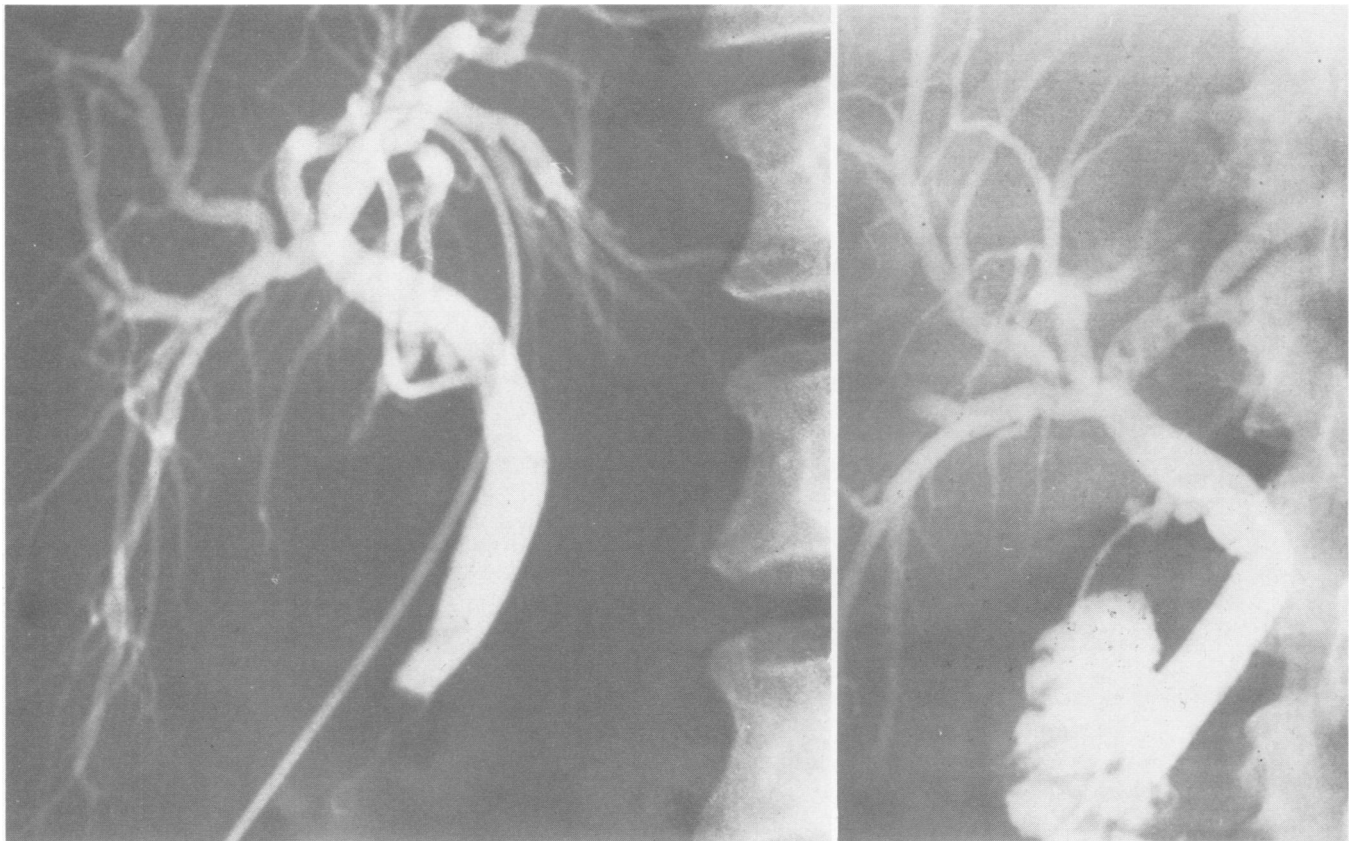


FIG. 14 a and b. (a) Postoperative cholangiogram on the 10th day after removal of 14 small stones from the biliary tract. A defect thought to be a remaining calculus at the lower end is seen. It disappeared after 3 washouts during 1 week with normal saline and lignocaine. The defect looks like a cast of the lower part of the common duct. (b) Preoperative cholangiogram lent to us by the courtesy of the authors¹ showing the small rounded stones located in the left hepatic duct. They do not resemble the defect in a. (From Catt *et al.*: Ann. Surg. 180:247. 1974).

split products than a blood clot that had not been in contact with the bile.

In order to study the influence of the bile stream on the clots, their behavior was compared in two of our models; in the first the whole bile stream was diverted through the T-tube and in the second, bile was also allowed to flow around the clot and down through the "sphincter".

0.25 ml of fresh human blood was injected into each of the systems with the screw clamps closed. It flowed to the lower part of the "common duct" (Fig. 13A) where it was left to coagulate and to contract for an hour (Fig. 13B). While the clamp was kept closed in the first system, it was partially opened in the second system to allow about 1/10 of the bile to flow around the coagulum (Fig. 13C).

The influence of this perfusion-washing was assessed by measuring the length of blood clots before and after a 20-hour perfusion (Fig. 13D) and by determining the weight of the clots at the end of this perfusion. The degree of statistical significance was determined by analysis of covariance for the change in length and by random block analysis of variance for the weight.

In eight experiments, the initial length of the non-perfused clots was 23 ± 2.4 mm, and the length of those to be perfused was 22 ± 2.3 mm. After 20 hours' perfusion, the length of the non-perfused clots remained unchanged at 23 ± 1.9 mm while the perfused clots significantly diminished in length to 11 ± 2.7 mm ($p < 0.001$). At the end of 20 hours' perfusion and in seven experiments, the weight of non-perfused clots was 113 ± 48.6 mg, while that of the perfused clots had decreased to 22 ± 6.4 mg ($p < 0.001$).

Comment: The experiments show that the fibrinolytic effect depends on the character of the contact between the clot and the bile flow. When the clot is continually washed in the flow, it is dissolved in about 24 hours; when the flow is side-tracked, and the clot rests in stagnating bile; it remains essentially intact.

Discussion

In *profuse biliary tract hemorrhage*, the blood promptly coagulates, as demonstrated in Case 1. In our experiment, when blood was injected with the force of an arterial hemorrhage into the bile stream, it mixed

with the bile and part of it clotted. We know that even after mixing, blood will clot as long as its proportion exceeds 70%.^{16,22} Bile evidently does not prevent blood from clotting, in spite of the presumed anticoagulant action of bile found by Garagnani.⁸

Formation of blood clots in *minor or occult biliary tract hemorrhage* has not previously attracted attention. One would rather expect, as Portal already did 2 centuries ago,²² that the blood in such an event would remain fluid and drain into the intestine. That this does not always happen is demonstrated in Cases 3 and 9. The explanation is given in our experiments showing that the blood has a tendency to remain separate from the bile and that a pure coagulum will form from a narrow stream of blood through the bile flow (Fig. 12). There is thus a marked difference between the pure blood clot formed in the experiments that imitate minor hemorrhage, and the mixture of blood and bile with partial clotting that occur in the experiments that simulate major hemorrhage.

If such clot formation from minor bleeding occurs frequently in patients, its clinical significance has probably been overlooked. It is a common experience that minor hemorrhage often accompanies exploration of the common duct and they occur in 30% of cases with acute cholecystitis and cholangitis.^{13,26}

Our Case 2 demonstrates the diagnostic problems arising from such immediate coagulation. If the clot escapes fibrinolysis, it will resemble and easily be mistaken for a calculus as in Cases 3 and 4. It is impossible to say how often such a mistake is being made. The following case is probably an example:

In the *Annals of Surgery* of 1975,⁴ a case of successful dissolution of an "overlooked stone" is described. On examination of the cholangiogram (Fig. 14a), the defect is triangular like a cast of the lower common duct. The 14 stones that were removed were small and appear round on the cholangiogram (Fig. 14b). The fact that the defect disappeared after a week of intermittent saline washouts increases the suspicion that it was caused by a coagulum rather than by a stone.

Fibrin clots of inflammatory origin also contain leukocytes and desquamated cells (Case 8), but their clinical behavior is on the whole not different from that of blood clots. In cholecystitis and cholangitis, there may also be bleeding from the hemorrhagic mucous membrane with blood clot formation.^{13,19}

Conversion of clots into gallstones may occur eventually as documented by Olsen.^{18a} The brown color of the clots sometimes reported^{10,22} indicates that they are impregnated with bile. One can speculate whether they may represent some so-called primary common

duct stones described by Aschoff¹ and discussed by Madden¹⁵ as consisting of "biliary mud".

The fibrinolytic effect of bile is well known.^{17,18} The rapidity and the efficiency of the mechanism is illustrated in Case 5. Split products of fibrinogen were also demonstrated in our experiments. The clearance of fibrin from the biliary tract is comparable with a similar situation in the peritoneal cavity, where fibrinolysis can be complete in 15 minutes,¹² and in the urinary tract.² Olesen¹⁸ said that "the influence of bile acids on fibrinolysis can tentatively be attributed a physiologic significance for the maintenance of free passage in the biliary tract through removal of occasional fibrin deposits." From a teleological point of view, this is an expression of nature's efforts at auto-repair. The fibrinolytic effect of bile is however not always beneficial, as it is the main cause for the slow healing of liver wounds.²⁴

Bearing in mind the fibrinolytic effect of bile, reports of successful dissolution of "remaining stones" through perfusion with various media^{9,25,27} should be re-assessed, it might occasionally just have been a question of fibrinolysis and expulsion of clots, as in Case 8 and probably in the above-mentioned case of Catt.⁴ This could also partly explain the fact that 20% of "overlooked stones" disappear in time. A coagulum will often be a cast of the viscus where it is formed: cylindrical in the canal (Fig. 3), triangular in the lowest portion (Fig. 14A) and branched in the biliary tree (Fig. 7). This might be of help in the differential diagnosis.

Our experiments in vitro demonstrate the obvious fact that a free flow of bile around the coagulum is an important condition for rapid fibrinolysis.

The persistence of clots can thus often be explained by a failure of biliary perfusion. Clots in the gallbladder will often remain and may cause cholecystitis.^{10,22} If a common duct drain is left open for some time, a coagulum below the draining point will be shielded and will remain intact as in Case 3 and in our model.

When a clot produces a total obstruction, no bile will pass it naturally, and it will remain until expelled into the intestine²² or until removed operatively as in Case 9. Eisold⁵, in describing a similar case, points to a stenosed papilla as a predisposing factor.

In continuous or repeated bleeding, the fibrinolysis might not keep pace with the coagulation and a multi-layered clot will result (Case 9).

Our clinical and experimental observations show that a free body in the biliary tract is not necessarily a stone. It may be a fibrin deposit or a blood clot even if no hemobilia has been observed. If this

is the case, an operative removal will not be necessary; the fibrinolytic effect of the bile will often suffice to clear the biliary tract. The surgeon must avoid measures that prevent the bile from exerting this action, i.e., he must not have a T-tube unclamped for a long time in the post-operative period. If a suspected clot still remains, washouts with bile or streptokinase may be tried. If a clot continues to cause a total obstruction which also helps it to escape fibrinolysis, it will eventually have to be extracted.

Conclusion

Profuse bleeding into the biliary tract produces mixed clots of blood and bile while minor bleeding produces pure blood clots. These clots act as gallstones and may be mistaken for such. They may even eventually convert into stones. Clots should always be suspected when defects appear in postoperative cholangiograms. Bile flow dissolves clots, but they remain intact when protected from the flow. The formation of clots may be avoided by control of hemorrhage. If they form, their dissolution may be stimulated by restoration of bile flow.

Acknowledgment

We wish to acknowledge the help of Dr. J. W. L. Robinson with the statistical analyses and the linguistic accuracy.

References

- 1a. Ammann, J.: Personal communication.
1. Aschoff, L.: Lectures on Pathology. New York, Paul B. Hoeber, 1924.
2. Astrup, T.: The Biologic Significance of Fibrinolysis. *Lancet*, 11:565, 1956.
3. Brintnall, B. B., Laidlaw, W. W., and Papp, J. P.: Hemobilia: Pancreatic Pseudocyst Hemorrhage demonstrated by Endoscopy and Arteriography. *Am. J. Dig. Dis.*, 19: 186, 1974.
4. Catt, P. B., Hogg, D. F., Clunie, G. J. A., et al: Retained Biliary Calculi. *Ann. Surg.*, 180:247, 1974.
5. Eisold, G.: Über Blutungen aus den Gallenwegen. *Chirurg*, 32:32, 1961.
6. Fisher, E. R., and Creed, D. L.: Clot Formation in the Common Duct. *Arch. Surg.*, 73:261, 1956.
7. Földvari, G., Széchy, M., and Köves, I.: Hämobilie mit tödlichen Ausgang. *Chirurg*, 34:83, 1963.
8. Garagnani, A., and Facchini, G.: Influenza della bile e dei sali biliari sul — l'emocoagulazione "in vitro" con particolare riguardo all'attività antitrombinica. *Arch. Patalog. Med.*, 33: 203, 1957.
9. Gardner, B.: Experiences with the Use of Intracholedochal Heparinized Saline for the Treatment of Retained Common Duct Stones. *Ann. Surg.*, 177:240, 1973.
- 9a. Grevertz, B. C., and Olsen, W. R.: Hepatostomy for Central Hepatic Hepatomas. *J. Trauma* 15:271, 1975.
10. Hawthorne, H. R., Oaks, W. W., and Neese, P. H.: Liver Injuries with a Case Report of Repeated Hemorrhages through the Biliary Ducts. *Surgery*, 9:358, 1941.
11. Johns, W. A., and Zimmerman, A.: Biliary Obstruction due to Hemobilia caused by Liver Cell Carcinoma. *Ann. Surg.*, 153:706, 1961.
12. Kieninger, G., Neugebauer, W., Gayer, M., et al: The Behaviour of Blood in the Peritoneal Cavity. *Eur. Surg. Res.*, 8, suppl. 1:106, 1976.
13. Koch, H.: Ursachen kryptogener Intestinalblutungen. 1. Die Hämobilie. *Brun. Beitr. Klin. Chir.*, 211:246, 1965.
14. van der Linden, W.: Hemobilia: A Case with recurrent Jaundice cured by Removal of Blood Clot from the Common Bile Duct. *Acta Chir. Scand.*, 141:445, 1975.
15. Madden, J. L., Vanderheyden, L., and Kandalaft, S.: The Nature and Surgical Significance of Common Duct Stones. *Surg. Gynecol. Obstet.*, 126:3, 1968.
16. Merendino, K. A., Dillard, D. H., and Commock, E. E.: The Concept of Surgical Biliary Decompression in the Management of Liver Trauma. *Surg. Gynecol. Obstet.*, 117:285, 1963.
17. Norén, J., Ramström, G., and Wallén, P.: Fibrin Plate Method with Reagents Purified by Affinity Chromatography and its Use for Determination of Fibrinolytic and other Proteolytic Activity in Saliva, Bile and Plasma. *Haemostasis*, 4:110, 1975.
18. Olesen, E. S.: Activation of Fibrinolysis in Guinea-pig Serum by Bile Acids. *Thromb. Diath. Haemorrh.*, 4:473, 1960.
- 18a. Olsen, W. R.: Personal communication.
19. Quast, M., and Clauss, D.: Verschlussikterus durch Hämobilie. *Zbl. Chir.*, 96:618, 1971.
20. Quincke, H.: Ein Fall von Aneurysma der Leberarterie. *Berl. Klin. Wschr.*, 8:349, 1871.
21. Rudström, P.: Hemobilia in Malignant Tumors of the Liver. *Acta Chir. Scand.*, 101:243, 1951.
22. Sandblom, Ph.: Hemobilia. Springfield, Ill., Charles C Thomas, 1972.
23. Sandblom, Ph., Rostan, O., Benz, G., et al: L'Hémobilie. A propos de cinq observations. *J. Chir.*, 109:137, 1975.
24. Sandblom, Ph., Mirkovitch, V., and Gardiol, D.: The Healing of Liver Wounds. *Ann. Surg.*, 183:679, 1976.
25. Sim, A. J. W., Campbell, E. H. G. and MacKay, L.: The Effect of Sodium Cholate and Heparin on Gallstone Dissolution *in vitro*. *Br. J. Surg.*, 63:154, 1976.
26. Stahl, W. M.: Gastrointestinal Tract Hemorrhage due to Gallbladder Disease. *N. Engl. J. Med.*, 260:471, 1959.
27. Way, L. W., Admirand, W. H., and Dunphy, J. E.: Management of Choledocholithiasis. *Ann. Surg.*, 176:347, 1972.
28. Wilkinson, G. M., Mikkelsen, W. P., and Berne, C. J.: The Treatment of Posttraumatic Hemobilia by Ligation of the Common Hepatic Artery. *Surg. Clin. North Am.*, 48:1337, 1968.