

# Extrahepatic Biliary Obstruction by Metastatic Colon Carcinoma

ANDREW L. WARSHAW, M.D., JOHN P. WELCH, M.D.\*

Extrahepatic biliary obstruction can be caused by cancer metastatic from the colon to the lymph nodes adjacent to the bile duct. This report details our experience with eight such cases treated at the Massachusetts General Hospital in the last seven years. The interval between resection of the primary tumor and appearance of jaundice averaged 13 months. The location of the obstruction, preferably defined preoperatively by cholangiography, was low on the common duct in three cases and high in the porta hepatis in five. Relief of biliary obstruction was accomplished by biliary-enteric bypass (four cases), internal biliary stenting by permanent indwelling tube (two cases), or by portal irradiation (two cases). In addition to palliating the symptoms of obstructive jaundice, the period of comfortable survival appears to have been extended: the bypassed patients lived 13–38 months. Erosion of tumor into the duodenum, with resulting gastrointestinal hemorrhage, was an additional problem in three patients. Our overall experience illustrates the value of distinguishing this subgroup of patients from the larger number whose jaundice results from extensive liver metastases, and of treating aggressively those with extrahepatic biliary obstruction.

**J**AUNDICE IS A COMMON late feature of uncontrolled colon carcinoma and usually signifies extensive hepatic metastases.<sup>9,14</sup> In this setting the onset of jaundice is a grave event, with a median subsequent survival time of only 33 days.<sup>9</sup> Death eventuates from hepatic failure due to replacement of the liver by cancer.

There is, however, a distinctly different subgroup of patients, whose jaundice is caused not by parenchymal destruction but by extrahepatic biliary obstruction. In these individuals metastases to lymph nodes behind the duodenum, along the common duct, or higher in the porta extrinsically compress the common duct. It has been our experience that the liver in these individuals is frequently free of gross metastases and that bypass operations to decompress the biliary tree may lead to comfortable survival for relatively long periods. We

*From the Surgical Services of the Massachusetts General Hospital and the Department of Surgery, Harvard Medical School, Boston, Massachusetts*

report here eight unselected cases to exemplify the potential for significant palliation of this complication of colon carcinoma.

## Materials and Methods

From January 1, 1971 to December 31, 1977, we have treated or had direct contact with eight patients at the Massachusetts General Hospital who have proved to have extrahepatic biliary obstruction caused by colon carcinoma metastatic to nodes adjacent to the bile ducts. These patients are not the result of a search among all colon carcinoma patients seen at this institution (150 cases per year) and thus yield a minimum incidence of this phenomenon. Because we included all patients that we knew to have extrahepatic biliary obstruction due to metastatic colon carcinoma, the experience should be fairly representative. All patients were followed to death or to the present time.

## Results

The cases are summarized in Table 1. Note that two of the patients were very young men. The spectrum of primary cancers was unremarkable. All were adenocarcinomas and all were invasive to mesenteric lymph nodes or through the serosa to surrounding structures at the time of the original colon resections. The interval between resection of the primary colon carcinoma and the appearance of jaundice averaged 13 months (range, 0–25 mo).

The jaundice was initially thought to be due to hepatitis in six of the eight cases. This erroneous clinical impression was based upon the general well-being of the patients in other respects. That is, they did not have the usual hallmarks of advanced cancer: weight loss, pain, fever, malaise, or fatigue. Blood chemistries, however, were typical of obstruction. Elevated alkaline

\*Current address: Hartford Hospital, Hartford, Connecticut.

Reprint requests: Andrew L. Warshaw, M.D., Department of Surgery, Massachusetts General Hospital, Boston, Massachusetts 02114.

Submitted for publication: March 27, 1978.

TABLE 1.

Pt.	Age, Sex	Primary Cancer	Interval to Onset of Jaundice (months)	Maximum Bilirubin (mg/100 ml)	Level of Bile Duct Obstruction	Method of Biliary Decompression	Survival after Decompression (months)	Other Treatment
1	66, F	Sigmoid	0	16	Duodenum	Choledochojejunostomy	38	Stenting through re-obstruction at 2 years
2	67, F	Sigmoid	5	14	Hilum	Right hepatic cholangiojejunostomy	17	5-FU (no benefit)
3	22, M	Ascending colon	10	10	Duodenum	Choledochojejunostomy, gastrojejunostomy	36	Splenorenal shunt 2 years later
4	21, M	Transverse	24	6	Hilum	T-tube	1	None
5	68, F	Hepatic flexure	10	9	Duodenum	Choledochojejunostomy, gastrojejunostomy	13	3000 r, 5-FU + BCNU (no benefit)
6	63, M	Rectosigmoid	25	20	Hilum	3750 r	14	Ligation and embolization of bleeding malignant duodenal ulcer at 6 months
7	56, M	Cecum	12	10	Hilum	4000 r	5	5-FU (no benefit)
8	58, F	Sigmoid	21	28	Hilum	Transhepatic tube	10 (living)	5-FU

phosphatase and elevated conjugated bilirubin were the predominant abnormalities, with lesser increases in transaminases. The nature and exact location of the obstruction were demonstrated by percutaneous transhepatic cholangiography (Fig. 1), endoscopic retrograde cholangiography (Fig. 2), or operative cholangiography (Fig. 3). In three cases the obstruction was located at the lower common duct at the level of the duodenum, and in five it was high in the porta at the hepatic duct bifurcation. In seven of eight patients there were no apparent liver metastases at the time of onset of obstructive jaundice. The eighth patient had one 2 cm nodule in the left lobe of the liver.

The three lower common duct obstructions were treated by Roux-en-Y choledochojejunostomy. Two of these were complemented by gastrojejunostomy because of invasion of the duodenum as well. The five high obstructions were treated by hepaticojejunostomy (Case 2), by insertion of a T-tube past the obstructed point (Case 4), by placement of a percutaneous transhepatic tube past the tumor down into the common duct (Case 8), or by radiation therapy (Cases 6 and 7).

Palliation was good to excellent in all successfully bypassed cases. Survival in these patients ranged from 13 to 38 months. Two patients were asymptomatic for more than two years (Fig. 4) and one for more than one year. One of the long-term survivors (Case 1) was re-

operated upon 26 months after choledochojejunostomy and a tube inserted through the anastomosis to reestablish bile drainage past the enlarging tumor which had reobstructed bile flow. The other long-term survivor (Case 3) had a splenorenal shunt 25 months after bypass because of splenic and portal vein obstruction causing portal hypertension and bleeding esophageal varices.

Bleeding from malignant ulceration into the duodenum (Fig. 5) was a major recurrent problem in three patients (Cases 1, 3 and 6), requiring transfusion therapy and further operations.

Postoperative adjunctive chemotherapy was used irregularly and without apparent benefit. Irradiation of the portal nodes was used in three cases, once (Case 6) producing complete and sustained relief of jaundice.

### Discussion

Metastases to lymph nodes along the common duct and in the port hepatitis may originate from primary carcinomas of the colon,<sup>7</sup> breast,<sup>12</sup> lung,<sup>1</sup> as well as from melanoma<sup>6</sup> or lymphoid neoplasms.<sup>3,7</sup> It is of particular importance that, at least with colon carcinoma, these periportal nodal metastases seem to occur surprisingly frequently without tumor in the liver itself, for "It is the presence of hepatic metastases rather than

any associated extrahepatic spread of the neoplasm which governs prognosis.<sup>17,9</sup> When the liver contains metastases from colon cancer, the median survival time ranges from three to ten months,<sup>4,9,13,14</sup> but median survival is only 33 days after the appearance of jaundice due to hepatic metastases.<sup>9</sup> In contrast, median survival is 23 months when only lymph nodes are involved by metastases.<sup>13</sup> Survival with advanced intra-abdominal colon cancer, furthermore, significantly exceeds the survival with comparable stages of other gastrointestinal malignancies: median survival time after palliative surgery for colon cancer in 9.7 months but only four months for other intra-abdominal cancers.<sup>4</sup> Thus, in several ways the type of patient under consideration in this report has a more favorable prospect for prolonged palliation. Among the seven who have died at this time, mean survival time *after appearance of jaundice* was 18 months and the median survival was 14 months.

The biliary-enteric bypass in any given case will vary with the circumstances. The duodenum, as a general rule, should not be used because it is or will be invaded by tumor. A Roux-en-Y limb of jejunum will insure a greater time interval before reobstruction. For similar

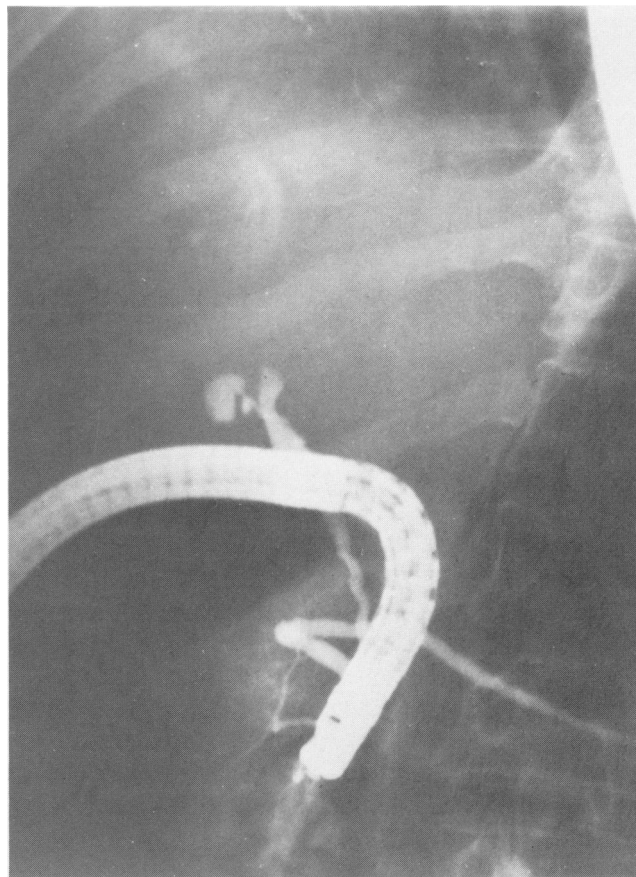


FIG. 2. Endoscopic retrograde cholangiogram (Case 8) showing complete obstruction of the common hepatic duct. Note the origin of the cystic duct below the obstruction.

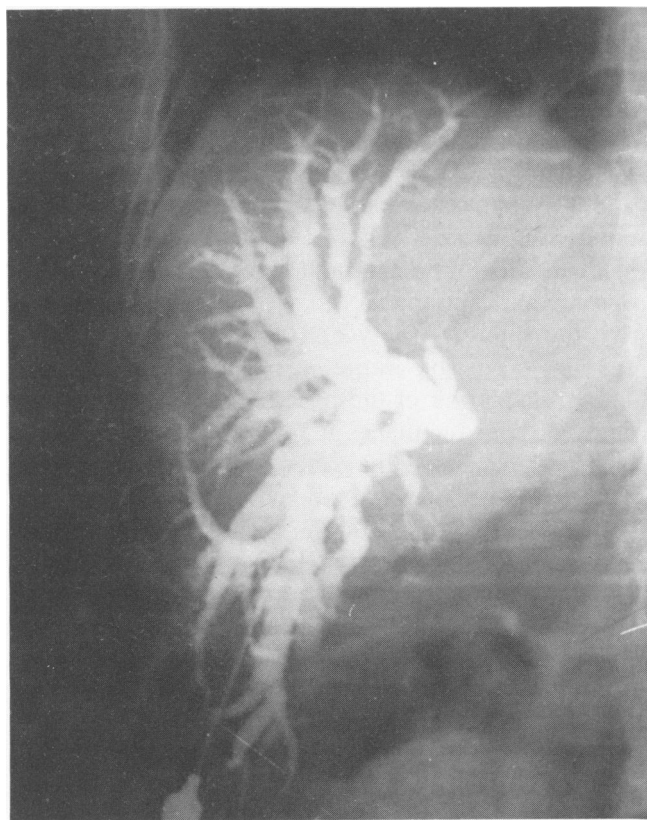


FIG. 1. Percutaneous transhepatic cholangiogram (Case 2) showing complete obstruction of the bile ducts in the porta. There is no apparent communication between the right and left hepatic duct systems.

reasons the anastomosis to the biliary tree should be as high as possible on the bile duct. The gallbladder should not be used because the level of biliary obstruction is usually at or higher than the cystic duct orifice, manifested by a collapsed gallbladder. The level of obstruction may in fact be high enough to necessitate intrahepatic anastomosis, the left hepatic duct being the easier to find and use.<sup>2</sup> In some cases of obstruction at the bifurcation it may be preferable to try the new technique of transhepatic passage of a tube down the bile duct, through the area of obstruction to the duodenum. This tube has side holes cut into it above and below the tumor and is left indwelling. Such tubes may be placed during laparotomy<sup>5</sup> or by percutaneous hepatotomy.<sup>11</sup> The tube can be replaced if it becomes occluded by debris.

Invasion of the duodenum from metastases in retro-duodenal nodes occurred in three of eight patients in this series and was responsible for ulceration and bleeding. Consequently we consider it advisable to perform a gastrojejunostomy to complement the biliary bypass in most cases. Defunctioning the duodenum by stapling or

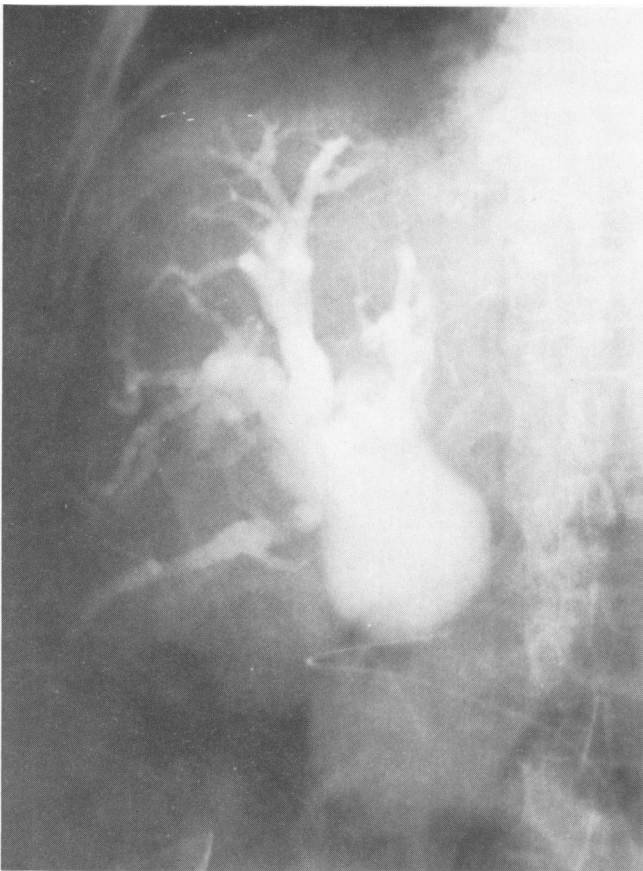


FIG. 3. Operative cholangiogram (Case 1) showing a massively dilated common duct with obstruction at its lower end.

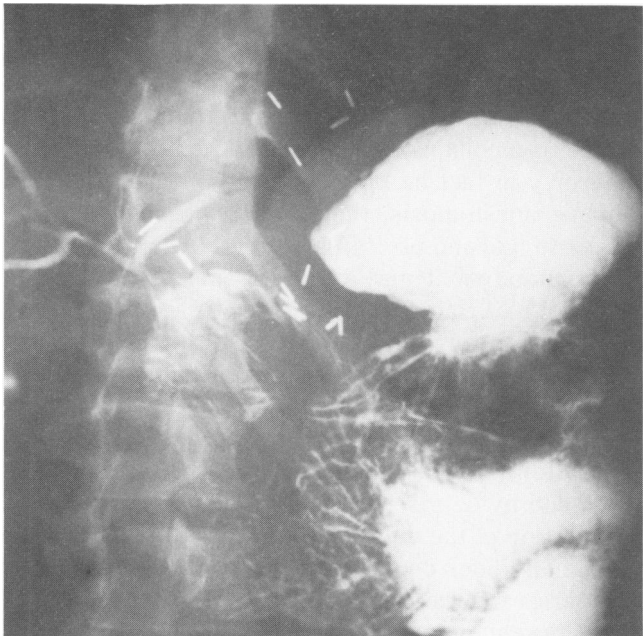


FIG. 4. Upper GI series two years after choledochojejunostomy (Case 3). The biliary tree remains completely decompressed.

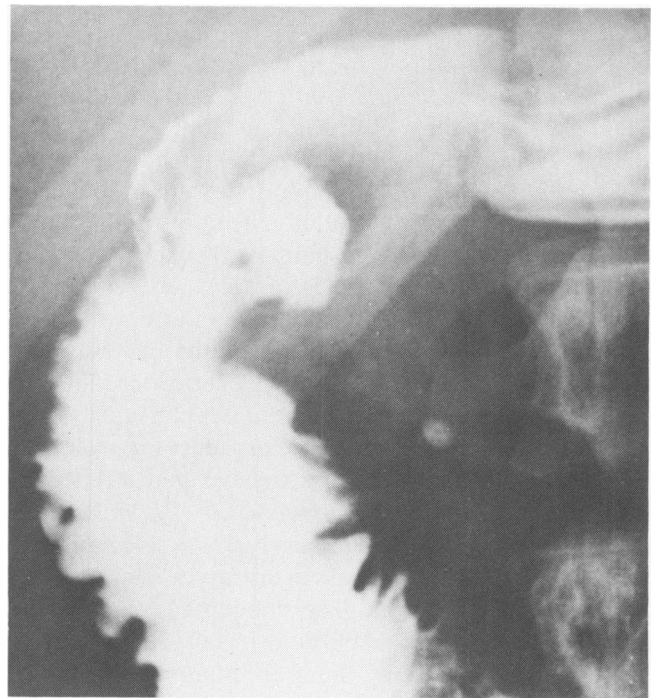


FIG. 5. Barium study of the duodenum (Case 3) showing a large postbulbar ulcer. This was proven at surgical exploration to be ulceration in a tumor mass eroding through the posterior wall of the duodenum.

suturing the pylorus closed has in our experience seemed to reduce the amount of blood loss from the malignant duodenal ulcer (personal observation).

Biliary bypass in patients with extrahepatic biliary obstruction from metastatic colonic cancer offers not just palliation of pruritus and other symptoms of biliary obstruction, but appears to prolong life. It is unlikely that our one to three year survivals would otherwise have been possible in the face of high-grade jaundice. The prolongation of life by biliary bypass in this circumstance distinguishes it favorably from the biliary obstruction caused by pancreatic and periampullary cancer. Median survival time with these latter forms of malignant biliary obstruction is three to five months<sup>4,5</sup> and is *not* lengthened by palliative bypass.<sup>4,15</sup> Whether adjunctive chemotherapy or radiation therapy can provide any additional advantages cannot be answered from our experience, but there has been particular reawakening of interest in local irradiation of the portal area.<sup>8,10</sup>

### References

1. Berkowitz, D., Gambescia, J., and Thompson, C. M.: Jaundice with Signs of Extra-hepatic Obstruction as the Presenting Symptom of Bronchogenic Carcinoma. *Gastroenterology*, 20:653, 1952.

2. Bismuth, H. and Corlette, M. B.: Intrahepatic Cholangioenteric Anastomosis in Carcinoma of the Hilus of the Liver. *Surg. Gynecol. Obstet.*, 140:170, 1975.
3. Bower, J. S. and Coca Mir, R.: Jaundice in Acute Subleukemic Lymphocytic Leukemia due to Obstruction of the Common Duct by Portal Nodes. *JAMA*, 146:987, 1951.
4. Brown, P. W., Terz, J. J., Lawrence, W. Jr. and Blievernicht S. W.: Survival After Palliative Surgery for Advanced Intra-abdominal Cancer. *Am. J. Surg.*, 134:575, 1977.
5. Cameron, J. L., Skinner, D. B. and Zuidema, G. D.: Long Term Transhepatic Intubation for Hilar Hepatic Duct Strictures. *Ann. Surg.*, 183:488, 1976.
6. Cole, H. S. and Freston, J. W.: Recurrent Melanoma Presenting with Obstructive Jaundice. Report of 2 Cases. *Rocky Mount. Med. J.*, 70:42, 1973.
7. Herbut, P. A. and Watson, J. S.: Metastatic Cancer of the Extrahepatic Bile Ducts Producing Jaundice. *Amer. J. Clin. Pathol.*, 16:365, 1946.
8. Hudgins, P. T. and Meoz, R. T.: Radiation Therapy for Obstructive Jaundice Secondary to Tumor Malignancy. *Int. J. Radiat. Oncol. Biol. Phys.*, 1:1195, 1976.
9. Jaffe, B. M., Donegan, W. L., Watson, F. and Spratt, J. S.: Factors Influencing Survival in Patients with Untreated Hepatic Metastases. *Surg. Gynecol. Obstet.*, 127:1, 1968.
10. Kopelson, G., Harisiadis, L., Tretter, P. and Chang, C. H.: The Role of Radiation Therapy in Cancer of the Extra-hepatic Biliary System: An Analysis of Thirteen Patients and a Review of the Literature of the Effectiveness of Surgery, Chemotherapy, and Radiotherapy. *Int. J. Radiat. Oncol. Biol. Phys.*, 2:883, 1977.
11. Nakayama, T., Ikeda, A. and Okuda, K.: Percutaneous Transhepatic Drainage of the Biliary Tract: Technique and Results in 104 Cases. *Gastroenterology*, 74:554, 1978.
12. Nardi, G. L.: Personal communication.
13. Silverman, D. T., Murray, J. L., Smart, C. R., et al.: Estimated Median Survival Times of Patients with Colorectal Cancer Based on Experiences with 9,745 Patients. *Am. J. Surg.*, 133: 289, 1977.
14. Stehlin, J. S. Jr., Hafström, L. and Greeff, P. J.: Experience with Infusion and Resection in Cancer of the Liver. *Surg. Gynecol. Obstet.*, 138:855, 1974.
15. Tepper, J., Nardi, G. and Suit, H.: Carcinoma of the Pancreas: Review of MGH Experience from 1963 to 1973: Analysis of Surgical Failure and Implications for Radiation Therapy. *Cancer*, 37:1519, 1976.