

# Fabrication and Evaluation of Tissue Leaflets for Aortic and Mitral Valve Replacement

HENRY T. BAHNSON, ROBERT L. HARDESTY, LENOX D. BAKER, JR.,  
DANIEL H. BROOKS, DONALD A. GALL

*From the Department of Surgery, University Hospital, Pittsburgh, Pennsylvania*

EARLY attempts at replacement of the aortic valve involved individual leaflets, the configuration of which was similar to the natural leaflet, and early results were encouraging in that the valves could be made competent and functionally adequate. A distinct advantage of the fabric leaflet valve was the freedom from embolic complications, a major problem of prostheses constructed of metal, synthetic materials and cloth. Early encouragement was followed by disappointment, however, as the fabric leaflets stiffened, broke and led to regurgitation, and the use of fabric leaflets was abandoned by all the earlier proponents.<sup>1</sup>

Because leaflets offer advantages in some instances for aortic replacement, we have used pericardium in selected cases in the past 5 years to reconstruct portions or all of the aortic valve, and have investigated various types of tissue for replacement. Single leaflets were placed in calves and dogs, a pulse duplicator was constructed to allow visual evaluation of leaflet valves, and a special forceps was fashioned to hold tissue and to make construction of tissue leaflets easier and more uniform. When we were confident a reliably competent valve could be constructed, total replacement of the aortic valve of patients was performed.

---

Presented at the Annual Meeting of the Southern Surgical Association, December 8-10, 1969, Hot Springs, Virginia.

Supported by Grant HE-08970 from the National Institutes of Health and by the Heart House Fund.

## Animal Experiments

The pulmonary valve was operated upon, during right heart bypass, in 26 dogs. There were 11 long-term survivors, the others died within 2 weeks, nine within 24 hours. The dogs were divided into three groups. Group one had coagulation of one pulmonary leaflet, group two had replacement of a single leaflet with pericardium, and group three had a single leaflet replaced with fascia lata.

The dogs that survived for less than 2 weeks died from hemorrhage or infection. Autopsy showed pliable thin leaflets without thrombus formation. If the leaflet was correctly positioned, it appeared competent.

The 11 long-term survivors consisted of four with replacement with fascia lata, four with pericardium, and three in which a leaflet was coagulated. All animals grew well, and were autopsied at one year. All of the test leaflets, whether coagulated or replaced, were markedly thickened and shortened. The leaflet was a scarred fibrous ridge and was adherent to the wall of the pulmonary artery. In several animals there were calcium deposits at the commissural edges.

The aortic valve of 14 calves was operated upon during cardiopulmonary bypass, moderate hypothermia and coronary perfusion.<sup>2</sup> Eight animals died in the first 24 hours as a result of inability to defibrillate the calf heart, hemorrhage, or respiratory insufficiency.

Three of the four deaths in the first 6

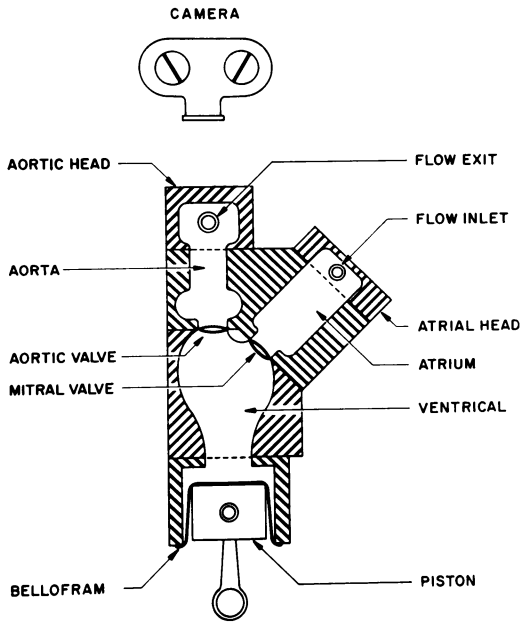


FIG. 1. Schematic diagram of pulse duplicator.

weeks occurred in calves which had only coagulation of the non-coronary leaflet. Autopsy showed thrombus formation and leaflet damage in all three. There were no signs of bacterial endocarditis. The fourth death was also the result of thrombus formation on a leaflet made from mediastinal pleura.

The two long-term survivors had leaflets made from mediastinal pleura replacing the non-coronary one. Both animals did well, but at one year, one had a murmur consistent with aortic insufficiency. This animal was sacrificed and the leaflet was found to be thin and without irregularity, thrombus, or calcium. The leaflet was not placed deeply enough, and this accounted for the regurgitation.

The second calf was catheterized at one year and had minimal insufficiency. Cineangiography showed good function of the leaflet. This animal was sacrificed a year later, 2 years after operation and after a tenfold gain in weight. The leaflet was in good position, and the valve appeared competent.

We concluded from these studies that testing of leaflets in these animals was diffi-

cult because of multiple technical problems; that functional leaflets that will grow can be constructed using a forceps described below and that careful placement is critical. Studies have shown that trauma even to the normal leaflet causes thrombus formation with leaflet thickening and destruction. Special care must be used in the handling of the autologous tissue leaflets to prevent such damage and subsequent failure. At least in some instances an aortic leaflet can be replaced with the thin pleura separating the mediastinal and left lobes of the lung, and this leaflet can grow with the animal and remain thin and functional.

### Pulse Duplicator

The pulse duplicator\* is shown schematically in Figure 1. The atrial, ventricular, and aortic counterparts are made of clear plastic. The upper portion is readily disassembled to allow easy replacement of both the mitral and aortic valves. Tissue valves can be sutured to a cloth covered sewing ring, and prosthetic valves can be sutured to a flat metal ring with multiple holes for sutures, in either case the valve is held in place and sealed in the duplicator with O-rings. The system is powered by a variable-speed electric motor which drives the piston-bellofram assembly through a variable linkage, providing a constant  $\frac{3}{8}$  of the cycle for systole and  $\frac{5}{8}$  of the cycle for diastole. The stroke volume of the piston can be continuously varied between 15 and 100 ml. The speed of the motor can be varied from almost zero to several hundred cycles per minute. Pressure taps are provided to allow the monitoring of aortic, ventricular, and atrial pressures.

The system shown in Figure 1 has essentially no compliance in either the atrium or the aorta. To obtain physiological pressure and flow profiles, it was necessary to provide compliance in both of these sections. In the atrial side, an insert containing three

\* Made by Surgitool, Inc., 3737 Library Road, Pittsburgh, Pa. 15234.

diaphragms 2 inches in diameter was placed between the body of the atrium and the atrial head (Fig. 2). The diaphragms were made of double thickness dental dam and were sufficient to provide the necessary compliance for the atrium. With a competent mitral valve, atrial pressures vary by  $\pm 5$  mm. Hg at flow rates of 5 l./min. and at speeds of approximately 70 strokes per minute.

In a similar fashion, three diaphragms of double thickness dental dam 1.25 inches in diameter were placed in a plastic insert between the aortic body and the aortic head. The outside of each of the three diaphragms was connected to a common chamber which could be pressurized.

This system produced pressures within the physiological range, but the elasticity of the system and the inertia of the pulsatilely flowing fluid provided a high frequency resonance to the system which was damped out very slowly. To improve this damping characteristic, it was necessary to add at the flow exit a 6-inch piece of copper pipe,  $\frac{3}{4}$  inch in diameter. The pipe contained 30 small holes (#60) and was covered by a sleeve of  $\frac{3}{4}$  inch Penrose tubing, sealed to the copper tubing at each end. At pressures above 50 to 60 mm. Hg, some fluid passes out through the small holes into the space between the copper and Penrose tubing; as the pressure decreases, fluid flows back through the holes in the opposite direction. This small amount of

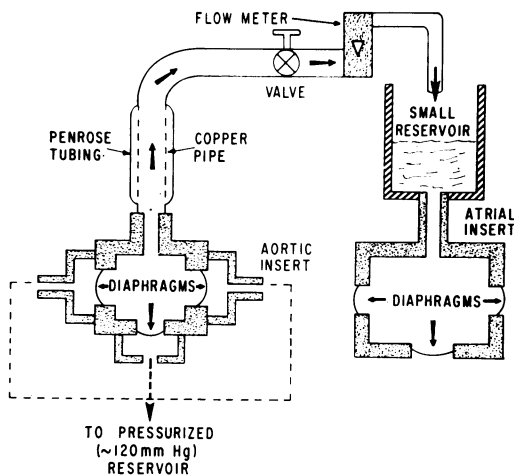


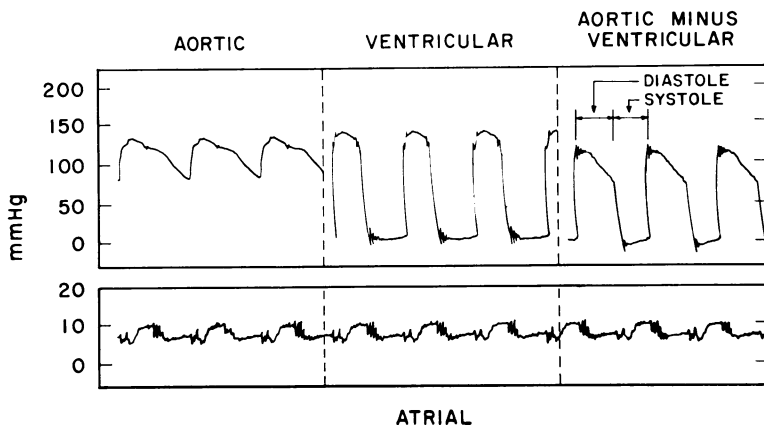
FIG. 2. Additions to the pulse duplicator to add the proper compliances and resistance to produce a more physiologically normal pressure and flow profile, and to measure mean flow rates.

added resistance is sufficient to damp out the high frequency pressure oscillations which otherwise occur in the system.

From here, flow passes through a variable valve which acts as capillary resistance, and by which mean aortic pressure is regulated through a flowmeter, back into a small reservoir, and from there into the atrial side.

At average flow rates less than 4 l./min., the system satisfactorily duplicates the pressure-flow characteristics of the left heart (Fig. 3). The aortic pressure is approximately 130/80 mm. Hg with a small diastolic notch. Ventricular pressures are approximately 140/0 with some oscillation

FIG. 3. Pressures obtained from the pulse duplicator. Electrical subtraction of ventricular from aortic pressure reflects the competence of the aortic valve.



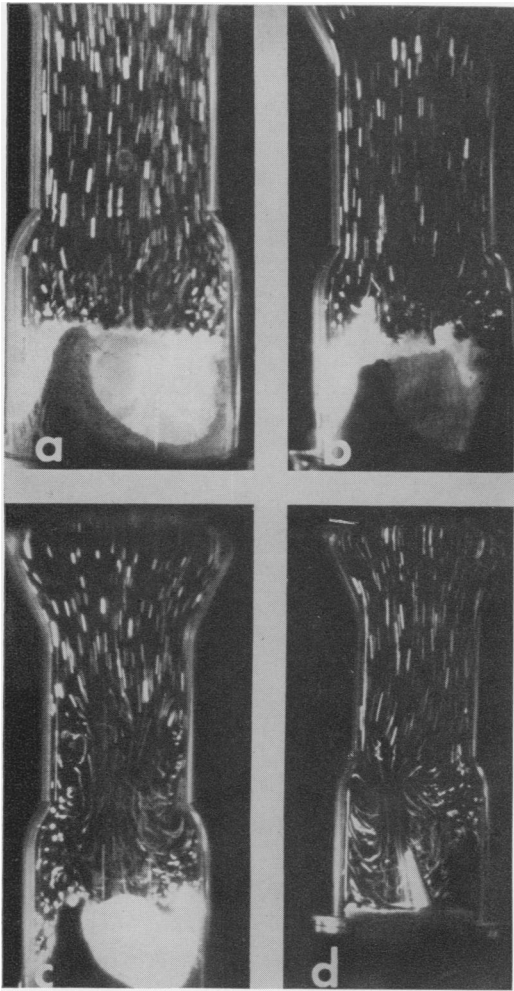


FIG. 4. Flow profiles of four valves taken approximately  $\frac{3}{64}$  of a second after initial opening of the valves. a. 30 mm. fascia lata leaflets in a 30 mm. ring. b. 33 mm. fascia lata leaflets in a 30 mm. ring. c. Hufnagel valve. d. Wada-Cutter valve.

still present during diastole. Electrical subtraction of aortic minus ventricular pressure shows the pressure gradient of from 120 to 75 mm. Hg when the aortic valve is closed (during diastole) and the  $-5$  to zero pressure gradient across the valve when the valve is open (during systole). Atrial pressures vary between 5 and 10 mm. Hg. This test was conducted on a homograft aortic valve approximately 30 mm. inside diameter with flows of 2.5 l/min. The mitral valve was a Barnard valve.

At flow rates above 4 l./min., compliance in the arterial side becomes too small and the difference between systolic and diastolic pressures tends to increase such that the wave form no longer looks physiological. This can be corrected by using larger diaphragms in the aortic side, but it was not deemed necessary for our purposes.

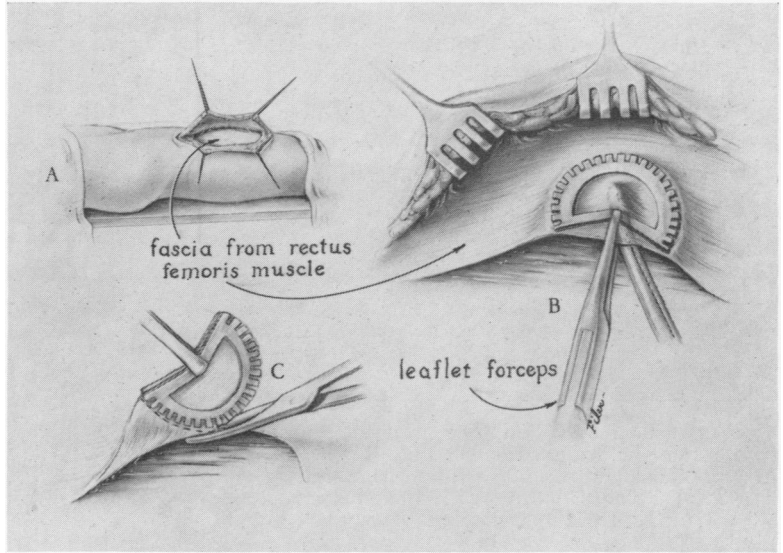
A more nearly physiological state can be obtained by using a glycerine-water mixture, but for most purposes distilled water was satisfactory as the pumped fluid. Valve action was seen and photographed through the clear chambers. In order to visualize flow patterns, polystyrene particles, 0.5 mm. in diameter, were added to the fluid and a high intensity slit of light was projected onto the chamber downstream from the valves. Light was provided by a 2,000 watt filament lamp, focused by a semi-circular condensing lens and collimated by two 1 mm. wide slits spaced 2 cm. apart. Two dimensional motion of the particles in the narrow band was photographed at 64 frames per second with 4X film (ASA 320) at  $f/2$ .

Enlarged single frames taken at near maximum flow conditions for four different valves are shown in Figure 4. Note the nearly constant streak length of the particles for the two fascia lata valves (Fig. 4a, 4b). This indicates a nearly uniform velocity profile across the aorta. The less complete opening of the Hufnagel valve (Fig. 7D) and the Wada-Cutter valve tend to produce vortices and nonuniform velocity distributions (Fig. 4c, 4d).

### Leaflets

The semilunar valves are seemingly simpler in anatomy and function than the atrioventricular valves. Since clinical mitral replacement would at present be made with a cloth covered sewing ring similar to that used in the pulse duplicator to test aortic or mitral valves, the following comments may apply to both aortic and mitral replacement.

FIG. 5. Leaflet forceps used to remove fascia lata. The forceps is designed to create some ballooning or belly in the leaflet. Greater belly can be obtained as shown when the fascia is harvested.

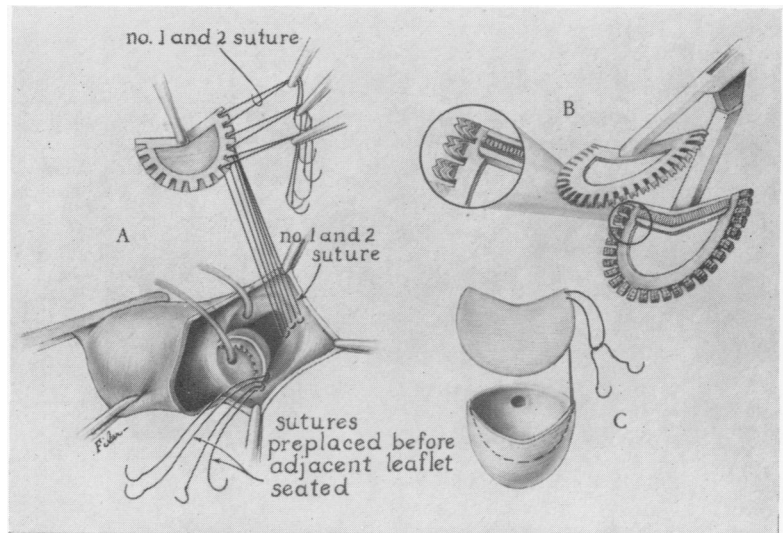


The leaflet valve depends for competence on suspension by the free edge and on approximation over a 1 to 3 mm. band of tissue adjacent to the free edge. A ballooning or belly in the leaflet helps assure approximation over the width of this band rather than just at the free edge. Proper suspension of the free edge depends upon proper matching of size of the three leaflets in order that they support each other, and one leaflet does not drop below the others. Such prolapse occurs when the free edge

of one is too long. Correct approximation and suspension is difficult to visualize in the opened aorta, even with normal, natural leaflets, but can be readily seen in a pulse duplicator.

Thin and flexible tissue will better adapt to the orifice size and to the adjacent leaflets. Clinical evidence suggests that thick and malformed leaflets may thicken more in time, since either rheumatic or congenital aortic stenosis appears to be a progressive lesion with deposition of fibrin,

FIG. 6. Leaflet forceps and technic used to replace aortic leaflets.



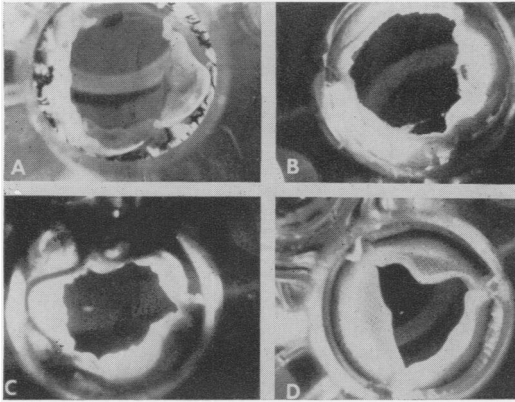


FIG. 7. Four valves in their maximally open positions as photographed on the pulse duplicator. A. Aortic homograft. B. 30 mm. fascia lata leaflets in a 30 mm. ring. C. 33 mm fascia lata leaflets in a 30 mm. ring. D. Hufnagel valve.

later thickening and calcification. In animal experiments Björk<sup>3</sup> and associates have shown thickening and calcification of leaflets made of pericardium. For these reasons, guiding principles followed in this project were, first, that tissue used for valve replacement should be as thin and flexible as compatible with strength, and second, that the replaced leaflet should be an accurate copy of the natural one.

To meet these requirements a tissue holder was necessary to enable us to suture free hand the very thin tissue of accurately determined dimensions and shape into the opened aorta. An isolated heart which pumped a clear solution was developed<sup>4</sup> to test leaflets by visual observation, but proved too cumbersome for this purpose. The pulse duplicator described above has

been a satisfactory alternative. Ease and rapidity of insertion and prompt exposure, processing and viewing of cine film of test valves in the duplicator are important advantages.

Tissue holders of many types were tried, designed to shape thin flat tissue to contoured three dimensions. The one\* currently used is shown in Figures 5 and 6. The atraugrip firmly holds thin tissue while sutures are placed through the multiple slots. The forceps can be made in many sizes. When sutures, preplaced in the proper sized leaflet and along the line of excision of the aortic valve, are tied, both suspension and approximation of leaflets result.

Pericardium, peritoneum, fascia, and mediastinal pleura have been tested in either the duplicator or animals or in both. There is a margin of safety of several millimeters in size. Leaflets that are too small do not properly meet and hence allow leakage through the central confluence. When too large, they buckle and do not open fully (Fig. 7). A set of calibrated discs has been made to size the aortic orifice accurately (Fig. 8).

A belly of the leaflet in addition to that from the shape of the forceps may be obtained as the tissue is grasped; when this is not done the leaflets approximate over a more narrow band, leaving less margin of competence for contraction of the leaflets.

\* Pilling Company, Delaware Drive, Fort Washington, Pa. 19034.

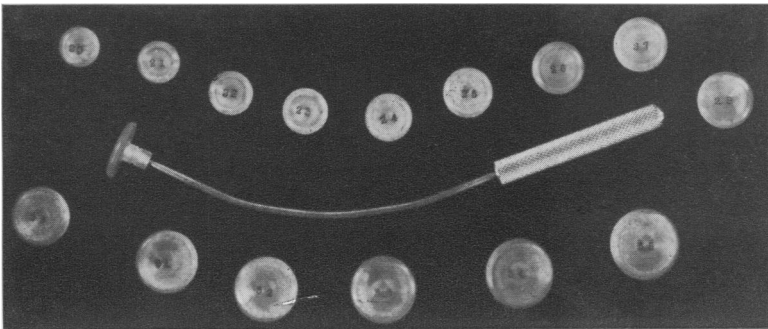


FIG. 8. Set of discs with holder used to measure the internal diameter of the valve orifice.

TABLE 1. *Autogenous Pericardium*

Patient	Diagnosis	Operation	Results
13 M	RHD—AS, AI, MS, MI	Pericardial extensions to contracted leaflets	Mod. → severe AI necessitating homograft replacement 2 yr. later
22 F	SBE—AI	Pericardial extensions to contracted leaflets	Gr. II/VI diastolic murmur 1 month postop. Lost to follow-up.
9 M	Congenital AI	All three leaflets replaced	Mod. AI on catheterization 1 month postop. Remains well clinically 4½ yr. postop.
12 M	Congenital AI	Commissurotomy and replacement of right leaflet	50 mm. Hg gradient and mod. AI 1 yr. postop. Remains well clinically 4½ yr. postop.
52 M	SBE—AI	Replacement of NC leaflet	Gr. I/VI diastolic murmur 6 months postop. Remains well clinically 1½ yr. postop.

All three leaflets for replacement should have the same dimension on the free edge; otherwise the edge may fold back when too short or prolapse when too long. A correctly sized and placed fascial valve closely resembles an aortic homograft in the pulse duplicator.

**Clinical Studies**

Entire aortic leaflets or portions of them have been replaced with autogenous tissue

in 13 patients since 1964 (Tables 1, 2). Prior to development of the leaflet forceps, five patients with aortic insufficiency underwent valve reconstructions with pericardial leaflets or pericardial extensions to partially contracted leaflets. In all instances, valve function and patients were considerably improved, but a murmur of aortic regurgitation was present in all.

Better competence of the valve has been obtained in the eight patients treated in

TABLE 2. *Autogenous Fascia Lata*

Patient	Diagnosis	Operation	Results
62 M	AS & AI	Total replacement 30 mm. (1-33 mm.)	Expired 2 months postop. with sepsis, anemia, and hepatic failure. No diastolic murmur. Valve competent at post.
5 M	VSD & AI & PS	Replacement R & NC leaflets	Mild AI 3 months postop.
44 M	AS & AI 3 yr. posthomograft	Total replacement 27 mm.	Expired following surgery with massive infarction. Severe coronary artery disease.
38 M	AS & AI	Total replacement 30 mm.	Developed SBE and diastolic murmur 1 month postop.
64 M	AS	Total replacement 30 mm.	Massive LV infarction with death 1 week postop.
56 M	AS	Total replacement 30 mm.	Doing well 2 weeks postop.
42 M	AS & AI	Total replacement 33 mm.	Doing well 2 weeks postop.
59 F	AS, AI & MI	Total replacement 27 mm.	Doing well 1 week postop.

the last 5 months with fascia lata leaflets made with the leaflet forceps. Two patients died during or soon after operation because of massive left ventricular infarction, clearly antedating operation in one case. One patient died 2 months after operation of sepsis, anemia, and hepatic failure. He had no diastolic murmur before death and the valve seemed competent and was free of infection at autopsy. These three failures may have been related to the use of leaflets for replacement, because this method requires a longer period of cardiopulmonary bypass than does use of a ball valve.

The other five patients are improved. Two have aortic regurgitation. In one patient, the murmur appeared only after bacterial endocarditis became evident, one month after operation. The other patient, a child, had two leaflets replaced because of prolapsed leaflets and aortic regurgitation in conjunction with a ventricular septal defect. His murmur increased in intensity following discharge from the hospital, but he continues to improve over his preoperative condition. All five patients have been followed for only a short time. No patient has been given anticoagulants after operation, and there has been no recognized thromboembolism.

In these patients fascia lata was at first taken from the lateral thigh, over the Vastus lateralis muscle and the iliotibial band. More recently thinner fascia (170 micra, compared with 340 micra of the iliotibial band) was taken from over the Rectus femoris muscle. Even the thinner tissue is twice as thick as much of the normal aortic leaflet. The thinner fascia seems satisfactory and the pulse duplicator studies indicate that function should be better.

### Discussion

One of the major challenges of cardiac surgery is the repair of valvular disease, more common and pressing in the adult, but important in the child. The list of complications which follow prosthetic valve re-

placement and the increasing number of prostheses and their modifications attest to the importance of the problem and to dissatisfaction with available prostheses. Leaflet valves have a low incidence of emboli to recommend their use, but no fully satisfactory synthetic material has been reported. The advantages of leaflet valves has been realized in the use of homografts introduced for aortic replacement by Barratt-Boyes<sup>2</sup> and by Ross.<sup>1</sup> Covered with endothelium initially and composed of appropriate tissue, homografts have been satisfactory for up to 6½ years,<sup>2</sup> but procurement of valves and the availability of appropriate sizes has limited the use of homografts. In addition, there is evidence that fresh tissue harvested aseptically is better than that preserved and sterilized, and this imposes an additional limitation of procurement and duration of storage. A systolic murmur is often present after homografting, probably because the homograft with attached aortic wall is placed inside the lumen of the recipient. Many of these patients have murmurs of aortic incompetence, although only a few have hemodynamically significant regurgitation or have required removal and replacement. These problems with aortic homografts have been evident to us in experience with more than 50 cases, and have added further incentive in the quest for better valve replacement. The good results reported by Senning<sup>7</sup> and Edwards<sup>5</sup> support the use of autogenous fascia lata. Although a competent valve can be made and sutured free hand, studies with a pulse duplicator have demonstrated the advantages of a reproducible and reliable method of constructing leaflets of variable sizes. Follow-up studies in humans will be required, but results to date are encouraging.

### Summary

Experimental replacement of valve leaflets has been described in animals and with a pulse duplicator. A special forceps has



been described with which a competent valve of autogenous tissue can be constructed in various sizes. Leaflet valves of fascia lata have been placed in eight patients. Five patients are alive and improved. Follow-up of patients is brief, but early results are encouraging and support the report of a larger series of cases by Senning.<sup>7</sup>

### References

1. Bahnson, H. T., Lewis, K. B., Criley, J. M. and Ross, R. S.: Replacement of the Aortic Valve with Individual Leaflets. *J. Thorac. Cardiovasc. Surg.*, 49:719, 1965.
2. Barratt-Boyes, B. G. and Roche, A. H. G.: A Review of Aortic Homografts over a Six and one-half Year Period. *Ann. Surg.*, 170:483, 1969.
3. Björk, V. O. and Hultquist, G.: Teflon and Pericardial Aortic Valve Prostheses. *J. Thorac. Cardiovasc. Surg.*, 47:693, 1964.
4. Brooks, D. H., Whiteford, J., Berk, A. D. and Bahnson, H. T.: Cinematographic Studies of the Interior of the Activity Contracting Heart. *Ann. Surg.*, 167:786, 1968.
5. Edwards, W. S.: Aortic Valve Replacement with Autogenous Tissue. *Ann. Thorac. Surg.*, 8:126, 1969.
6. Larson, R. E. and McGoon, D. C.: Experimental Cardiac Surgery in Calves. II. Management for Aortic Valve Surgery. *J. Surg. Res.*, 3:104, 1963.
7. Senning, A.: Fascia Lata Replacement of Aortic Valves. *J. Thorac. Cardiovasc. Surg.*, 54:456, 1967.

### DISCUSSION

DR. JAMES R. JUDE (Miami): I compliment Dr. Bahnson on one of the most beautiful studies of heart valves I have ever seen. His use of the pulse duplicator, with the use of photography and the suspension of materials in the flow, has shown some of the dangers one can expect from various prosthetic valves—the severe turbulence that occurs and the lack of this turbulence with the fascial lata grafts. With the use of a homograft valve I suspect that one would also see a rather normal linear flow.

In the same period of time that Dr. Bahnson has been using the fascial lata graft, we have switched entirely to the fresh—and I emphasize “fresh”—homograft aortic valve, which has been removed unsterile. They are sterilizing in Keflin and Colimycin with all becoming sterile in 3 to 5 days.

These homograft aortic valves have been used free-hand in the normal subcoronary position or in the stents in the mitral position. We have had two operative deaths in 25 patients. The results up to 4½ to 5 months have been absolutely 100% perfect. I have never seen patients who have had such good hemodynamics. The house staff has commented on the ease of postoperative care of these patients.

The concern of all of us, however, is the longitudinal study and function of these valves. Just as Dr. Ochsner has shown the longitudinal results beautifully for ligation of the cava, our

friends from Canada, Dr. Gordon Murray and Dr. Ray Heimbecker, have done the same for fresh homograft aortic valves. Dr. Heimbecker just recently visited us as a visiting professor, and brought along some cineangiographs of patients 11 and 15 years after Drs. Gordon Murray and Heimbecker had put fresh—and I emphasize “fresh”—homografts into the descending aorta. They did this in five or six patients. The two 11- and 15-year aortograms showed excellent function of these fresh valve leaflets. This is the longest valve replacement follow-up that I know of.

(Slide) The fresh homograft valve is easily trimmed by the house staff, kept at 4° C. (slide), it can easily be placed, but takes about 1–1½ to 2 hours in the aortic position.

(Slide) If you use it in the mitral position, of which eight of our 25 were, it has to be on a stent. We are not using any long-term anticoagulation in any of these patients, and I might say that that saves the patient about \$300 a year.

DR. LENOX D. BAKER, JR. (Closing): We have tested the flow pattern of the homografts and they are similar to our own fascia lata.

We have used homografts in 45 patients at Pittsburgh with good results. However, we continue to have the usual difficulties with procurement and sterilization of an adequate number of homografts of good quality and variable sizes.

Also we believe that if we are getting such good results with homologous tissue, we should get even better results using autologous tissue.