

Expanded Polytetrafluoroethylene Graft Fistula for Chronic Hemodialysis

VIVIAN A. TELLIS, M.D., WILLIAM I. KOHLBERG, M.D., DINESH J. BHAT, M.D., BARRY DRISCOLL, M.D.,
FRANK J. VEITH, M.D.

In a retrospective study of 66 PTFE arteriovenous fistulae and 71 BCH arteriovenous fistulae for dialysis access, PTFE had a higher patency rate than BCH at 12 months (62.4 versus 32.5%). PTFE was easier to work with and easier to handle in the face of infection. The lateral upper arm approach to placement of the PTFE graft is desirable in patients who have had multiple previous access procedures because this area is usually free from scarring, is distant from neurovascular structures, and provides a greater length of graft for needle punctures.

BY INCREASING THE AVAILABILITY and improving the knowledge of chronic maintenance hemodialysis the numbers of patients with end-stage renal disease has increased. This has resulted in a growing number of patients in whom circulatory access cannot be provided by the standard arteriovenous fistula. Serious problems accompanying the use of bovine carotid heterografts (BCH)^{5,6} under these circumstances, combined with favorable reports with the use of expanded polytetrafluoroethylene (PTFE)* grafts^{1,2,7} prompted our interest in and evaluation of the material in providing access for hemodialysis. This report compares our experience with PTFE and BCH and describes a new technique for construction of a prosthetic AVF under difficult circumstances.

Materials and Methods

Arteriovenous access was created 487 times from February 1973 to October 1977. Of these, 350 were primary arteriovenous anastomoses; 137 prosthetic grafts were utilized when hemodialysis access could not be provided by a primary arteriovenous fistula. From February 1973 to August 1976, 71 BCH graft arteriovenous fistulae were created for hemodialysis access in 42 patients. Forty-one were forearm grafts from radial artery to antecubital or basilic vein; 30 were in the thigh from femoral artery to saphenous vein.

Supported by grants from the James Hilton Manning and Emma Austin Manning Foundation.

Submitted for publication: April 17, 1978.

* W. L. Gore Associates, Newark, Delaware.

From the Montefiore Hospital and Medical Center and Albert Einstein College of Medicine, New York, New York

From July 1976 to October 1977, 66 PTFE graft arteriovenous fistulae were created in 52 patients. Of these, 65 grafts were in the upper limb and one femoral saphenous fistula was created. The two groups were comparable regarding age distribution, sex and the presence or absence of diabetes.

Surgical Technique

In 24 patients, the radial to basilic PTFE graft fistula by a lateral approach was performed as follows (Fig. 1). Under axillary block or local analgesia, a longitudinal incision was made overlying the ulnar border of the brachioradialis, distal to the antecubital crease. The radial artery was identified near its origin and mobilized out of its deep position. A longitudinal incision was made in the upper arm over the brachial artery pulse in the bicipital groove. The basilic vein was identified and mobilized for a distance of 3–4 cm. A size 22 French red rubber catheter was placed on the arm between the incisions so as to describe a gentle curve extending across the lateral extremity of the antecubital crease. This was then marked on the skin. A subcutaneous tunnel was created under this line by means of gentle blunt dissection with a large curved clamp; this usually necessitated one additional incision at approximately the midpoint of the tunnel. The catheter was then introduced into this tunnel, thus confirming the adequacy of its size and the absence of any acute angulation even in flexion of the elbow. The end of a 6 mm PTFE graft of appropriate length was transected obliquely. The previously mobilized vein was placed on traction with silastic tapes† so as to provide atraumatic occlusion, and a 1 cm longitudinal venotomy created. The vein was irrigated with heparinized

† Vesseloops™, Medgeneral, Minneapolis, Minnesota.

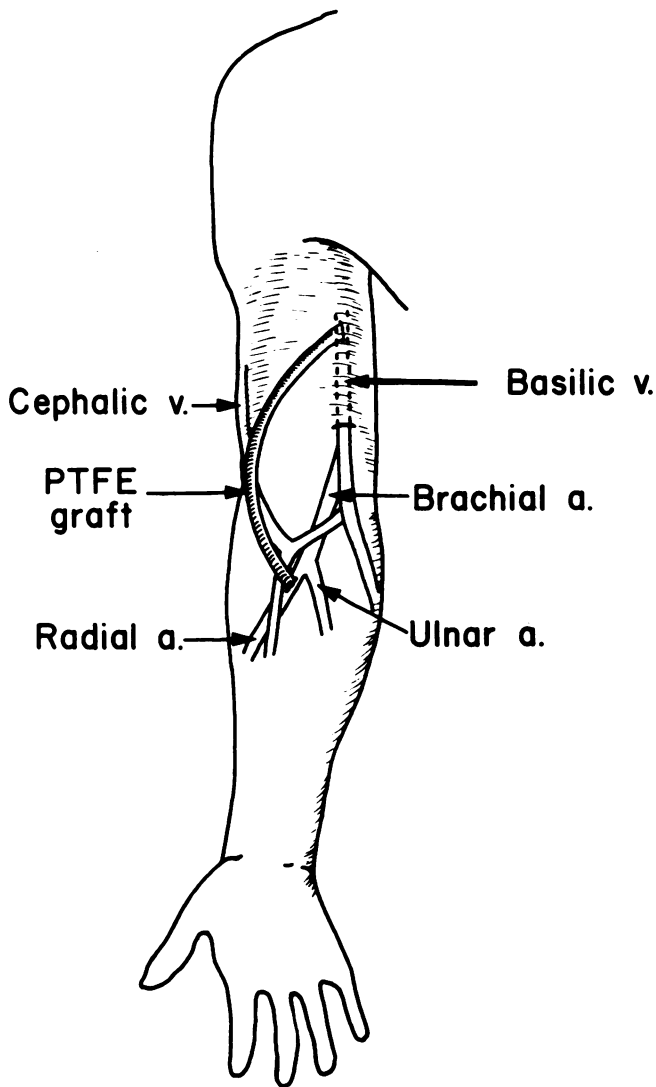


FIG. 1. Lateral approach to placement of a PTFE graft arteriovenous fistula (schematic representation).

saline to confirm its patency and an end-to-side graft-to-vein anastomosis was created with 6-0 polypropylene.‡ A bulldog clamp was placed on the graft immediately beyond the anastomosis, the traction released, and compression applied for a few minutes to ensure hemostasis. After evacuation of air, the free end of the graft was irrigated with heparinized saline, while the clamp was temporarily released to confirm adequacy of the anastomosis and the outflow. The anastomosis was allowed to retract into the wound to assume its permanent position. The free end of the graft was then attached to the catheter and led through the tunnel into the lower incision, avoiding traction on the anastomosis or torsion of the graft; it was transected where

it overlies the radial artery in its natural position with the elbow extended. The radial artery was then placed under traction with silastic tapes and a longitudinal arteriotomy of approximately 7–8 mm performed. The patency of the artery was confirmed by means of heparinized saline irrigation, and the passage of graduated vascular dilators. The momentary release of silastic tape traction confirmed adequacy of blood flow and an end-to-side graft-to-artery anastomosis was performed with continuous sutures of 6-0 polypropylene. Before completion, the graft was filled with saline, the bulldog clamp was removed from the venous end of the graft, and the suture tied, after which traction was released from the artery. In most instances the graft promptly developed pulsatile flow with a palpable thrill. The wound was irrigated and closed. The remaining 42 PTFE graft fistulas were created by methods similar to those which have been described previously.^{3,4}

In all patients, graft puncture was avoided for at least one week and hemostasis after dialysis was achieved by digital compression. Circumferential tape and dressings were avoided.

Results

Patency

Cumulative patency at 12 months was 62.4% for all PTFE grafts, 32.5% for all BCH grafts and was 23.1% for all upper arm BCH grafts (Fig. 2). The difference in patency between all PTFE grafts and all BCH grafts was statistically significant ($p < 0.005$).

For each type of graft, there were no significant differences in patency between diabetics and nondiabetics or between the various surgical approaches used.

Occlusion

The most common complication was graft occlusion. Occlusion occurred as a result of: (1) inadequate arterial inflow due to atherosclerotic disease, small arteries, or hypotension; (2) venous outflow obstruction due to neointimal proliferation at the venous end of the graft; and (3) external mechanical pressure on the graft as a result of bleeding into the subcutaneous tunnel, a tourniquet or pressure bandage, or pressure on the fistula arm during sleep.

There were 52 episodes of occlusion in BCH grafts. In 21 instances (40.4%) thrombectomy with or without revision was attempted. Of the 52 occlusions, 17 were successfully revised. In the PTFE grafts there were 46 episodes of occlusion. In 29 instances, (63%) thrombectomy with or without revision was attempted. Fourteen of the 46 occlusions were successfully revised.

‡ Prolene™, Ethicon, Inc., Summerville, New Jersey.

Some grafts in both groups had multiple occlusions and thrombectomies.

In many instances, BCH and PTFE grafts had been anastomosed to small, diseased, or otherwise questionable arteries. Such grafts were not re-explored when they occluded. In others, the grafts functioned and obviated more complex and less desirable procedures.

Infection

Twelve functioning grafts (six BCH and six PTFE) presented with evidence of local infection ranging from erythema to abscess formation with frank purulent drainage. Infections occurred after operation or re-operation in three cases and from sites of venipuncture for dialysis in nine cases.

All infected BCH grafts were removed to avoid the danger of severe bleeding. Two functioning PTFE grafts, which presented as perigraft abscesses that were not near a suture line, were successfully treated with incision and drainage and antibiotics, and the wounds over the exposed grafts healed within 14–21 days. Four other PTFE grafts were removed because the infection involved the entire tunnel and the sites of arterial and venous anastomoses.

In patients with BCH and PTFE grafts, there were several other instances of fever and positive blood cultures without localizing signs. These were presumed to be graft infections, and they were successfully treated with long-term antibiotics.

Bleeding and Aneurysm Formation

As time passes, functioning BCH grafts can develop a series of thin-walled aneurysms (Fig. 3). In five BCH grafts, this led to serious bleeding either after dialysis or from spontaneous rupture. One patient exsanguinated at home. No aneurysm or serious bleeding has been noted in the PTFE grafts.

Other Complications

Hematomas in the tunnel resulted in occlusion of two PTFE and two BCH grafts. This was associated with anticoagulation or with premature use of the grafts for dialysis. Steal phenomena leading to peripheral ischemia, manifested by pain, coldness and numbness in the extremity, were noted in two PTFE and two BCH grafts; these were in patients with severe distal arterial disease who had brachial artery grafts. One PTFE graft was surgically narrowed by a ligature but subsequently thrombosed. Thrombectomy was successfully performed through an incision in the graft,

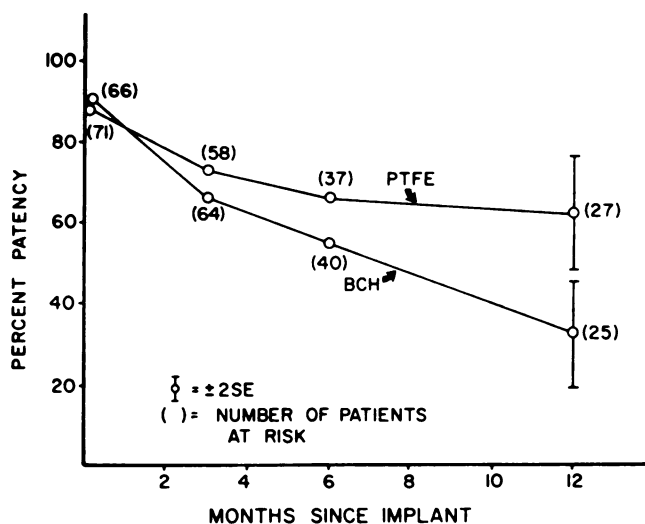


FIG. 2. Graphic representation of comparative patency of BCH and PTFE graft fistulas. The difference at 12 months is statistically significant ($p < 0.005$).

which was closed so as to narrow the graft; this successfully abolished the symptoms. The three other patients improved spontaneously.

A variable degree of edema of the extremities was noted, depending mainly on the extent of previous operations or venous occlusive disease. This usually subsided over a period of time with elevation of the extremity.

Discussion

The primary arteriovenous fistula has rightly become the preferred method of access to the circulation for chronic hemodialysis. At our institution, it was attempted on 350 occasions, when there was a possibility

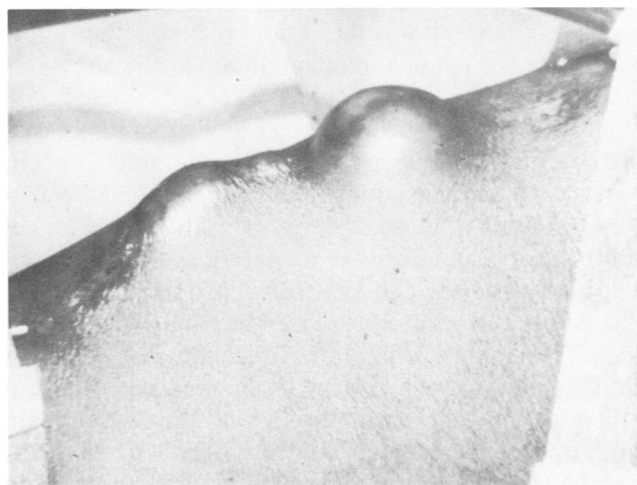

FIG. 3. Photograph of an arm with BCH 18 months after operation. Two aneurysms are clearly seen.

of success. The requirements were the presence of an adequate artery and superficial vein that could be anastomosed without tension and without jeopardizing circulation to the extremity. In addition the resultant arterialized vein had to be easily accessible to repeated venepuncture and yield adequate blood flows.

These criteria cannot always be met. Arteriosclerosis or diabetes can occlude peripheral arteries. Prolonged hospitalization or drug addiction can exhaust superficial veins, and the use of multiple external shunts can destroy vessels. It is frequently possible to perform a more proximal fistula, such as an antecubital fistula, under these circumstances.⁸ However, in obese patients, the resultant veins may be so deep that multiple painful attempts are required for dialysis venepuncture, and massive hematomas may result.

The use of BCH grafts seemed at first a satisfactory means to bridge the gap between an adequate artery and vein and to provide a suitable structure for repeated needle insertion. But several problems have become apparent with the use of the material. Deterioration of graft substance, often with destruction of large areas of the wall in association with venepuncture sites, often results in aneurysmal dilatation of the entire graft or multiple thin-walled aneurysms throughout its length. These may cause serious hemorrhage or infection. Intense inflammatory reaction renders removal of the infected graft exceedingly difficult. Infected BCH grafts, whether functioning or not, usually presented as a series of abscesses throughout the length of the graft. They frequently had to be removed piecemeal by multiple incisions or wide excision. Even in the absence of infection, reoperation is usually difficult. The graft itself is exceedingly friable, rendering suture lines weak. Exposure and mobilization of the graft is both difficult and hazardous. Frequently, a markedly thickened pseudointima within the graft reduces the lumen significantly. Venous intimal buildup at the site of the anastomosis is also common.

PTFE grafts appear to have certain advantages over BCH grafts. Although grafts are vulnerable to occlusion in the face of poor arterial inflow or inadequate venous outflow, there are important differences when grafts must be subjected to reoperation. PTFE is easily exposed and dissected free from surrounding tissue. It can be sutured securely. A thrombus is easily extracted from the lumen of the graft, which usually has a thin intimal lining. Build-up of pseudointima however, can still sometimes be noted throughout the lumen of the graft or at the venous anastomosis. The latter problem can be corrected by a jump graft to a more proximal vein.

Both types of grafts are foreign material, and as such

are more susceptible to infection than primary arteriovenous fistulas. However their reaction to possible infection differs. An infection around a functioning PTFE graft, away from a suture line, can be managed by adequate and wide incision and drainage. Although the graft material is exposed, secondary healing can result, and the fistula can be salvaged for future use. In contrast, failure to remove an obviously infected functioning BCH invariably leads to bleeding and/or loss of the access, irrespective of any other measures employed. An additional advantage of PTFE grafts is that when nonfunctioning, they often present as a draining sinus through which the graft can be grasped and removed by simple traction since the artery and vein are thrombosed.

In our experience, the patency rate of PTFE grafts is significantly better ($p < 0.005$) than BCH grafts at one year, by which time most bovine grafts were lost due to thrombosis or aneurysmal dilatation. However, patency may depend on a number of variables other than graft material. These include the patient's blood pressure, the status of peripheral vessels, the anatomical location of the graft and the skill and care employed in the use of the fistula. While attempts at thrombectomy or fistula revision were equally successful with both types of grafts, the ease and safety of reoperation on PTFE grafts encouraged a more aggressive approach. This may partially explain the improved patency in the latter group.

When a prosthetic graft is required, our policy is to place a straight graft from the distal radial artery to a medial vein at or above the elbow joint when possible. Most methods of access for dialysis also use the forearm or the medial aspect of the arm. Thus, in a patient who has had multiple previous attempts at access, we have found our lateral approach for the creation of PTFE graft fistulas to be very useful, since the area is usually free of previous operative scars. The proximal radial artery is almost always usable, even if the distal radial artery is not patent or inadequate. On occasion, an unsuspected large superficial vein is encountered during exposure of the artery, and a proximal fistula can be performed, avoiding a graft. Even when a graft is unavoidable, the use of the proximal radial artery, rather than the brachial artery, reduces the chance of ischemia to the extremity, since normal ulnar artery flow is maintained. The position of the graft is such that it overlies no major neurovascular structures which could be subject to needle injury by an inexperienced technician or patient in training. Furthermore, the lateral routing of the graft across the upper arm provides much greater length for needle insertion. However, the circuitous route demands that great

care be taken so that the graft is not angulated or twisted during its placement. Finally, its insertion into a large proximal vein of the arm insures adequate outflow. The ability of PTFE to resist kinking and to remain patent, although placed across joints, facilitates this approach.

Thus, we conclude that in those circumstances where a primary arteriovenous fistula cannot provide access for hemodialysis, PTFE grafts have a better patency rate, and are superior in handling characteristics, safety, and ease of reoperation when compared to bovine grafts. We further conclude that the lateral approach to graft placement is very useful in difficult circumstances.

References

1. Baker, L. D., Johnson, J. M. and Goldfarb, D.: Expanded Polytetrafluoroethylene (PTFE) Subcutaneous Arteriovenous Conduit; An Improved Vascular Access for Chronic Hemodialysis. *Trans. Am. Soc. Artif. Int. Organs*, 22:382, 1976.
2. Butler, H. G., Baker, L. D. and Johnson, J. M.: Vascular Access for Chronic Hemodialysis: Polytetrafluoroethylene (PTFE) vs. Bovine Heterograft. *Am. J. Surg.*, 134:791, 1977.
3. Hutchin, P., Jacobs, J. R., Devin, J. B., et al.: Bovine Graft Arteriovenous Fistulas for Maintenance Hemodialysis. *Surg. Gynecol. Obstet.*, 141:255, 1975.
4. Kaplan, M. S., Mirahmade, K. S., Winer, R. L., et al.: Comparison of PTFE and Bovine Grafts for Blood Access in Dialysis Patients *Trans. Am. Soc. Artif. Int. Organs*, 22: 388, 1976.
5. Mohaideen, A. H., Mendivil, J., Avram, M. M. and Mainzer, R. A.: Arterio Venous Access Utilizing Modified Bovine Arterial Grafts for Hemodialysis. *Ann. Surg.*, 186:643, 1977.
6. Rolley, R. T., Stenoff, S. and Williams, G. M.: Arteriovenous Fistulas for Dialysis Using Modified Bovine Arteries. *Surg. Gynecol. Obstet.*, 142:700, 1976.
7. Soyer, T., Lempinen, M., Cooper, P., et al.: A New Venous Prosthesis. *Surgery*, 72:864, 1972.
8. Tellis, V. A., Veith, F. J., Soberman, R. J., et al.: Internal Arteriovenous Fistula for Hemodialysis. *Surg. Gynecol. Obstet.*, 132:866, 1971.