

Selective Treatment of Duodenal Ulcer with Perforation

ARTHUR J. DONOVAN, M.D., THOMAS L. VINSON, M.D., GILBERT O. MAULSBY, M.D., JAMES R. GEWIN, B.A.

Selective treatment of duodenal ulcer with perforation has been based on several premises: 1) The natural history of the ulcer following closure of a perforation is generally favorable with an acute and unfavorable with a chronic ulcer. 2) An upper gastrointestinal series with water soluble contrast media can reliably document a spontaneously sealed perforation. 3) With a spontaneous seal, nonsurgical therapy is an acceptable option and is preferable for an acute ulcer or a chronic ulcer with poor surgical risk. 4) The treatment of choice for an unsealed perforation of an acute ulcer is simple surgical closure. 5) The treatment of choice of perforation of a chronic ulcer with acceptable surgical risk is an ulcer definitive operation. Sixty cases of perforation of duodenal ulcer have been treated. Nonsurgical therapy was employed without complication in eight cases with radiologically documented spontaneous seal. Truncal vagotomy and pyloroplasty in 36 cases and truncal vagotomy and antrectomy in two cases were each without mortality. Four fatalities occurred among 13 cases of closure and omental patch, each a case with severe associated disease. The mortality was 6.7% among the 60 cases; 2.4% for chronic ulcer and 16% for acute ulcer.

WHEN AN ACUTE OR CHRONIC duodenal ulcer acutely perforates into the peritoneal cavity three components require treatment—the ulcer, the perforation and the resulting peritonitis. The therapeutic priorities are treatment of the peritonitis and secure closure of the perforation. These goals may be achieved without or with a surgical procedure which alters the ulcer diathesis, the latter an act that when indicated is of the second order of priority. The perforation and peritonitis are immediate and serious threats to life; the ulcer in itself is not.

This paper will report the results of selective nonsurgical and surgical treatment of a consecutive series of 60 cases of duodenal ulcer with perforation and peritonitis. The protocol that was employed was developed as a direct consequence of the authors' personal experience with and knowledge of details of the intensive study of this lesion by Berne and Rosoff.³

Premises

1) When the perforation of an acute ulcer is closed the vast majority of cases do not experience sub-

Presented at the Annual Meeting of the Southern Surgical Association, December 4-6, 1978, Hot Springs, Virginia.

Reprint requests: Arthur J. Donovan, M.D., 2451 Fillingim St., Mobile, Alabama 36617.

Submitted for publication: December 7, 1978.

*Departments of Surgery and Radiology,
University of South Alabama College of Medicine,
Mobile, Alabama*

sequent major morbidity consequent to duodenal ulcer.^{8,12,19}

2) The vast majority of cases with a chronic ulcer that perforates and in which the surgical treatment is limited to closure of the perforation will have subsequent early or late morbidity, or both, due to duodenal ulcer.^{7,8,12} At least one-third of the patients will require reoperation in the early or late postoperative period. Many additional cases will experience severe symptomatic disability. Perforation is an event of ominous prognostic significance in the natural history of a chronic duodenal ulcer.

3) The perforation of a peptic ulcer may spontaneously seal. As early as 1843 Edward Crisp noted that "occasionally the aperture is filled up by adhesions of the stomach to some of the surrounding viscera, and in these instances the contents of the stomach do not escape into the peritoneum."⁴

4) The spontaneous seal of an acute perforation, or conversely, continuing leakage from the perforation may be reliably and safely documented by a radiological examination of the stomach and duodenum with water soluble contrast media.* The use of this procedure for this purpose was first discussed by Berne and Mikkelsen in 1958 and such a study will be subsequently referred to as a gastroduodenogram.²

5) An operation which both securely closes the perforation and which is intended to control the ulcer diathesis can be performed at the time of perforation with low morbidity and mortality.^{3,9-11,14,15} Due to the poor prognosis for persistent or recurrent peptic ulcer when a chronic ulcer perforates, such an operation is preferable in selected cases of chronic ulcer.

Diagnostic Considerations

Radiology

The diagnosis of peptic ulcer with perforation is usually made on the basis of a typical history and phys-

* Hypaque Sodium, Winthrop Laboratories.

ical examination and is confirmed in over 80% of cases by the radiological documentation of free intraperitoneal air. The lateral decubitus right side up radiographic view of the abdomen or erect chest film are preferable to an erect film of the abdomen for detection of free air.¹³ The patient with acute chemical peritonitis due to perforation of peptic ulcer will be in pain, hypovolemic consequent to "third spacing" and may develop postural hypotension in the erect position. The patient can lie for five minutes or longer in the lateral decubitus position prior to radiograms.

If the diagnosis of peptic ulcer with perforation and peritonitis is suspected but free intraperitoneal air is not demonstrable, or if free air is present but the diagnosis is not deemed secure, a gastroduodenogram can be performed. In the absence of free air, the differential diagnosis is most often between acute pancreatitis or peptic ulcer with acute perforation. A modest elevation of serum amylase is frequently present with peptic ulcer with perforation.¹ On occasion, a localized perforation in the right upper quadrant may mimic an acute biliary tract syndrome. When leakage is shunted into the right lower quadrant by the falciform ligament, liver and hepatic flexure of the colon the clinical picture may resemble acute appendicitis. An atypical history and physical examination with or without pneumoperitoneum may lead to confusion as to peritonitis due to perforation of an ulcer, the appendix, a colonic diverticulum or another lesion. In any of the aforementioned situations the gastroduodenogram may demonstrate a duodenal ulcer with or without intraperitoneal spill of contrast media. The significance of a demonstrable ulcer will spill or of a normal duodenum is obvious. If, in a case with peritonitis, the ulcer is seen and spill not observed, either spontaneous seal has occurred or two diseases coexist, duodenal ulcer and another cause of peritonitis. Synchronous duodenal ulcer and another lesion as a cause of the peritonitis will be a rare occurrence. Thus, the demonstration of a duodenal ulcer without extraduodenal spill of media is a strong indication that the cause of the peritonitis is a duodenal ulcer that perforated with spontaneous seal.

The gastroduodenogram is performed with fluoroscopic imaging. Mucosal imaging is better with barium but water soluble contrast media is used rather than barium due to the potential for untoward consequences if the barium spills into the peritoneal cavity and bacterial infection supervenes.¹⁸ Pylorospasm may be present as with any acute abdominal syndrome and interfere with the filling of the duodenum. Persistent effort and administration of glucagon may overcome this difficulty.

Evidence suggestive of chronicity may be noted on the gastroduodenogram such as a scarred duodenum,

with or without obstruction. A second posterior ulcer may be seen with an anterior ulcer that has perforated or a giant saddle ulcer may be identified. All chronic ulcers will not reveal these radiographic hallmarks of chronicity, particularly when the examination is performed with water soluble media.

The role of the gastroduodenogram in establishing whether the perforation is leaking or spontaneously sealed deserves special emphasis. Berne and Rosoff reported that a seal was documented by gastroduodenogram in over 40% of several hundred consecutively studied unselected cases of duodenal ulcer with perforation.³ Diagnostic accuracy was witnessed by the favorable response to nonsurgical treatment in these cases of spontaneous seal. The seal was secure and leakage an extreme rarity. This high incidence of spontaneous seal exceeds by far that which most surgeons would predict, based on personal experience. During surgery and in the act of exposing the right upper quadrant and the duodenum the seal is frequently broken. The fibrin on the undersurface of the liver where seal had occurred will be apparent. If either the duodenum does not fill, or an ulcer is not seen, or both, significance cannot be placed on failure to demonstrate intraperitoneal spill of contrast media.

When the perforation is leaking, diffusion of media throughout the peritoneal cavity may be seen. The media may be shunted into the right lower quadrant or a localized subhepatic spill may be observed. The intraduodenal media together with the extraduodenal collection may resemble a collar button. Spill into such small localized pocket may reflect a perforation in the process of sealing.

Radiograms that depict the diagnostic value of the gastroduodenogram are reproduced in Figures 1 and 2.

Acute vs. Chronic Ulcer

Several authors have arbitrarily selected a three month history of symptoms of peptic ulcer as the criterion for a diagnosis of chronic ulcer.^{12,19} An additional consideration is the radiological demonstration of the signs of chronicity. Observations at the time of celiotomy such as scarring and callous establish chronicity. These radiological and surgical findings may exist in the case with denial of previous symptoms consistent with peptic ulceration. The unreliability of the history obtained at time of perforation is generally recognized.

A history of prior perforation or prior or synchronous major hemorrhage attributed to duodenal ulcer, multiple duodenal ulcers or saddle ulcer would be assumed to establish the prognostic equivalence of chronicity. Synchronous perforation and major hemorrhage are particularly ominous.

Thus, three areas are considered in the diagnosis of

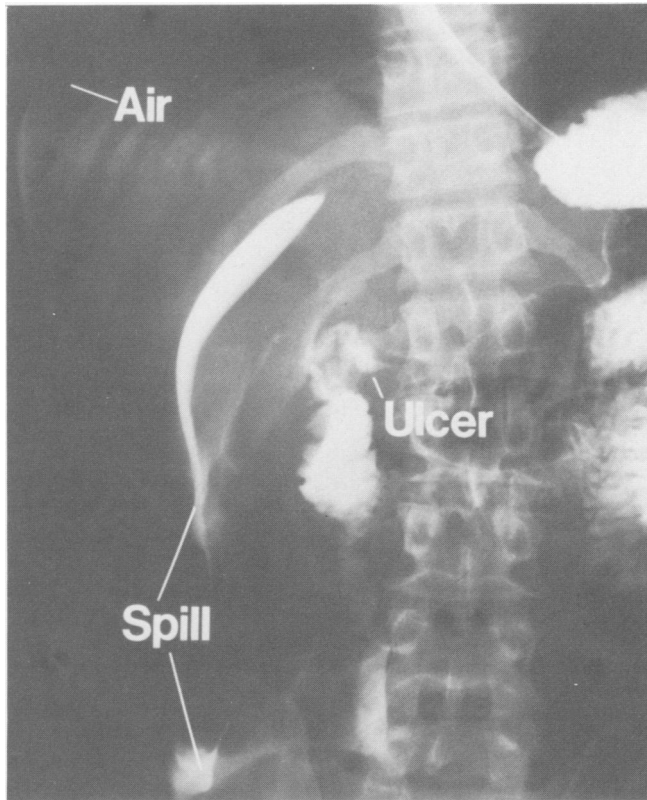


FIG. 1. This gastroduodenogram with Hypaque reveals a duodenal ulcer with perforation and diffuse spill of the contrast media into the peritoneal cavity. Extraluminal air is present beneath the right diaphragm.

chronic or acute ulcer—history, radiological findings and findings during surgery. Pyloric and juxtapyloric ulcer are pathophysiologically similar to duodenal ulcer and are treated as such. These criteria for definition of acute ulcer or chronic ulcer will be employed in all subsequent sections of this paper.

Protocol

When a diagnosis of a duodenal ulcer with perforation is established appropriate therapy is employed to correct any fluid deficit and electrolyte imbalance, nasogastric suction is instituted, the head and torso elevated 15–20° and broad spectrum antibiotic therapy begun. The peritoneal burn with consequent “third spacing” is treated aggressively. If tension pneumoperitoneum is present and respiration is embarrassed, needle aspiration is performed to relieve the pneumoperitoneum. This permits continued deliberate resuscitation.

The treatment of duodenal ulcer with perforation is surgical with two exceptions. These exceptions are 1) a presumed acute ulcer with spontaneous seal of the perforation or 2) a chronic ulcer with very poor surgical risk and spontaneous seal of the perforation. A gastro-

duodenogram is performed in both of the above instances to establish the presence or absence of seal.

Nonsurgical Treatment

Nonsurgical treatment is selected for cases of acute ulcer, or chronic ulcer with very poor surgical risk, if the gastroduodenogram has demonstrated a duodenal ulcer without intraperitoneal spill of contrast media. The peritonitis resolves with remarkable rapidity when the perforation is sealed. Indeed, continuing major third spacing after four to six hours of hospitalization, progressive signs of peritonitis or increasing pneumoperitoneum arouse strong suspicion that an erroneous conclusion has been drawn and that a perforative lesion other than the radiologically demonstrable duodenal ulcer is the cause of peritonitis. Failure of early resolution of peritonitis demands immediate reconsideration of the decision to employ nonsurgical treatment. Unless compelling reasons to the contrary exist, surgery is indicated. In cases of chronic duodenal ulcer with spontaneous seal which are treated nonsurgically because of high operative risk, deferred ulcer definitive operation is recommended, if the patient's condition permits.

Surgical Treatment

Any arbitrary goal for time that is lapsed between presumed perforation and surgery is ignored. Surgery is performed when resuscitation is complete.

In a very rare instance and with extremely severe associated disease, surgical risk may be prohibitive with a leaking perforation from either an acute or chronic ulcer. In such cases the peritoneal cavity can

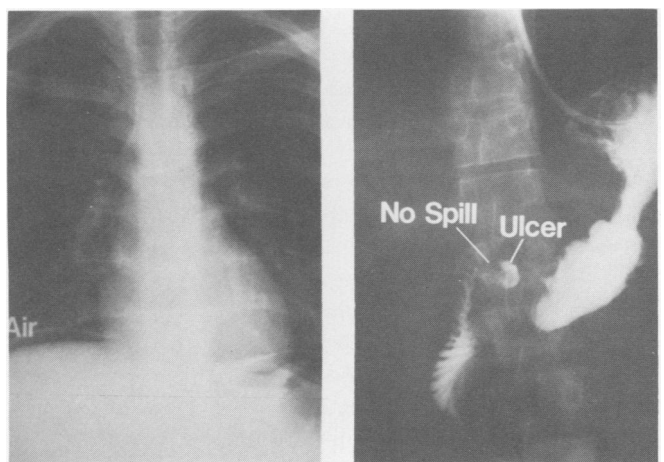


FIG. 2. The erect chest radiogram on the left reveals free intraperitoneal air consequent to perforation of the duodenal ulcer seen in the simultaneous gastroduodenogram on the right. The perforation is sealed and media does not spill out of the duodenum. Diffuse peritonitis resolved. Nonoperative therapy was followed by uneventful recovery.

be entered under local anesthesia through an incision in the right upper quadrant. Sump suction is established to and drains are placed in the region of the perforation. The duodenal leakage is shunted externally. If the patient's condition stabilizes, a deferred operation is performed.

If the final conclusion at surgery is that the ulcer is acute, the perforation is closed and an omental pedicle patch applied. A gastrostomy is performed in this, as well as in other instances of surgical closure of the perforation of a duodenal ulcer. An exception is technical inability to draw the stomach forward to seal the gastrostomy site to the parietes.

If the ulcer is judged to be chronic an ulcer definitive procedure is preferred. The operation recommended has been a truncal vagotomy and Heineke-Mikulicz pyloroplasty. There are three exceptions to this latter policy for chronic ulcer. These are the giant saddle ulcer, purulent peritonitis or an extremely poor risk or intraoperatively very unstable patient.

The giant saddle ulcer extending from the posterior duodenal wall superiorly and anteriorly usually perforates at its anterior edge near the porta hepatis. Almost the entire circumference of the duodenum will need to be mobilized to secure pliable tissue for a pyloroplasty. When this dissection is complete, the proximal duodenum will usually have been transected in most of its circumference. Under these circumstances an antrectomy is the simpler procedure. A tube duodenostomy may be performed rather than to close the duodenal stump.

In the presence of purulent peritonitis, the peritoneal cavity is drained externally. In this instance or in the very poor risk case with a chronic ulcer in which the perforation is leaking or in the case that becomes very unstable during operation, the perforation is *securely* closed, a vagotomy is omitted and surgery terminated. Some of the techniques for closure of the perforation of a duodenal ulcer are depicted in Figure 3.

Assumptions that might be drawn on the basis of history as to the duration of perforation are ignored in these therapeutic decisions. History is often unreliable. The degree of peritonitis is the important consideration and will be more related to whether leak has continued or whether spontaneous seal has occurred, than to the duration of time since perforation. Only purulent peritonitis is a contraindication to an ulcer definitive operation in a properly resuscitated and reasonable risk case with a chronic ulcer.

The attending surgeon responsible for the care of the individual case is free to select a form of therapy that differs from this protocol, if he considers such a selection to be in the best interest of the patient. Major deviations that have occurred will be apparent in the section on "Results."

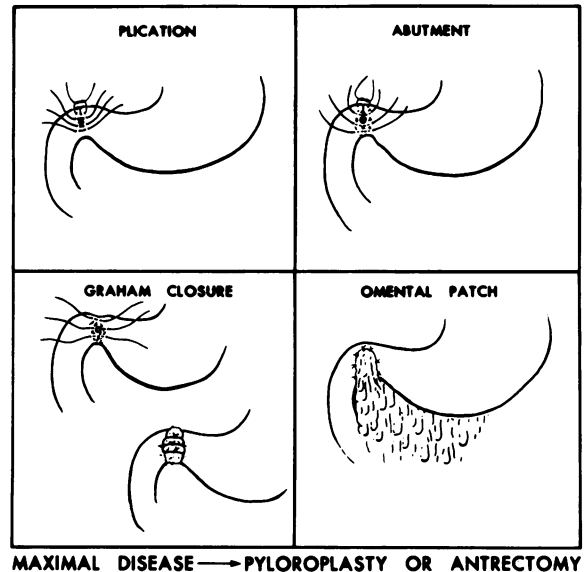


FIG. 3. Techniques for closure of the perforation of a duodenal ulcer are depicted. An omental pedicle patch is applied over a closure by plication or abutment. The closure described by Graham is with a free omental graft over the perforation and the opening itself is not closed.⁶ Reperforation, obstruction and hemorrhage in a maximally diseased duodenum may be best avoided by pyloroplasty or antrectomy.

An algorithm outlining this protocol is depicted in Figure 4.

Results

Clinical Data

Sixty cases of proven duodenal ulcer with perforation have been treated during the past five years. Fifty-three of the 60 cases were male and seven were female. The ages of the cases ranged from 18 to 93 years with a median age of 40 years. In the final analysis the ulcers were judged to be acute in 19 cases and chronic in 41 cases, a ratio of acute to chronic of approximately 1:2. Free intraperitoneal air was present in 50 or 83% of 60 cases. These facts are depicted in Figure 5.

Gastroduodenogram

A gastroduodenogram was performed in 22 cases. The history that was obtained on admission in eight cases suggested chronicity and in 14 cases an acute ulcer. Contrary to protocol a gastroduodenogram was not performed in the other five cases of historically acute ulcer.

The duodenum was visualized and the diagnosis of ulcer substantiated in all 22 cases. Extraduodenal spill of media was observed in 12 cases and was not seen in ten cases. In these latter ten cases, in which spon-

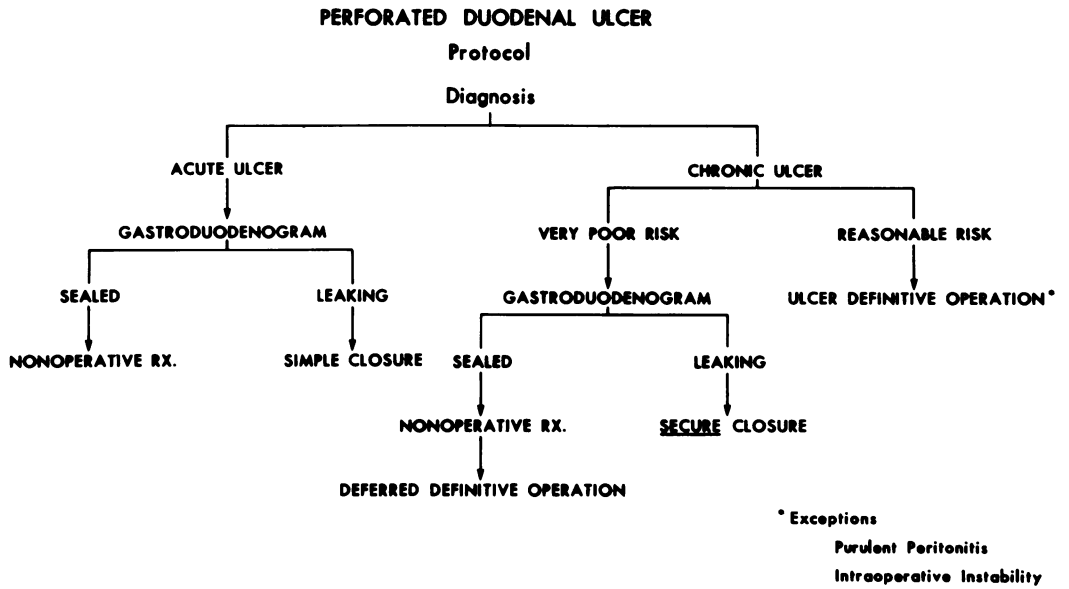


FIG. 4. This allogrhythm depicts the protocol employed for the treatment of the cases of duodenal ulcer with perforation that are reported in this paper. If historical, radiographic or surgical evidence of chronicity is identified, the protocol for chronic ulcer is followed.

taneous seal of the perforation of the demonstrable ulcer had occurred, signs of peritoneal irritation were minimal or essentially absent in two cases with pneumoperitoneum, a *forme fruste* type of perforation.¹⁷ The signs of spreading peritonitis present on hospital admission in the remaining eight cases with spontaneous seal were indistinguishable from those noted in the 12 cases with continuing leak from the perforation. Pneumoperitoneum was present in 20 of the 22 cases. These results are depicted in Table 1.

Nonsurgical Treatment

Eight of the ten cases with documented duodenal ulcer which had perforated and in which there was not

spill documented on gastroduodenogram were treated nonsurgically. The remaining two cases of spontaneous seal were instances of chronic ulcer in which the gastroduodenogram was performed for diagnostic confirmation. These two cases were judged to be of reasonable surgical risk and, following resuscitation, an ulcer definitive operation was performed.

The ages of the eight cases treated nonsurgically ranged from 21 to 54 years with a median age of 27 years. In the final analysis the ulcer was judged to be acute in four cases and chronic in four cases. All eight cases recovered without complication. Duration of hospitalization ranged from three to nine days with a median of six days. Deferred ulcer definitive surgery was recommended in the four cases of chronic ulcer considered to be poor risk for acute phase ulcer definitive operation. This recommendation was rejected in one case; one case was transferred to a Veterans Hospital for operation and a deferred ulcer definitive operation was successfully performed at the University of

DUODENAL ULCER WITH PERFORATION
60 Cases

MALE: 53 ACUTE: 19 FREE AIR: 50/60
FEMALE: 7 CHRONIC: 41

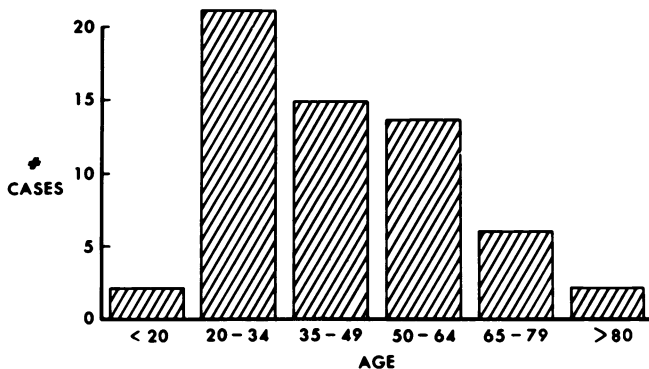


FIG. 5. Statistics concerning the cases of duodenal ulcer with perforation reported in this paper are depicted on this graph.

TABLE 1. Summary of Data on 22 Cases Selected for Gastroduodenogram*

| Data | Number of Cases |
|---------------------|-----------------|
| Acute ulcer | 14 |
| Chronic ulcer | 8 |
| Ulcer visualized | 22 |
| Perforation sealed | 10 |
| Perforation leaking | 12 |
| Pneumoperitoneum | 20 |
| Peritonitis | 22 |
| Spreading | 20 |
| Forme fruste | 2 |

* Gastroduodenogram was performed for diagnostic confirmation or to determine presence or absence of spontaneous seal of the perforation.

South Alabama Medical Center in the two remaining cases.

Surgical Treatment: Closure and Omental Patch

The surgical treatment in 14 cases was closure and omental patch, in all but one instance for acute ulcer. The case which deviated from the protocol will be discussed as Case 1. Duration of hospitalization ranged from seven to 37 days with a median of 12 days.

Seven of these 14 cases experienced one or more postoperative complications and three of these cases survived and four died. Complications in three cases that survived were nonexigent upper gastrointestinal hemorrhage from the site of gastrostomy and urinary tract infection in one case, atelectasis and pneumonitis in another case and severe aspiration pneumonitis with major associated morbidity in the third case. Three of four fatal cases were instances of perforation of an ulcer in elderly males with severe preexisting disease. Two of the three were already hospitalized for therapy of other disease when the perforation occurred. The fourth case, an acute ulcer, was not seen and admitted until severe purulent peritonitis had already developed. Brief summaries of these four fatal cases follow:

Case Reports

Case 1: A 70-year-old man was admitted to the medical service with pulmonary and cardiac failure. Six days later he developed severe abdominal distention and signs of sepsis. He was sent to the Radiology department for abdominal radiograms. These radiograms revealed a massive amount of free intraperitoneal air. While in the Radiology department he experienced a cardiac arrest and was resuscitated. A surgical consult was requested.

When seen by the surgeon the patient was intubated and on a respirator, without audible blood pressure, receiving vasopressors, unresponsive and without urine output. A #18 needle was inserted into the peritoneal cavity and the tension pneumoperitoneum was relieved. Cardiovascular and pulmonary function immediately improved but increasing pneumoperitoneum was soon reapparent. Under 1% novocain anesthesia and in the Intensive Care Unit, a 3 cm lateral right subcostal incision was made into the peritoneal cavity. A sump suction and penrose drains were digitally located in the region of the duodenum. The pneumoperitoneum was relieved. An effective external duodenal fistula was established. Forty-eight hours later the patient's condition had stabilized and all critical organs were functional. The duodenal fistula persisted.

The patient was taken to the Operating Room. At surgery a very badly scarred and calloused, inflamed and distorted duodenum was found. The perforation was closed by abutment and an omental patch applied with the addition of external drainage of the right upper quadrant. Postoperatively the duodenum was obstructed and the stomach never emptied. He has repeated episodes of upper gastrointestinal hemorrhage, presumably from the chronic duodenal ulcer. He reperfected and developed a high output fistula through the drains in the right upper quadrant. Another operation was performed on the 19th postoperative day consisting of an antrectomy, vagotomy and tube duodenostomy. The patient developed multiple organ failure and died on the fifth day following the final operation.

Comment

This case illustrates at least three points. 1) Relief of tension pneumoperitoneum can be of therapeutic benefit. 2) Sump suction established under local anesthesia can control leakage from the duodenum, relieve a tension pneumoperitoneum and create an external duodenal fistula. This maneuver may provide the physician a period of grace to prepare a desperately ill patient for a needed surgical procedure. Closure by abutment and omental patch, although simple, may not be the safest and most secure means to seal the perforation of a badly scarred and phlegmatous duodenum. In this case a pyloroplasty or antrectomy at the first operation may have been tolerated and have avoided the lethal complication that developed.

Case 2: An 83-year-old man experienced acute perforation of an acute duodenal ulcer while under treatment for chronic renal failure, severe arteriosclerotic cardiac disease and septic arthritis. He was recovering well from an operation consisting of plication and omental patch. He died suddenly on the ninth postoperative day. A pulmonary embolus or myocardial infarction was suspected. Autopsy was denied.

Case 3: A 77-year-old male with chronic renal failure, acute urinary tract infection and severe anemia sustained acute perforation of an acute ulcer. Following plication and omental patch he developed an exacerbation of the urinary tract infection, respiratory failure and disseminated intravascular coagulation. He died on the nineteenth postoperative day.

Case 4: A 40-year-old male alcoholic perforated an acute duodenal ulcer several days prior to arrival at the hospital. He was septic on hospital admission. At surgery purulent fluid was present throughout the abdomen. Cultures grew *E. coli*. Operation consisted of peritoneal lavage, plication of the ulcer and an omental patch. Postoperative course was characterized by continued sepsis, acute pancreatitis, pulmonary insufficiency, lactic acidosis and death on the tenth postoperative day.

Surgical Treatment: Ulcer Definitive Surgery

Ulcer definitive surgery was performed in 38 cases. The operation was truncal vagotomy and pyloroplasty in 36 cases and vagotomy with antrectomy in two cases of saddle ulcer, one of the latter with and one without a tube duodenostomy. These 38 cases ranged in age from 19 to 93 years with a median age of 46 years. Postoperative complications consisted of one instance each of wound infection, atelectasis and pulmonary embolism. Hospitalization ranged from seven to 26 days with a median of nine days. The oldest patient, a male who was 93 years old, did not have serious associated disease, had a very badly scarred duodenum and recovered uneventfully following vagotomy and pyloroplasty. Thirty-six of the 38 cases were instances of chronic ulcer and two were instances of acute ulcer. In one of the latter, the protocol was not followed. In the other, despite absence of criteria of chronicity, the surgeon performed a vagotomy and pyloroplasty. Four brothers had undergone surgery for duodenal ulcer.

TABLE 2. Results Among 22 Selected Cases of Perforation of Duodenal Ulcer*

| Treatment | Number of Cases | Age-Years Median Range | Cases with Complications | Mortality |
|-----------------------------|-----------------|------------------------|--------------------------|-----------|
| Non-operative | 8 (13.3%) | 27 (21-54) | 0 | 0% |
| Closure | 14 (23.3%) | 60 (18-83) | 7/14† | 29% |
| Ulcer definitive operation* | 38 (63.3%) | 46 (19-93) | 3/38‡ | 0% |
| Total | 60 | 40 (18-93) | 10 | 6.7% |

* Vagotomy and pyloroplasty 36; vagotomy and antrectomy 2. †Pulmonary sepsis—2. GI hemorrhage—1. Pulmonary embolus—1 (fatal). Multiple organ failure—3 (fatal). ‡Wound infection—1. Atelectasis—1. Pulmonary embolus—1. All deaths severe coexisting diseases.

Summary of Data: Mortality

Of the 60 cases, eight or 13.3% were treated non-surgically, 14 or 23.3% by closure and omental patch and 38 or 63.3% by ulcer definitive procedure. In 36 of the latter the operation was vagotomy and pyloroplasty. The treatment in 19 cases finally judged to be acute ulcer was nonsurgical in four, was with closure and omentopexy in 13 and vagotomy and pyloroplasty in two cases. Three cases died, a mortality for acute ulcer with perforation of 16%. The treatment in 41 cases of chronic ulcer was nonsurgical in four cases of poor surgical risk, was by closure and omentopexy in one fatal case and by ulcer definitive operation in 36 cases. The one death resulted in a mortality of 2.4% for chronic ulcer with perforation.

The overall mortality was 6.7%. Four deaths occurred, all in the group with closure and omentopexy. In three of the four the perforation was an almost terminal event in an otherwise severely ill and elderly male. The fourth death occurred in a young male alcoholic who did not seek treatment until several days after perforation of an acute ulcer. Purulent peritonitis had already developed.

A table summarizing data on therapy of all of these cases and on mortality is shown on Table 2.

Discussion

This paper concerns selective treatment of duodenal ulcer with perforation and peritonitis and relates almost exclusively to the first two of these components—the ulcer and the perforation. This is not to minimize the importance of the peritonitis but with proper supportive care the peritonitis will almost invariably resolve, if the perforation is securely closed. Bacterial colonization, purulent peritonitis and abscess are the hallmarks of late diagnosis, neglect and continuing leakage.

The role of examination of the stomach and duodenum with water soluble contrast media, the gastroduodeno-

gram, in the process of diagnosis and in selection of therapy has been stressed. This examination may demonstrate the ulcer and confirm the diagnosis, reveal evidence of chronicity and reliably document whether spontaneous seal has occurred or whether leakage continues. The surgeon can be unblinded in his selection from the variety of nonsurgical and surgical techniques available for closure of the perforation and treatment of the ulcer. Secure closure of the perforation takes precedence.

The Perforation

Spontaneous seal of the perforation may be by omentum, but far more often the site of perforation is sealed by fusion of the duodenum to the undersurface of the liver, between the gallbladder and the falciform ligament. If leakage prior to early sealing consists dominantly of air, the patient may manifest minimal signs of peritonitis despite the presence of pneumoperitoneum. This is the classic *forme fruste* perforation described by Singer and Vaughn.¹⁷ More important, a magnitude of spill leading to typical spreading peritonitis with or without pneumoperitoneum may occur but the perforation be spontaneously sealed. The importance of this latter phenomenon has been emphasized by Berne and Rosoff.³ With massive pneumoperitoneum it is less likely that spontaneous seal has occurred. Aerophagia may contribute to increasing pneumoperitoneum. Spontaneous seal is probably more frequent in a small perforation of an acute ulcer with a softer and more pliable duodenum.

Several surgeons have applied their knowledge of the phenomenon of spontaneous seal to the treatment of perforation of duodenal ulcer. Wangenstein practiced nonsurgical treatment in a group of selected cases with what he believed to be localized perforation.²⁰ Both Herman Taylor in England¹⁹ and Seeley in the United States¹⁶ employed nonsurgical treatment as the therapy of choice in a series of cases of duodenal ulcer with perforation. Herman Taylor reported 28 deaths (11%) among 256 cases of which 235 were treated nonsurgically. Seeley reported a mortality of 5%.

Nasogastric suction is believed to be a key to nonsurgical treatment and Taylor has emphasized the importance of proper positioning of a nasogastric tube in the stomach.¹⁹ Undoubtedly, in some cases not sealed at the initiation of therapy, sealing subsequently occurred. Sealing is a dynamic process. The concept of induction of seal by nasogastric suction was inherent in the experience of Taylor. Failure of treatment was reflected by increasing signs of peritonitis, with or without increasing pneumoperitoneum.

Based on the above reports, in the late 1940's and the early 1950's most surgeons attempted nonsurgical

treatment in selected cases of perforation of duodenal ulcer. These were usually the poor risk cases. Too frequently the result was disaster—the leakage from the perforation persisted. Blind nonsurgical therapy acquired a most unfavorable reputation. These unfortunate experiences do not negate the desirability of nonsurgical treatment of the perforation in certain cases such as those selected at the University of South Alabama for such treatment. These have been cases with presumed acute ulcer or with chronic ulcer and very poor risk for surgery. In both instances spontaneous seal of the perforation was documented by gastroduodenogram and the spontaneous seal was secure. An operation with its inherent morbidity, that would take down the seal to reseal the perforation, was not necessary in these cases.

If spontaneous seal of the perforation has not occurred a variety of techniques can be employed for surgical closure of the perforation. The protocol for selective therapy reported in this paper limited surgical closure of the perforation without an ulcer definitive operation to a) acute ulcer with continuing leak by gastroduodenography, b) chronic ulcer in very poor risk cases with continuing leak by gastroduodenography, c) intraoperatively unstable cases and d) cases with purulent peritonitis.

The technique selected for surgical closure of the perforation depends on the physical character of the gastropyloroduodenal tissues. The closure should be in the transverse axis of the pyloroduodenal channel. When the ulcer is acute the tissues are usually pliable enough to permit closure by plication. Seromuscular nonabsorbable or synthetic sutures of the Lembert type are employed. With scar, callous and intense inflammatory reaction seromuscular sutures may cut through or plication would result in obstruction. Abutment with simple through and through chromic catgut sutures may be preferable. Alternatively, the technique advocated by Roscoe Graham can be employed. It consists of the placement of three through and through chromic catgut sutures well back from the edge of the perforation. A free graft of omentum is placed over the perforation itself. The sutures are tied loosely. The omentum acts as a plug and as stated by Graham, "An attempt is not made to actually close the perforation."⁶

In any of the above techniques for closure an omental patch or graft may be placed over the sutures for reinforcement. In the Graham closure a free graft of omentum is used but more often a living pedicle patch of omentum is employed. The omentum is believed to enhance fibrin deposition at the site of closure. If sutures are tied over the omental pedicle, strangulation of the omentum may occur. For that reason an onlay pedicle graft of omentum or surrounding fibroadipose

tissue is preferable. This is fixed over the site of closure with a few circumferential sutures.³ These varied techniques are depicted in Fig. 3.

When the pathology in the pyloroduodenal area is maximal an attempt at closure by any of the above techniques may fail with reperforation or obstruction, or both. In the case of saddle ulcer of "kissing" ulcers hemorrhage may complicate the postoperative course. Berne and Mikkelsen in 1958 noted that closure with a badly diseased duodenum may be more safely achieved by pyloroplasty or antrectomy, with or without tube duodenostomy than by so called simple closure.² The fact that the pyloroplasty or antrectomy may be a component of an ulcer definitive operation is in this instance secondary to the need for secure closure of the perforation. The only failure in closure of the perforation among the 60 cases reported in this paper was the one case of chronic ulcer with very severe scar treated by abutment and omental patch. Obstruction, hemorrhage and reperforation ensued. Despite high operative risk due to associated disease, pyloroplasty or antrectomy would have been preferable treatment for the perforation at the initial operation. The three deaths among cases of perforation of acute ulcer were all in cases with very severe coexisting disease.

In performing pyloroplasty one should begin dissection proximally and distally in reasonably normal tissue both on the superior and inferior margins of the duodenum. Planes can be developed, fibrin dissected away and pliable duodenal wall identified. In the gastropyloroduodenotomy a lozenge shaped piece of tissue surrounding the perforation and including the callous is excised. A Kocher maneuver to mobilize the duodenum will facilitate the pyloroplasty. The gastric limb of the gastropyloroduodenotomy is made 1–2 cm longer than the duodenal limb.

The Ulcer

In the case of an acute ulcer with either spontaneous seal or surgical closure of the perforation the ulcer should be treated medically. The current enthusiasm for cimetidine almost assures that such treatment will be instituted with the intravenous form of the drug and in the immediate postoperative period. Usual policies of medical treatment should be pursued.

The rationale for an ulcer definitive operation in the treatment of the chronic ulcer that perforates has already been discussed. With one operation the perforation is closed and the ulcer, which is usually destined to be a source of further major morbidity, is treated. Among American surgeons who recognized this fact was Donald of Alabama who in 1939 discussed the advantages of pyloroplasty as a means of secure closure of the perforation which simultaneously would favor-

ably influence the incidence of postperforative morbidity due to chronic peptic ulcer.⁵ The group at Baylor University quite early adopted a policy of gastric resection if the ulcer appeared chronic and the patient's condition permissive. Most importantly, they distinguished between acute and chronic ulcers, a point all too frequently omitted in discussions of treatment of duodenal ulcer with perforation. An ulcer definitive operation is unnecessarily aggressive in perforation of an acute ulcer. Closure without an ulcer definitive operation will condemn the majority of cases of chronic ulcer to subsequent major morbidity from peptic ulcer. The group from Baylor have subsequently added vagotomy to the procedure and in their latest report Jordon, Debakey and Duncan have indicated a mortality of 2.2% for gastrectomy with or without vagotomy for duodenal ulcer with perforation.⁹ Whether others can reduplicate this commendable record will need to be established.

Following adoption of truncal vagotomy and pyloroplasty in the elective surgery for duodenal ulcer, this operation was reported for duodenal ulcer with perforation.¹⁴ Early concern that the vagotomy might invite development of mediastinitis has not been substantiated. Most recently, advocates of proximal gastric vagotomy have reported its use in conjunction with closure of the perforation.^{10,15} Advocates of these various operations all report excellent results in selected cases.

In the series being reported an ulcer definitive operation was performed at the time of perforation in cases of chronic duodenal ulcer that were of reasonable operative risk. There was not a single death among 36 of the 41 cases submitted to such an operation—vagotomy and pyloroplasty in 34 and vagotomy and antrectomy in two additional cases. Of the four cases of chronic ulcer initially treated nonoperatively three cases subsequently underwent successful elective ulcer definitive surgery. The only fatality due to perforation of a chronic ulcer was in the one case previously mentioned in which the perforation was treated by abutment and omental patch and death was directly related to technical failure of this operation.

The present series is not intended as a plea for one or the other specific form of ulcer definitive operation. The surgeon will select an operation which in an individual case would appear to be most appropriate. Performance of proximal vagotomy requires recognition that the operation will be longer in duration than truncal vagotomy and, depending on the degree of inflammation, could be tedious. In the badly scarred and contracted duodenum the matter of both secure closure and adequate channel for gastric emptying must be considered. Pyloroplasty or gastroenterostomy might

be needed in addition to proximal gastric vagotomy, negating a major advantage of the latter type of vagotomy. Truncal vagotomy and pyloroplasty has the advantage of an operation of short duration and one in which the results are excellent in terms of the management of severe duodenal pathology. In certain cases with giant duodenal ulcer, a vagotomy and antrectomy may be the more desirable procedure.

References

1. Amerson, J. R., Howard, J. M. and Vowles, K. D. J.: The Amylase Concentration in Serum and Peritoneal Fluid Following Acute Perforation of Gastroduodenal Ulcers. *Ann. Surg.*, 147:245, 1958.
2. Berne, C. J. and Mikkelsen, W. P.: Management of Perforated Peptic Ulcer. *Surgery*, 11:591, 1958.
3. Berne, C. J. and Rosoff, L., Sr.: Acute perforation of peptic ulcer. *In* Nyhus, L. M. and Wastell, C. (eds.) *Surgery of the Stomach and Duodenum*. Third Ed. Boston, Little Brown and Co., 1977.
4. Crisp, E.: Cases of Perforation of the Stomach, With Deductions Therefrom Relative to the Character and Treatment of That Lesion. *Lancet*, 2:639, 1843.
5. Donald, D. C.: Discussion of Perforation of Peptic Ulcer, *JAMA*, 113:2018, 1939.
6. Graham, R. R.: The Treatment of Perforated Duodenal Ulcers. *Surg. Gynecol. Obstet.*, 64:235, 1937.
7. Illingworth, C. F. W., Scott, L. D. W. and Jamieson, R. A.: Progress After Perforated Peptic Ulcer. *Br. Med. J.*, 1:787, 1946.
8. Jarrett, F. and Donaldson, G. A.: The Ulcer Diathesis in Perforated Duodenal Ulcer Disease. *Am. J. Surg.*, 123:406, 1972.
9. Jordon, G. L., Jr., Debakey, M. E. and Duncan, J. M., Jr.: Surgical Management of Perforated Peptic Ulcer. *Ann. Surg.*, 179:628, 1974.
10. Jordan, P. H., Jr., Hedenstedt, S., Korompai, F. L. and Lundquist, G.: Vagotomy of the Fundic Gland Area of the Stomach Without Drainage: A Definitive Treatment for Perforated Duodenal Ulcer. *Am. J. Surg.*, 131:523, 1976.
11. Jordan, P. H. and Korompai, F. L.: Evolution of a New Treatment for Perforated Duodenal Ulcer. *Surg. Gynecol. Obstet.*, 142:391, 1976.
12. McDonough, J. M. and Foster, J. H.: Factors Influencing Prognosis in Perforated Peptic Ulcer. *Am. J. Surg.*, 123:441, 1972.
13. Paster, S. B. and Brogdon, B. G.: Roentgenographic Diagnosis of Pneumoperitoneum. *JAMA*, 235:1264, 1976.
14. Pierandozzi, J. S., Hinshaw, D. B. and Stafford, C. E.: Vagotomy and Pyloroplasty for Acute Perforated Duodenal Ulcer. *Am. J. Surg.*, 100:245, 1960.
15. Sawyers, J. L. and Herrington, J. L.: Perforated Duodenal Ulcer Managed by Proximal Gastric Vagotomy and Suture Plication. *Ann. Surg.*, 185:656, 1977.
16. Seeley, S. F. and Campbell, D.: Nonoperative Treatment of Perforated Peptic Ulcer; A Further Report. *Int. Abstr. Surg.*, 102:435, 1956.
17. Singer, H. A. and Vaughan, R. T.: Treatment of the "Forme Fruste" Type of Perforated Peptic Ulcer. *Surg. Gynecol. Obstet.*, 54:945, 1932.
18. Sisel, R. J., Donovan, A. J. and Yellin, A. E.: Experimental Fecal Peritonitis: Influence of Barium Sulfate or Water Soluble Radiographic Contrast Material on Survival. *Arch. Surg.*, 104:765, 1972.
19. Taylor, H.: The Non-Surgical Treatment of Perforated Peptic Ulcer. *Gastroenterology*, 33:353, 1957.
20. Wangenstein, O. H.: Non-Operative Treatment of Localized perforation of the Duodenum. *Minn. Med.*, 18:477, 1935.