

# Surgical Experience with Neonatal Necrotizing Enterocolitis (NNE)

JAMES A. O'NEILL, JR., M.D., GEORGE W. HOLCOMB, JR., M.D.

Neonatal necrotizing enterocolitis, a highly lethal disorder of premature infants, is a common occurrence in newborn care units. This report details operative experience with 33 infants over the past seven years. During this time many more infants with NNE have recovered with supportive therapy. All patients are treated on a standard protocol of therapy and monitoring designed to select those with signs of continuing clinical deterioration. Therefore, those coming to operation had additional complications, such as perforation, intestinal gangrene or stenosis. This protocol is described. The 33 infants, averaging less than 4 lbs., developed NNE within five days of birth. Perforation and signs of continued clinical deterioration were the indications for operation; severe sepsis and clotting abnormalities were the rule. The overall mortality was 40% but included six infants with total bowel necrosis who had laparotomy alone. Five patients had intestinal or colonic resection with primary anastomosis, with two leaks leading to death. Twenty-one patients had staged resection with delayed anastomosis and only four deaths. Thus 27 determinative cases had a 26% mortality, and the recent group with staged resection had a 19% mortality. The essentials of pre-, intra- and postoperative management are detailed, as well as pathology and bacteriologic data. Most infants had temporary malabsorption requiring parenteral nutrition and special diets. Long-term results are gratifying.

NEONATAL NECROTIZING ENTEROCOLITIS (NNE) was first described in 1891 by Genersich.<sup>5</sup> Although individual cases were reported after that, the first series of cases of this nature was reported by Berdon, Santulli and the group at Columbia University in 1964.<sup>3</sup> They described the classical clinical picture of sepsis, gastric retention, bile-stained vomitus and abdominal distention with ileus and bloody stools and called this syndrome necrotizing enterocolitis of infancy. Since that time a striking increase in the incidence of this syndrome has been noted around the world, paralleling the development of neonatal in-

*From the Department of Pediatric Surgery,  
Vanderbilt University Medical Center,  
Nashville, Tennessee*

tensive care units and the increasing survival of low-birth-weight infants. Neonatal necrotizing enterocolitis predominately affects low-birth-weight neonates, but we, as others, have noted this syndrome occasionally in term infants, particularly in those with severe cyanotic heart disease or those with severe diarrheal syndromes.<sup>10</sup>

Virnig and Reynolds described the remarkable differences in the incidence of this disorder which have been noted from time to time and place to place, suggesting that epidemiologic factors may be involved.<sup>15</sup> Common etiologic factors noted in most reports include such things as significant stress at the time of birth or immediately following, the occurrence of one or more hypoxic episodes, exchange transfusion, hyperosmolar feedings, umbilical artery catheterization and respiratory distress syndrome.<sup>4,8,9,13</sup>

In recent years it has become clear that most infants are capable of recovering from apparently severe NNE with supportive therapy alone. A number of efforts have been made to distinguish those infants who are capable of responding to supportive therapy and those who will require surgical intervention.<sup>2,7</sup> The proper timing of surgical intervention is still to some degree unclear.

Our group has developed a protocol for therapy and close follow-up which has been utilized over the past several years. In a previous report we described a number of factors constituting indications for operation; these included deterioration under conservative therapy, signs of perforation, such as free air and progressive ascites, persistent acidosis and drops in platelet counts unaccounted for by any other factor.<sup>7</sup> This report describes our continued experience with this protocol, as well as the surgical results obtained in this group of patients.

Presented at the Annual Meeting of the Southern Surgical Association, December 4-6, 1978, Hot Springs, Virginia.

Reprint requests: Dr. James A. O'Neill, Department of Pediatric Surgery, Vanderbilt University Medical Center, Nashville, Tennessee 37232.

Submitted for publication: December 7, 1978.

### Clinical Aspects

The treatment protocol of supportive therapy includes the concept that all infants suspected of having NNE are followed jointly by the neonatology and pediatric surgical teams (Fig. 1).

If an infant is thought to have a mild form of the disease with transient abdominal distention and bloody stools, feedings are withheld and drainage with an orogastric tube is instituted. Intravenous nutritional support via peripheral vein is provided in the form of 10% glucose, amino acids and fat emulsion. Antibiotics are administered as indicated, according to data obtained from nasopharyngeal, stool, urine, endotracheal, cerebrospinal fluid and serial blood cultures. Ordinarily intravenous ampicillin and gentamicin are administered, and other antibiotics are added as culture information becomes available. If the infant's clinical picture improves within a few days, enteral feedings are cautiously begun again, following a week of bowel rest.

In those infants suspected of having a severe form of the disease, manifested not only by bloody stools and sudden abdominal distention but also severe clinical deterioration and perhaps lethargy, apneic spells, hypothermia and circulatory collapse, a much more aggressive regimen is instituted. A Silastic® catheter is introduced into the superior vena cava via the common facial vein at first for the purpose of repairing volume depletion and then for the purpose of providing total parenteral nutrition for two or more weeks as needed until some enteral intake is possible. Since glucose intolerance is common during the initial stages of NNE when the infants are septic, 10% glucose with 1.4% crystalline amino acids is administered intravenously, the strength of the solutions gradually being increased to 20% glucose and 2.8% amino acids as the infant's ability to tolerate glucose improves. Every effort is made to insure sufficient calorie and protein intake, as well as optimum plasma and red cell volume and acid-base and electrolyte balance.

Those infants suspected of having NNE are examined by the two treatment teams at least every eight hours. At the same intervals, recumbent and left lateral decubitus abdominal x-rays are obtained. These intervals are lengthened or shortened according to the infant's clinical progress. If significant abdominal fluid is noted on x-ray in an infant who has distention paracentesis is performed, sometimes with peritoneal lavage with Ringer's lactate, so that the fluid obtained may be cultured and tested with Gram's stain. Serial bilirubin, hematocrit, white blood cell count, electrolyte, pH and blood gas determinations are made as indicated. During the past five years, it has been the

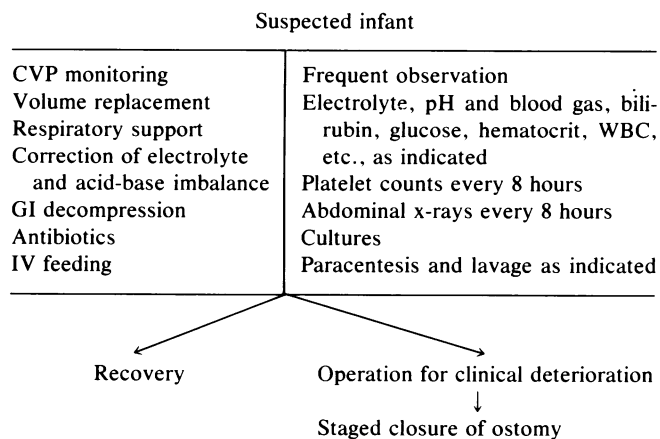


FIG. 1. NNE—treatment and follow-up protocol.

practice to obtain platelet counts every eight hours initially and less frequently as clinical improvement occurs. Blood glucose determination is followed with heel stick estimations.

The decision to terminate supportive therapy and institute operative intervention is individualized. Indications for operation include clear-cut signs of perforation, as judged by x-ray and examination of peritoneal fluid, or evidence of continued physiologic deterioration, as indicated by the various laboratory studies mentioned. During the past five years, particular emphasis has been placed on drops in the platelet count to levels of 100,000 or below in infants who had normal platelet counts initially and who have no other obvious reason for such a fall.

During the past seven years, approximately 4,250 infants have been admitted to the Vanderbilt neonatal intensive care unit, and 142 (3.3%) of these were considered to have definite signs of NNE on the basis of operative or postmortem information or on the basis of combined physical signs along with radiographic demonstration of pneumatosis intestinalis. Although a number of other infants displayed some of the clinical signs of mild NNE and were treated as having such, they did not satisfy sufficient numbers of these criteria to be included in this review. It is of interest that the incidence of NNE in this intensive care, low-birth-weight population has increased from approximately 2.5% in 1975 to 4% during the past three years. Of the 142 patients with a definite diagnosis of NNE, 33 (23%) were subjected to operation on the basis of the above-mentioned criteria.

Of the 33 surgical patients, 18 were male and 15 female. Birth weight ranged from 1 lb. 6 oz. to 6 lbs., with a mean of slightly less than 4 lbs. Gestational age was estimated to be from 24 to 40 weeks, but the majority of infants were premature, with low birth weight and idiopathic respiratory distress syndrome. The maternal

TABLE 1. *Necrotizing Enterocolitis Laboratory Findings*

Determination	No. of Patients
Anemia	32
↓ Serum sodium	19
Persistent acidosis	8
Abnormal clotting	30
↓ Serial platelet counts (Fell 150,000; avg. 72,000)	27/28

Serial platelet counts which fell from normal levels to below 100,000 almost always correlated with the presence of gangrenous bowel in patients who had no other obvious reason for the fall.

history in all of these 33 patients included at least one of the following findings: prolonged or precipitous labor, premature rupture of membranes or severe meconium staining of amniotic fluid, suggestive of intrauterine fetal distress. The infants themselves had low Apgar ratings for up to ten minutes following birth, shock in the early neonatal period, a prolonged hypoxic episode or obvious respiratory distress syndrome. Essentially all of these patients demonstrated severe respiratory distress and hypoxia soon after birth, and 18 of the 33 patients required respiratory support at some time prior to the onset of NNE. While no definite predisposing factor could be determined in a few of the patients who recovered on supportive therapy alone, it is remarkable that all of the patients who required surgical intervention had some obvious severe form of perinatal stress and hypoxemia.

### *Signs and Symptoms*

All 33 infants who subsequently required operation displayed signs and symptoms including ileus with abdominal distention and gastric retention, vomiting of bile-stained, usually guaiac-positive material, lethargy and temperature instability usually in the form of hypothermia. Changes in the appearance of the infant's peripheral circulation were noted in 30 of the 33 infants. Stooling usually stopped, and what stool was present invariably had gross or occult blood in it. Jaundice, apneic spells requiring respiratory assistance, dehydration and abnormal bleeding occurred in half the group.

Sixteen of the 33 infants had received at least one feeding prior to the onset of symptoms, but only one had received any feedings which might be considered hyperosmolar. Three patients had exchange transfusion because of hyperbilirubinemia prior to the onset of enterocolitis. In six instances the first clinical signs noted were sudden shock, tight abdominal distention and clear evidence of a catastrophic intra-abdominal event. Twenty-eight of the 33 patients had the first sign of NNE within the first five days of life,

while four patients had their first signs and symptoms between the sixth and fourteenth days, and one patient had the onset of symptoms at 30 days following birth.

### *Physical Findings*

Twenty of the 33 patients had physical findings including abdominal tenderness and evidence of peritoneal irritation. However, the remaining 13 patients had only equivocal signs of tenderness. The physical findings in the surgical group as a whole did not differ significantly from those noted in patients treated with supportive measures alone. Redness and edema of the abdominal wall was present in only two of the patients who required operation.

### **Laboratory Findings (Table 1)**

Six patients had only a single set of laboratory determinations made prior to operation, but 27 had serial laboratory studies which were available for analysis. A sudden drop in serum sodium seen in 19 patients, indicated the presence of sepsis with significant third-space volume loss. This persisted in four patients on supportive therapy and was accurately considered to be a sign of deterioration requiring operative intervention. Metabolic acidosis unresponsive to therapy for longer than four hours occurred in eight of these infants; this also proved to be an accurate indication that the infant was not responding to supportive therapy. Thirty of the 33 patients demonstrated abnormally low platelet counts, with lengthening of the partial thromboplastin generation or prothrombin times. Serial platelet counts were performed prospectively in 28 patients, who subsequently developed gangrenous bowel requiring operation. In 27 of these 28, platelet counts fell 150,000 or more from initial levels to the range of 5,000–130,000. One patient with gangrenous bowel who had an initial platelet count of 192,000 had a follow-up count six hours later of 200,000 but was subjected to operation because of resistant metabolic acidosis. Anemia was present in the majority of instances but did not indicate that a change in therapy was in order.

### **Radiologic Findings**

Abdominal radiographs on all patients demonstrated intestinal distention and varying amounts of intramural intestinal gas, primarily in the right lower quadrant, although occasionally on the left side of the abdomen as well. Pneumatosis generally cleared within 72 hours. In many instances it cleared within 24 hours. Pneumatosis progressed to a picture of abdominal distention and apparent ascites in eight patients. Gas was noted within

the portal venous tree in six instances, but it tended to be transient and cleared within 18 hours in all. Pneumoperitoneum was seen in nine patients. Those patients who had progressive accumulation of intra-abdominal fluid were subjected to paracentesis, sometimes with Ringer's lactate lavage, and bacteria were found on a smear in all. This was an accurate indication that operation was needed. None of these patients had barium contrast studies early, and it is our feeling that they are contraindicated under these circumstances.

### Operative Procedures

Six low-birth-weight infants whose weight averaged approximately 2,000 g were found to have involvement of essentially the entire gastrointestinal tract, and all died within 18 hours; only laparotomy was performed, and one of these patients was re-explored at 12 hours without success. Intraoperative use of vasodilators, steroids and similar supportive measures were not helpful. Although focal necrosis of the midsmall bowel was noted in five additional patients, it was relatively limited and either responded to no treatment, limited plication, or, in one instance, resection and jejunal anastomosis. Early in the series four patients had ileo-right colic resections with primary anastomosis, and two of these patients had anastomotic leaks leading to death. During the past three years, a fifth patient had a successful jejunal resection with anastomosis along with ileostomy. Twenty-one patients underwent staged exteriorization resection with only four deaths, all these occurring within eight hours of operation. Six patients underwent resection of varying lengths of the distal ileum and right colon with exteriorization; two and four patients, respectively, had right and left colonic resections with colostomy. One patient had resection of the transverse and left colon with colostomy, and eight patients had subtotal colectomy with ileostomy and closure of the rectal remnant. Peritoneal drainage was not utilized in any patient and would probably not have been helpful, except perhaps in the two patients who had primary ileocolic anastomoses which leaked.

Gastrostomy was added to these procedures in eight patients who were expected to have long-term gastrointestinal dysfunction because of spotty areas of small bowel necrosis scattered throughout the gastrointestinal tract. In every instance, total parenteral nutrition was used for support postoperatively. Varying degrees of malabsorption were the rule in the 20 surviving patients, so that reinstatement of full enteral feedings was invariably a slow process requiring total or partial intravenous nutritional support for as long as two months postoperatively while gradual in-

creases in oral intake were accomplished. Dilute feedings were used initially and then gradually increased to full strength as patients demonstrated ability to absorb fat and carbohydrates. Recently, we have been using a mixture of Portagen<sup>®</sup>, Polycose<sup>®</sup>, vegetable and medium-chain triglyceride oils, casein hydrolysate, calcium and vitamins graduating from one-fourth to full strength (20 calories/oz).

All of these patients were severely ill, and careful pre-, intra- and postoperative management was essential to their survival. Double exchange transfusion was performed pre- or postoperatively in four patients, and platelet transfusions were administered immediately preoperatively, as well as intraoperatively, in six patients. In every instance these patients benefitted from these procedures. As far as possible, all patients were returned to electrolyte and acid-base balance before operation was undertaken, although this was not feasible in every instance. Intraoperative management included monitoring of arterial and central venous pressures as well as determination of pH and blood gases. All 33 patients were maintained on postoperative controlled ventilatory assistance.

Two patients were operated on 25 and 30 days, respectively, following onset of enterocolitis, because of left colonic strictures. Both patients had primary anastomosis and survived operation, but one of these patients died one week later because of resistant *Klebsiella pneumonia* with sepsis.

The overall operative mortality is 40%, but if those patients with inoperable disease are excluded, the mortality is 26% and only 19% for those treated by staged resection and later anastomosis.

Reanastomosis of the gastrointestinal tract has been performed in 15 patients 2–10 months following operation; two patients are currently awaiting this procedure. It has been our practice to defer reconstitution of the gastrointestinal tract until the patient has recovered from the various complicated medical problems which invariably coexist with enterocolitis and until weight gain has been demonstrated. It did not appear that earlier anastomosis would have helped any of these patients.

### Pathology

The gross and microscopic findings in involved bowel were typical of NNE as described by Santulli and his associates; they included mucosal necrosis with ulceration, submucosal hemorrhage and inflammation, pseudomembrane formation, intramural gas, involving both submucosa and subserosa, and occasional thromboses in small mesenteric vessels.<sup>13</sup> Six of the 33 patients had necrosis of essentially the entire gastro-

intestinal tract. Five additional patients who had primary involvement of the colon also had focal areas of necrosis in the midsmall bowel. However, 26 of the 33 patients had gangrenous changes with or without perforation in the ileocolic region. Ten patients had irreversible gangrenous changes in the distal ileum and right colon; two patients and four patients, respectively, had localized areas of right and left colon involvement. One patient had involvement of the transverse and descending colon, and eight patients had extensive involvement of essentially the entire colon and distal ileum. Two patients who were initially thought to have recovered on supportive therapy alone went on to develop partial intestinal obstruction and long fibrotic strictures in the descending colon.

### Bacteriology

Thirty of the 31 emergent patients had peritoneal cultures which yielded bacterial growth, and one patient had an apparently sterile culture. While almost all patients had one or more blood cultures, 16 patients had positive blood cultures which correlated with the results of the peritoneal cultures. There was also good correlation between peritoneal cultures and cultures from other areas, such as cerebrospinal fluid, pulmonary secretions, and stool, indicating that extensive colonization had occurred in these patients.

The organisms most frequently encountered were *E. coli*, *Klebsiella pneumoniae* and *Pseudomonas* in varying combinations in 23 patients. *Klebsiella pneumoniae* was the most frequently encountered. In the remaining seven patients with positive cultures the organisms were *Staphylococcus*, *Candida albicans*, *Clostridium perfringens*, enterococcus and beta *Streptococcus* either singly or in combination. Fortunately, in only one instance was a *Klebsiella* resistant to all antibiotics available.

### Long-term Follow-up

Reference has already been made to the problems with intestinal absorption and need for long-term nutritional support in many of these patients. Secondary surgical procedures for reconstitution of intestinal continuity have generally gone very well. Only one patient has required a later operative procedure for intestinal obstruction due to adhesions. Those patients who had reconstitution of intestinal continuity by ileorectostomy have invariably had persistent diarrhea but have gradually adapted over a period of 3–6 months on modified diets and careful attention to perianal skin care.

Sixteen of the 20 surviving patients appear to be neurologically normal in every respect, but four pa-

tients have neurological problems. One of the four is clearly mentally retarded; one patient has severe seizures and may be retarded; and two have mild to moderate cerebral palsy with no definite signs of retardation.

### Comments

Neonatal necrotizing enterocolitis continues to be a serious problem in low-birth-weight, intensive care populations of newborn infants. While we, as others, have noted this problem occasionally in term infants, it has predominantly occurred in stressed, low-birth-weight neonates requiring treatment for severe respiratory distress syndrome. A few years ago the incidence in our newborn intensive care unit population was approximately 2.5% of admissions. Over the past three years the incidence has been 4.0% of the population at risk, but this is almost certainly a factor of increased rate of diagnosis rather than a true increase in incidence of the disease.

A number of etiologic factors have been mentioned as possibly contributing to the development of NNE. Neonatal asphyxia, transient hypoxemia, sepsis and shock at or shortly following birth may logically result in diminished splanchnic blood flow with resultant mucosal necrosis, invasive bacterial proliferation and transmural infarction, as suggested by Harrison et al.<sup>6</sup> Exchange transfusion via the umbilical vein has been mentioned by Orme and others as a possible causative factor in that it may result in altered portal flow in infants with a closed ductus venosus.<sup>8</sup> Although this is certainly possible, it is probably a minor factor in etiology since most infants with NNE do not have exchange transfusion as a part of their clinical picture. As a matter of fact, exchange transfusion has recently been used successfully to treat some of the severe hematologic abnormalities seen in infants with this syndrome. Certainly the patent ductus syndrome associated with idiopathic respiratory distress syndrome in premature infants seems to be related to NNE; these infants have severe derangements in cardiac output which would be expected to result in abnormalities of splanchnic flow during the first week in life. A number of our patients had this association. Additional information relating diminished splanchnic flow to the etiology is the fact that the vast majority of patients have involvement of bowel in areas of peripheral blood flow and, in particular, the terminal ileum and right colon. Hyperosmolar feedings and rapid feeding have also been indicted by Book and others as causative factors in that they may cause flow changes related to dumping.<sup>4</sup> In our surgical group of 33 patients, 16 had received feedings but in only one instance was

it considered hyperosmolar. The infants may have been progressed to feedings too rapidly, however. Seventeen of the 33 patients had never been fed prior to the onset of NNE. It is currently our practice to withhold enteral feedings from any infant who has severe hypoxemia and respiratory distress during the first week of life and to provide support with peripheral intravenous glucose, amino acids and fat emulsion. While a number of bacteriologic organisms have been encountered, gram-negative bacteria have predominated in this group in a fashion to suggest heavy colonization rather than a primary bacteriologic etiology, as suggested by Pedersen.<sup>9</sup> It seems that a number of etiologic factors are involved in a cumulative fashion.

The supportive treatment regimen has been designed to provide maximal multisystem support with emphasis on volume repletion, acid-base neutralization, minimalization of hypoxemia, careful bacteriologic surveillance, correction of hematologic abnormalities and intensive nutritional support. As supportive therapy has improved, survival of infants treated by these methods have improved proportionately. Over the past seven years, 109 patients treated by supportive measures alone in our unit have had an 81% survival rate, with the majority of deaths being due to causes other than NNE. It has become clear that the vast majority of infants with NNE are capable of recovering with non-operative therapy alone.

Despite the fact that the number of patients treated by non-operative means has increased with improvements in life support measures, some subjects have progression of disease and operation becomes mandatory. Over the past seven years, 33 of the 142 (23% patients encountered with this disease have required operation. Emphasis has been placed on the development of a protocol to select infants who will require operation prior to a time when the disease has progressed to the point of free perforation. It appears that multiple laboratory and x-ray findings as well as clinical information from physical observation are required in order to make this determination. Our group has placed particular emphasis on serial determination of platelet counts as a mode of follow-up, along with the other things mentioned above, as a possible guide to selecting infants who will require operation. Unfortunately, severe hematologic abnormalities are common in infants with severe hyaline membrane disease and other disorders of prematurity, but infants who do not have another explanation for an abnormally low platelet count may be followed in this fashion. In 28 patients who had gangrenous bowel in whom serial platelet counts were performed prospectively, significant decreases occurred in 27, and only one patient with gangrenous bowel was not selected

TABLE 2. *Necrotizing Enterocolitis—Surgical Survival*

Authors	No. Patients	% Survival
Torma et al., '73 <sup>14</sup>	24	42
Roback et al., '74 <sup>11</sup>	42	32
Santulli et al., '75 <sup>13</sup>	27	33
Roty et al., '76 <sup>12</sup>	27	41
This series	33	61

This lists comparable series generally demonstrating increasing survival over the years. If patients with irreparable pathology are excluded, survival ranges from 50–80%.

by this study. Information from physical examination was generally not helpful in selecting infants who required a change from supportive to operative therapy. Serial x-rays were helpful in terms of making an initial diagnosis, determining when free perforation had occurred or when progressive accumulation of intra-abdominal fluid was present, as a guide to the timing and location of abdominal paracentesis. Any radiologic evidence of localized or generalized abdominal fluid associated with abdominal distention added emphasis to the need for operation, particularly when associated with decreasing platelet counts.

The experience with this series of patients suggests that the aforementioned protocol of follow-up of infants on supportive therapy is a valid method of selecting those who will require operation. This is supported by an increasing survival rate of patients in the non-operative group, as well as an increase in survival of those who have undergone operation, since more have been operated on at an earlier time than in previous years, when most infants had progressed to the point of perforation before operation was undertaken.

Unfortunately, a certain number of patients will have such severe disease that no therapy will be sufficient to provide survival, as was the case in six of our patients. An additional four died within eight hours of operation with fulminant sepsis and irreversible shock despite intensive therapy. If the six patients with complete bowel necrosis are excluded, mortality in the surgical group is 26%, although the overall surgical survival of 60% still compares favorably with reported series in the literature (Table 2). The majority of authors indicate that resection with primary anastomosis is to be avoided and that staged, exteriorization resection and late anastomosis is to be preferred. Certainly our experience would be in agreement with this. Although the timing of the second stage for anastomosis is debatable, our experience has led us to believe that it is preferable to wait until these critically ill infants are out of the woods and thriving before intervening again. The late occurrence of stricture in the defunctionalized distal bowel is perhaps another reason to take this approach. Even though the majority of

infants are able to recover today on supportive therapy alone, careful observation for one or two months is essential since some reports suggest that as many as 10% of patients may develop strictures,<sup>1</sup> although our experience does not indicate that the percentage is this high.

Intravenous nutritional support continues to be one of the mainstays of care in the postoperative period. Since most patients have significant malabsorption problems for periods varying from two weeks to three months, initial provision of total parenteral nutrition with a gradual advance to partial parenteral nutrition with small supplements of enteral feedings has proven to be the most effective method of management thus far available. An additional dividend obtained has been the ability to support early nutrition without being forced to push enteral feedings which might potentiate the recurrence of enterocolitis. Not a single patient in this series had recurrence of NNE during the period of follow-up.

The long-term follow-up of infants who have been followed through the period of gastrointestinal tract reconstruction, even in the case of subtotal colectomy, has been gratifying in the long run. All eventually resumed normal growth and development. Even though some patients have had prolonged periods of malabsorption and diarrhea, this has eventually responded to therapy and adaptation. A limitation perhaps is the realization that a certain number of these very tiny, critically ill infants will be brought through a long and difficult illness only to end up with varying degrees of neurologic impairment. However, this is a factor in the care of low-birth-weight infants in general and must be evaluated as further experience is gained in long-term follow-up.

#### DISCUSSION

DR. H. BIEMANN OTHERSEN, JR. (Charleston, South Carolina): Dr. O'Neill has presented an elegant protocol for diagnosis and treatment and management of these children, and his results are certainly to be applauded. I agree with all of the data and the method of management which he has presented. I would just like to ask two questions.

Why do we see such an incidence difference in various parts of the country?

In Charleston, we rarely see infants with NNE, and I don't know why. I have talked to our pathologist about it, and he doesn't know why. Shortly after we talked about it, we had three cases come in, but I expected that. Subsequent to that, we have seen very few.

And if anyone knows of a reason why there is such a difference in incidence around the country and around the world, I don't think it's been brought out. But I'd like to know if Dr. O'Neill knows that.

And the second question is: Did you use intraluminal antibiotics, as well as systemic antibiotics?

#### References

1. Bell, M. J., Ternberg, J. L., Askin, F. B. et al.: Intestinal Stricture in Necrotizing Enterocolitis. *J. Pediatr. Surg.*, 11:319, 1976.
2. Bell, M. J., Ternberg, J. L., Feigin, R. D. et al.: Neonatal Necrotizing Enterocolitis: Therapeutic Decisions Based on Clinical Staging. *Ann. Surg.*, 187:1, 1978.
3. Berdon, W. E., Grossman, H., Baker, D. H. et al: Necrotizing Enterocolitis in the Premature Infant. *Radiology*, 83:879, 1964.
4. Book, L. S., Herbst, J. J. and Jung, A. L.: Comparison of Fast- and Slow-feeding Rate Schedules to the Development of Necrotizing Enterocolitis. *J. Pediatr.*, 89:463, 1976.
5. Genersich, A.: Bauchfellentzündung beim Neugeborenen in Folge von Perforation des Ileums. *Arch. Pathol. Anat.*, 126: 485, 1891.
6. Harrison, M. W., Connell, R. S., Campbell, J. R. and Webb, M. C.: Microcirculatory Changes in the Gastrointestinal Tract of the Hypoxic Puppy: An Electron Microscopic Study. *J. Pediatr. Surg.*, 10:599, 1975.
7. O'Neill, J. A., Stahlman, M. T. and Meng, H. C.: Necrotizing Enterocolitis in the Newborn: Operative Indications. *Ann. Surg.*, 182:274, 1975.
8. Orme, R. L. and Eades, S. M.: Perforation of the bowel in the New born as a Complication of Exchange Transfusion. *Br. Med. J.*, 4:349, 1968.
9. Pedersen, P. V., Hansen, F. H., Halveg, A. B. and Christiansen, E. D.: Necrotizing Enterocolitis of the Newborn—Is It Gas Gangrene of the Bowel? *Lancet* 11:715, 1976.
10. Polin, R. A., Pollack, P.F., Barlow, B. et al.: Necrotizing Enterocolitis in Term Infants. *J. Pediatr.*, 89:460, 1976.
11. Roback, S. A., Foker, J., Frantz, I. F. et al.: Necrotizing Enterocolitis: An Emerging Entity in the Regional Infant Intensive Care Facility. *Arch. Surg.*, 109:314, 1974.
12. Roty, A. R., Kilway, J. B., Brown, A. L. and Peelen, M.: Neonatal Necrotizing Enterocolitis—A Personal Experience. *Surgery*, 80:340, 1976.
13. Santulli, T. V., Schullinger, J. N., Heird, W. D. et al.: Acute Necrotizing Enterocolitis in Infancy: A Review of 64 Cases. *Pediatrics*, 55:376, 1975.
14. Torma, M. J., DeLemos, R. A., Rogers, J. R. and Diserens, H. W.: Necrotizing Enterocolitis in Infants: Analysis of 45 Consecutive Cases. *Am. J. Surg.*, 126:758, 1973.
15. Virnig, N. L. and Reynolds, J. W.: Epidemiological Aspects of Neonatal Necrotizing Enterocolitis. *Am. J. Dis. Child.*, 128:186, 1974.

DR. ANTHONY SHAW (Charlottesville, Virginia): It is curious how the differences from one region to another are so marked. Almost all of the infants in whom the diagnosis of neonatal necrotizing enterocolitis was made in our neonatal nursery at the University of Virginia required surgical treatment; and I think we're perhaps as astute at diagnosing it as anyone.

Our criteria are clinical and radiographic. Those who had radiographic evidence of the disease we would treat with parenteral and enteral antibiotics, withdrawal of early feedings—we even gave them dextran intravenously, which some people recommend—and almost all of them progressed downhill. Their acidosis got worse, and all the bad things that Dr. O'Neill indicated on his slide occurred, and almost all of them required an operation.

Our findings at surgery were similar to his. The severest involvement was in the distal small bowel, the terminal ileum, and the right bowel. This was managed with resection, a cutaneous enterostomy, and oversewing of the distal end. We usually would perform a gastrostomy as well.

Our major problem lay in those children who seemed to have involvement from stem to stern. There were some in whom the