

Ileal Resection Potentiates 1,2-Dimethylhydrazine-induced Colonic Carcinogenesis

JAN E. A. OSCARSON, M.D., HERMAN F. VEEN, M.D., JEFFREY S. ROSS, M.D., RONALD A. MALT, M.D.

The effect of colonic hyperplasia produced by resection of the distal third of the small bowel (DSBR) on the development of chemical carcinogenesis of the colon by dimethylhydrazine (DMH) was tested in rats. For the most part the amounts of RNA and DNA in the small bowel were the same with the combined treatments as with either one alone; quantities of nucleic acids tended to increase only in transverse and distal colon. After 37 weeks the number of neoplasms per rat was increased six-fold by combining DSBR with DMH. Neoplasms were spread throughout the colon after combined treatment as opposed to the ascending colon after DMH alone. Postresectional hyperplasia appears to increase the incidence and distribution of colon tumors.

COLONIC TUMORS RESULTING FROM administration of 1,2-dimethylhydrazine (DMH)^{16,23} closely resemble human colonic carcinomas in morphology and development.⁹ Moreover, just before they appear there are signs of increased cell proliferation, such as a greater number of thymidine-labeled cells in the glands of Lieberkühn and on the surface of the colonic mucosa.^{9,10,19} These signs are similar to the "phase-2" lesions believed to precede frank neoplasia^{8,9} and are seen in familial polyposis.³ Since experimental injury and diseases such as ulcerative colitis that stimulate cell proliferation lower the threshold of colonic mucosa to carcinogenesis^{5,11,15} and since distal small bowel resection in the rat produces colonic hyperplasia within 48 hours,¹³ we tested the susceptibility of hyperplastic colonic mucosa stimulated by ileal resection to the development of DMH-induced neoplasia.

Materials and Methods

Male Sprague-Dawley derived rats (Charles River Breeding Laboratories Inc., Wilmington, MA) weighing 130–140 g were kept in cages with open wire-mesh bottoms and were fed Purina rat pellets[®] and

From the Surgical Services, Shriners Burns Institute and Massachusetts General Hospital, and the Department of Surgery, Harvard Medical School, Boston, Massachusetts

water for 7–10 days before being randomly allocated to one of four groups. The animal quarters were lighted in alternate 12 hour cycles.

Normal rats had no operation. Rats with resections had the distal third of the small bowel (26.5 ± 0.7 cm) removed (preserving the ileocecal valve), and an end-to-end anastomosis was performed with 6-0 silk. All animals were fed until operation (9:00 a.m. to 1:00 p.m.), but then had food withheld for 24 hours. Half of the normal rats and half of the rats with resection were randomly allocated to receive a subcutaneous injection of 10 mg/kg body weight of 1,2-dimethylhydrazine (symmetrical, Aldrich Chemical Company, Inc. Milwaukee, Wisc.) from a fresh solution made by dissolving the DMH crystals in sterile isotonic NaCl solution and adjusting the pH with 0.1 M NaOH. The other half of each group received an injection of equal volume of the vehicle with pH adjusted to 6.5 with 0.1 M HCl. The injections were given at the end of the operation or, in the unoperated animals, at an equivalent timepoint. Five batches containing all four experimental groups were produced for planned sacrifice five, 13, 21, 29 and 37 weeks after the first injection. Each animal received a weekly injection for a maximum of 12 weeks.

At the time of sacrifice (9:00 a.m. to 1:00 p.m.), following the order of use, each animal was given a subcutaneous injection of 100 μ Ci of [³H-methyl]thymidine (6.7 Ci/mole, New England Nuclear Corp. Boston, MA) and was killed by cervical dislocation one hour later. The cecum, the large bowel, and the small bowel were separated. Each segment was flushed gently with ice-cold NaCl solution and was placed on a glass plate resting on crushed ice. The opened large bowel mucosa was checked for tumors. Mucosa from 5cm segments from the ascending, transverse and descending colon was scraped between glass slides,

Reprint requests: Ronald A. Malt, M.D., Massachusetts General Hospital, Boston, Massachusetts 02114.

Submitted for publication: October 6, 1978.

Supported in part by the U.S. Public Health Service through the National Cancer Institute and the National Large Bowel Cancer Project, Grant CA-17324, and the Henry Greco Memorial Fund.

frozen in liquid nitrogen, and stored at -70° for later analysis. Neither visible tumors nor Peyer's patches were included in specimens for estimation of nucleic acid contents. The small bowel was opened, and a 5cm segment from the mid small bowel was treated the same way. The cecum was checked for visible tumors. Immediately distal to each mucosal scraping, specimens of bowel 1cm long were taken and fixed in 10% Formalin. Random specimens of scraped intestinal wall showed few residual crypts on microscopical examination.

Later, the mucosal specimens were thawed and homogenized in 5% (w/v) citric acid in 0.25 M sucrose. Contents of RNA and DNA were estimated.^{7,18} Aliquots of the DNA fraction were counted by liquid scintillation spectrometry at 25% efficiency corrected by internal standardization.

From coded, properly oriented histological sections stained with hematoxylin and eosin, 10 determinations of villous height and crypt depth were made per slide. Sections from tumors were prepared similarly for histopathological classification.

Statistical significance was assessed by Student's *t*-test for unpaired data or by the Mann-Whitney test, unless otherwise indicated.

Results

Weight Gain

The weight increase was approximately the same in four experimental groups ($N = 162$). Figure 1 shows the weight development during 37 weeks. During

growth and at sacrifice all groups were statistically identical (one-way analysis of variance). More pronounced weight loss of animals with distal small bowel resection and DMH administration was seen one week after the first injection and the weights remained low during the whole observation period; however, as compared with weights of animals with distal small bowel resection and administration of vehicle they were not statistically different.

Mortality Rate

The survival until sacrifice was 100% in the control group that received vehicle alone (28/28) and 94% in the group that received DMH (42/45). Of animals with distal small bowel resection 81% survived after injection of vehicle (36/44) and 82% after injection of DMH (37/45). Eight postoperative deaths were from anastomotic leakage: three in the vehicle-injected groups and five in the DMH-injected groups. Pneumonia was the cause of death in four animals injected with DMH (two with and two without distal small bowel resection) and of five animals with distal small bowel resection and injected with vehicle. Bowel sections from two animals dying of intussusception of colonic tumors (one with bowel resection and one unoperated) were examined for incidence of tumors but not for nucleic acid contents.

Effect of Resection

Resection of the distal small bowel produced adaptive mucosal hyperplasia in the remaining bowel mu-

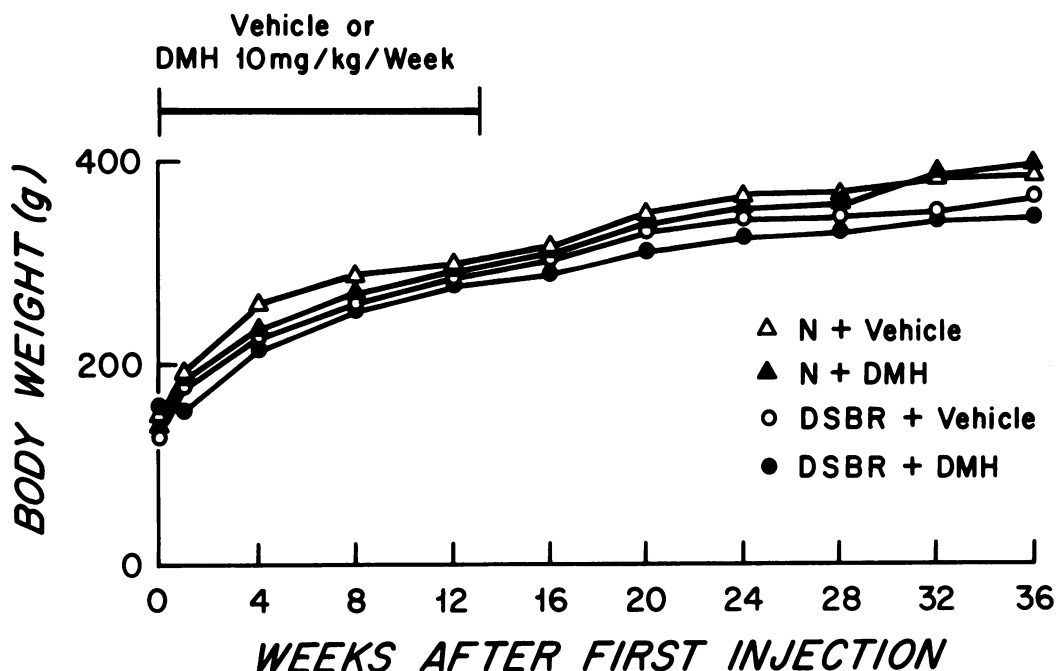


FIG. 1. Mean body weight (g) of each group measured weekly for 37 weeks. *N*, normal rats; *vehicle*, isotonic saline solution; *DMH*, dimethylhydrazine; *DSBR*, distal small-bowel resection.

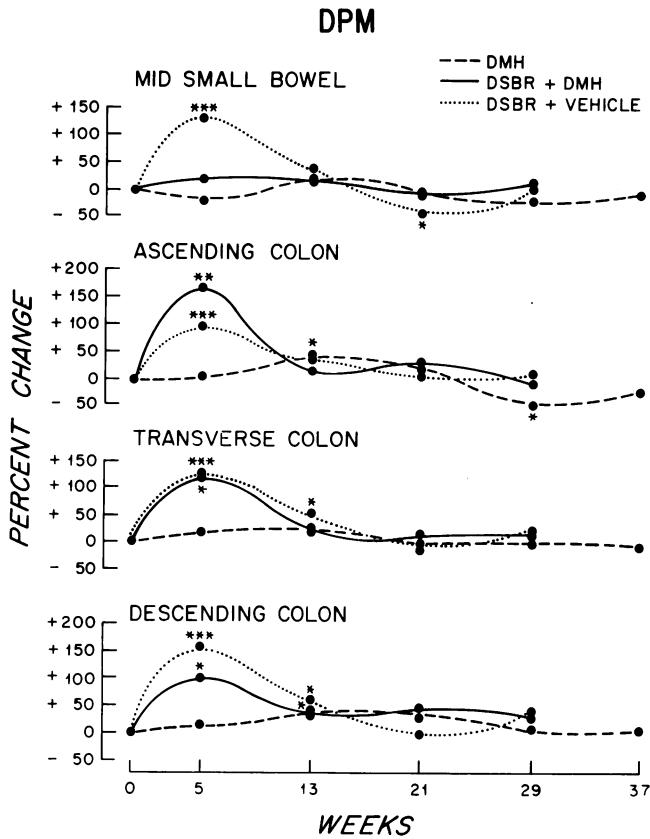


FIG. 2. Total radioactivity in DNA content in 5cm mucosa of the mid small bowel, ascending, transverse, and descending colon: DPM, disintegrations per minute. Base line is control (unoperated rats receiving vehicle). Changes presented as deviation in per cent from base line. Significances versus control * $p < 0.05$, ** $p < 0.01$, *** $p < 0.001$.

cosa. The radioactivity in DNA was equally increased in the small and large bowel mucosa; in all instances this effect was most pronounced five weeks postoperatively and was barely noticeable eight weeks later (Fig. 2). In the mucosa of the mid small bowel and of the ascending and transverse colon the increase in DNA content was maximal five weeks postoperatively; it gradually diminished thereafter, but was still noticeable after 24 weeks (Fig. 3). The RNA content also increased rapidly in the small bowel mucosa and diminished with time; in the large bowel mucosa a moderate increase was seen 21–29 weeks postoperatively (Fig. 4). The effect on the villous height was most pronounced in the small bowel 21 weeks postoperatively (Table 1).

Effect of DMH

Injection of DMH elicited a moderate increase in radioactivity incorporated into DNA of small and large bowel mucosa. This effect was most pronounced 13 weeks after the onset of treatment (*i.e.*, one week after the course of injections was finished) (Fig. 3). The

amounts of both DNA and RNA followed suite and also increased moderately (Figs. 3 and 4). Twenty-one weeks postoperatively the villous height of the mid small bowel showed its maximal increase (Table 1).

Effect of Distal Small Bowel Resection Combined with DMH

In the mid-small bowel, DMH treatment abolished the increase in radioactivity in DNA seen after resection alone (Fig. 3), and apart from an early increase in the RNA content similar to that of resection alone, the effects of the combined treatments on the amounts of DNA and RNA were the same as those after injection of DMH alone (Figs. 3 and 4). In the large bowel radioactivity in DNA was the same as after resection alone (Fig. 2). In the ascending colon the DNA content tended to be slightly higher than after DMH alone. The net increase in RNA content after the combination of treatments was similar to that of either treatment alone. In the transverse and descending colon the DNA content was greater than that after DMH injection.

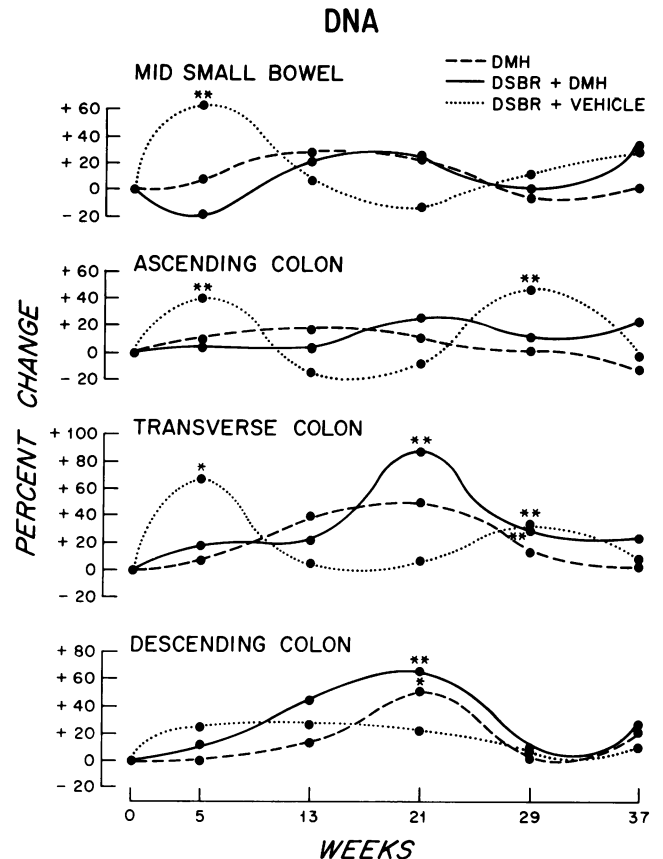


FIG. 3. Total DNA content in 5cm mucosa of the mid small bowel, ascending, transverse, and descending colon. Base line is control (unoperated rats receiving vehicle). Changes presented as deviation in per cent from base line. Significances versus control * $p < 0.05$, ** $p < 0.01$.

tion or distal small bowel resection alone (Fig. 3). A similar tendency, but less pronounced, was also seen in the RNA content (Fig. 4).

Development of Tumors

No tumors were found in animals injected with vehicle. The prevalence of tumors in DMH-treated rats was 16%. The tumors were polypoid, tubular, colloid, or mixed adenocarcinomas with an exophytic, intramucosal, submucosal or infiltrative growth pattern. Routine histology showed that DMH caused focal changes over deposits of lymphoid tissue (Peyer's patches); these changes were hyperplasia, atypicality, and true neoplastic growth. Tumors were macroscopically visible after 21 weeks and appeared more frequently in animals that had had a distal small bowel resection ($2\alpha > 0.1$, Mann-Whitney test, Fig. 5), but statistical significance was not quite reached. Unoperated animals developed tumors in the cecum and the ascending colon, whereas animals with a distal small bowel resection had their tumors distributed more uniformly (Fig. 6). Rats that were operated on also had tumors more varied in size than unoperated animals (Fig. 7). No difference in grade of differentiation was noted (Table 2). One rat with bowel resection and two unoperated rats had metastatic disease. In only one instance was a papilloma of the external ear canal found; this animal had no intestinal tumors. Weight loss before sacrifice was noted only in rats with widespread disease. In all other instances tumors were found without signs of systemic disease.

Discussion

Hyperplasia provoked in colonic mucosa by DMH was further increased by the stimulus of ileal resection. The incidence of colonic tumors appeared to increase because of the added postresectional hyperplasia, although statistical significance was not quite reached because of the limited number of observations and the desire to keep the yield of tumors per animal low.

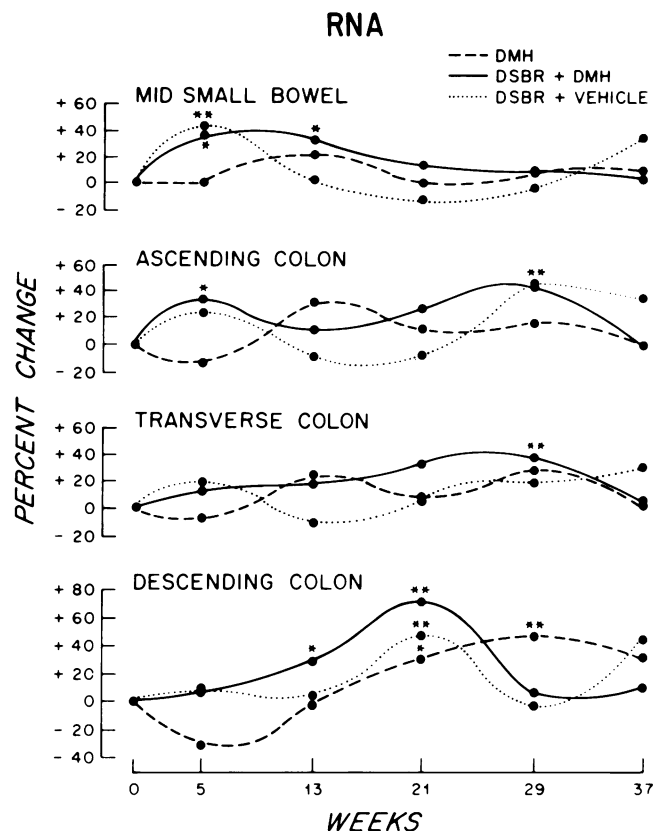


FIG. 4. Total RNA content in 5cm mucosa of the mid small bowel, ascending, transverse, and descending colon. Base line is control (unoperated rats receiving vehicle). Changes presented as deviation in per cent from base line. Significances versus control * $p < 0.05$, ** $p < 0.01$.

Hyperplasia of the small and large bowel mucosa after giving DMH alone agrees with reports of increased cell proliferation in rat and mouse colonic mucosa after treatment with a chemical carcinogen.^{19-21,25} When malignant cells were present, they were often associated with lymphoid tissue²² and areas of focal hyperplasia,^{6,20} but the cell mass of a tumor of hyperplastic lymph follicle does not account for the measured increase in RNA and DNA content since they were excluded from analysis.

TABLE 1. Changes in Mucosal Thickness Produced by Dimethylhydrazine (DMH) (10mg/kg Body Weight, 12 Weekly Injections) After 21 Weeks

	N + Vehicle μm	N + DMH μm	DSBR + Vehicle μm	DSBR + DMH μm
Ascending colon	277 \pm 15.9	218 \pm 14.0	209 \pm 3.4	221 \pm 7.5
Transverse colon	272 \pm 21.0	271 \pm 13.8	291 \pm 19.2	303 \pm 15.1
Descending colon	269 \pm 9.4	260 \pm 7.9	303 \pm 11.5	289 \pm 14.3
Mid-small bowel villous height	326 \pm 8.5	394 \pm 13.0*	551 \pm 28.3**	499 \pm 18.5***
Mid-small bowel crypt depth	168 \pm 6.7	158 \pm 6.0	174 \pm 9.7	181 \pm 16.4

N = unoperated, DSBR = distal small-bowel resection.

* N + DMH > N + vehicle, $p < 0.01$.

** DSBR + vehicle > N + vehicle, $p < 0.001$.

*** DSBR + DMH > N + DMH, $p < 0.001$.

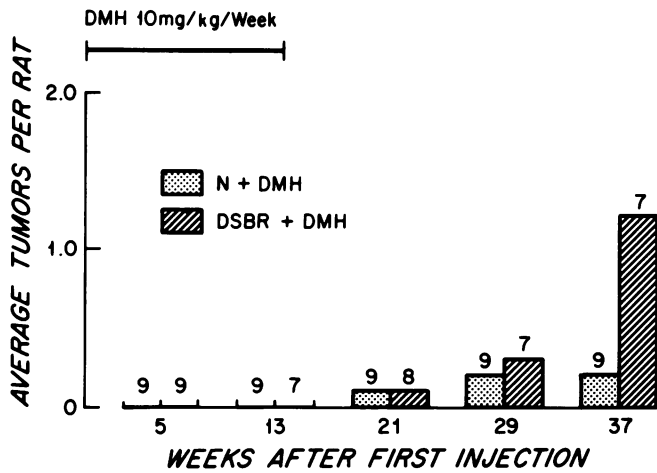


FIG. 5. Frequency of tumors in unoperated rats (N) and those with distal small bowel resections (DSBR) after injection with DMH.

Distal small bowel resection resulted in a rapid response, mainly hyperplasia, in the remaining small and large bowel.¹³ When animals with ileal resections were injected with DMH, compensatory hyperplasia was slower. At five weeks the effect of the two stimuli combined on incorporation of thymidine into DNA of the large bowel was similar to that of resection alone; in the small bowel the postresectional hyperplasia was abolished when DMH was added. The maximal effect of combined ileal resection and DMH on the amounts of RNA and DNA content in colonic mucosa was at 21 weeks. At this time the effect of resection alone was diminishing and that of DMH was maximal, neither one alone having an effect exceeding that of the two combined. DMH injections and distal small bowel resection therefore appeared to augment one another. A similar effect occurs after jejunal resection when azoxymethane is the carcinogen.²⁵ The time of maximal

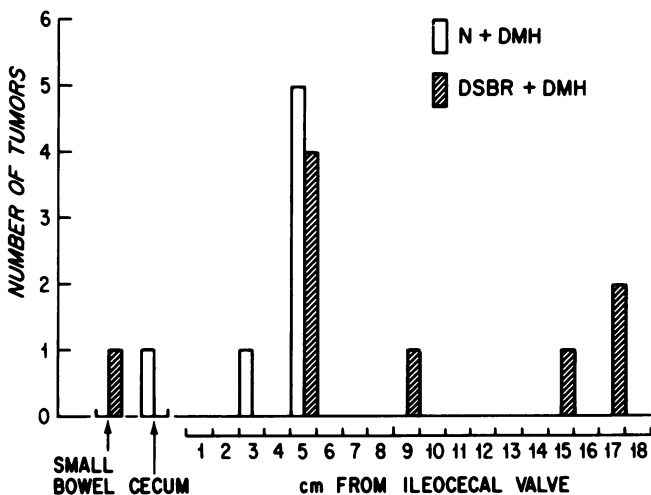


FIG. 6. Distribution of bowel tumors.

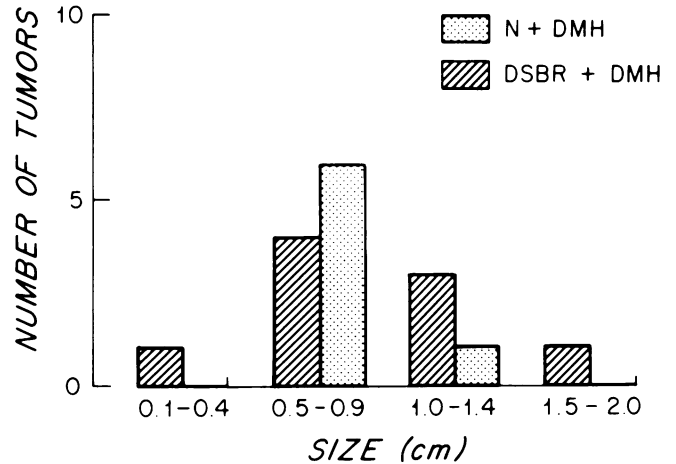


FIG. 7. Size of bowel tumors.

response in nucleic acid content coincides with the expected appearance of macroscopic tumors. This time also corresponds to the initiation stage of the two-stage process for DMH-induced bowel cancer presented by Richards.¹⁷

The design of the present experiment was to achieve a fairly low incidence of large bowel tumors to assure tumor-free mucosa for nucleic acid analysis. Although spontaneous colonic cancers scarcely ever occur in rodents,⁴ after 29 weeks of observation both DMH groups had a similar prevalence of tumors (tumor/animal ratio of 0.2 and 0.3 respectively). For practical reasons also the number of rats had to be limited to less than ten in each group for each time point. At the end of the experiment, eight weeks later, the tumor/animal ratio remained the same in the unoperated group, but was six times higher (1.2) in the group with distal small bowel resection. Multiple tumors were found only in animals with ileal resection. The location of their tumors was throughout the entire colonic mucosa, but unoperated rats had tumors only in the ascending colon. The grade of differentiation was not altered.

By reason of having a shorter small bowel rats with ileal resection could have had less reabsorption of bile.¹² This hypothetical sequence could be argued to increase the excretion of bile, delivering a greater amount of carcinogenic substance to the colonic mucosa.^{23,24} However, in fact, after distal small bowel resection, jejunal absorption of cholate and taurocholate increases with mucosal hyperplasia, and colonic bile absorption remains unchanged.¹⁴ Animals with shortened bowel had no signs of the bile-induced diarrhea seen after extended small bowel resection, and the insusceptibility of the proximal small bowel to induction of tumors with DMH remained. As in the enhancement of colonic carcinogenesis after jejunal resection and azoxymethane treatment,²⁵ the hyperplastic

TABLE 2. Tumors After 12 Weekly Injections of 10mg Dimethylhydrazine (DMH)/kg Body Weight

Type of Tumor	Number	Related to Peyer Patch	Developed by Resected Rat	Grade of Differentiation		
				Well	Moderate	Poorly
Polypoid adenocarcinoma	3	0	3	2	1	0
Tubular adenocarcinoma, pure	6	5	4	2	2	2
Colloid adenocarcinoma, pure	3	2	1	0	0	0
Mixed tubular and colloid adenocarcinoma	3	3	2	0	0	3
Not examined histologically (with metastases)	1	—	1	—	—	—

stimulus of ileal resection seems to act as a colonic co-carcinogenic factor. The likely explanation is that the hyperplastic colonic mucosa after small bowel resection contains more stem cells in the mitotic cycle, which could be at greater risk for malignant transformation.^{1,2,26}

Acknowledgment

We thank Robin C. N. Williamson, M. Chir., F.R.C.S., for criticism.

References

- Campbell, R. L., Sing, D. V. and Nigro, N. D.: Importance of the Fecal Stream on the Induction of Colon Tumors by Azoxymethane in Rats. *Cancer Res.*, 35:1369, 1975.
- Chan, P. C., Cohen, L. A. and Narisawa, T.: Early Effects of a Single Intrarectal Dose of 1,2-Dimethyl-hydrazine in Mice. *Cancer Res.*, 36:13, 1976.
- Deschner, E. E. and Lipkin, M.: Proliferative Patterns in Colonic Mucosa in Familial Polyposis. *Cancer*, 35:413, 1975.
- Druckrey, H.: Organospecific carcinogenesis in the digestive tract. In Nakahara, W., Takayama, S., Sugimura, T. and Odashima, S. (eds.) *Topics in Chemical Carcinogenesis*, Baltimore, University Park Press, 1972. p. 73.
- Farmer, R. G., Hawk, W. A. and Turnbull, R. B., Jr.: Carcinoma Associated with Mucosal Ulcerative Colitis and with Transmural Colitis and Enteritis (Crohn's Disease). *Cancer*, 28:289, 1971.
- Garbutt, J. T., Lack, L. and Tyor, M. P.: The Enterohepatic Circulation of Bile Salts in Gastrointestinal Disorders. *Am. J. Med.*, 51:627, 1971.
- Hinrichs, H. R., Petersen, R. P. and Baserga, R.: Incorporation of Thymidine into DNA of Mouse Organs. *Arch. Pathol.*, 78:245, 1964.
- Lipkin, M., Deschner, E. E. and Troncale, F.: Cell Differentiation and the Development of Colonic Neoplasms. *Gastroenterology*, 59:303, 1970.
- Lipkin, M.: Proliferative Changes in the Colon. *Am. J. Dig. Dis.*, 19:1029, 1974.
- Maskens, A. P.: Histogenesis and Growth Pattern of 1,2-Dimethylhydrazine-induced Rat Colon Adenocarcinoma. *Cancer Res.*, 36:1585, 1976.
- Morson, B. C.: Cancer in Ulcerative Colitis. *Gut*, 7:425, 1966.
- Nigro, N. D., Bhadrachari, N. and Chomchai, C. A.: A Rat Model for Studying Colonic Cancer. *Dis. Colon Rectum*, 16:438, 1973.
- Nundy, S., Malamud, D., Obertop, H., et al.: Onset of Cell Proliferation in the Shortened Gut: Colonic Hyperplasia after Ileal Resection. *Gastroenterology*, 72:263, 1977.
- Perry, P. M., Mok, H. Y. I. and Dowling, R. H.: Bile acid absorption after small bowel resection in the rat. In Dowling, R. H. and Riecken, E. O. (eds.) *Intestinal Adaptation*. Stuttgart F. K. Schattauer Verlag, 1974. p. 47.
- Pozharisski, K. M.: The Significance of Nonspecific Injury for Colon Carcinogenesis in the Rat. *Cancer Res.*, 35:3824, 1975.
- Reddy, B. S., Narisawa, T., Maronpot, R., et al.: Animal Model for the Study of Dietary Factors and Cancer of the Large Bowel. *Cancer Res.*, 35:3421, 1975.
- Richards, T. C.: Early Changes in the Dynamics of Crypt Cell Population in Mouse Colon Following Administration of 1,2-Dimethylhydrazine. *Cancer Res.*, 37:1680, 1977.
- Scott, J. F., Fraccastoro, R. P. and Taft, E. B., Jr.: Studies in Histochemistry: I. Determination of Nucleic Acids in Microgram Amounts of Tissue. *J. Histochem. Cytochem.*, 4:1, 1956.
- Springer, P., Springer, J. and Dehlert, W.: Die Vorstufen des 1,2-Dimethylhydrazin-induzierten Dick- und Dunndarmkarzinoms der Ratte. *Z. Krebsforsch.*, 74:236, 1970.
- Thurnherr, N., Deschner, E. E., Stonehill, E. H., et al.: Induction of Adenocarcinomas of the Colon in Mice by Weekly Injections of 1,2-Dimethylhydrazine. *Cancer Res.*, 33:940, 1973.
- Tutton, P. J. M. and Barkla, D. H.: Cell Proliferation in the Descending Colon of Dimethyl-hydrazine Treated Rats and in Dimethyl-hydrazine Induced Adenocarcinoma. *Virchows Arch. B Cell. Pathol.*, 21:147, 1976.
- Ward, J. M.: Morphogenesis of Chemically Induced Neoplasms of the Colon and Small Intestine in Rats. *Lab. Invest.*, 30:505, 1974.
- Weisburger, J. H.: Colon Carcinogens: Their Metabolism and Mode of Action. *Cancer*, 28:60, 1971.
- Weisburger, J. H.: Chemical Carcinogens and Their Mode of Action in Colonic Neoplasia. *Dis. Colon Rectum*, 16:431, 1973.
- Williamson, R. C. N., Bauer, F. L. R., Oscarson, J. E. A., et al.: Promotion of Azoxymethane-induced Colonic Neoplasia by Resection of the Proximal Small Bowel. *Cancer Res.*, 38:3212, 1978.
- Wittig, G., Wildner, G. P. and Ziebarth, D.: Der Einfluss der Ingesta auf Kanzerisierung des Rattendarms durch Dimethylhydrazin. *Arch. Geschwulstforsch.*, 37:105, 1971.