

# Non-Surgical Removal of Retained Common Duct Stones:

## Case Report

ROBERT P. MCBURNEY,\* M.D., H. COLBY GARDNER,\*\* M.D.

*From the Department of Surgery, Baptist Memorial Hospital, Memphis, Tennessee*

OPERATIVE cholangiography has greatly reduced the incidence of retained common duct stones but in practice, as the following case illustrates, this may occur even when operative cholangiograms are done.

When a diagnosis of retained common duct stones is made, immediate reoperation may not be advisable because of the risk

of a second procedure. The T-tube may be irrigated in the hope that the stone will pass through the ampulla of Vater. "Dissolving" solutions such as ether, paraffin and chloroform has been reported to be effective but are not widely used or considered reliable.

Lamis, Wilson and Letton<sup>1</sup> recently described a variation of the irrigation technic which holds promise and reported cases in which the common duct was cleared of

---

Submitted for publication February 26, 1970.

\* Department of Surgery.

\*\* Department of Radiology.

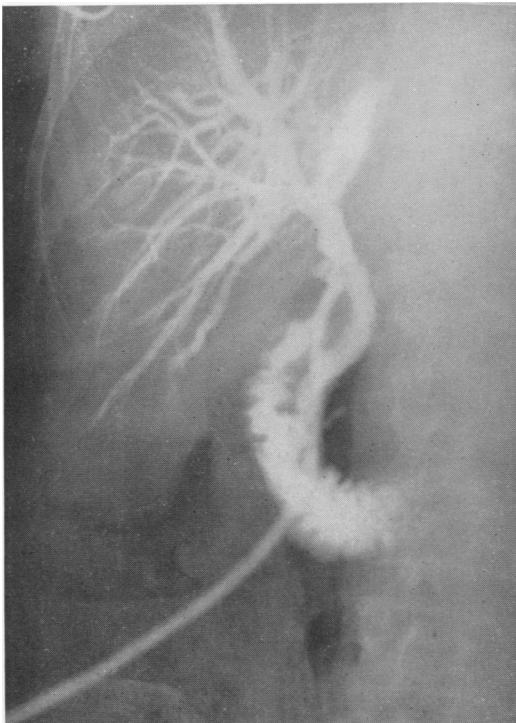


FIG. 1. Operative cholangiogram interpreted as showing a clear common duct.

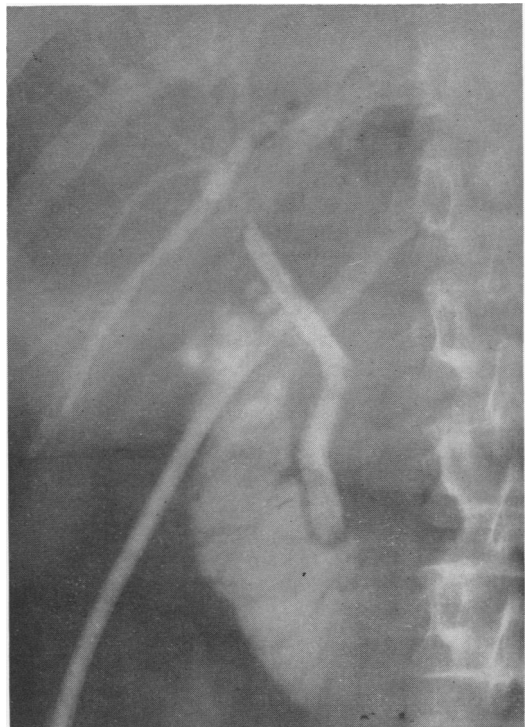


FIG. 2. Postoperative cholangiogram shows two radiolucent defects.

stones by catheterization of the duct under the x-ray image intensifier with irrigation and dilatation of the ampulla. This report prompted the technic used and success in the following case.

### Case Report

A. T. A 60-year-old woman, was seen on November 5, 1969. She had intermittent abdominal pain and jaundice of almost 1 years' duration. Cholecystectomy for chronic cholecystitis with stones had been performed 5 years previously.

She was well developed, well nourished and had mild jaundice. There was a right upper quadrant abdominal scar. Laboratory and x-ray studies confirmed the diagnosis of obstructive jaundice and operation was advised.

At operation on November 10, 1969, a small portion of residual gallbladder containing stones was excised and the common duct was opened and one 5 mm. stone was removed. Operative cholangiogram was interpreted as showing no further stones (Fig. 1).

Recovery was uneventful but the day prior to dismissal a cholangiogram showed two definite retained common duct stones (Fig. 2).

The patient was dismissed from the hospital with instructions to drain the common duct daily and return in 4 weeks for further treatment.

She returned on December 15, 1969, and cholangiogram again confirmed the presence of the stones.

The following day in the x-ray department, under light general anesthesia the T-tube was removed and a #16 French rubber catheter with the tip cut off was inserted down the tract into the common duct. Under image intensification this was visualized and a small amount of radio opaque media was injected and showed the duct and stones adequately. The catheter was then maneuvered to close proximity with the stone and

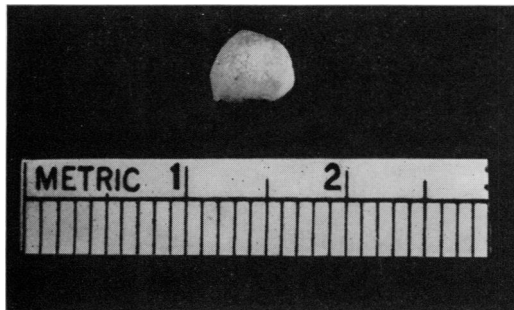


FIG. 3. Common duct stone removed by catheter suction technic.

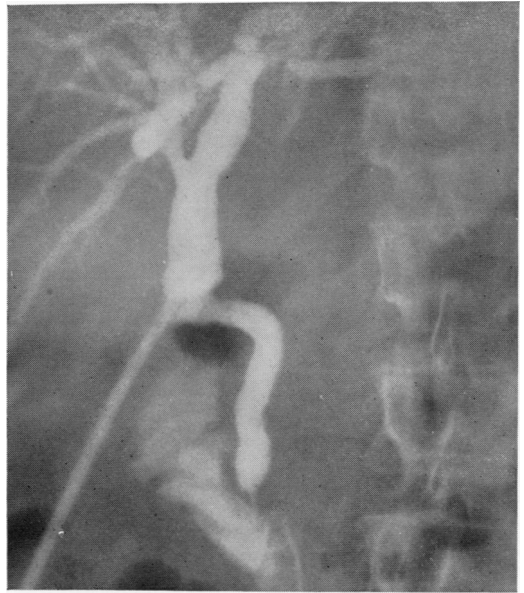


FIG. 4. Cholangiogram shows clear common duct after removal of one stone and irrigation.

with the stone against the tip of the catheter, suction was applied and the catheter along with the stone was removed (Fig. 3).

An attempt was then made to repeat the procedure and remove the second stone. After passing the catheter through the ampulla and irrigat-

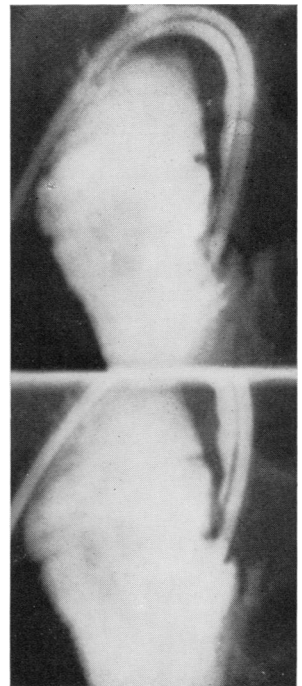


FIG. 5. (top) Catheter passed into lower common duct down to the ampulla. (bottom) Catheter passed through the ampulla into the duodenum.

ing the common duct and ampullary region the second stone could no longer be seen.

The catheter was left in the distal common duct and the procedure terminated. The following day cholangiogram (Fig. 4) confirmed that the duct was clear whereupon the catheter was withdrawn and the patient was dismissed.

She has had no further trouble.

### Discussion

It is easy to pass a catheter and perhaps other instruments into the common duct after a tract is formed and stones can be removed by a technic of sucking them to the lumen of a catheter in a way such as used in this instance. Most retained common duct stones are small and could theoretically be drawn through the tract of a T-tube.

Hepatic ducts, common duct and ampulla can be selectively studied with the technic of duct catheterization.

One technical aid in passage of the catheter should be mentioned. In our case the catheter passed into the upper common duct when it was pushed. To get it into the lower common duct an arteriographic catheter (7.5 French) over a flexible guide wire which had a preformed curve at its tip was passed. The wire was withdrawn, the preformed tip was directed distally into the lower common duct. The rubber #16 catheter was then passed over the arteriographic catheter and the arteriographic catheter withdrawn. By either advancing

or withdrawing the guide wire from the catheter tip the advancing distal end may be curved variously into divisions of biliary radicals. This can also be accomplished by available catheter guide systems, and the technics of arteriography can be applied to the biliary system (Fig. 5).

Lamis and associates<sup>1</sup> credit the idea of passage of catheters down the T-tube tract to Dr. Alvero Caro, Professor of Surgery at Bogota, Colombia. Their report plus this case convinces us that the idea has merit and no doubt further variations will be tried.

### Summary

Retained common duct stones are a problem which often requires a second operation. A non-operative procedure which resulted in removal of a retained common duct stone is reported. The technic is that of passage of a catheter into the common duct via the tract of a T-tube. Under image intensification the tip of the catheter was placed next to the stone and suction was applied to the catheter. The stone became attached to the catheter tip and the catheter with the stone was withdrawn.

### Reference

1. Lamis, P. A., Letton, A. H. and Wilson, J. P.: Retained Common Duct Stones: A New Non-operative Technique for Treatment. *Surgery*, 66:291, 1969.