

CYSTIC LYMPHANGIOMA OF THE GREATER OMENTUM

By PHILIP M. GRAUSMAN, M.D.

AND

HENRY L. JAFFE, M.D.

OF NEW YORK, N. Y.

OF THE cystic lymph tumors of the abdominal cavity those of the greater omentum occur least frequently. Wegner's paper in 1874 was the first comprehensive discussion of lymph-vessel tumors. While there is a large literature concerning this class of tumor in general, cystic lymphangioma of the greater omentum has been only briefly discussed, except in the few special papers on the subject.

Spencer-Wells,¹ in 1890, described a large cystic tumor of the omentum in a child. Schwartzenger² described a case of recurrent ascites of two years' duration in a child four and one-half years of age. At operation a large solitary cyst, filled with yellow fluid and lined by endothelium, was found hanging from the omentum by several pedicles. Outerbridge³ while operating on a thirty-four-year-old woman for a uterine fibroid found the greater omentum adherent to the uterus and numerous cysts in the region of attachment. These he interpreted as lymph cysts due to inflammatory occlusion of the lymph vessels. Minervini⁴ also described a case of lymphangioma of the abdominal peritoneum and greater omentum which after five years caused death from exhaustion. Stillman⁵ removed a cystic tumor of the greater omentum, many of the cysts being as large as 6 cm. in diameter, in a case which he had observed clinically for years. Borchers⁶ described a case of progressive enlargement of the abdomen in a four-year-old child caused by a huge cystic tumor of the greater omentum. Kahuschkin's⁷ case presented cysts of the omentum, which he interpreted as cystic lymphangioma. At the autopsy of a fifty-year-old man, Henke⁸ found a cystic peritoneum and omentum. He diagnosed the condition as lymphangioma but Merkel considered it pseudomyxoma peritonei. Karas⁹ found a multicystic tumor of the right half of the omentum at the autopsy of a thirty-eight-year-old woman. He believed that the cysts were embryonal in origin and were developed from misplaced peritoneal cells. Himmelheber and Kirchberg¹⁰ described a case of multiple cysts of the peritoneum in a fifty-one-year-old woman. The cysts were most numerous in the greater omentum, and the lesion was interpreted as either a lymphangioma or a lymphangio-ectasia.

We recently observed a cystic tumor of the greater omentum in a man forty-four years old. His illness dated back for a few months before admission to the hospital on March 29, 1926. The chief complaint during this time was pain in the left lower quadrant of the abdomen and some rather indefinite symptoms referable to the gastrointestinal tract. The physical examination on admission to the hospital was negative except for diffuse tenderness throughout the abdomen, particularly in the lower quadrants. The temperature was 98.4° F. The white blood-cell count was 14,000 with 86 per cent. polymorphonuclear leucocytes, 11 per cent. lymphocytes, 1 per cent. transitionals and 2 per cent. eosinophiles. There were 4,512,000 red blood-cells. The urine examination was negative.

At operation a large cystic mass was found attached to the under surface of the liver and the intestines. This mass was apparently the greater omentum. It was dissected as completely as possible from its attachments. The viscera and the rest of the peritoneum were apparently negative.

Pathology.—*Gross.*—The tumor was removed in several pieces. There were two

CYSTIC LYMPHANGIOMA OF THE GREATER OMENTUM

large cystic masses, one measuring 6 by 7 by 2 cm.; the other mass was irregular and measured 9 by 8 cm. and up to 3 cm. in thickness. In addition there were several pieces of rather nodular, firm and fatty omentum, and several smaller multicystic masses which had evidently been removed separately but which undoubtedly had been connected with the main tumor tissue.

The smaller of the two main tumor masses was very cystic, and only a small amount

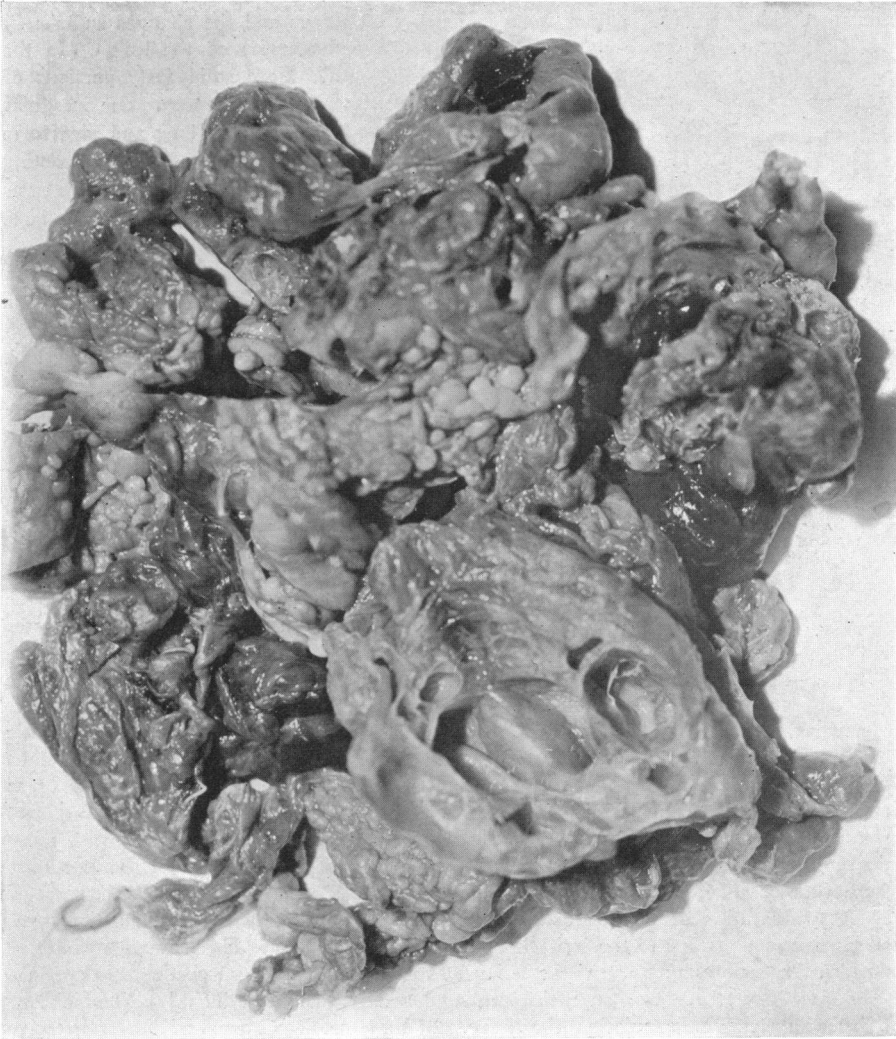

FIG. 1.—Showing most of the tumor mass with several of the larger and smaller cysts exposed.

of fat remained on one surface which enabled one to identify it as greater omentum. When this tumor was sectioned liberally, it was found to consist of hundreds of single and communicating cysts which measured from 1 mm. to 2 cm. in diameter. The cyst wall linings were smooth and the walls for the most part were less than 1 mm. thick. The cysts were filled with a thick jelly-like material. In the more solid portions of the tissue many tiny spaces were seen which on pressure oozed fluid and gave the gross impression of a soft lymphangiomatous tumor so often seen in the skin.

The larger tumor mass contained much more fat and was therefore easily identified as coming from the greater omentum. On section it showed many large and small cysts. Between the cysts there was a firmer, whitish, oedematous tissue. In this portion of the cystic omentum the larger cysts were more widely separated and their walls somewhat thicker. Several representative areas of the tumor were taken for section. (See Fig. 1.)

Microscopic.—The histological picture varied considerably in the different sections examined. However the sections were sufficiently numerous and the changes sufficiently graded to permit an interpretation of the probable pathogenesis of the lesion. In the

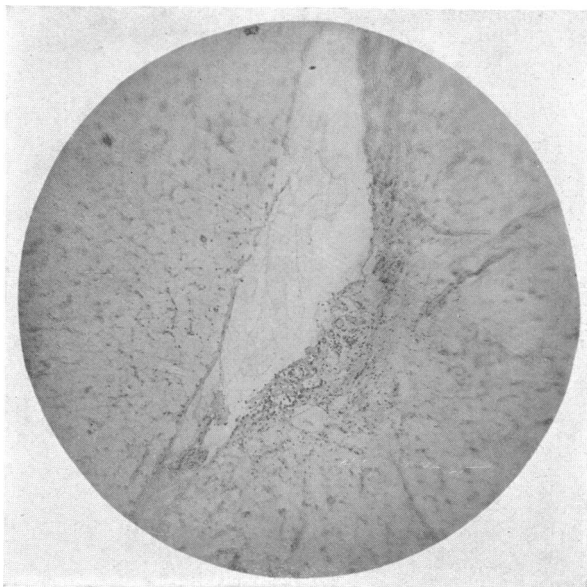


FIG. 2.—A widely dilated preformed lymphatic vessel in the omental fat.

more solid fatty portions of the omentum an irregular branching and plexiform dilatation of the preëxisting interlobular lymphatics was the predominating lesion. Some of these lymphatic spaces were empty, while others were filled with a pink-staining, granular, practically acellular material. Flattened endothelium lined these lymph spaces, though in some places there was hypertrophy and piling up of these cells two or three layers deep. At the intersections of these dilated lymph spaces processes were seen extending into the lumens. These processes were covered by endothelium, beneath which there was a connective tissue

framework, containing blood-vessels. At such intersections many new lymphatic vessels were also seen. These channels were plexiform, rather narrow, and lined by hyperplastic endothelium, one to four cells thick. Some lymphocytes were seen in the supporting stroma between the channels, which was rather oedematous and contained in addition many leucocytes. Other sections of this tissue showed more intense leucocytic infiltration with granulation tissue on the surface of the omentum where it was adherent to the surrounding tissues. These changes were interpreted as due to dilatation of the preformed lymphatics with secondary proliferative changes and tissue reactions due to the irritation of mild pressure. (See Figs. 2 and 3.) Tissue in which the tumorous nature of the lesion was apparent was found particularly between the cysts. Here there was an undifferentiated mesenchyme in which lymphangioblasts produced in places a granulation-like tissue. In these sections stages of the progressive enlargement and growth of the newly formed lymphatics produced in the granulation tissue were also seen. In addition the tissue showed diffuse leucocytic and lymphocytic infiltration. (See Figs. 4, 5, and 6.)

The large cysts were seen in a stroma of loose connective tissue. In the sections most of the cysts were empty while some contained a pink-staining granular material. The larger cysts which measured many low power fields in diameter were lined by flattened endothelium. Both sides of the dividing septa were covered by such endothelium supported by a connective-tissue layer. In the smaller cysts the lining endothelium was either hypertrophied or several cells thick. In some of the cysts there was evidence

CYSTIC LYMPHANGIOMA OF THE GREATER OMENTUM

FIG. 3.—Numerous communicating and branching preformed lymphatics with hypertrophied endothelium.

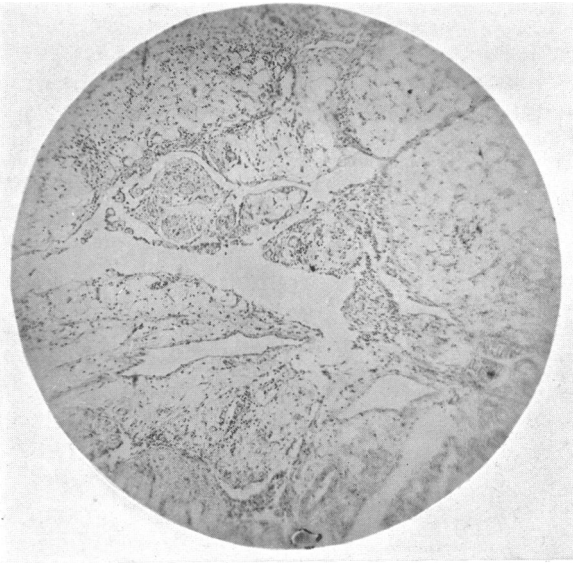
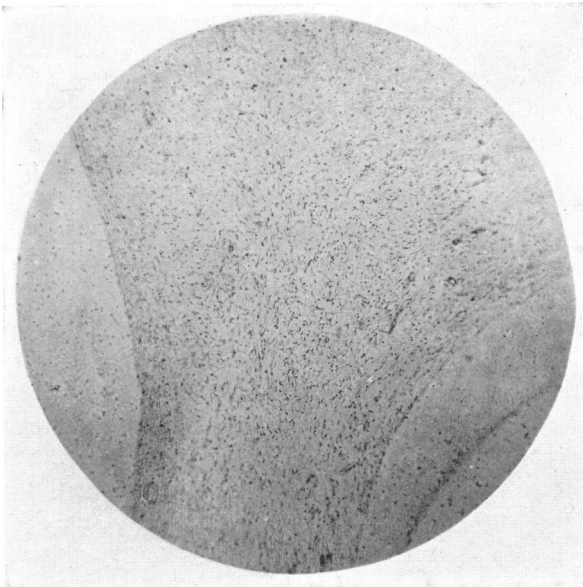


FIG. 4.—Undifferentiated mesenchyme between some larger cysts.



of proliferation with the projection of papillary processes into the lumens. (See Figs. 7 and 8.)

Summarizing the pathological findings, the material removed at operation consisted of most of the greater omentum with very little fatty tissue remaining. There were many small and large cysts. Between these cysts the tissue was either soft, containing many tiny spaces and appearing like the rather soft lymphangiomas of the skin, or the intercystic tissue was somewhat firmer and cedematous. The histological examination of this last tissue disclosed

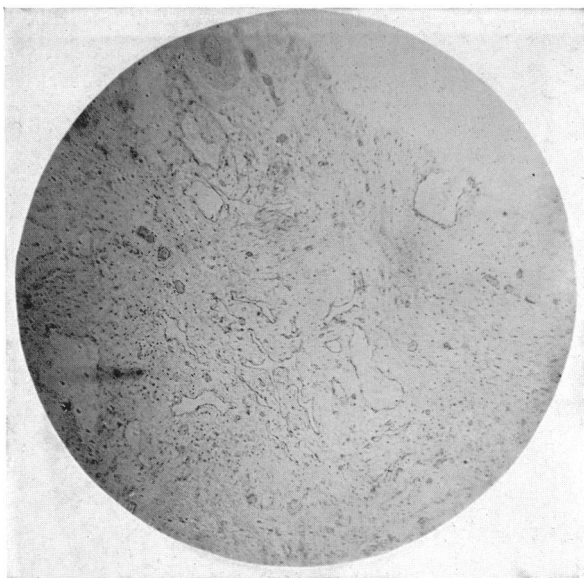


FIG. 5.—The formation of branching lymph vessels in the undifferentiated mesenchyme.

a marked development of new lymphatic channels from what appeared to be a rather indifferent mesenchymal tissue. From these microscopical channels definite stages of lymph channel enlargement were traced. As these channels enlarged, evidences of hypertrophy and hyperplasia of the lining endothelium were recognizable. Where the cysts became very large, the lining endothelium either became flattened or entirely lost. Just beneath the endothelial lining,

particularly of the smaller and medium-sized cysts, diffuse lymphoid infiltration was seen producing definite lymph follicles in some places. The preformed lymph vessels of the greater omentum were also dilated, due to obstruction of the efferent channels.

Discussion.—We believe that this case is one of a true tumor of the lymphatics of the greater omentum with certain secondary and obstructive changes that led to its final multicystic form. Although tumors of the lymphatics are divided into simple, cavernous and cystic lymphangiomas, according to their gross and microscopical appearance, genetically they have a common origin. The pathological divisions are not very sharp, for there may be transitions from one group to another. The consensus of opinion at present is that all these angiomas are true tumors of the lymphatic vessels, though some features may be attributed to stasis.

Simple lymphangiomas arise from the lymph spaces and lymph vessels and as a rule they are arranged in an anastomotic network. Cavernous lymphangiomas consist of a framework of connective tissue supporting numerous single and communicating grossly visible cysts filled with lymph.

CYSTIC LYMPHANGIOMA OF THE GREATER OMENTUM

Fig. 6.—Showing the progressive dilatation of the newly formed lymphatic channels.

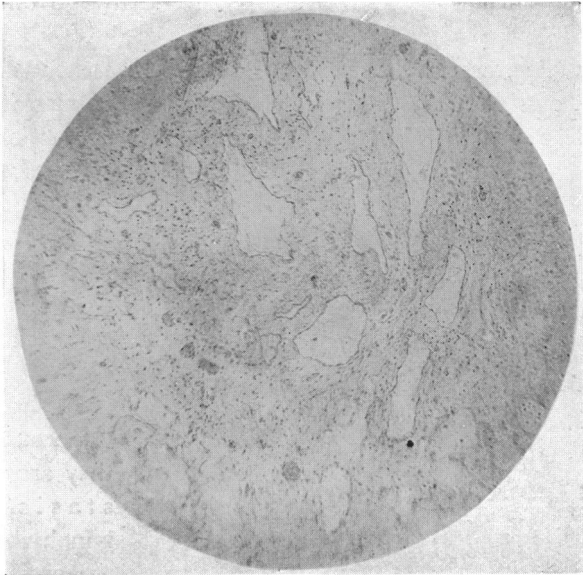
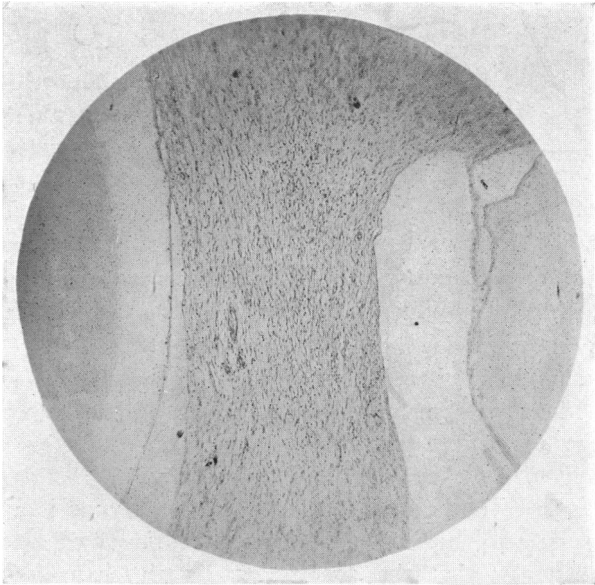


Fig. 7.—A large cyst lined by flattened endothelium.



Under cystic lymphangioma are collected those tumors with a great number of thin-walled convoluted cysts which are filled with lymph or lymph-like fluid, and which are bound together by connective tissue. This stroma contains many smaller spaces which may eventually go on to large cavity formation.

Workers like Nasse,¹¹ Ribbert,¹² Sick¹³ and Henschen¹⁴ have interpreted the origin of cystic omental tumors from embryonally misplaced nests, potentially capable of producing lymph channels, or from post-natally developed

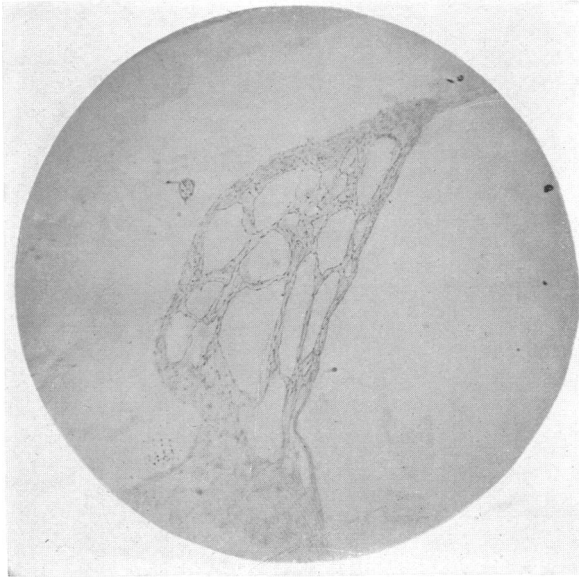

FIG. 8.—Two large cysts with numerous smaller cysts in the connective tissue between them.

connective tissue also having such potentialities. Others have contended that cystic lesions of the omentum, like cystic lesions in other portions of the abdominal cavity, were not tumorous, believing that they arose as a result of stasis of the efferent lymph channels, and that the proliferative changes were due to the irritative effects of the early results of pressure. In support of this contention Wegner's original experiments are usually quoted in which he filled

the abdominal cavity with air and continued the increased abdominal pressure for some time. The air entered the subperitoneal lymphatics and the lymphatics of the greater omentum, leading to obstruction of the draining vessels with the consequent production of large cysts with proliferative changes in the walls.

On the other hand, Langhans and Ribbert have denied the participation of stasis in the development of these tumors, though others like Borst,¹⁵ Sick and Borchers believe that stasis plays an important but secondary rôle, and leads only to the enlargement of the tumor.

On the basis of our case we believe that the tumor is a true blastoma; that it arises from a mesenchymal connective tissue capable of producing lymphatic channels; that the preëxisting lymph channels of the greater omentum are not involved in the true tumorous proliferation; that if these channels are involved and become cystic, it is due to the obstruction of their lymph flow and that if proliferative changes do occur in their walls, they are due to this obstruction. Many of the new-formed tumorous lymph chan-

CYSTIC LYMPHANGIOMA OF THE GREATER OMENTUM

nels become obstructed and dilated, though it is conceivable that many, because of their tumorous nature, are blind and become cystic on this account. It is our opinion that while stasis does occur in these growths, it is secondary to the real tumorous nature.

The fluid of these cysts varies in color from water clear to dark brown, and may be of a thin watery to a thick pasty consistency. It is alkaline in reaction, and coagulates on boiling because of its high globulin and albumin content. The sediment shows fatty endothelial cells and cholesterol crystals, though Gödel¹⁶ described the presence of many lymphocytes. No mucin is present in the fluid. The chylous cysts contain a milky fluid which Henschen showed had much in common with chyle on chemical analysis. Undoubtedly lymph seems to be of primary importance in the formation of the fluid content of these cysts, and variations of the cyst fluid from normal lymph are due to factors such as filtration, diffusion, secretory activity of the cyst wall endothelium and degeneration.

This report deals with endothelial lined cysts and excludes all epithelial lined cysts of the greater omentum which may result from embryonic inclusions.

CONCLUSIONS

Another case of cystic lymph tumor of the greater omentum is added to the small number of cases already recorded in the literature. We believe that cystic lymphangiomas are true blastomas arising in the greater omentum from undifferentiated mesenchyme which is capable of producing lymphatic vessels by proliferation of lymphangioblasts. Many of these newly formed lymphatic vessels become enlarged and cystic, due to the blocking of the outlets and possibly because they are blind vessels. Some of the original lymphatic vessels are also obstructed and show secondary changes such as dilatation and proliferation of the endothelium. We believe that the preformed lymphatics are not involved in the tumor growth.

BIBLIOGRAPHY

- ¹ Spencer-Wells: *Brit. M. J.*, 1890, vol. i, p. 1361.
- ² Schwartzberger, B.: *Beitr. z. klin. Chir.*, 1894, vol. xi, p. 713.
- ³ Outerbridge: *Proc. Soc., Phila.*, 1914, vol. xvi, p. 75.
- ⁴ Minervini: Quoted by Borchers.
- ⁵ Stillman, S.: *J. A. M. A.*, 1911, vol. lvii, p. 726.
- ⁶ Borchers, E.: *Beitr. z. klin. Chir.*, 1920, vol. cxviii, p. 710.
- ⁷ Kahuschkin, N. M.: *Zentralbl. f. Chir.*, 1908, vol. xxxv, p. 247.
- ⁸ Henke, F.: *Verh. d. Deutsch. path. Gesellsch.*, 1899, p. 251.
- ⁹ Karas, H.: *Virch. Arch.*, 1907, vol. clxxxviii, p. 138.
- ¹⁰ Himmelheber, K.: *Arch. f. Gyn.*, 1909, p. 67.
Kirchberg, P.: *Frankf. Ztschr. f. Path.*, 1912, vol. x, p. 290.
- ¹¹ Nasse, D.: *Arch. f. klin. Chir.*, 1889, vol. xxxviii, p. 614.
- ¹² Ribbert: *Virch. Arch.*, 1898, vol. cli, p. 381.
- ¹³ Sick, C.: *Virch. Arch.*, 1902, vol. clxx, p. 9; 1903, vol. clxxii, p. 445.
- ¹⁴ Henschen, K.: *Beiträge zur Geschwulstpathologie des Chylusgefäßsystems*. Zürich, 1905.
- ¹⁵ Borst, M.: *Die Lehre von den Geschwülsten*. J. B. Bergmann, Weisb., 1902.
- ¹⁶ Gödel, A.: *Frankf. Ztschr. f. Path.*, 1922, vol. xxvi, p. 564.