

# LYMPHOID HYPERPLASIA OF LACRYMAL AND SALIVARY GLANDS

MIKULICZ' DISEASE

By JOSEPH F. SMITH, M.D.

OF WAUSAU, WIS.

AND

WARNER S. BUMP, M.D.

OF CHICAGO, ILL.

FROM THE SURGICAL SERVICE OF ST. MARY'S HOSPITAL, WAUSAU, WISCONSIN, AND THE HENRY BAIRD FAVILL LABORATORY, ST. LUKE'S HOSPITAL, CHICAGO, ILLINOIS

IN 1888,<sup>1</sup> Mikulicz described a symmetrical enlargement of the lacrymal and salivary glands, the glandular tissue of which had been almost entirely replaced by lymphoid tissue. This process, however, apparently was not a part of a generalized disease of lymphoid tissue. Since that time, there have been reported about 100 instances of similar symmetrical enlargement of these glands without alteration of the blood, without generalized enlargement of the lymph-nodes, without splenic enlargement, and without apparent systemic disease.

In view of the relatively infrequent occurrence of the so-called Mikulicz' disease, it seems quite worth-while to report another, especially since the changes in the tissues were not recognized, at first, as those of Mikulicz' disease and were confused with carcinoma.

CASE HISTORY.—Mrs. G. L., age sixty-two years, a housewife, entered St. Mary's Hospital, Wausau, Wisconsin, August 4, 1924, complaining of swellings in front of and below the ears and of periodic dryness of the mouth.

The trouble began one year before with a sudden pain in front of the right ear, which came on while eating, and was followed by the appearance of a nodule, the size of a walnut, below the right ear. This nodule decreased in size several times; but finally became progressively larger, especially during the four months before entering the hospital. In the meantime, swellings had appeared in front of and below the left ear.

She had been married for ten years with no pregnancies. She had had scarlet fever and diphtheria in early childhood. Some difficulty in swallowing remained after the latter disease. She always had been troubled with frequent attacks of tonsillitis.

*Physical Examination.*—The patient is a rather obese, white woman with gray hair. She is mentally alert and physically active.

There is a flattened, dense, fairly well circumscribed swelling, about the size of a lemon, in front of the right ear. This mass extends caudad, forming a second portion below the right ear. There is a similar mass, the size of a pigeon-egg, in the region of the left parotid gland, and a discrete, movable nodule in the left, anterior triangle of the neck.

Swallowing and tracheal movements are free. No enlarged lymph-nodes are found and the spleen is not felt. The heart is enlarged to the left, but there is no definite murmur. The pupils, optic fundii, knee jerks, and superficial reflexes are normal. The temperature is 98.2 degrees F., the pulse rate 76 per minute, and the respiratory rate 18.

The blood has 98 per cent. hæmoglobin; 4,780,000 erythrocytes per cubic mm., and 7,000 leukocytes. In skiagrams of the chest the shadow of the heart extends almost to the left border of the thorax; and both hilus-shadows are a little denser than normal. The Wassermann reaction (blood) is negative.

*Operation.*—On August 5, 1924, a red, encapsulated mass was removed from the region of the left submaxillary gland (J. F. S.). The operation was followed by X-ray therapy with recession of the masses. However, in the spring of 1925 the mass on the left side reappeared, but this time was not affected by exposure to X-rays. Nevertheless, the patient felt well and had gained nine pounds in weight.

November 9, 1925, the left parotid gland and the dense, adherent, associated mass of tissue were removed (J.F.S.).

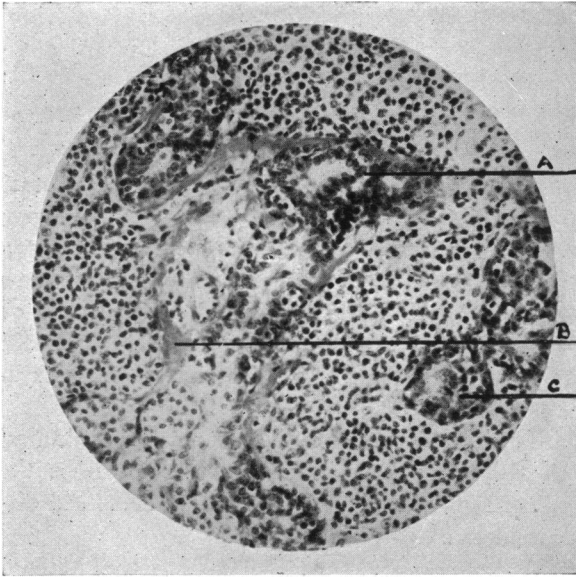


FIG. 1.—Photomicrograph of section of the left submaxillary gland. A. Duct-like epithelial structure. B. Collagen. C. Duct with its normal structure destroyed by ingrowth of lymphoid tissue. (x275.)

cent. small lymphocytes, 19 per cent. large lymphocytes, 4 per cent. large mononuclears, and 2 per cent. eosinophils.

Tissue, removed at the first operation, was considered to be a lymph gland with metastases of an epithelial growth, which in places had a duct-like appearance. Changes in the tissue, removed at a later operation, suggested to the same observer an embryonal carcinoma, possibly from the remains of a branchial cleft.

At the suggestion of Dr. E. R. LeCount, who also examined the tissue and recognized it as the disease Mikulicz described, a more detailed study of the tissue was made by one of us (W. S. B.).

Sections of the tissue, removed at the first operation, consist of lobules of rather closely packed cells, resembling lymphocytes, distributed in which are many, variously shaped, well demarcated islands of cells (Figs. 1 and 2). Throughout the tissue, and especially about many of the cell-islands, there is considerable connective tissue which in places is rich in fibroblasts and in others consists mainly of collagen (Fig. 1,B). Here and there is distributed a moderate number of eosinophil leukocytes. Giant cells with large, clear nuclei are present but very scarce. There are some cells, somewhat larger than lymphocytes, with more basophilic cytoplasm and with the chromatin arranged as

Later, nodules appeared below and in front of the right ear and the mass in front of the left ear reappeared. The glandular tissue on both sides was removed by the method of Adson, July 18, 1926 (J. F. S.). The face remained symmetrical, except for a slight drooping of the upper lip, apparent only upon whistling.

May 9, 1927, the patient felt and appeared well. The erythrocyte count was 5,080,000 per cubic mm., the leukocyte count 7,500, and the hæmoglobin content 85 per cent. In smears of the blood there was no abnormal variation in the size, shape, or staining of the erythrocytes. Sixty-six per cent. of the leukocytes were polymorphonuclear neutrophils, 7 per

## HYPERPLASIA OF LACRYMAL AND SALIVARY GLANDS

in plasma cells. In some sections, apparently cut from the periphery of the gland, there is considerable fat. Here are a few normal ducts with normal gland-acini.

The cell-islands, which are the outstanding structures in the sections, vary in shape from almost circular to branched forms (Figs. 1 and 2). In some places their structure approximates that of normal ducts; that is, there is a definite lumen, lined by columnar cells with pale, oval nuclei (Fig. 1,A). However, for the most part their structure is in varying degrees altered by the growth of the lymphocytes and connective tissue between the cells and into the lumens (Figs. 1,C and 2). In many places the epithelial cells have undergone metaplasia, becoming squamous in type, as though from crowding by the lymphoid tissue (Fig. 2,A). In some islands there is proliferation of the epithelial cells, while in others there is little left, but masses of lymphoid tissue demarcated by connective tissue (Fig. 2).

Three neighboring cell-islands, chosen at random, were followed through thirty-eight serial sections. A wax model, constructed to scale from outline drawings of these islands, demonstrates branching, like in an orderly duct-system (Fig. 3) and therefore, establishes beyond doubt that these structures are the remains of the duct-system of the gland, which was more resistant to the destructive process than the acini.

In a more detailed report of his patient in 1892<sup>2</sup> Mikulicz stated that the submaxillary glands were the size of a

child's fist. They had lobes and lobules, like normal glands, but surfaces, made by sectioning, were pale, red-yellow, speckled with more translucent places, instead of being normally finely granular and gray-red. The substance of the gland was lardaceous and was seemingly without blood-vessels. The tissue consisted of uniformly arranged round cells, in some places thickly packed and in others with a fine reticulum. Certain larger cells had mitotic figures. Imbedded in this mass of round cells were a few acini, considerably separated.

In the glands which Tietze<sup>3</sup> examined no glandular tissue remained. Everywhere was lymphoid tissue with giant cells, atypical round cells, and many eosinophil leukocytes. He noted an over-growth of the capillary endothelium.

Stower<sup>4</sup> found chronic inflammatory changes in the glands with round cell-infiltration, giant cells, occasional eosinophil leukocytes, a few epithelioid cells, and disappearance of the normal gland-structure.

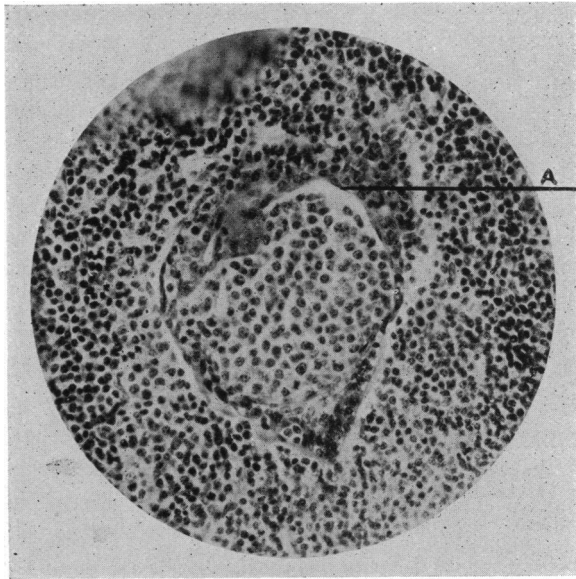


FIG. 2.—Photomicrograph of section of left submaxillary gland with a duct markedly altered by the growth of lymphoid tissue. A. Squamous epithelial cells. (x300.)

Bass<sup>5</sup> noted an increase in the connective tissue, which was infiltrated with small round cells and plasma cells.

Kummel<sup>6</sup> described substitution of the glands by lymphoid tissue with eosinophil leukocytes and giant cells.

The process was interpreted by Minelli<sup>7</sup> as a marked proliferation of the lymph cells already in the gland with gradual replacement by connective tissue and with mechanical destruction of the original glandular tissue. The latter

process, he thought, gave rise to cysts, foreign body giant cells, and eosinophil leukocytes. He described remains of ducts and acini, which in his illustrations appear quite normal.

Tissue, removed from the patient of De Wecker and Masselon,<sup>8</sup> led to a pathologic diagnosis of epithelial tumor, although the only epithelial structures in the accompanying illustration were normal-appearing gland-acini.

In short, the essential change in this disease has been described by all observers as a replacement of the normal glandular tissue, in whole or in part, by lymphoid tissue. For the most part, it is agreed that the glandular tissue, itself, plays entirely a passive

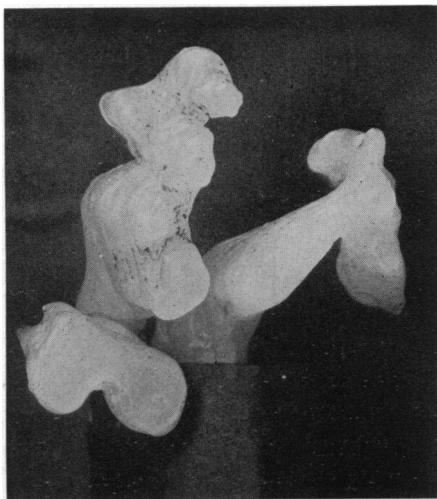


FIG. 3.—Wax model, constructed from outline drawings of thirty-eight serial sections, demonstrating duct-like branching of the epithelial masses.

rôle; that its destruction is due to the tremendous proliferation of the lymphoid tissue. This lymphoid replacement-tissue has varied in the descriptions from a simple proliferation of lymphocytes to a lymphoid tissue with plasma cells, eosinophil leukocytes, and giant cells, and with considerable increase in the connective tissue.

The description of the glands in this report is, therefore, essentially like those of other observers, except that structures, identified as ducts in varying stages of destruction, are described and reproduced in photomicrographs. Consequently, this report is made not merely because Mikulicz' disease is relatively rare, but mainly to describe these partly destroyed ducts, to the end that their presence need not be confusing.

Mikulicz' disease may occur at any age, but usually in early adult or middle life. Of forty-one reports, collected by Howard,<sup>9</sup> in which the data seemed sufficient to classify them with the so-called Mikulicz' disease, the oldest patient was seventy-seven years old, the youngest five and five-tenths, and the average age thirty-three. Twenty-six were men and fifteen were women. There was involvement of both the lacrymal and salivary glands in sixteen patients, with the first involvement of the lacrymal glands in nine, of the

salivary glands in two, and with undetermined priority in five. The lacrymal glands were involved alone in eleven patients and the salivary glands alone in fourteen. Both increase and decrease in glandular secretion were not infrequent symptoms.

Mikulicz, in his report of 1892, ventured a suggestion as to the origin of the peculiar disease. He thought that it was neither neoplastic nor related to leukæmia, because of the localization of the disease to the region of the face, the normal blood-formula, the lack of generalized lymphatic enlargement, and because, once the gland was wholly extirpated, it did not recur. He was aware that Heidenhain had found lymphoid tissue in the normal glands. Bearing in mind the remarkable and prompt response of lymphoid tissue to infecting organisms, he suggested that the disease was an infectious or parasitic one; the glandular tissue being destroyed by the excessive growth of the lymphoid tissue of the glands. He conceived of the infection beginning in the lacrymal glands, probably from the conjunctival sac, and then secondarily involving the salivary glands by way of the tear-duct, pharynx, and mouth.

Brunn<sup>10</sup> noted that symmetrical enlargements of the lacrymal and salivary glands involved the lacrymal glands alone, or the salivary glands alone, as well as involving both sets of glands. He found that these enlargements had been reported as unaccompanied by changes in the lymph-nodes, spleen, and blood; and that they had also been reported with enlargement of the lymph-nodes and spleen<sup>11</sup> and even with a leukæmic blood-formula.<sup>12</sup> Therefore, he concluded that the condition, described by Mikulicz, was a symptom-complex, rather than a disease-entity, and that it bore a close relationship to pseudoleukæmia and leukæmia. Many later writers have agreed with Brunn, believing that there is no definite line of division between the uncomplicated salivary and lacrymal enlargements and those occurring with pseudoleukæmia and leukæmia, that one group merges into the other, and that they probably have a common cause.

On the other hand, symmetrical enlargement of these glands has also been reported as coexistent with tuberculosis, syphilis, erythema multiforme, and epidemic encephalitis, and even has been connected with deranged function of the glands of internal secretion. However, no conclusive evidence, such as the finding of tubercle bacilli, spirochæta pallida, or other organisms in the tissue, has been presented, except by Krailsheimer,<sup>13</sup> who reported the discovery of numerous tubercle bacilli in the submaxillary gland, as well as tubercle-like nodules in the iris.

And furthermore, Mikulicz' disease has been classified by Ziegler<sup>14</sup> as an atypical form of Hodgkin's disease, similar to that form which involves the gastro-intestinal tract.

Inasmuch as the origin of lymphatic leukæmia, pseudoleukæmia, and Hodgkin's disease is entirely unknown, the attempt to connect Mikulicz' disease with them does not serve to clarify our knowledge of the nature of the disease. Then too, if there is such a close connection between all symmetrical enlargements of the lacrymal and salivary glands and these little-

understood diseases, it seems strange that such a large group with symmetrical glandular enlargement has not developed apparent signs of leukæmia, pseudoleukæmia, or Hodgkin's disease. The disease had existed for three years in Ranzi's<sup>15</sup> patient without change in the lymph glands or in the blood; for five years in Snell's<sup>16</sup> and in Berlin's<sup>17</sup> patients; for eight years in Kummel's<sup>18</sup> patient; and for twelve years in Tietze's.<sup>19</sup> Zondeck<sup>20</sup> later stated that the patient of Tietze's report had not developed change in the blood after another ten years, although the involved glands had become larger. There is no report of any patient, whose disease began as the uncomplicated one of Mikulicz, who died of that disease or as a direct result of it, except for the patient of Marcuse.<sup>21</sup> However, not long after the disease was noticed in this patient, the lymph glands were found to be enlarged, especially the mediastinal group, and death occurred eighteen months after the onset of the disease.

Kummel, De Wecker and Masselon, Berlin, Hahnle,<sup>22</sup> and Rollet<sup>23</sup> have noted, like Mikulicz, that there is no recurrence if the gland of Mikulicz' disease is completely removed. This is not the rule with the glandular involvements of leukæmia or Hodgkin's disease.

In view of these discrepancies, the ideas of Munck<sup>24</sup> seem, indeed, rational. He has called attention to the work of Chiewitz,<sup>25</sup> which indicates that the lymphoid tissue, found in the normal salivary or lacrymal glands, is anatomically and embryologically a part of the lymphatic system. Therefore, it is to be expected that this tissue would be subject to the diseases to which lymphoid tissue, elsewhere, is subject. Hence, it may react to various infections, including tuberculosis and syphilis, and may participate in such diseases as leukæmia, pseudoleukæmia, and Hodgkin's disease. While symmetrical enlargement of the lacrymal and salivary glands may be incidental to such diseases as leukæmia or Hodgkin's disease, or may be due to tuberculosis or syphilis, nevertheless, the original suggestion of Mikulicz may be true; that there is, indeed, a group in which the glandular enlargement is due to an infection, the organisms gaining entrance through the ducts of the glands by way of the conjunctival sac or buccal cavity. The occurrence of conjunctival, nasal, pharyngeal, or tonsillar infection, preceding the onset of the disease, has been reported by several observers<sup>26</sup> and may not be without significance.

If the term, Mikulicz' disease, be made to include all chronic, symmetrical enlargements of the lacrymal and salivary glands, it is evident that it cannot imply a disease-entity. Nevertheless, there seems to be a definite group of patients, like the patient of Mikulicz' report, whose disease has a long course without effect upon the general health or life of the patient, and hence, with a wholly different prognosis than that of leukæmia or Hodgkin's disease.

*Summary.*—Structures in the salivary glands of a patient with Mikulicz' disease are identified as ducts in various stages of destruction; are described; and are reproduced in photomicrographs.

Mikulicz' disease is essentially a disease of the lymphoid tissue of the lacrymal and salivary glands with secondary destruction of the parenchyma. It is probable that this lymphoid tissue, for the most part solitary nodes in

## HYPERPLASIA OF LACRYMAL AND SALIVARY GLANDS

and about the walls of the ducts, undergoes or is subject to diseases quite like those of lymphoid tissue elsewhere in the body. A separate classification of these diseases seems unnecessary.

### REFERENCES

- <sup>1</sup> Berl. klin. Wochenschr., 1888, p. 759.
- <sup>2</sup> Beit. z. Chir. Festschr. Theo. Billroth., 1892, p. 610.
- <sup>3</sup> Beit. z. klin. Chir., vol. xvi, p. 816, 1896.
- <sup>4</sup> Munchen. Med. Wochenschr., 1901, p. 177.
- <sup>5</sup> Ztschr. f. Augenheil., vol. x, p. 184, 1903.
- <sup>6</sup> Mittl. a. d. Grenzgeb. d. Med. u. Chir., vol. ii, p. 111, 1897.
- <sup>7</sup> Arch. f. Path. Anat. u. Phys., vol. clxxxv, p. 117, 1896.
- <sup>8</sup> Arch. d'Ophthal., vol. xii, p. 95, 1892.
- <sup>9</sup> Internat. Clinics, vol. i, p. 30, 1909.
- <sup>10</sup> Beit. z. klin. Chir., vol. xlv, p. 225, 1905.
- <sup>11</sup> Raymond: Cited by Brunn. Adler: Wien. klin. Wochenschr., 1889, p. 422. Hirsch: Mittl. a. d. Grenzgeb. d. Med. u. Chir., vol. iii, p. 381, 1898. Zirm: Cited by Brunn. Osler: Am. Journ. Med. Scien., vol. cxv, p. 27, 1898. Hackel: Arch. f. klin. Chir., vol. lxxix, p. 191, 1903.
- <sup>12</sup> Gallasch: Jahrb. f. Kinderheilk., vol. vii, p. 82, 1874.
- <sup>13</sup> Ophthalmoscope, vol. vi, p. 172, 1908.
- <sup>14</sup> Die Hodgkin. Krank., Jena, 1911.
- <sup>15</sup> Mittl. a. d. Grenzgeb. d. Med. u. Chir., vol. xvi, p. 554, 1906.
- <sup>16</sup> Snell: Lancet, vol. ii, p. 51, 1893.
- <sup>17</sup> Berlin: Cited by Brunn; also, Wurttemb. Korrespondenzbl., 1878, p. 249.
- <sup>18</sup> Kummel: Mittl. a. d. Grenzgeb. d. Med. u. Chir., vol. ii, p. 111, 1897.
- <sup>19</sup> Tietze: Beit. z. klin. Chir., vol. xvi, p. 816, 1896.
- <sup>20</sup> Zondeck: Cited by Howard; also, Verhandl. d. deutsch. Gesellsch. f. Chir., 1906.
- <sup>21</sup> Berl. klin. Wochenschr., vol. xli, p. 1205, 1904.
- <sup>22</sup> Hahnle: Ophth. Klin., 1900, vol. iv.
- <sup>23</sup> Rollet: Cited by Howard; also, Trans. Tenth Congres. Internat. d'Ophth. Lucerne, 1904.
- <sup>24</sup> Arch. f. Path. Anat. u. Phys., vol. cclvi, p. 81, 1925.
- <sup>25</sup> Cited by Munck; also, Fosterets. Udviking., 1892.
- <sup>26</sup> Mikulicz, Haltenhoff, De Wecker and Masselon, Kummel, Ranzi, Hahnle, Ziegler: Ann. Ophth., vol. xv, p. 72, 1906, and Von Reuss—Cited by Howard.