

CONTRIBUTION TO PLASTIC SURGERY *

REMOVAL OF SCARS BY STAGES; AN OPEN OPERATION FOR EXTENSIVE LACERATION OF THE ANAL SPHINCTER; THE KONDOLEON OPERATION FOR ELEPHANTIASIS

By WALTER E. SISTRUNK, M.D.
OF ROCHESTER, MINN.

FROM THE DIVISION OF SURGERY OF THE MAYO CLINIC

SIMPLE surgical procedures are often used and forgotten, and for this reason I wish to report in this symposium on plastic surgery two simple but useful surgical measures which, no doubt, have been used before but to which I am unable to find references. I also wish to discuss certain modifications of the Kondoleon operation which have proved valuable in improving the end-results in the treatment of elephantiasis.

REMOVAL OF SCARS BY STAGES

The skin, probably on account of its elastic fibres, easily stretches when put under tension. We see examples of this in large tumors, goitres, and in cases of elephantiasis after the oedema has been reduced by bandages and rest in bed. It is possible to take advantage of this characteristic of the skin and to remove scars situated in certain regions, where it would be inadvisable to use grafts in stages, allowing the skin after each operation to stretch and again become loose and movable. From the appearance of scars following skin grafts, from the color of the skin in these areas, or from the border of the graft when thick grafts have been applied, one can usually tell that grafts have been used. The appearance of the scar for which the original operation was performed may have been greatly improved, but the result is not always that desired by the operator.

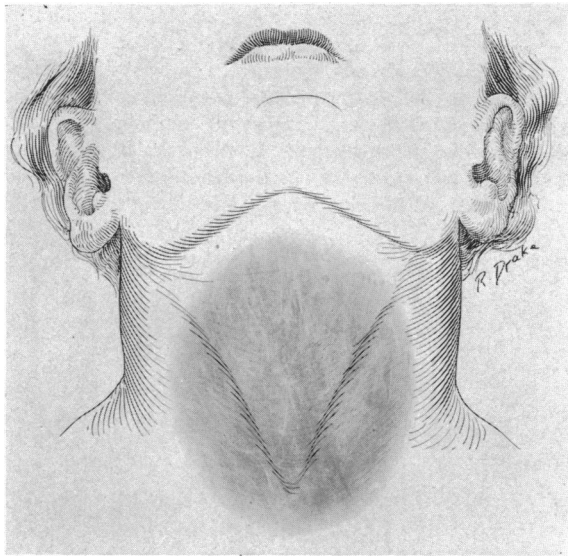


FIG. 1.—Appearance of Röntgen-ray burn before operation.

CASE I.—The patient was a woman, aged thirty, who had been affected with goitre since the age of sixteen. From many exposures to the Röntgen-ray in the treatment

* Read before the American Surgical Association, May 24, 1926.

WALTER E. SISTRUNK

of this goitre, a superficial burn resulted and the scar which followed involved almost the entire anterior surface of the neck from the hyoid bone nearly to the clavicle. Its appearance was so unsightly that the young woman was quite sensitive about it and to hide it wore, at all times, a scarf or a high collar. She had repeatedly consulted sur-

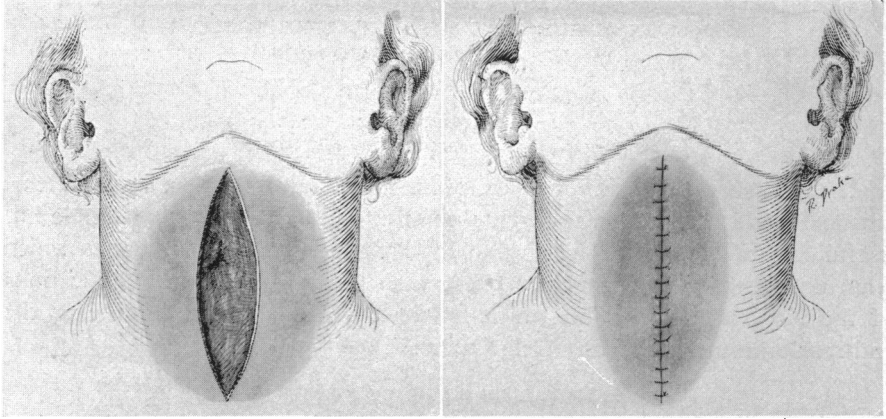


FIG. 2.—First stage of the operation. A small portion of the burned area excised and the wound closed. geons in the hope that it could be removed, but had always been advised against operation since they felt that the skin graft which would be necessary after removal of the scar would be almost as unsightly as the burn.

Examination showed the scar of a superficial burn with movable skin which was unattached to the deeper tissues. It was quite red in appearance and showed many large, dilated capillaries. Apparently nothing short of complete excision of the burn would improve the appearance of the neck. It was accordingly suggested that the burn be removed by stages, to which method of treatment the patient gladly consented.

As much of the skin as could be removed and still allow closure of the edges of

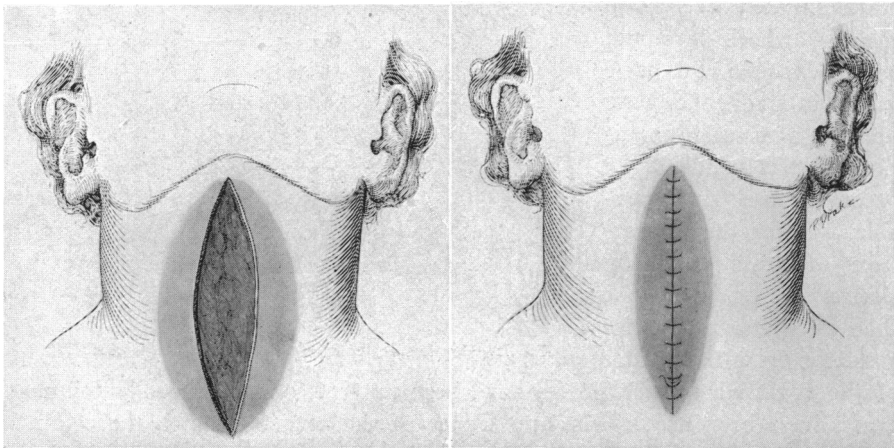


FIG. 3.—Second stage of operation (repetition of first stage).

the wound without tension was removed. The skin and superficial fat only were removed and special effort was made to avoid undermining the skin in order to prevent adhesions between it and the deeper structures which would later prevent the skin being stretched by massage, and so forth. It was possible in this way to remove about one-

CONTRIBUTION TO PLASTIC SURGERY

third of the scar. Following the operation, the patient stretched the skin by movements of the neck and by massage. On her return six months later, the skin was as loose and pliable as it was at the first operation and the scar was only two-thirds as large. A similar operation was then performed, to remove about one-half of the remainder of the scar. The patient returned again after six months and, at a third operation, the remaining portion of the scar was removed. Now only a single line may be seen. In this way the skin was removed from almost the entire anterior surface of the neck without a graft (Figs. 1, 2, 3, and 4).

I have since employed the same method in removing an ugly scar from the anterolateral surface of the neck. The patient, a young woman, had

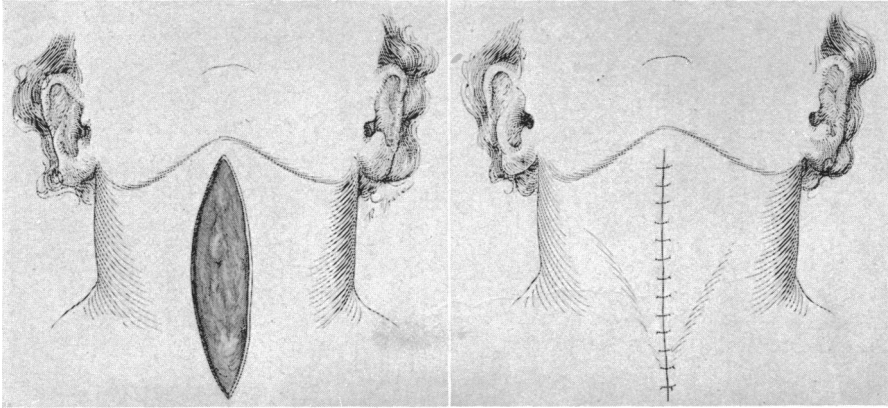


FIG. 4.—Third stage of operation. Remainder of burned area excised and wound closed.

suffered a severe superficial burn following the application of a strong solution of iodine. The results of the operation were excellent.

AN OPEN OPERATION FOR EXTENSIVE LACERATION OF THE ANAL SPHINCTER

In the ordinary case in which a primary operation is performed for a tear of the external sphincter ani, the operation almost universally described in text-books is quite satisfactory and is usually followed by good results. However, an occasional case is seen in which practically the entire external sphincter has been destroyed, usually either by an infection, as is seen in perirectal abscesses, or as a result of an operation for rectal fistula.

In the type of case which I am attempting to describe, the sphincter has often been largely destroyed and the nerves supplying it usually impaired or destroyed. In many such cases it is almost impossible to draw the ends of the sphincter together without such tension as to prevent satisfactory healing. The anus, too, in such cases, is necessarily so tightly closed in bringing the ends of the sphincter muscle together that too small an opening is left and the muscle ends usually separate during the first act of defecation. Should satisfactory healing occur, the normal control of the muscle is not regained, and the anus cannot be closed even by voluntary efforts.

For some years I have, in treating anal fistula, divided the tissues anterior to the fistulous tract and severed the external sphincter over a probe. In

order to prevent wide separation of the sphincter ends and still be able to pack the fistulous tract with gauze so as to allow the wound to heal from the bottom by granulation, I have sutured the cut ends of the external sphincter muscle to the internal sphincter (levator ani muscle). An operation of this sort has usually cured the fistula and at the same time has established excellent control. The effect on control of bowel movements has been so satisfactory that I have extended the use of the operation and now follow practically the same method in operating for complete lacerations of the

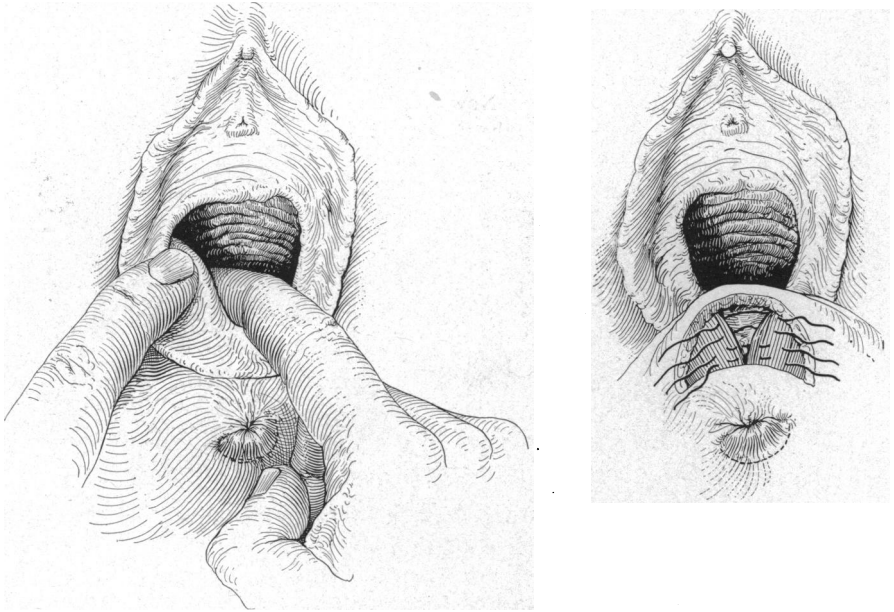


FIG. 5.—Exposure of levator ani muscle.

perineum and in repairing the anal sphincter when it has become incompetent from any cause.

Technic.—A curved transverse incision is made just above the anus or along the vaginocutaneous margin, and the levator ani muscle isolated. This muscle is sutured over the anterior rectal wall, as in an ordinary perineorrhaphy. The ends of the external sphincter which are often widely separated are isolated and sutured to the levator ani, the ends being brought as closely together as possible without too much tension. If sutured under too much tension, satisfactory healing will not occur, as the tissues will slough and the sutures fail to hold. The ends of the muscle are usually brought close enough together to close the anus so that it fits snugly around an index finger introduced into the rectum. The wound is left open and packed with iodoform gauze, as is done in operations for rectal fistula. The gauze is usually held in position by a suture placed through the edges of the skin and loosely tied in such a way that the edges of the skin are left wide open. After seven or eight days it may be removed and a healthy granulating surface usually

CONTRIBUTION TO PLASTIC SURGERY

results which slowly heals. The scar tissue which forms in the healing process unites fairly satisfactorily the edges of the external sphincter. If the nerve supply to this muscle is uninjured, the patient usually develops normal control; if it has been injured, normal control will not be regained but the patient will usually be able to close the external sphincter voluntarily by elevating the levator ani through efforts to close the vagina or to lift the rectum upwards. Through this voluntary effort, patients are usually able to close the anus fairly tight upon a finger introduced into the rectum and can

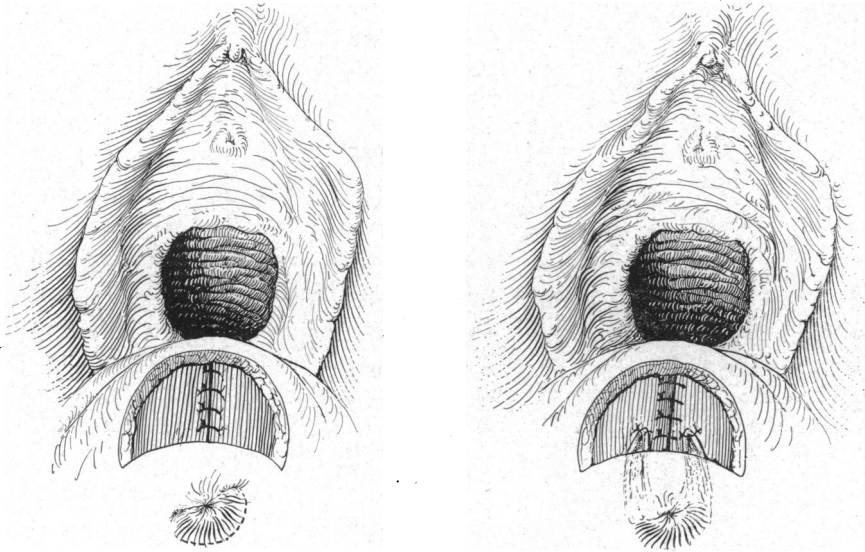


FIG. 6.—Levator ani muscles sutured together and remaining portion of anal sphincter sutured to them.

usually keep the anus closed sufficiently long to control gases and faeces until the toilet can be reached. The ability to close the anus by voluntary effort gives the patient great mental relief. The operation differs from that ordinarily performed for complete lacerations, as I have seen it described and carried out. In the common operation, the ends of the sphincter are merely sutured together, often under great tension, without any attempt to suture them to the levator ani. The method I have described tends to give much better voluntary control, the only control that can be expected in certain cases in which the sphincter has largely disappeared and its nerve supply been injured (Figs. 5 and 6).

More satisfactory results are obtained when patients are given castor oil forty-eight hours previous to the operation and allowed only water, fruit juices and sugars after the oil has acted. I usually induce constipation by administering paregoric before the operation. This medication is also continued for about ten days after the operation, during which time patients are given only water, fruit juices and broth. After ten days, oil enemas, consisting of 180 c.c. of olive oil, are given by rectum morning and night, and a

mild laxative, such as milk of magnesia, is administered several times a day until satisfactory bowel movements have occurred.

CERTAIN MODIFICATIONS OF THE KONDOLEON OPERATION FOR ELEPHANTIASIS

These changes in the Kondoleon operation have been made after nearly ten years' experience with the operation and contribute to the success of the end-results. At the present time I feel that this operation is of much value

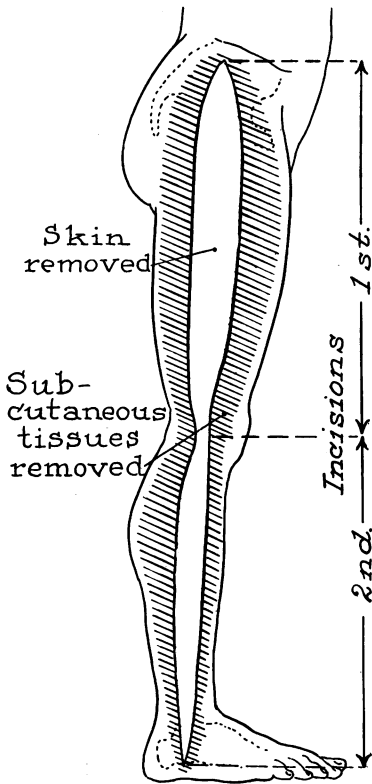


FIG. 7.—Strip outlined and undermined areas shaded.

in dealing with this disease. The operation cannot be considered one which will restore a perfectly normal limb, but as one through which the progress of this disease may be controlled and the size of the limb greatly diminished. Briefly, it may be stated that, although we see congenital elephantiasis, the so-called "idiopathic elephantiasis," which is usually seen in this country, is a sequel to partial or complete obstruction of the inguinal lymph-nodes. Elephantiasis is always preceded by simple lymphoedema which progresses until it gradually merges into elephantiasis. In lymphoedema the skin is thin, without the thickened dermis and aponeurosis and the large quantities of scar tissue seen in the subcutaneous tissues in true elephantiasis. The superficial lymphatic system alone is involved even in advanced cases of elephantiasis and this system is definitely separated from the deep lymphatic system by the aponeurosis covering the muscles. The Kondoleon operation is performed with an idea of connecting these two systems by removing a large amount of this aponeurosis. At the same

time, a large amount of the skin and subcutaneous fat is removed and the skin, with a small amount of the subcutaneous fat, is allowed to become attached to the muscles. When these raw surfaces are apposed, new blood-vessels, new nerves and new lymphatics form, and the superficial lymphatic system is thus connected with the deep system.

I believe that the removal of large amounts of diseased tissue with its blocked lymphatics is one of the very important steps of the operation. Kanaval has called attention to the fact that this was suggested many years ago by Rogers of Milwaukee. Better results are obtained if much larger amounts of the aponeurosis are removed than first suggested by Kondoleon, and I feel that the more tissue removed the better the result. In order that

CONTRIBUTION TO PLASTIC SURGERY

large amounts of diseased tissue may be removed and the edges of the skin still be closed, patients should be carefully prepared for the operation by rest in bed for periods of from ten days to several weeks. During this time, the limb to be operated on is kept elevated and firmly bandaged so that the fluids may

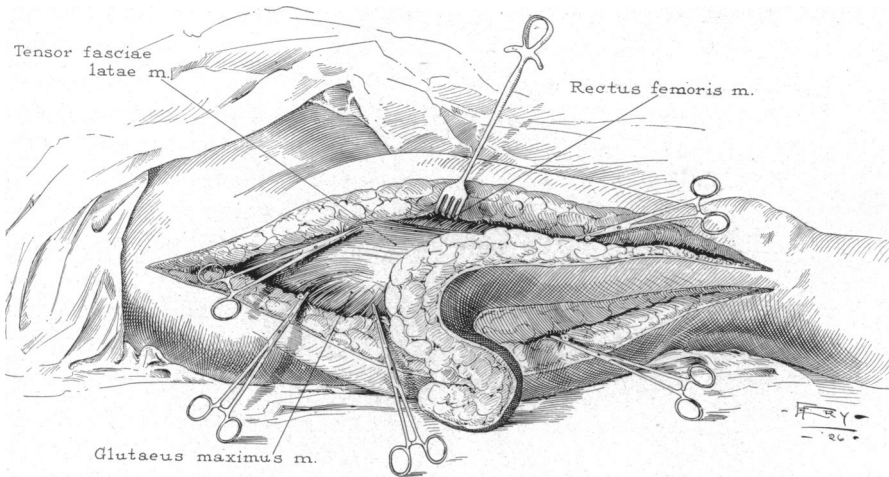


FIG. 8.—Strip nearly excised, vessels clamped.

be pressed out and the oedema diminished. The bandages are changed as often as they become loose and the patients are made to get up and walk rapidly down the hospital halls for a few minutes several times each day, so that the blood-pressure may be kept as near normal as possible. At the

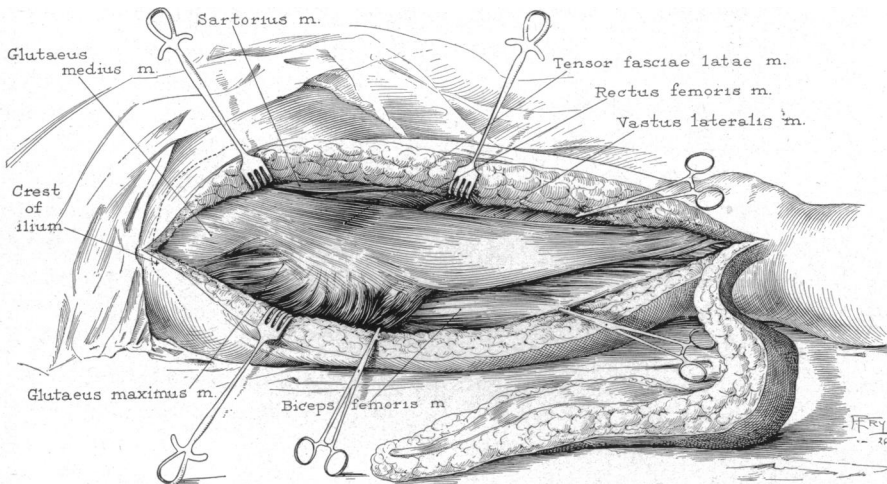


FIG. 9.—Strip from thigh excised with aponeurosis attached.

present time a very much more radical operation is performed than in the early cases.

Technic.—A long, modified semi-elliptic incision, which includes the skin to be sacrificed, is made on one side of the affected limb. On the outer aspect

of one of the lower extremities, for instance, this incision extends from the crest of the ilium to a point a little below the external malleolus. Then, in order to facilitate wide removal of the subcutaneous fat, the skin is reflected on each side of the incision for a distance of about 6 cm. The skin is then

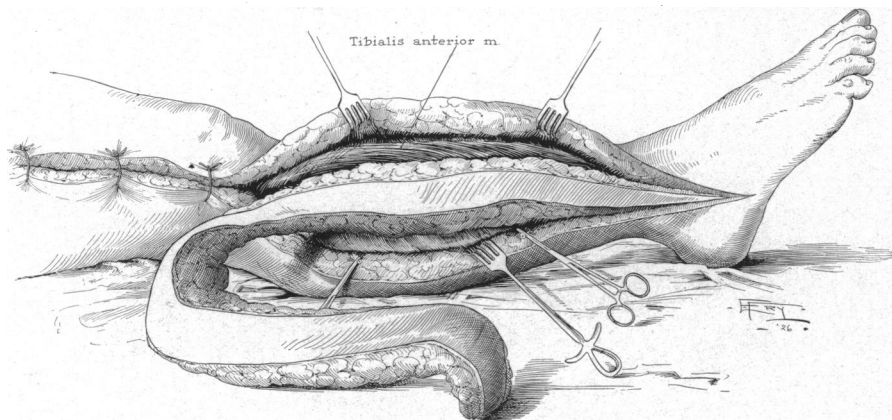


FIG. 10.—Incision in thigh closed and strip ready to be removed.

retracted and underneath each of the edges of reflected skin a long incision is made through the subcutaneous fat down to, and including, the aponeurosis. These incisions are made almost parallel with the original skin incision. Included between them is a quadrilateral piece of subcutaneous fat and aponeurosis. The two incisions through the aponeurosis are then connected at

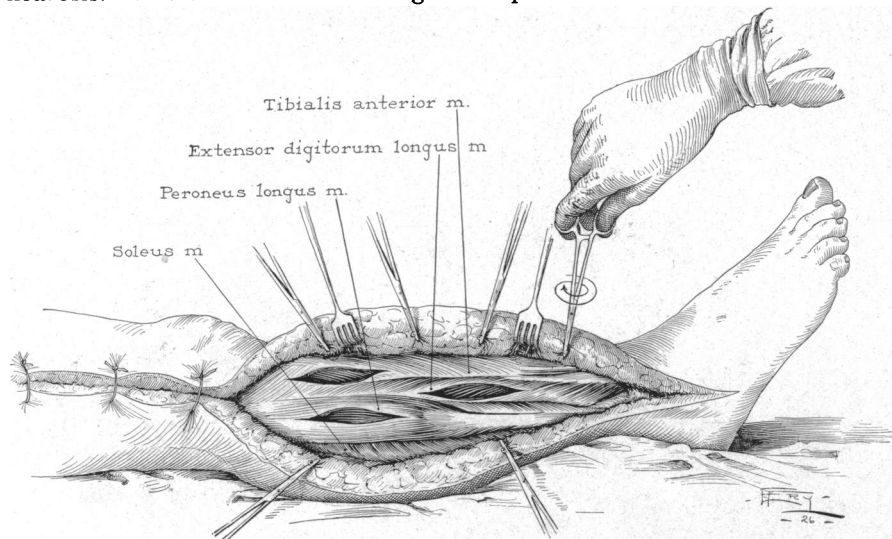


FIG. 11.—Incision in thigh closed, strip removed from leg and slits in muscles.

their ends, so that the tissues to be removed are free except for the attachment of the aponeurosis to the underlying muscles. By traction on these tissues it is easy to dissect the aponeurosis from the muscles throughout the entire length of the limb and to remove in one long piece the skin, subcu-

CONTRIBUTION TO PLASTIC SURGERY

taneous fat underneath it and aponeurosis. The skin with the small amount of subcutaneous fat is allowed to drop down on the muscles and the wound is closed with interrupted silkworm sutures without drainage. It is usually necessary to perform a similar operation on the opposite side of the limb (Figs. 7, 8, 9, 10, and 11).

The operation is not devoid of danger as very severe shock often follows a radical operation of this sort. Efforts are made to prevent this, first, by keeping the blood-pressure up as near normal as possible during the pre-operative period, and by the administration of opiates, usually one-quarter grain of morphin, one-half hour before the operation, and by deep ether anæsthesia. Nerve blocking, no doubt, would also help to prevent shock, although I have never used this method. After the operation the patient is immediately treated as though severe shock were present: the head of the bed is lowered, external heat is applied, morphin is administered, and isotonic solution of sodium chloride is given subcutaneously and by rectum. From 5 to 10 minims of a 1:1000 solution of epinephrin is also administered shortly after the operation, and repeated each hour for several doses. The period during which shock develops is usually passed after from six to twelve hours.

It is best before the operation to have a distinct understanding with patients as to the result to be expected; they should clearly understand that the operation is an attempt to control a disease which grows progressively worse if left untreated and which will eventually produce tremendous deformity and often in the late stages of the disease result in death through repeated attacks of erysipelas. They should also understand that it will be necessary to use a bandage for an indefinite period after the operation. Should extensive œdema develop after operation, in spite of the bandaging, much benefit is received by an occasional rest in bed with the limb elevated and carefully bandaged.