

ANNALS *of* SURGERY

VOL. LXXVI

AUGUST, 1922

No. 2

PLASTIC SURGERY OF THE FACE

BY EMMETT DE WITT HIGHSMITH, M.D.

OF ATLANTA, GEORGIA

PLASTIC surgery is concerned with any portion of the body in which there are defects from any cause, or from errors of development, though only deformities of the face will be discussed in this paper.

The chief aim of this work is to restore function, as well as to correct deformities. The technic differs to some extent from general surgery, especially operations on the face. As it is very necessary to prevent scar tissue as much as possible, we must be careful not to traumatize delicate tissue, lest our carelessness be registered in a deforming cicatrix.

Possibly the most frequent facial deformity we are called on to correct is harelip and cleft-palate, and while this condition is not a menace to life, these unfortunate individuals are greatly incapacitated, and as this deformity is relatively rare, too often they are allowed to go through life without correction or encouragement. The general surgeon only sees a few cases in a lifetime, though I think there is a greater number than is generally supposed.

Davis claims that harelip occurs once in 2400 infants; that there are 73 per cent. more males than females; and that more often a left side involvement than right.

Harelip operations should be done early. If there is a separation of the gums it is of the utmost importance that these cases be operated on before the fourth month, in order that the alveolar process may be bent and held in apposition by metal splits.

Lip operations can be done well at any age. In order to overcome the stiffening effect of the scar, whether the patient be infant or adult, it is essential to exercise the lip through massage, and in the case of an infant the use of the pacifier is beneficial for this purpose.

The cleft-palate cases should be done before the child learns to talk, as it is very hard to break them of their nasal sounds, once they have been established.

Rhinoplastic operations are even more rare than lip operations, though often the deformity is much more unsightly. While these patients do not suffer real pain, their humiliation is great and many are robbed of the chance to earn a livelihood by their unsightly appearance. The great value of these operations is the cosmetic and psychic effect.

EMMETT DE WITT HIGHSMITH

In the reconstruction of a nose there are three essential factors to be considered :

- 1st. An epithelial lining.
- 2nd. A bone or cartilage framework.
- 3rd. A skin covering.

The epithelial lining can be obtained from the adjacent skin with a pedicle.

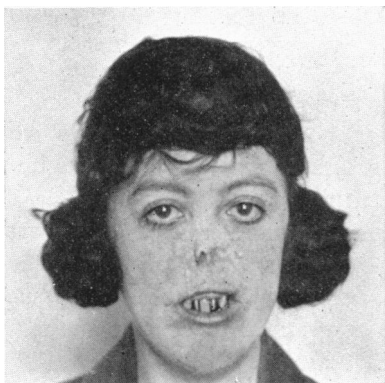

FIG. 1.—Case I. Front view showing destruction of nose and lip; before operation.

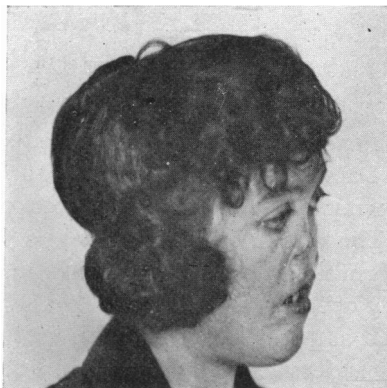

FIG. 2.—Case I. Profile.

If bone is to be used for the bridge it can be taken from the outer table of the frontal bone of the forehead attached to the flap to be used for the skin covering.

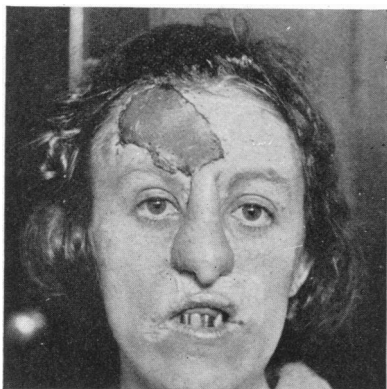

FIG. 3.—Case I. Showing patient ten days after first operation with Wolf graft in place on forehead, and before pedicle of nose is cut and returned.



FIG. 4.—Case I. Showing patient six months after the nose and lip operation has been completed.

I prefer cartilage to bone, which can be easily obtained from the ninth costal cartilage. In this case it is best to cut the cartilage to the size and shape desired, leaving on all the perichondrium possible, embed this in centre of the flap to be used from the forehead ten days prior to the operation in

PLASTIC SURGERY OF THE FACE

order that the circulation may be thoroughly established before the flap is disturbed.

CASE I (Fig. 1).—A young woman age thirty-one. Had always enjoyed good health until eighteen years of age, when a hard, indurated ulcer appeared on the upper lip which remained for six months with very little change. After that time it began to spread very rapidly, destroying the upper lip and nose to the

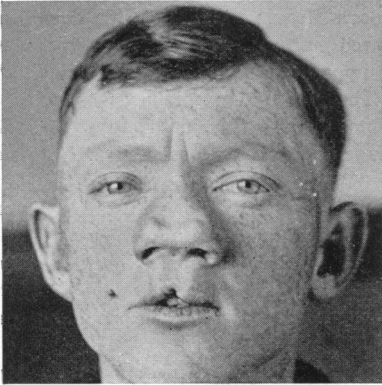

FIG. 5.—Case II. A young man twenty-four years old with a congenital deformity of the nose and lip. Family and past history negative.



FIG. 6.—Case II. Three months after operation.

nasal bones. Up to this time no diagnosis had been made; a later consultant was supposed to have given her some "blood medicine" and the ulceration rapidly healed. She came to the Gray Clinic in Atlanta in 1920, examination

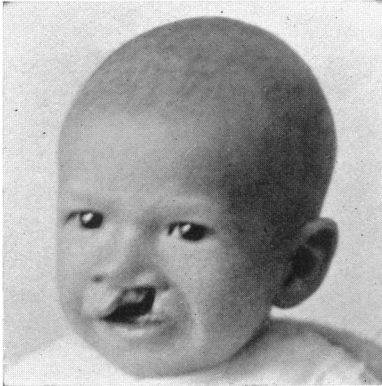

FIG. 7.—Case III. Shows baby three months old with unilateral harelip with wide cleft through alveolar process extending through horizontal process of palate with deviation of nasal septum to the right.

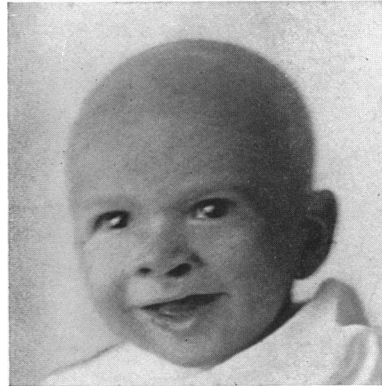


FIG. 8.—Case III. Eight weeks after first operation and two weeks after second operation.

showed a 4-plus Wassermann. She had taken thirty-two doses of Diarsenol with a 3-plus Wassermann when the first operation on her nose was done. Three months after the operation was completed she had a 4-plus Wassermann.

Technic of Operation.—Ten days prior to the nose operation the rudimentary

EMMETT DE WITT HIGHSMITH

septum was cut above, leaving a pedicle below, and brought down to act as a part of the supporting framework and the septum of the new nose. Also a piece of cartilage about one and a quarter inches long was taken from the ninth costal cartilage and cut to the size and shape desired, and slipped under the skin of the forehead in the centre of the flap to be used for the skin covering of the nose. At the time of the nose operation the patient was given 4-½ ounces of ether in olive oil, colonic method, which completely anesthetized her for a period of two hours. A cross incision was made through the skin on the nose and equal distance above to the prepared septum below, and turned down, leaving epithelial side down for the skin lining, and sutured to the prepared septum. A triangular piece of skin on each side of the nose was turned up and sutured to the first flap and septum, completing the epithelial lining. Then by actual measurement with a piece of tin foil, the skin covering for the nose was cut from the forehead with pedicle attached, leaving the prepared cartilage in the centre, sutured and dressed with Carpenter's court plaster.

CASE II (Fig. 5).—A young man, twenty-four years old, with a congenital deformity of the nose and lip. Family and past history negative.

Technic of Operation.—A horizontal incision through upper lip just above vermilion border and closed with dermal suture, bringing the thin tab down which gives the appearance of the cupid's bow, and dressed with Carpenter's court plaster which was left on five days.

In correcting the nose, a vertical incision was made commencing in the centre over nasal bones and extending to near the tip of nose. A portion of nasal bones was chiseled off, the cartilage on right was removed and the cartilage on left swung to the centre for the supporting framework of the nose. The redundant skin was cut away, and dressed with Carpenter's court plaster.