

## Peripheral neutrophil inclusions in amiodarone treated patients

P. C. ADAMS<sup>1</sup>\*, P. SLOAN<sup>2</sup>, A. R. MORLEY<sup>2</sup> & D. W. HOLT

Departments of <sup>1</sup>Cardiology and <sup>2</sup>Pathology, Freeman Hospital, Newcastle-upon-Tyne and Poisons Unit, Guy's Hospital, London SE1

In 14 patients receiving chronic amiodarone therapy the appearance of multilamellar inclusion bodies in peripheral blood neutrophils was related to both plasma concentrations of amiodarone and its desethyl metabolite and unwanted effects of the drug. Seven of the patients had well defined inclusion bodies. In this group mean amiodarone and desethylamiodarone concentrations were significantly higher than in the remaining seven patients and all but one had unwanted effects of the drug. Of the seven patients without inclusion bodies only one, with high plasma amiodarone and desethylamiodarone concentrations, had unwanted effects of the drug. It is concluded that the appearance of multilamellar bodies in the blood neutrophils of amiodarone-treated patients may help to distinguish those patients at risk of long-term amiodarone toxicity.

**Keywords** amiodarone neutrophil inclusions toxicity

### Introduction

We have previously shown that amiodarone and its principal metabolite in man, desethylamiodarone, accumulate in human tissues in high concentrations (Adams *et al.*, 1985) consistent with the drug's exceptionally large volume of distribution (Holt *et al.*, 1983). We have also demonstrated the frequent development of multilamellar inclusion bodies in a variety of tissues, including pulmonary macrophages, hepatocytes, peripheral nerve tissue, cornea and blood neutrophils, suggesting a drug-induced lipodosis (Adams *et al.*, 1985). These morphological changes are seen not only in association with clinical adverse effects (Dake *et al.*, 1985), but also in their absence, an observation which has led us to investigate the frequency with which multilamellar bodies appear in the neutrophils of peripheral blood samples from patients taking long-term amiodarone. Their presence or absence has been correlated with drug and metabolite concentrations in plasma and with

putative lipodosis-associated adverse effects, in particular those affecting the liver and lung.

### Methods

Fourteen patients (9M/5F), mean  $\pm$  s.d. age  $59.7 \pm 8.8$  years (range 41–70), who had received a mean amiodarone dose of  $403 \pm 136$  mg day<sup>-1</sup> (range 200–600) for  $16.4 \pm 12.2$  months (range 2.5–41.5) were studied. Patients were receiving amiodarone for the treatment of a variety of cardiac arrhythmias—ventricular tachycardia (8), supraventricular tachycardia(3), frequent ventricular premature beats(2) and atrial fibrillation(1). The patients were assessed for the development of the most clinically significant amiodarone-induced adverse effects. Thus, pulmonary effects were documented from clinical examination, radiology and changes in carbon monoxide transfer factor and hepatic effects

\*Present address: Division of Cardiology, Mount Sinai Medical Center, New York, USA  
Correspondence: Dr D. W. Holt, Poisons Unit, Guy's Hospital, London SE1

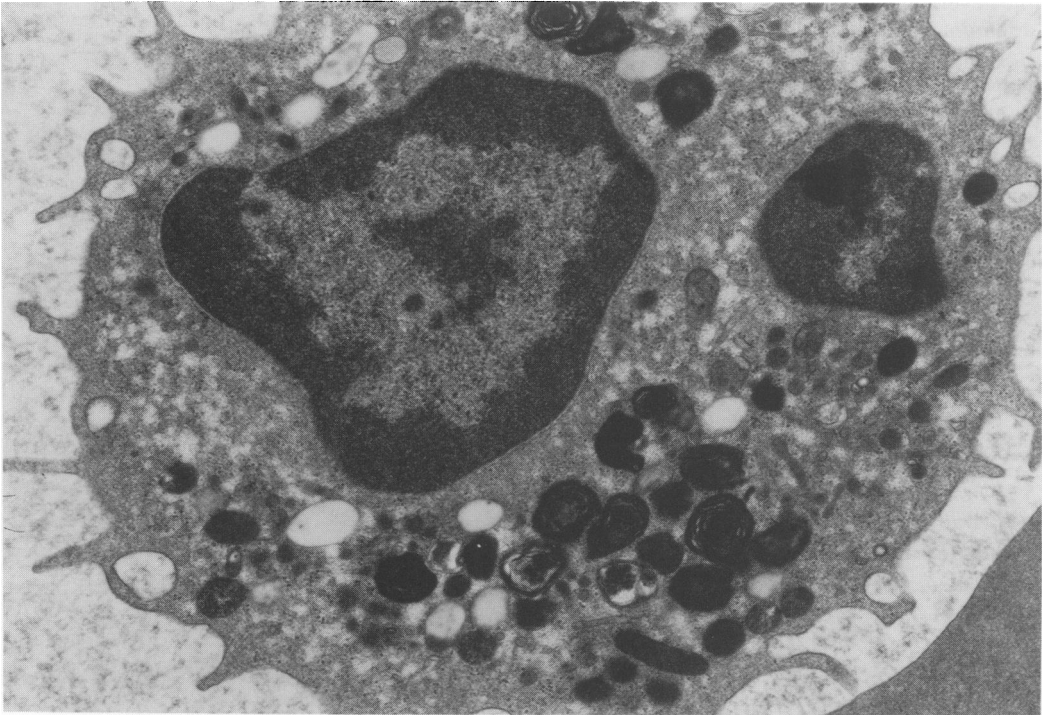
from plasma AST activity; clinical neuropathic features were noted and thyroid function assessed. Corneal changes and skin photosensitivity, common but clinically less important, were not considered.

Plasma amiodarone and desethylamiodarone were measured by high-performance liquid chromatography (Storey *et al.*, 1982) and separate EDTA anticoagulated samples were collected for the preparation of buffy coat specimens. The separated buffy coat samples were fixed in osmium tetroxide and embedded in araldite; semi-thin sections were stained with uranyl acetate and lead citrate. These sections were examined by transmission electron microscopy at a magnification of  $\times 10000$  and randomly selected fields were photographed. The prints were assigned to one of two groups by an independent observer, blind to patient details. In Group 1 multilamellar bodies were absent or equivocal whilst in Group 2 there were at least three multilamellar bodies per neutrophil, as illustrated in Figure 1.

## Results

There were seven patients in each group. In Group 1 only one patient had unwanted effects as defined, a raised AST ( $64 \text{ iu l}^{-1}$ ), and his plasma amiodarone and desethylamiodarone concentrations were high ( $4.4/2.3 \text{ mg l}^{-1}$ ); one patient was hypothyroid. In Group 2 only one patient had no unwanted effects but four had AST at least twice normal, and three had frank pulmonary toxicity; one patient suffered peripheral neuropathy, whilst another had a sustained fall in carbon monoxide transfer factor of 26% and was hypothyroid.

Plasma concentrations of amiodarone and desethylamiodarone are shown in Figure 2; mean plasma concentrations of amiodarone and desethylamiodarone were higher in Group 2 ( $2.7 \pm 0.5 / 2.9 \pm 1.1 \text{ mg l}^{-1}$ ) than in Group 1 ( $1.5 \pm 1.4 / 1.2 \pm 0.6 \text{ mg l}^{-1}$ ),  $P < 0.02$  (Mann-Whitney U test). There was a significant association between the appearance of multilamellar bodies and plasma amiodarone concentrations in excess

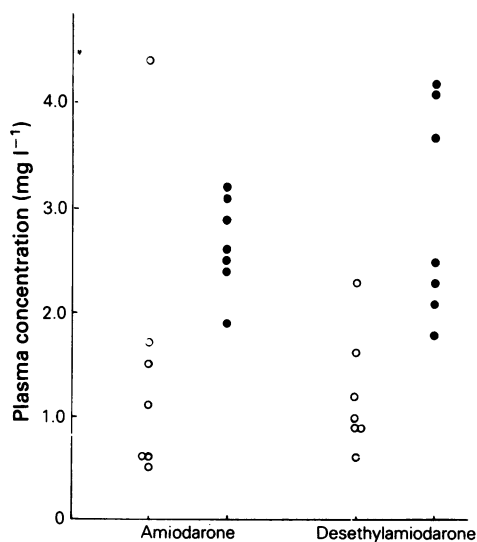


**Figure 1** Transmission electron micrograph (original  $\times 10000$ ) of a peripheral blood neutrophil from a patient in Group 2; note the prominent multilamellar lysosomal inclusions.

of 2 mg l<sup>-1</sup>,  $P < 0.04$ , ( $\chi^2$  test with Yates correction). Although the mean daily dose of amiodarone was higher in Group 2 ( $363 \pm 171$  mg vs  $443 \pm 83$  mg), there was no significant difference between the two groups in either the duration of therapy or the total dose.

### Discussion

The appearance of multilamellar bodies in a variety of cell types secondary to amiodarone therapy has been well documented (Adams *et al.*, 1985; Dake *et al.*, 1985) and is consistent with the development of a drug-induced lipidosis. In this preliminary study of a patient population with a high incidence of amiodarone toxicity the presence of multilamellar bodies in blood neutrophils was related to a number of clinically important unwanted effects, suggesting a systemic lipidosis. High amiodarone and desethylamiodarone concentrations were associated with the detection of multilamellar bodies and, since there is a linear relationship between amiodarone dose and plasma concentrations (Holt *et al.*, 1986), the development of lipidosis is likely to be dose related. However, in the small group of patients in this study, a relationship between dose and the development of multilamellar bodies was not apparent, raised plasma amiodarone concentrations being a more useful guide to their appearance. Electron microscopy of peripheral blood neutrophils, as well as the measurement of plasma drug concentrations, may be of value in



**Figure 2** Plasma amiodarone and desethylamiodarone concentrations in patients classified as Group 1 (○) or Group 2 (●) with respect to the development of multilamellar inclusion bodies (see text for details of classification).

assessing the risk of toxicity and planning dosage adjustment in patients receiving the drug chronically.

### References

- Adams, P. C., Holt, D. W., Storey, G. C. A., Morley, A. R., Callaghan, J. & Campbell, R. W. F. (1985). Amiodarone and its desethyl metabolite: tissue distribution and morphological changes during long-term therapy. *Circulation*, **72**, 1064–1075.
- Dake, M. D., Madison, M. J., Montgomery, C. K., Shellito, J. E., Hinchcliffe, W. A., Winkler, M. L. & Bainton, D. F. (1985). Electron microscopic demonstration of lysosomal inclusion bodies in lung, liver lymph nodes and blood leukocytes of patients with amiodarone pulmonary toxicity. *Am. J. Med.*, **78**, 506–512.
- Holt, D. W., Tucker, G. T., Jackson, P. R. & Storey, G. C. A. (1983). Amiodarone pharmacokinetics. *Am. Heart J.*, **106**, 840–447.
- Holt, D. W., Tucker, G. T., Jackson, P. R. & McKenna W. J. (1986). Amiodarone pharmacokinetics. *Br. J. clin. Pract.*, **40**, Symposium Suppl., **44**, 109–114.
- Storey, G. C. A., Holt, P., Curry, P. V. L. & Holt, D. W. (1982). High performance liquid chromatographic measurement of amiodarone and its desethyl metabolite: methodology and preliminary observations. *Therapeutic Drug Monitoring*, **4**, 385–388.

(Received 12 June 1986,  
accepted 1 August 1986)