

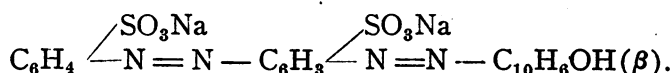
THE EFFECT OF SCARLET RED, IN VARIOUS COMBINATIONS, UPON THE EPITHELIAION OF GRANULATING SURFACES.*

BY JOHN STAIGE DAVIS, M.D.,
OF BALTIMORE, MD.,

Instructor in Surgery, Johns Hopkins University; Assistant Surgeon in the Out-patient Department of Johns Hopkins Hospital.

THIS paper has as its basis the observations made during the treatment of 60 cases with scarlet red.

Chemical Structure.—Scarlet red, or Biebrich's scarlet red, was discovered in 1882, and is an anilin dye which stains silk and wool a brilliant scarlet color. It is a disulphonic acid derivative, and the dye on the market is the sodium salt of the staining acid, and is in the form of a powder. It is made from diazoazobenzoldisulphonic acid and β -naphthol and has the formula,



Experimental Use of Scarlet Red.—Fischer, of Bonn, in his paper on "Experimental Generation of Atypical Epithelial Proliferations, etc.," published in 1906, called attention to the fact that when a saturated solution of scarlet red in olive oil was injected subcutaneously, an inflammatory condition was produced, and there was also an increase of mitosis in the germinal layer of the skin, as well as in the hair follicles and skin glands. He was able to produce this proliferation only in the skin, and from this was led to believe that scarlet red acted as a specific attraxin upon the surface epithelium. He found that the new formation of epithelium caused by the injection of scarlet red oil, which very markedly resembled skin carcinoma, showed no tendency for independent after-

growth, and kept up only as long as the injections were made. When these were discontinued the new formation retrograded and degenerated into epithelial pearly bodies. This suggested to him that it might be used therapeutically.

Helmholz, in 1907, was able to produce similar epithelial proliferations in the skin, and in addition succeeded in creating a like growth in the mouth and rectum. He thought that, with the technic as finally developed, he could get the same results in the stomach, intestines, etc. The positive results in the mucous membranes of the mouth and rectum would rule out the idea of Jores that the presence of hair follicles was necessary.

Helmholz found that there must be close contact between the scarlet red oil and the epithelium, in order that any reaction take place. He believed that scarlet red could hardly be claimed as a specific attractin, but rather something that by interaction with the connective tissue produced a soil that was ready for epithelial development. He also showed that the cylindrical epithelium in these experimental tumors remained so only as long as it lined a lumen, and when it formed in masses it changed to the squamous type, and just as readily returned to the cylindrical type when lumina formed in the epithelial masses. This metaplasia showed how different the process was from carcinoma, in which the character of the cells remains constant.

Werner, in 1908, found that concentrated scarlet red oil injected into mice carcinomata stimulated the growth only while the injections were continued, and from his experiments came to the conclusion that the proliferation was not a chemotactic influence on the cells, but occurred through the irritation of the same.

The above brief mention of the action of scarlet red oil, when injected subcutaneously, will give an idea of the theories brought forth as to the cause of the epithelial proliferations. I shall not discuss their relative merits here, but will simply take up the clinical results obtained by the local application of scarlet red, in various combinations, on granulating wounds,

in order to hasten epitheliation. From the experimental work mentioned above, and from the results of the therapeutic action so far reported, it seemed perfectly safe to use scarlet red externally for therapeutic purposes, without danger of producing carcinoma. My own investigations have, so far, confirmed me in this belief.

The only literature on the therapeutic use of scarlet red is as follows: Schmieden was the first to apply Fischer's suggestion, and published a paper on "Epithelial Growth under the Effect of Scarlet Red" early in 1908. Kaehler, in May, 1908, and Krajca, in September of the same year, and also Cernezzi, in February, 1909, published enthusiastic articles on this subject, with modifications of Schmieden's technic. Wolfrum and Cords, in February, 1909, reported favorable results on corneal ulcers with scarlet red salve.

Being stimulated by these papers, and having an opportunity to treat and observe a number of granulating wounds in the Surgical Outpatient Department of the Johns Hopkins Hospital, I began a series of experiments with the scarlet red. A few of the cases thus treated were house cases in the Johns Hopkins Hospital and at the Union Protestant Infirmary, but the greater number were those in the Outpatient Department. These cases were not selected, and the wounds for the most part were very unsatisfactory to start with. Many were chronic ulcers of various varieties, belonging to the class of wounds upon which Schmieden stated the treatment with scarlet red was useless. A large number of these patients continued their daily occupations, and thus the factors of rest and regular attendance could not be counted on. In fact, a more severe test of a treatment could scarcely be applied.

The dye employed was that manufactured by the Badische Company of Ludwigshafen, Germany, which is sold in one pound cans, and is inexpensive. In the experiments, I have used 2, 4, 5, 8, 10, and 20 per cent. scarlet red ointments, with a simple vaseline base. As I have been unable to observe any especial antiseptic properties in scarlet red, I had the following antiseptic ointments of U. S. P. strength made up in

vaseline, and containing 8 per cent. scarlet red; boric acid; zinc; iodoform; blue ointment; and an ointment consisting of one drachm balsam of Peru to one ounce of vaseline. On several occasions I have dusted small wounds with the pure powder.

The ointments were prepared by rubbing up the scarlet red with a small amount of olive or castor oil, until a smooth mass resulted, and then this mass was thoroughly mixed with the base. Sterilization of the ointment caused the color to become somewhat darker, but this change did not seem to affect the stimulating power of the preparation.

Technic.—Clean, healthy granulations should be bathed with boric acid solution and dried. Should the granulations be unhealthy, peroxide of hydrogen is used in addition before the boric acid solution. I have found it best not to use bichloride of mercury or other strong antiseptic solutions on the wound before treating it with the scarlet red. Free use of nitrate of silver stick is advisable to keep down exuberant granulations. The skin surrounding the defect should be anointed with some bland ointment up to within 1 cm. of the edge. Since this has been done the irritation complained of in some of the early cases has been, to a large extent, eliminated.

The ointment may be applied over the whole surface of the wound if it be small, or simply to the growing epithelial edges. Whichever method is chosen it is best to apply the ointment on perforated old linen, to which the granulations will not adhere, and which allows the escape of secretions and thus prevents maceration. When applied to the edges, the old linen should be used in narrow strips covered with a thin layer of the ointment. I prefer the old linen to the rubber protective advocated by Cernezz, as it is less macerating.

Another very satisfactory method is to apply a thin coating of the scarlet red ointment to the wound edges with a camel's-hair brush, being sure that the edges are dry. Then either cover with strips of old linen, or expose to the air. This is especially useful in the partial graft cases and on small wounds.

as the ointment can thus be accurately placed and the amount regulated. The portions of the wound not covered by scarlet red may be dressed as seems best, or may simply be exposed to the air under a cage.

A light dressing of sterile gauze secured by a bandage completes the procedure. This dressing should be removed within forty-eight hours, twenty-four-hour intervals being preferable, and replaced by some bland ointment, such as zinc or boric acid ointment. After the same interval has elapsed the scarlet red dressing should be replaced. The importance of careful dressing is to be emphasized, as in some cases severe irritation has followed the improper application of the dressing. It is well to warn patients that the ointment may stain the dressing red, as several have returned much frightened, saying that the wound had been bleeding.

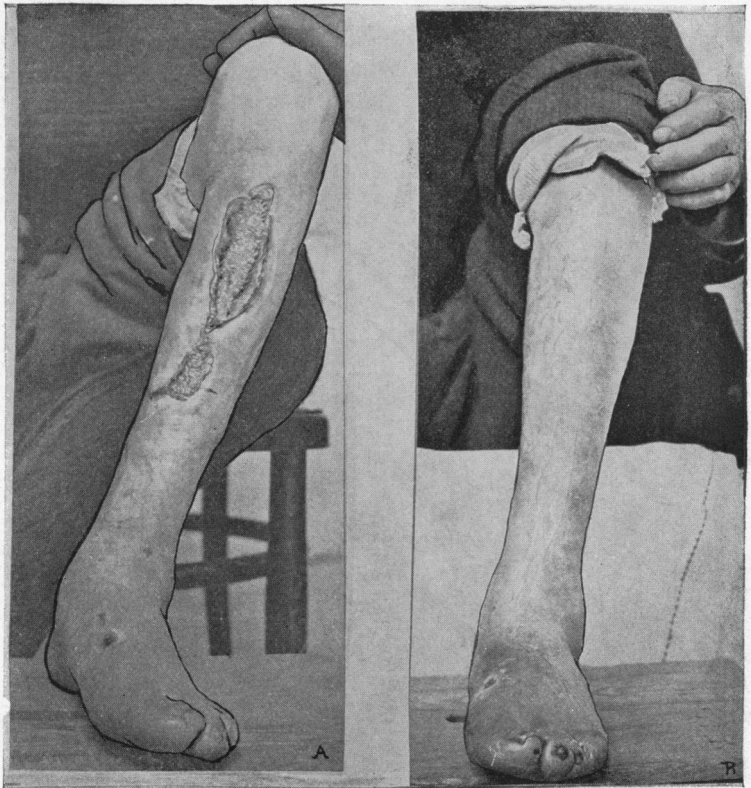Cases Treated.—There were 60 cases treated, of whom 44 were males and 16 females. The youngest was 2 years old, and the oldest 76 years. White, 46; colored, 14. *Duration of the lesions*, a few days to 15 years.

The cases were grouped as follows:

Partial skin grafts,.....	7
Ulcer following operation for infection,.....	10
Ulcer following burn,.....	11
Traumatic ulcer,.....	10
Specific ulcer,.....	8
Varicose ulcer,.....	7
Ulcer following Cotting operation for ingrown toe nail,...	3
Bedsore,	2
Miscellaneous ulcer,.....	2

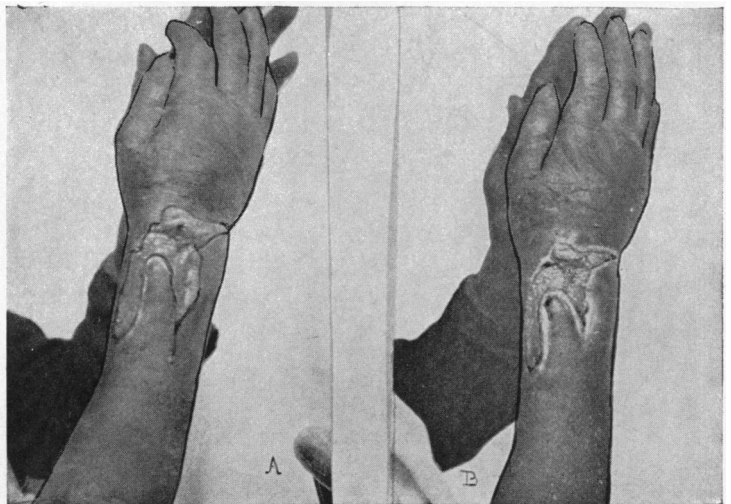
The general health of the patient seems to have some bearing on the stimulating effect of the scarlet red, which is distinctly less marked in nephritic and diabetic cases. The age, on the other hand, has little or no effect; for instance, the measured growth on one patient 76 years old was 3 mm. in 48 hours; and in another 67 years old, there was a growth of thick epithelium 4 mm. wide in 48 hours (Figs. 1 and 2). As we seldom have two lesions of exactly the same size on the same person, it is difficult to make an accurate comparison

FIG. 1.



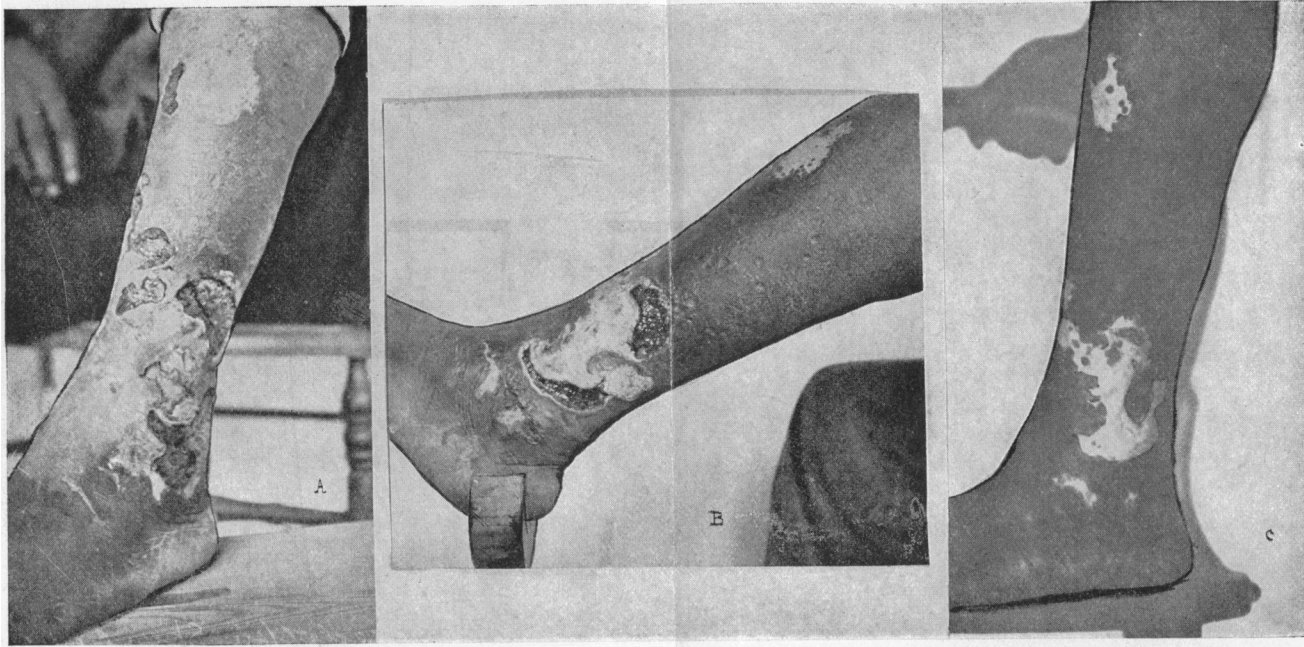
Traumatic ulcers, 11×5 cm. and 5×2 cm. Age of patient, 76 years. Duration, 3 months. (A) Taken January 27, when treatment was begun. (B) Taken March 22.

FIG. 2.



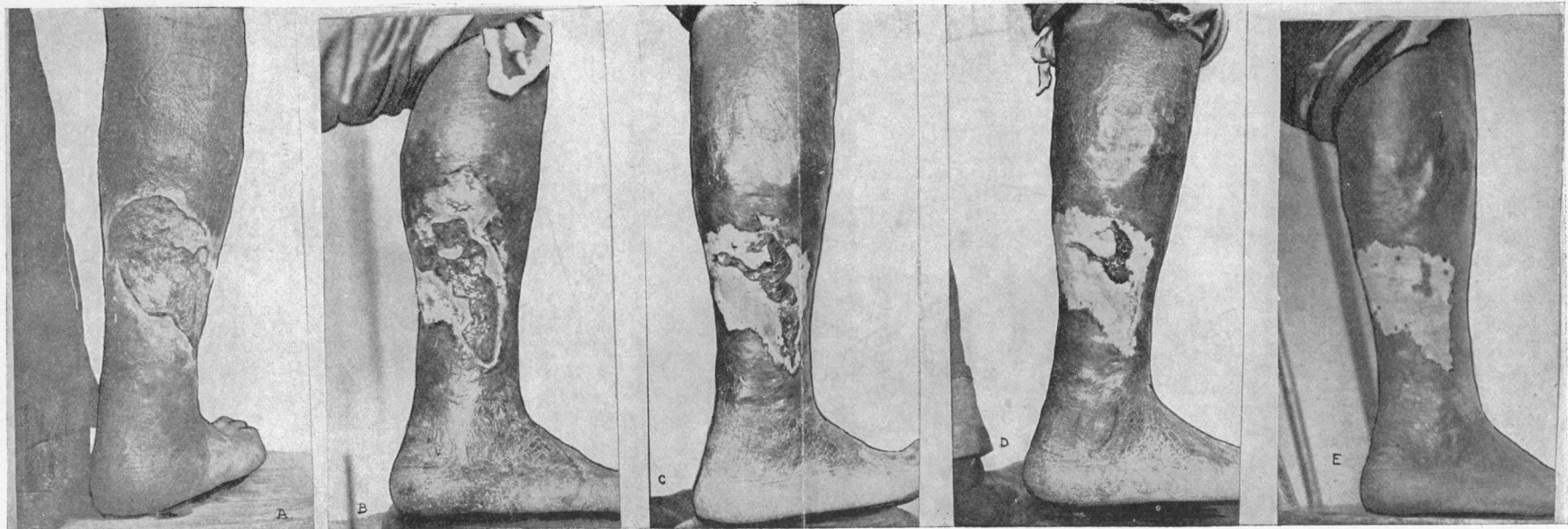
Ulcer following operation for infection of forearm and wrist. Largest diameters 15×5 cm. (A) Taken January 27, when treatment was begun. (B) Taken January 29. The stimulation of the epithelial edges is well shown in this picture, and measures 4 mm.

FIG. 3.



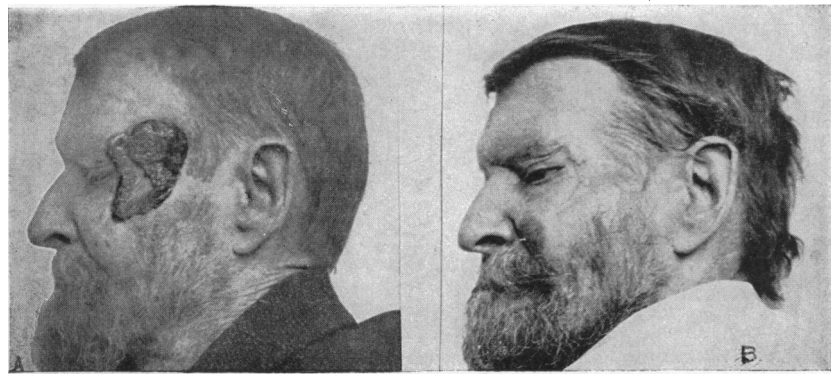
Multiple specific ulcers on outer side of leg of negro. Duration over one year. Ulcers, 4×2 cm., 6×4 cm., 8×3 cm. (A) Taken November 25, 1908, when treatment was begun. (B) Taken December 9. (C) Taken February 4, 1909. Note return of pigmentation in newly formed skin (C).

FIG. 4.



Varicose ulcer, 15×9 cm. Duration several months. (A) Taken October 16, 1908, when treatment was begun. (B) Taken November 18. (C) Taken December 18. (D) Taken January 2, 1909. (E) Taken February 10. A to C show the stimulation of the lower left-hand portion of the skin edge. Note return of pigment in new pink skin in E.

FIG. 5.



Ulcer following excision of epithelioma, 6×5.5 cm. Bone exposed. (A) Taken January 11, when treatment was begun. (B) Taken March 17. Difficult to make out edges of the scar.

between the rapidity of healing of a wound treated with scarlet red and one treated with the ordinary methods. However, on one patient there was an ulcer 3.5×3 cm. on each leg, and the one treated with scarlet red healed three weeks before the other, which was treated in the usual way. The difference in the appearance of the newly healed area was very marked, that following the scarlet red being thick, firm, and so much like the normal skin that it was difficult to make out the original outline of the ulcer, while the usual sharply defined scar marked the location of the other ulcer. In many cases there is undoubtedly a very marked stimulation of the epithelial growth, and, taking the results as a whole, while personal supervision in this series in connection with careful dressing is a factor which must be considered, one would hardly feel justified in attributing the success of the treatment entirely to this supervision.

The rapidly growing epithelium is thick and at first a bluish-red with an opalescent spreading edge. Venules of considerable size can be seen close to the surface. The color and the enlarged vessels soon disappear, however, and the newly formed tissue rapidly assumes the color and characteristics of the normal skin. A section through an area thus healed shows practically normal skin. As a rule, after a short time this skin becomes freely movable over the underlying tissues.

In several instances the patient did not return for from 5 to 16 days after dressing with scarlet red, and it was noted in two of these cases that where the granulations had been exuberant on small ulcers, a cone-shaped mass of epithelium covered these granulations. This projection soon disappeared and the epithelium assumed the level of the surrounding skin. No apparent bad effect resulted from the prolonged exposure to scarlet red in these cases, except that a grayish membrane formed over the granulations, which could be stripped off and the healthy granulations exposed. It is needless to say that there was no irritation in this group of cases. The grayish membrane over the portion of the granulations covered with scarlet

red will often form within 48 hours, and can be easily lifted off.

The method of pigmentation of the newly formed pink skin on negroes is interesting. Within a short time the sharply defined edges of the normal skin become wavy, and streaks of pigment project from it (Figs. 3 and 4). Here and there in the pink skin isolated patches of pigment appear, some of which are several centimetres from the pigmented skin edge. This seems to show that the pigment is derived from the deeper tissues, as well as from the skin edge. The pigment spreads from these patches also, and the entire area becomes dusky and later assumes the color of the neighboring skin.

The sensation of the newly formed skin begins at the margins and gradually spreads towards the centre. This is similar to what occurs in skin grafts, the nerve supply coming from the edges of the wound and not from the underlying tissues.

On those wounds which heal and then break down, because of the unstable condition of the epithelium, scarlet red has been useful; for example, a superficial ulcer following a burn on the front of the ankle and entire dorsum of the foot had nearly healed several times, and then completely broken down again. Treatment with scarlet red ointment was begun on December 26, 1908, and the healing was complete and all dressings were omitted on January 8, 1909, since which time the patient has had no further trouble, as the wound is covered with thick stable epithelium.

Scarlet red should not be used on burns until the irritation has disappeared, and the granulations are well established.

The exact strength and combination of the ointment to be used on different types of wounds can hardly be dogmatically stated, as experience is necessary for this knowledge. However a few general observations may be of advantage. The 8 per cent. ointment is used unless especially contraindicated. In some cases which were sluggish to the 8 per cent., the 20 per cent. ointment has caused rapid stimulation of the edges. I should not advise the constant use of the 20 per cent. strength, as on several occasions it has proved too irritating

in spite of all precautions. It is of value now and then, although its action should be carefully watched.

On several wounds which were nearly closed, the pure scarlet red powder was dusted on the uncovered area, after protecting the surrounding skin. It had a marked drying effect and caused no irritation.

When the wounds are covered with unhealthy granulations and the discharge is profuse and foul smelling, I have found the scarlet red in iodoform ointment, or balsam of Peru, or blue ointment very efficacious in cleaning up the granulations and at the same time stimulating the epithelial growth.

As an example of the unfavorable type of wounds treated, I will mention an extensive multiple leg ulcer of five years' standing, which was covered with maggots when the rags with which it was wrapped were removed. This was cleaned up and dressed with scarlet red and within 48 hours there was a definite stimulation of the epithelial edges, and uneventful healing later. It is interesting that this patient came to the Dispensary because he had mashed the tip of his little finger, and not for the leg condition, which he had been taking care of at home.

A number of large specific ulcers having a duration of from three months to five years, which had not responded to constitutional or local treatment, were stimulated markedly by scarlet red. Although they were among the most unfavorable-looking ulcers, the healing was prompt and lasting. In the specific cases constitutional treatment was of course continued. Several of these ulcers were very sensitive, and the patients volunteered the statement when returning for dressing that the "red salve" gave them more comfort than any dressing they had ever had. This seems a curious fact, inasmuch as scarlet red had an irritating action on some other cases, and caused pain and discomfort. Scarlet red in blue ointment is especially useful in treating specific ulcers.

There is a difference in the degree of stimulation caused by scarlet red on the epithelial edges of the same wound at different times. I have also noted that in several cases one portion

of the growing edge was markedly stimulated while the remaining portions were only moderately so.

The skin formed under scarlet red seems to fill the place of the missing skin, somewhat like a whole-thickness graft, and in only one case has there been any tendency towards cicatricial contraction. This case, a burn of the neck and chest, was treated in the hospital by the usual methods for some time before scarlet red was started. Several weeks after healing the patient returned with a small contracted band of scar tissue on the left side of the neck. She was advised massage, and told to return if the condition continued.

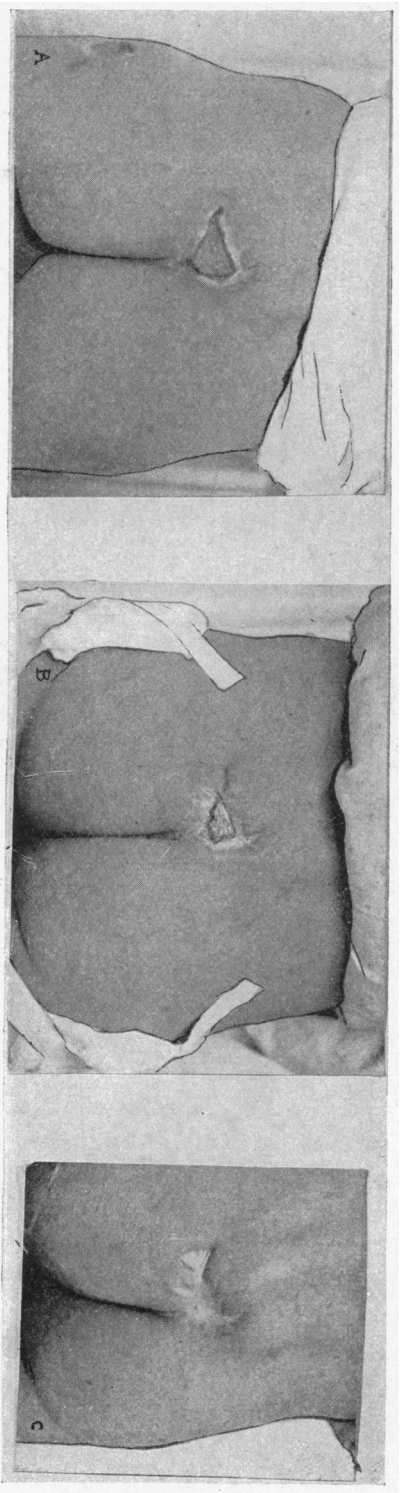
Several varicose ulcers were treated with scarlet red without a pressure bandage, in order to test the efficacy of the healing, and there was no diminution noted in its rapidity or character.

Ulcers following the Cotting operation for ingrown toenail are usually sluggish and heal slowly, but with scarlet red the healing is materially hastened.

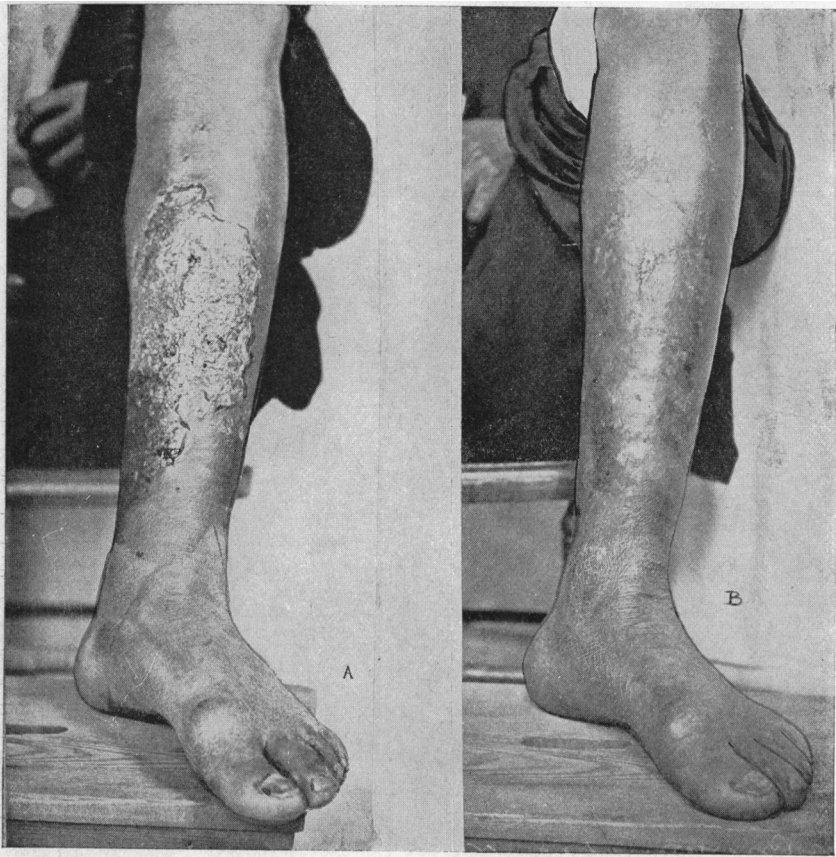
In an ulcer following the excision of an epithelioma of the face, there was a recurrence in the lower angle of the wound three weeks after operation. The ulcer had been treated once with scarlet red, only two days before the recurrence was noted, so I do not consider that the scarlet red was in any way responsible for the recurrence (Fig. 5).

I have been able to try the effect of scarlet red on an autodermic and isodermic partial Thiersch and whole-thickness grafts, and also on zöodermic (dog) grafts. All of the seven cases which were grafted had very extensive lesions, and several partial grafts were placed on each of these at different times. The wound edges and also the edges of all these types of grafts were markedly stimulated. Scarlet red, 8 per cent., if applied to the surface of a Thiersch graft within four days after transplantation, causes maceration of the surface. In order to avoid this I find it advisable to apply the scarlet red, in from 4 per cent. to 8 per cent. strength, to the edges of the graft alone, and not until ten days have elapsed. Only the edges of whole-thickness grafts should be covered with scarlet

FIG. 6.

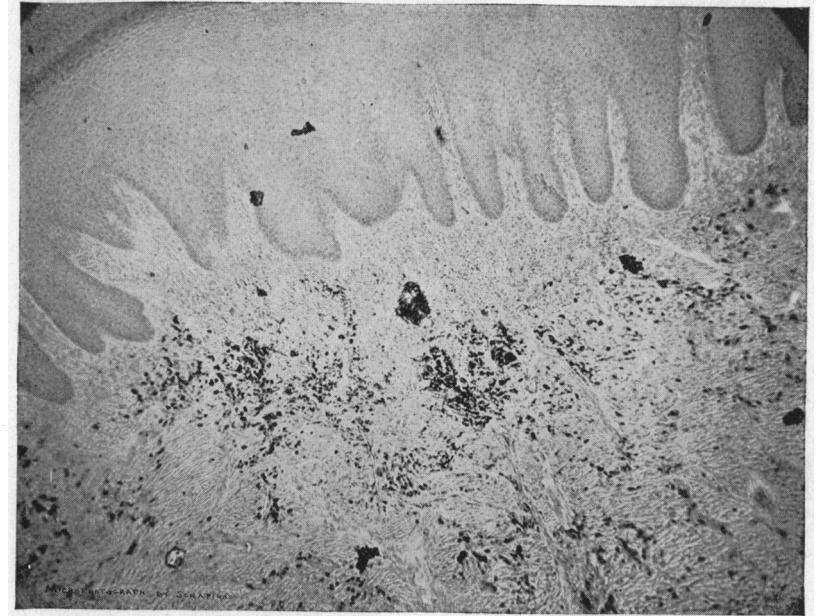

Redsore following typhoid, 3×5 cm. Duration several months. (A) Taken November 6, when treatment was begun. (B) Taken November 18. (C) Taken December 7.



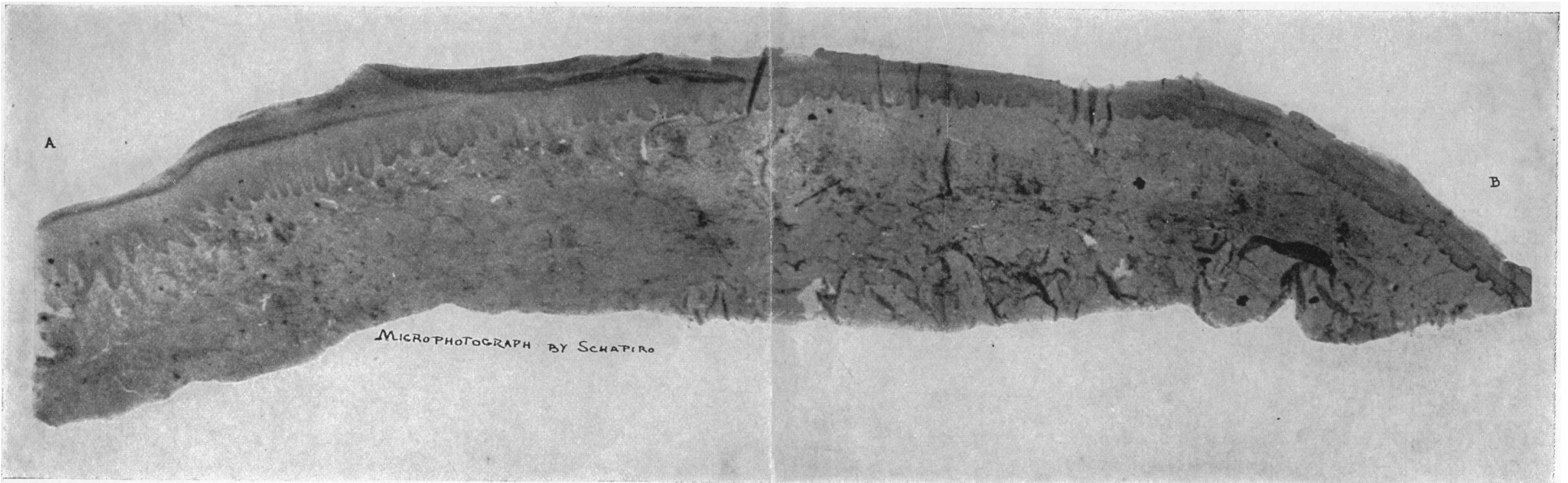
Ulcer following injury, with subsequent deep infection. (A) Taken December 4, when treatment was begun. (B) Taken December 14.

FIG. 8.



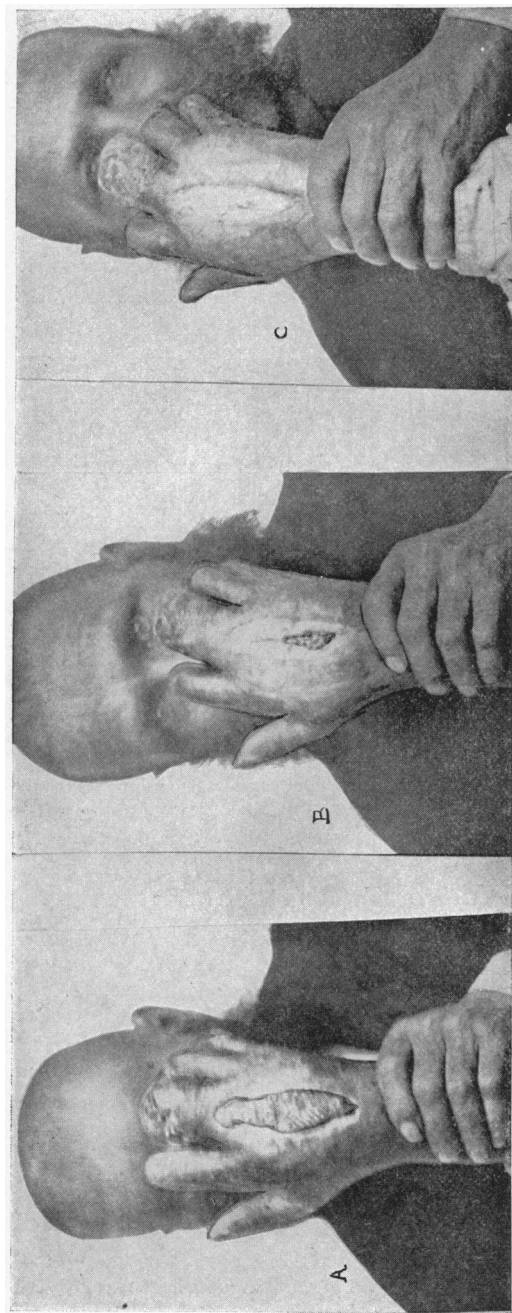
A small portion of Fig. 9 under higher magnification. Note the papillary formation and the thickness of the stratum Malpighii. The masses of pigment cells in the deeper layers of the skin are interesting from the fact that the newly formed skin is pink and shows no pigmentation, while in certain portions of the section, where it passes through an isolated pigmented spot in the pink skin, there seems to be a definite relationship between the pigment in the deeper layers and that in the cells of the stratum Malpighii.

FIG. 9.



Section of negro skin, formed under Scarlet Red treatment, on a chronic varicose ulcer of the leg. The end A is 2 mm. from the growing epithelial edge. The end B is a portion of the normal surrounding skin and shows pigment in the deep layers of the stratum Malpighii. At B the papillary formation is not especially noticeable and the stratum corneum and Malpighii are about normal thickness. As we follow the surface toward A, the papillary formation becomes more marked. All the layers of the epidermis become

FIG. 10.



Ulcer following operation for infection, 9×3 cm. Duration, 1 month. (A) Taken December 30, 1908, when treatment was begun. (B) Taken January 8, 1909. (C) Taken January 15. Measure on final healing, 6.5×1.5 cm.

red, unless the superficial layers are cast off, in which case the whole surface of the graft should be covered, as it will hasten the "topping" of the graft with epithelium.

Wolfrum and Cords report favorable results with 5 per cent. scarlet red ointment on corneal ulcers.

My experience with scarlet red on mucous membranes has been confined to pieces of vaginal mucosa transplanted to granulating wounds. The edges of these grafts were stimulated; also, the defect left by the removal of sections for examination healed under scarlet red very rapidly. From the above experience I have no doubt but that this method of treatment can be utilized with advantage on mucous membranes which can be kept reasonably dry.

It is an interesting fact that the scarlet red is absorbed and then excreted by the kidneys. This has been noted in a number of cases; for example, a large ulcer of the chest, following a burn, was dressed with scarlet red, 8 per cent., at 1.30 P.M. December 13, 1908. The urine voided at 2.10 P.M. was amber clear; at the next voiding at 9.30 P.M. it was a bright scarlet; December 14, at 2 A.M., still a bright scarlet; at 8.10 A.M. it was a pale red; at 11.25 A.M. still a pale red; at 1.30 P.M. the scarlet red was removed and the wound was dressed and irrigated. At 2.15 P.M. the urine was a reddish amber; and so on until 8.30 A.M., December 15, when it was a pale pinkish color; after this the urine resumed its normal amber color. There is no undue stimulation of urinary secretion, and except for the color the constituents of the urine are unchanged. The other excretions were apparently unaffected.

There was severe irritation in ten cases, eight of which were not permanently helped by the treatment, although there was stimulation of the epithelial growth in all but two cases. Most of these cases were those treated early in the series, and since better technic has been employed no severe irritation has occurred. However, in sixteen other cases there was a slight reddening of the surrounding skin accompanied by a burning sensation at some time during the treatment, although this in no way interfered with the ultimate result.

In several instances scarlet red had to be discontinued on account of the pain and irritation caused by it. This was espe-

cially noticeable in women and young children. In the case of a child two years old, with an ulcer following a burn of the axilla, the irritation of 5 per cent. scarlet red ointment was very marked. Following a second application of the ointment there was a sharp attack of erysipelas. Cultures from the ointment were negative, and as there had been no case of erysipelas in the hospital for some time it is likely that the irritation produced a favorable condition for the infection.

In a case of varicose ulcer of which the duration was ten years, and where the skin was particularly sensitive to scarlet red, there was a definite phlebitis of several veins in the neighborhood of the ulcer after the third dressing with scarlet red, and it seems probable that the irritation caused by the scarlet red might have extended into some of the superficial varicose veins. This patient became very ill and was admitted to the hospital. He ran a high temperature for about ten days, which was suspected to be due to typhoid infection, but this was not proved, and about three weeks later he was discharged from the hospital, the phlebitis having cleared up perfectly.

In a tuberculous ulcer of the groin of eight months' duration, measuring 8 x 10 cm. and having undermined edges, scarlet red was tried and very markedly stimulated the epithelial growth. It was quite remarkable that the new thick epithelium started beneath the undermined edges, and for a time these edges overlapped the new epithelium slightly, but were finally absorbed. This ulcer healed rapidly with firm healthy skin until 1.5 x 2.5 cm. remained uncovered, then suddenly without any apparent cause the ulceration began again here and there on the edges and in the new skin. On the continuance of the same treatment the ulcer finally healed completely, and as yet shows no tendency to break down.

Where tight pressure bandages are applied over scarlet red, there is more likelihood of irritation. There have been several cases in which there was marked stimulation of the epithelial edges at the beginning of the treatment, but later just as marked deterioration. This was the case especially when the attendance of the patient was irregular, and in such instances the treatment with scarlet red was discontinued.

In one case where a patient with a varicose ulcer stayed away from the Dispensary for five days with the scarlet red dressing,

the irritation of the surrounding skin was so intense that a breakdown was feared. This fortunately did not occur.

The skin over old scar tissue is apparently much more easily irritated than ordinary skin. The stability, thickness, and normal appearance of the healing under scarlet red is noteworthy, and even if the healing in some few instances is no more rapid than that under the ordinary methods, these advantages would seem to make it worth while (Figs. 6, 7, 8, 9, and 10).

BIBLIOGRAPHY.

- Cernezzi: *Gas. d. Ospedali e. d. Cliniche*, No. 14, February 2, 1909, p. 145.
Fischer: *Münch. med. Wochnschr.*, October 16, 1906, No. 42, p. 2041.
Helmholz: *Johns Hopkins Hosp. Bull.*, September, 1907, p. 365.
Kaehler: *Med. Klin.*, May 31, 1908, No. 22, p. 836.
Krajca: *Münch. med. Wochnschr.*, September 22, 1908, vol. lv, p. 1969.
Neitzki: *Chemie der organ. Farbstoffe*, 1889, p. 58.
Schmieden: *Centralbl. f. Chir.*, 1908, vol. xxxv, p. 153.
Werner: *Münch. med. Wochnschr.*, November 3, 1908, No. 44, p. 2268.
Wolfrum and Cords: *Münch. med. Wochnschr.*, February 2, 1909, No. 5, p. 242.