

SKELETAL CARCINOMATOSIS.*

WITH REPORT OF A CASE.

BY G. W. HAWLEY, M.D.,

OF BRIDGEPORT, CONN.

THE following case is of interest because carcinoma of the bones is not often recognized or suspected during life. Carcinomatous disease of bone has received little attention from the fact that it does not cause sufficient changes in the architecture of bone to excite clinical notice. Only rarely are any gross osseous lesions found, which accounts for the fact that few cases have been submitted to radiographic examination. Moreover, the subjective symptoms which accompany this disease are not distinctive, and tend to confuse it with more common affections. It is also apt to be overlooked for the reason that carcinoma of bone is never primary, but always secondary to a growth in some epithelial organ, usually remote.

In the case which I report, an accident (spontaneous fracture), not frequently occurring in carcinoma of bone, led to the discovery of bone disease, and the history of breast cancer gave a clue to its probable nature.

Mrs. S., apparent age 55 years. Began in July, 1907, to notice a gradually increasing feeling of general weakness, with sharp attacks of pain in right breast. In October she began to have pains in the legs and lower lumbar region. These pains continued more or less constant, and the weakness gradually increased so that she had difficulty in walking across a room. Finally, in December she became bedridden, and a month later was removed to St. Vincent's Hospital, Bridgeport. At that time she weighed 180 pounds. Pains in legs and back subsided somewhat, but the hospital chart states that pain in the breast was often severe. In February, 1908, the breast was amputated for cancer. The hos-

* This term, suggested by von Recklinghausen, has been chosen for the reason that it expresses more accurately the nature of the anatomic changes in the bones.

pital record shows that patient still complained of weakness, pain in the back, legs and sometimes all over the body. At one time pain was referred to the left hip. Eighteen weeks after the operation she began to walk, but had great difficulty in doing so, even with support. After several weeks' attempt to get about she was forced to spend most of her time in bed.

About one year after the breast operation, while standing in a bathtub, the left leg suddenly gave way, with an audible crack. Three months later she felt something give way in the right thigh as she was being lifted from a bed pan. Swelling about the hip followed the injury to both legs.

Examination October 22, 1909, shows a thin, anæmic woman. On the right side of the chest is a long cicatrix extending well up into the axilla. At the upper end of the scar are a few small, hard nodules and a large one in the axilla. In the left breast there is a hard nodule.

Both legs appear short and distorted; the left lies in normal extension and rotated outward 90° . The thigh appears to bulge forward very much like anterior bowing of the femur in rickets, making the inguinal fold very deep. Active motion is very limited and only slight passive motion was attempted because of pain. Palpation reveals the shaft of the femur extending upward and ending abruptly one inch below and somewhat anterior to the spine of the ilium, which lies hidden in the deepened inguinal fold. In the region of the trochanter is a large irregular mass of bone which rotates with the shaft.

The right leg lies flexed at 160° , adducted and rotated inward 90° . The thigh appears symmetrically enlarged above. Active motion slight. Passive motion gives patient fear that leg will break. On palpation there seems to be a uniform enlargement of upper end of the femur, extending from upper third into trochanter which seems enlarged, but in normal position, and rotates with the shaft. Measurements were not attempted because of the distorted, fixed position of the legs.

Further skeletal examination revealed a moderate total lateral curvature of the spine to the right; tenderness over the third and fourth lumbar vertebræ, and over the condyles of right femur. There was tenderness also over the seventh and eighth ribs on left side, and under the pressure of the examining finger the seventh rib caved in with the feeling of crepitus.

The blood examination, made by Dr. Patterson, resulted as follows: Hæmoglobin, 75 per cent.; R.B.C., 3,172,000; W.B.C., 7,300. Differential count: Polynuclears, 63 per cent.; small mononuclears, 27 per cent.; large mononuclears, 10 per cent. No eosinophiles or myelocytes found in specimens examined. Red cells uniform in color but varied slightly in size and shape. One nucleated red seen.

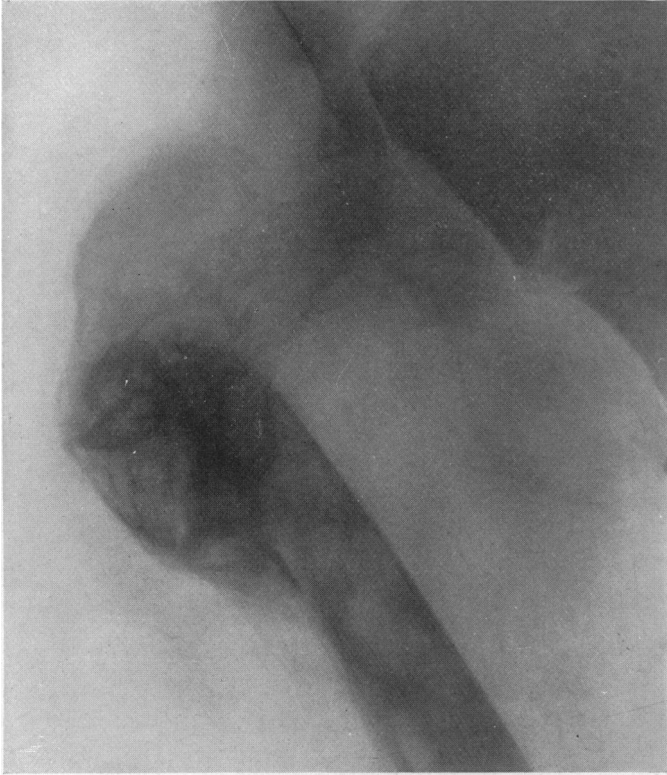Radiographs taken by Dr. Fleck show a fracture of the left femur (Fig. 1) about 4 inches below the trochanter, with considerable callus formation, overriding and angulation, also irregular areas of osteoporosis in the shaft and neck. The radiograph of the right hip (Fig. 2) shows a fracture just below the trochanter with the fragments united at a right angle; also honeycombing of the shaft, neck, and trochanter. Other exposures made reveal similar areas of softening in both fibulæ and two ribs.

Frequency of Carcinoma in Bone.—Von Recklinghausen, in 1891, was the first to make any careful study of carcinoma of bone. This he did in the course of his investigations upon cancer of the prostate. He noted, with surprise, the frequency and peculiarity of skeletal metastasis in prostatic carcinoma. He states that this discovery was accidental, due to the finding in one case of a small tumor of the frontal bone. Otherwise, he adds, the bones would not have been examined.

Kaufmann, who later investigated this subject, pointed out the fact that cancer of bones followed with surprising regularity cancer of the breast, thyroid and prostate; that in the great majority of cases it was secondary to carcinoma in one of these three structures; and that it never developed primarily in bone tissue. Limacher, who has studied the metastasis in mammary carcinoma, found the bones involved in 14 per cent. (1 in every 7 cases).

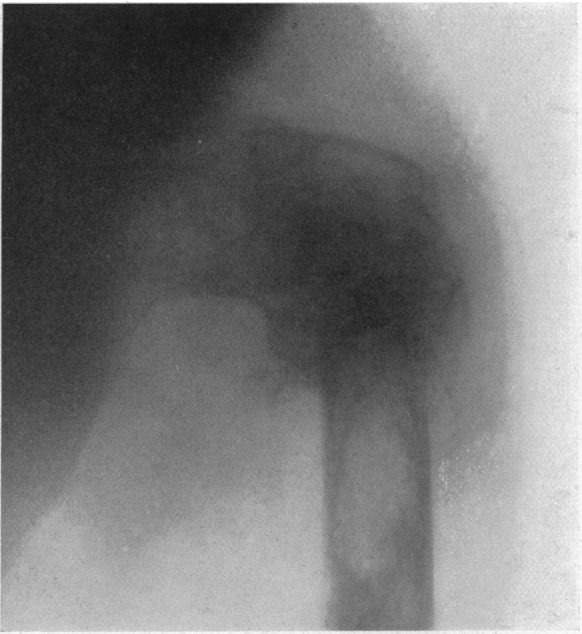Leuzinger, who has investigated bone lesions in cancer of the thyroid, found secondary deposits in the skeleton in 37 per cent. And Kaufmann, in his own 22 cases of prostatic cancer at the Basle Institute found bone metastasis in 16 (72 per cent.), and in his 100 collected cases, many of which were taken from the literature and lacked complete details, bone involvement was recorded in 34.

FIG. 1.

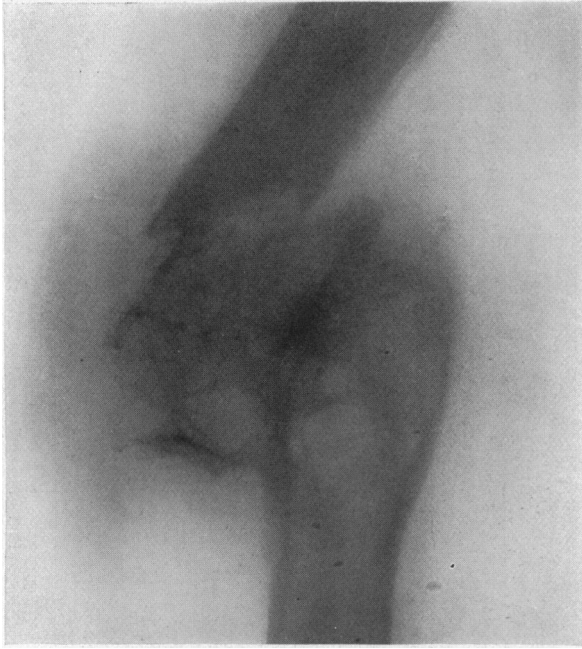

Radiograph by Dr. H. W. Fleck, from Saint Vincent's Hospital, Bridgeport. (Postero-anterior exposures of hips were made because of the apparent anterior position of the upper end of each femur.) Showing fracture about 4 inches below trochanter. There is considerable overriding of the fragments and some angulation. Areas of raffication are seen in the neck and throughout the callus, with larger areas in trochanter and shaft.

FIG. 2.



Radiograph of right hip by Dr. H. W. Fleck, from St. Vincent's Hospital, Bridgeport. (Same method of exposure as in Fig. 1). Showing fracture just below trochanter, overriding, and fragments united at an angle of 90° . Fine honeycombing in the neck with large areas of osteoporosis in shaft.



Case by Dr. W. P. Healy. Radiograph by Dr. L. G. Cole. Showing old fracture of left femur with callus, and recent fracture just above; also irregular areas of softening in the shaft and old callus.

FIG. 4.

FIG. 5.

FIG. 6.

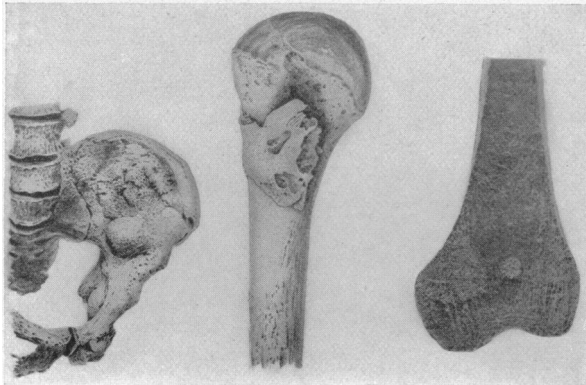


FIG. 4. Excessive osteoplastic "carcinose" of the pelvis. (After Kaufmann. Case VIII. From the collection in the Basel Pathological Institute). In this case the clinical diagnosis was carcinoma of the prostate and bones; the prostate was the size of a hen's egg and contained small cancer nodules, with metastases in pelvis, lumbar vertebræ, ribs, sternum, left femur, and right humerus.

FIG. 5. Unusual osteophytic outgrowth on the posterior surface of the left humerus. (After Kaufmann. Case V.—Basel Collection.) In this case the lumbar vertebræ, femur, sternum, and ribs were involved.

FIG. 6. An uncommon type of cancer deposit (solitary nodule) in the lower end of the right femur. (After Kaufman. Case III.—Basel Collection.) The symptoms in this case were pain in right leg and hip, and the clinical diagnosis was chronic rheumatism; the prostate was moderately enlarged inclosing two cancer nodes; carcinoma deposits in lumbar vertebræ, ribs, femur, humerus, tibia, and skull (osteoplastic).

FIG. 7.

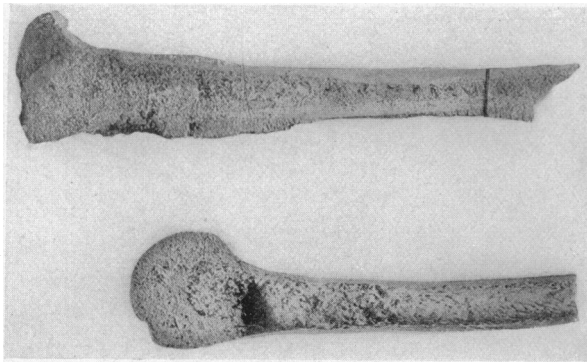


FIG. 8.

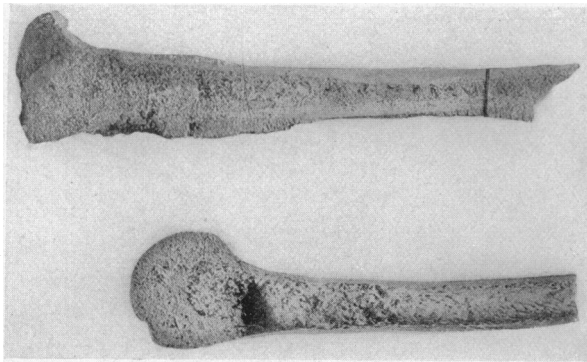


FIG. 7. Osteoplastic "carcinose" of the head and upper end of the right humerus, showing miliary osteoporosis in the head and neck, and small growths of new bone in the central canal. (After Kaufmann, Case III.—Basel Collection.)

FIG. 8. Osteoplastic "carcinose" in the right tibia—in part osteoplastic and part osteoclastic. (After Kaufmann. Case III.—Basel Collection.)

FIG. 9.

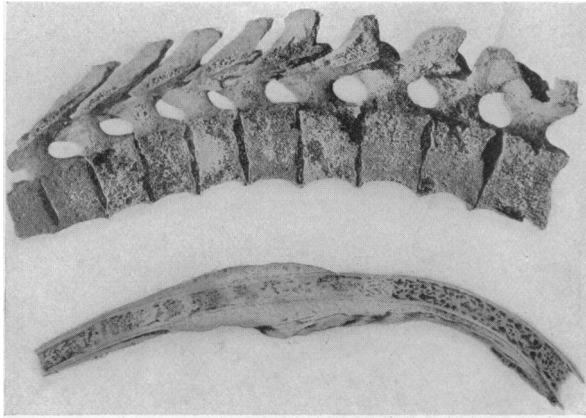


FIG. 10.



FIG. 9. Longitudinal section through a carcinomatous rib. (After Kaufmann. Case IX.—Basel Collection.) In this case metastases also in the pelvis, vertebrae, right femur, and right humerus.

FIG. 10. Part osteoclastic, part osteoplastic "carcinose" of the vertebrae—fifth dorsal to second lumbar. (After Kaufmann. Case VIII.—Basel Collection.)

Pathology.—Following von Recklinghausen's careful study of the pathology of carcinoma in the bones in five cases, Cone published in detail the post-mortem findings in a case taken from Halsted's clinic. Still later, Kaufmann made a comprehensive investigation of 34 cases. Although these were all cases of prostatic origin, Kaufmann found that the behavior of carcinoma in the bones is practically the same whether secondary to a growth in the breast, thyroid or prostate, or, as more rarely happens, from the uterus and stomach.

The work of these investigators has placed the pathology of this disease upon an intelligent basis. They found that invariably more than one bone was involved, usually six or eight, and that cancer with notable regularity invades certain bones. The favorite sites found were: The vertebræ (particularly the lumbar), the femur, ilium, ribs, sternum, humerus, skull, sacrum and tibia. Thus, Kaufmann in his 34 cases found the lumbar vertebræ involved in 27, the dorsal in 19, the femur in 23, the ilium in 21, the ribs in 19, the sternum in 12, and the skull in 11.

Von Recklinghausen found that the invasion began in marrow, which was usually found studded with nodules of cancer tissue. In the long bones these occurred most frequently in the expanded extremities; in the vertebræ throughout their bodies. This is in accord with the theory that the invasion of bone occurs via the blood stream, since Lexer has pointed out that the metaphyses are the most vascular parts of bone.

These cancer nodules usually found in groups, rarely attained any great size. Occasionally it was more miliary in character.

This invasion of the marrow leads to a low-grade osteoporosis (called by von Recklinghausen, "osteomalacia carcinomatosa") which often extends from the central canal to the periosteum, with nests of cancer cells scattered throughout the Haversian canals. Extension to the periosteum is productive of a fibroperiostitis with formation of new bone. New bone formation also occurs in the marrow. These two pro-

cesses, osteoclastic and osteoplastic, as a rule, are not productive of extensive alteration in the architecture of bone. Kaufmann remarks on the slow, restricted growth of this neoplastic disease. In the majority of his 34 cases the disease was usually limited to a comparatively small area in an otherwise healthy bone; only occasionally did the external surfaces show evidence of disease and then generally as a superficial, irregular deposit of new bone not unlike callus formation. The destructive lesion within usually showed localized areas of softening with some thinning of the external walls. In no case did he find penetration of the periosteum and extension into the soft parts or into a joint cavity. In only a few cases had spontaneous fracture occurred, and in only three were osseous tumors found of sufficient size to be detected clinically.

Grunert, in a comprehensive monograph on spontaneous fractures in which he mentions carcinoma and sarcoma of bone as common causes, describes the lesion as a general osteomalacia, a general diathesis of bone. He states that cancer tissue may or may not be found at the site of fractures; but he records only four cases, in which there is report of autopsy in only two, and in these the post-mortem examination appears to have been incomplete.

Symptoms.—I have been able to find but very little in the literature bearing directly on the symptomatology of this disease. What I have obtained has been gleaned from the histories of reported cases, in the majority of which the presence of bone disease was accidentally discovered at autopsy.

In almost all the cases pain has been a prominent symptom. In most instances the pain has been referred to the back, in many to the extremities, and in some it has been general. Usually it has been more or less constant and occasionally severe. Almost invariably, it has been called myalgia, lumbago, sciatica, or chronic rheumatism. This is illustrated in a case reported by Ganau, in which a man of 70 suffered pain in the sacrum and both legs. The clinical diagnosis was chronic rheumatism, but autopsy revealed carcinoma in the

lumbar vertebræ, ribs, femur and humerus, and small cancer nodules in a slightly enlarged prostate. In another case by von Frisch, pain in the back was treated for lumbago for several years, where post-mortem examination demonstrated deposits in the vertebræ, sternum and skull, secondary to a small cancer nodule in an atrophic prostate.

In some cases general bodily weakness has been a prominent feature. Occasionally it has been the principal subjective symptom. In the case reported here, the patient became so weak shortly after the onset of pain that she could hardly walk a few steps, although she had not then lost in weight.

Tenderness over bones has been reported in a few cases. Among Kaufmann's cases tenderness was noted over the spines of the vertebræ, also over the sternum, ribs, sacrum, and trochanter of the femur.

Gross tumors springing from the bones have been few. Out of his collection, Kaufmann reports but three. One was von Recklinghausen's case, which presented a small tumor of the frontal bone, another was a tumor of the ilium in which the clinical diagnosis was sarcoma, the third was Cone's case, in which a leg was amputated for a tumor of the tibia. Dr. J. C. Bloodgood, in a personal communication, mentions a case in which amputation at the shoulder joint was done for carcinoma of the humerus.

Spontaneous fractures do not occur as frequently as might be expected. Kaufmann found it in four out of thirty-four cases. In one a rib and femur were fractured, in another both clavicles. Grunert in his work on spontaneous fractures mentions four cases.

Skeletal deformities have not been recorded. I find few records of spinal curvature. Nor has spinal paralysis been reported except in a case of Burckhardt's; but in this case the disease was localized within the vertebræ and the paraplegia was due to a cancer nodule within the spinal dura. Bending and distortion of the bones, such as is seen in osteomalacia, I find mentioned in only a single case by Grunert, in which pathological fracture of the fourth rib occurred, and osteomalic

changes in the pelvic girdle were noticed six years after a breast amputation, but the only bones recorded as examined post mortem were the ribs.

Joint symptoms have not been reported.

The blood picture is said to be altered in bone cancer. This has been studied on thirteen cases by Kurjuweit, who believes that blood changes are early and frequent features. He found a myelocytosis most characteristic with nucleated red cells and poikilocytes. Similar observations have been made by Braun, Ehrlich, and Türk. This phenomenon has been explained by the suggestion that carcinoma of the bones is really a disease of the marrow, and that the changes in the bone cortex are the result of irritation.

So far as I have been able to determine, radiography of skeletal carcinoma has not been systematically studied. Dr. Cole, of New York, tells me that he recalls only one case, that of a woman, the patient of Dr. W. P. Healy, in which spontaneous fracture of the femur occurred, just above the site of a similar fracture a year previous and three years after the onset of a carcinoma of the breast. The radiograph (Fig. 3), kindly furnished me by Dr. Cole, shows honeycombing of the shaft in the region of the fracture, extending into the old callus.

Dr. Caldwell, of New York, informs me that he has not seen a case, unless it was in an elderly physician where the diagnosis was obscure. The radiograph kindly shown me by Dr. Caldwell exhibited a slight enlargement of the shaft of the humerus dotted with irregular areas of softening, similar areas in the ribs, and a single large spot in the acromion process of the scapula.

Dr. Pfahler of Philadelphia writes me that he has seen three or four cases following breast cancer. He says that there is usually a marked absorption of lime salts, that the areas are sharply defined as compared with syphilis, osteomyelitis or tuberculosis, and the outlines are more irregular than bone cysts. He adds that there is no marked periostitis.

Dr. Eastmond, of Brooklyn, in a personal communication states that he has studied three cases. He says that the

radiographic findings are essentially the same as those seen in any acute infection—a destruction of bone followed by the piling up of detritus. In the vertebræ, he says, the condition is similar to that seen in Pott's disease.

Rumpel, in his X-ray studies on tumors and inflammations of bones, published in 1908, includes three radiographs in three cases of bone cancer. In all his three cases distinct tumor was present (one of the fibula, one of the ulna, and one of the tibia). He states that the X-ray picture of carcinoma is not unlike that of central sarcoma.

The radiographs of the case I report (Figs. 1 and 2) show irregular areas of rarification throughout the shafts of both femora, in two ribs, and both fibulæ.

In the main, the lesions pictured in the bones by the X-ray correspond to the anatomic changes found by dissection, although, as Dr. Eastmond remarks, the number of cases examined has been too small to draw any definite conclusions. The cases which have been radiographed, undoubtedly represent exceptional cases. Naturally the cases most likely to come to the radiographer are those presenting tumor or fracture.

In six cases which I saw at post-mortem dissection at the Vienna Pathological Institute, there was no evidence of disease of the bones until their internal structure had been exposed.

In conclusion, it may be said that while this disease of bones presents a subject of academic interest, in that it has received little clinical consideration and is more common than generally believed, it also has points of practical significance, although no hope of cure can be expected in a malignant disease involving several bones, notwithstanding the fact that books on surgery of recent publication advise radical operation. In Cone's case a leg was amputated for a tumor of the tibia, in which carcinomatous deposits were also found in the vertebræ, two ribs, and ilium at autopsy.

This disease is of clinical interest in connection with that common group of cases labelled myalgia, lumbago, and chronic rheumatism. The majority of Kaufmann's cases were classed as "rheumatics." It will be a service if we can emancipate

another group of these so-called rheumatics from useless drugging. More of these victims should be submitted to X-ray examination. Dr. Eastmond states that in all his three cases the radiographic diagnosis was made accidentally, in two the examination being to determine the cause of pain in the extremities.

This disease has considerable significance in connection with fractures, especially those resulting from slight injury. In Dr. Healy's case, the earlier of the two fractures occurring in the same femur followed a minor injury, at which time Dr. W. T. Bull stated that the fracture was the result of a disease of the bone. It is of further interest to note that natural repair in these pathological fractures does occur. In Healy's case solid union took place in the first fracture. In one of Grunert's cases, a fracture of the tibia was entirely healed in two months. In the case I report, union is complete in both femora with excessive callus formation.

Skeletal carcinoma sometimes offers the first evidence of a primary neoplasm in the breast, thyroid or prostate. Thus, in Grunert's case, just mentioned, a tumor of the breast was not discovered till some time after the spontaneous fracture of the tibia. In another of his cases, pain in the bones, a small tumor of the skull, and pathological fracture of humerus and femur preceded the finding of a cancer of the thyroid. In Bloodgood's case, excision of the breast followed the amputation for cancer of the humerus. Kaufmann, as a result of his study of 100 cases of carcinoma of the prostate, states, "That the finding of metastases in the bones and lymph-glands is frequently the first evidence of a prostatic tumor." This is of peculiar interest since he has shown that cancer generally occurs as a small nodule in the hypertrophied, normal, or atrophic prostate; that it rarely grows to any appreciable size; and that it usually kills through its metastases in the bones or internal organs. According to Young cancer is found in 25 per cent. of enlarged prostates, and it is said that 34 per cent. of men past fifty have prostatic enlargement, though in only six per cent. does it cause urinary obstruction.

The relation of latent carcinoma in the bones to so-called

cures after radical operations upon the breast is an interesting question. On this point one of Grunert's cases is suggestive. In this case pain in the back and limbs occurred six years, spontaneous fracture and death eight years, after an apparent operative cure for mammary cancer. Dr. Eastmond tells me that all his patients were women upon whom excision of the breast had been done three to five years previously without recurrence at the site of operation.

LITERATURE.

1. Braun (L.): Ueber osteoplastisches Carcinom der Prostata, zugleich ein Beitrag zur Genese der perniciosen Anämie. *Weiner med. Wochensch.*, 1896, No. 13 and 14.
2. Bloodgood (J. C.): Review of Bone Tumors, in the *Progressive Medicine Series*.
3. Burckhardt (E.): Socin and Burckhardt's *Die Verletzungen und Krankheiten der Prostata*. Stuttgart, 1902.
4. Cone (S. M.): A Case of Carcinoma Metastasis in Bone from a Primary Tumor of the Prostate. *Bulletin of the Johns Hopkins Hospital*, May 1898, vol. ix.
5. von Frisch (A.): Frisch and Zuckerkandl's *Handbuch der Urologie*, 1905.
6. Goetsch (W.): Ueber den Einfluss von Carcinometastasen auf das Knochengewebe. *Zeigler's Beiträge z. pathologische Anat.*, Band 39, 1906.
7. Grunert: Ueber pathologische Frakturen (Spontan-Frakturen). *Deutsche Zeitschr. f. Chir.*, Band 76, 1905.
8. Kaufmann (E.): Die malignen Neubildungen der Prostata. Socin and Burckhardt's *Die Verletzungen und Krankheiten der Prostata*, 1902.
9. Kaufmann (E.): *Lehrbuch der Speciellen Pathologischen Anatomie*. Berlin 1901.
10. Kurjuweit (O.): Zur Diagnose von Knochenmarksmetastasen bei malignen Tumoren aus dem Blutbefund. *Arch. f. klin. Med.*, 1903. Band lxxii.
11. Lenzinger: Die Knochenmetastasen bei Krebs. *Ing.-Diss.*, Zurich, 1886.
12. Ritchie (J.): Carcinoma Metastases. *Edin. Med. Journ.*, xlii, 1892.
13. Rumpel (O.): Geschwulste und Entzündliche Erkrankungen der Knochen im Roentgenbild. Hamburg, 1908.
14. Sasse (F.): Ostitis Carcinomatosa bei Carcinom der Prostata. *Arch. f. klin. Chir.*, 1894, Band xlviii.
15. von Recklinghausen (F.): Die fibröse und deformirende Ostitis der Osteomalacie und die osteoplastischen Carcinome in ihren gegenseitigen Beziehungen. *Festsch. zu Virchow 71 Geburtstag*. Berlin, 1891.