

UNILATERAL LAMINECTOMY.*

BY ALFRED S. TAYLOR, M.D.,

OF NEW YORK,

Visiting Surgeon to Fordham Hospital; Attending Surgeon to New York City Children's Hospitals and Schools; Assistant Surgeon to the Babies' Hospital; Consulting Surgeon to Tarrytown (N. Y.) Hospital.

IN December, 1908, while considering the resection of posterior spinal roots, the thought suggested itself that a procedure less extensive and bloody than the usual bilateral laminectomy would be desirable.

A series of trials upon the cadaver made it evident that ample room could be had by unilateral laminectomy, not only for resection of nerve roots within the spinal dura, but for many of the other purposes for which the spinal canal is opened.

So far as I know the operation is original, and was first done upon the living subject on December 16, 1908, in a case of Dr. T. P. Prout's. Since that time occasion has arisen to use the same technic upon various parts of the spine in four other cases (five in all).

The operation is as follows: The patient is placed face downward, sometimes flat, sometimes with the body slightly tilted to one side. In the five cases operated upon ether has been used. The incision is made just to one side of the spinous processes, and of sufficient length for the purpose in hand. The knife is carried close to the sides of the spinous processes down to their bases. A broad deep retractor is used to pull the muscles outward (incidentally stopping hemorrhage) and the deeper layers of muscle are easily separated from the laminæ by a periosteal elevator. Gauze pads stuffed firmly into the wound and left for three minutes will give a dry field. When the pads are removed and the muscles well retracted, there are exposed the lateral surfaces of the spinous processes

* Read before the New York Neurological Society, December 7, 1909.

and the dorsal surfaces of the laminæ as far outward as the articular processes.

With a Doyen saw the laminæ are divided at their junction with the bases of the spinous processes, the line of section passing somewhat downward and inward (in the operating position). Another line of section is made well out toward the articular processes and is slanting like the preceding one (Figs. 5, 6 and 7). The laminæ vary in thickness in different parts of the spine, being thinnest in the cervical region, then increasingly thick downward through the dorsal and lumbar regions to the sacral region where they are as thin as in the cervical region (3 to 8 mm.). The saw has a guard by which the depth of the saw-line may be controlled. Moderate experience, however, teaches one to determine by the feel of the unguarded saw when it has divided the bone. This may seem a hazardous method, but the considerable fat layer surrounding the dura and the volume of spinal fluid within the dura eliminate any real danger to the cord if the saw is handled with nicety. Hemorrhage has not been a factor in the cases so far done.

After the sawing is completed, a thin periosteal elevator is slipped beneath the lowest lamina which is raised sufficiently for a bone forceps to grasp and remove it, care always being used not to tilt the fragments so as to endanger the cord. The remaining laminæ are lifted out with the forceps.

In cases where only a small exposure is needed, one lamina may be removed by the use of the saw, and the remaining ones cut away with special rongeurs (Figs. 1, 2, and 3). This method does not give so advantageous an exposure for the exploration of the other side of the canal, because so favorable a slant at the base of the spinous process cannot be obtained with the rongeur.

After removing the laminæ, the extradural layer of fat and veins is divided longitudinally in the middle of the wound, which is then gently packed with gauze to stop bleeding. After a few minutes the gauze is removed and the shiny dura is exposed in the bottom of the wound (Fig. 8).

The dura is divided longitudinally. First a short slit is made with a pointed knife to let the spinal fluid, which spurts

FIG. 1.

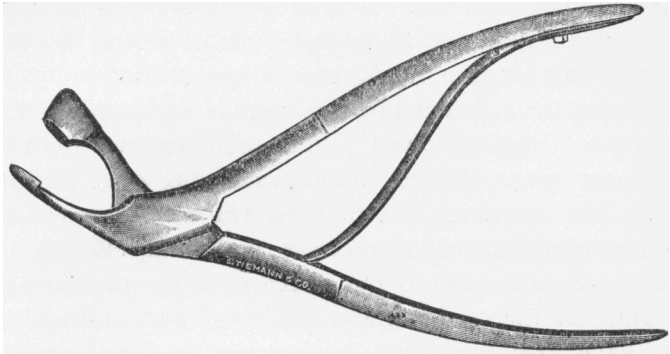


FIG. 2.

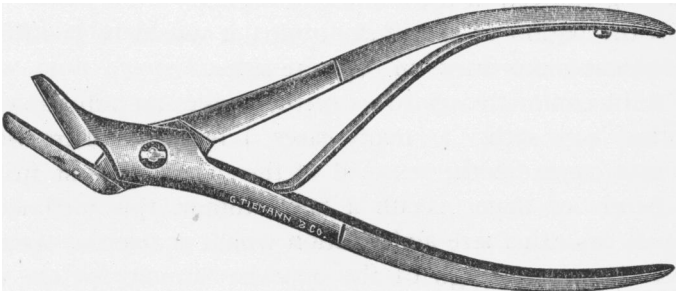
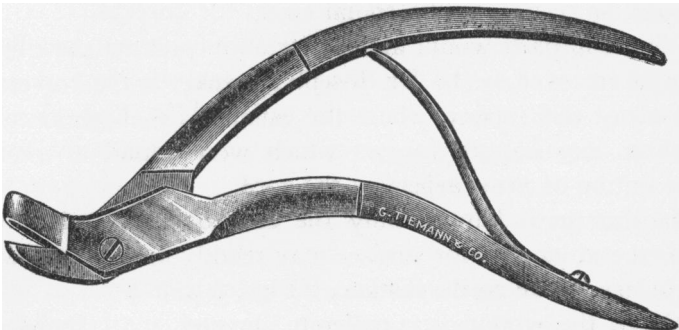


FIG. 3.



out, escape slowly. The division of the dura is completed with scissors, exposing the cord and nerve roots for whatever surgical attack is contemplated. Afterward the dura is closed

with a continuous catgut suture; the muscles are sutured to the interspinous tissues with chromic gut; the aponeurosis is closed with chromic gut; and the skin with silk.

No drainage is used. A firm sterile dressing is fastened by adhesive straps and a bandage. The patient lies mostly upon the sides or face during the healing process.

The exposure obtained by this method varies in width with the portion of spine involved. In the adult cadaver the following spaces were obtained: midcervical, $1\frac{3}{4}$ cm.; middorsal, 1 cm.; midlumbar, 1.3 cm. or even $1\frac{1}{2}$ cm., by encroaching somewhat on the articular processes; midsacral, $1\frac{1}{2}$ cm.

This approach permits the resection of the nerve roots on both sides of the cord without injury to the cord substance. This I have done upon the cadaver many times, and once upon the living subject, in the middorsal region.

In the region of the cauda equina it would be possible to anastomose motor roots of opposite sides.

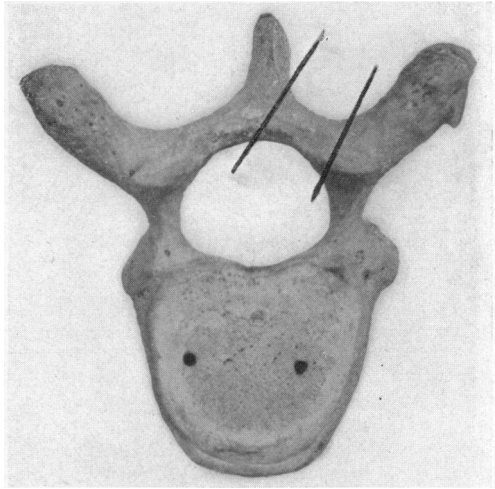
In tumors of the cord this method gives an admirable exploratory approach. In many cases, I feel sure, there would be ample room for the removal of the tumor without further destruction of bone. With a large tumor, this method, by exposing its exact size and location would enable the operator to remove just enough of the opposite laminae for the easy extirpation of the tumor, and would thus minimize the loss of bony protection to the spinal cord.

This approach would almost certainly prevent the mishap reported in two cases by Dr. Joseph Fraenkel at the November meeting of this society, where the usual bilateral laminectomy failed to expose cord tumors which were found at autopsy to lie on the anterior aspect of the cord.

In unilateral laminectomy the side of the cord is well exposed and its anterior surface may readily be explored without injury to the cord substance (Figs. 8 and 9).

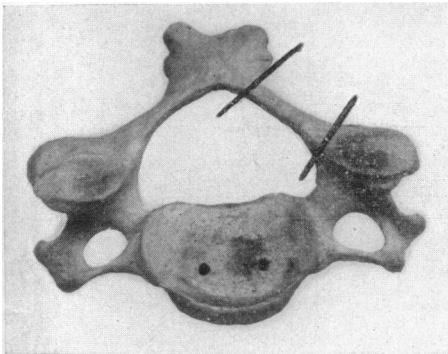
When the wound is completely sutured, the spinous processes are in their normal positions, there is no visible or palpable deformity of the back, and, because of the thick muscle pad overlying the laminae, no form of examination, other than

FIG. 6.



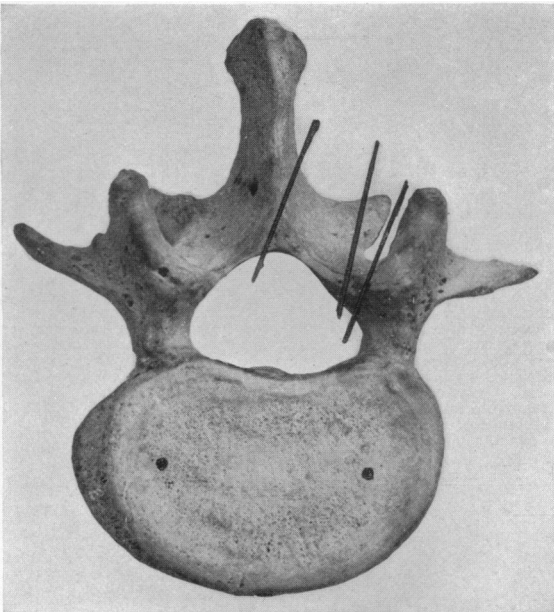
Seventh dorsal vertebra.

FIG. 5.



Fourth cervical vertebra.

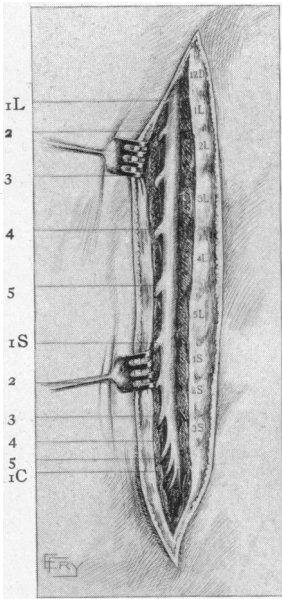
FIG. 7.



Third lumbar vertebra.

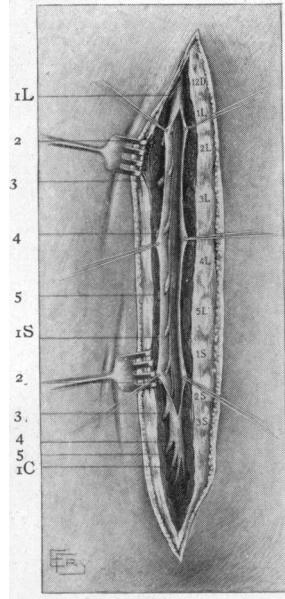
These vertebrae are life size, but come from a spinal column smaller than the average. The ink lines indicate the usual slant and position of the saw cuts. In Fig. 7 the outer cut is used when the articular process is sacrificed to gain more room. The laminae in Figs. 6 and 7 are not so thick as they seem, because they are not photographed on edge.

FIG. 8.



Drawing from a dissection, showing unilateral laminectomy in the lumbar and sacral vertebrae. In this case the articular processes were encroached upon as in the outer line of section Fig. 7. The spines of the vertebrae are numbered on the right and the nerve roots on the left in the drawing. The artist has placed the roots a little too high to correspond properly with the spinous processes. The free view of the cord and the ease of exploring its lateral and anterior aspects is evident.

FIG. 9.



Same as Fig. 8, with the dura opened longitudinally. The same remarks apply to the relations of the roots to the spinous processes. Also the lower end of the cord itself should show at the level of the second lumbar spinous process. The cauda equina is easy to manipulate because of the length of its component bundles.

FIG. 10.

FIG. 11.

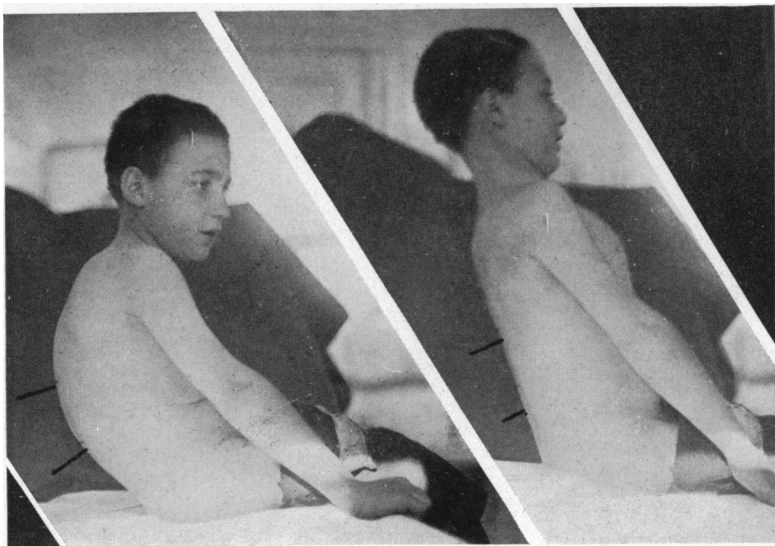
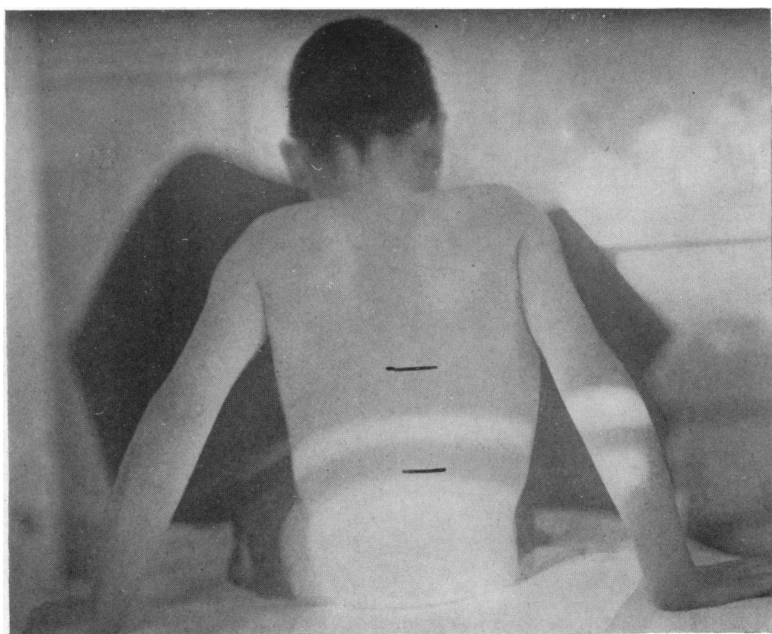

FIG. 12.



Case II. Boy, eight years old. Three months after operation.—Figures 10, 11 and 12 show the postoperative flexibility of the spine. The laminae removed lie between the ink marks. In Fig. 12 the dorsal linear scar shows faintly.

FIG. 13.

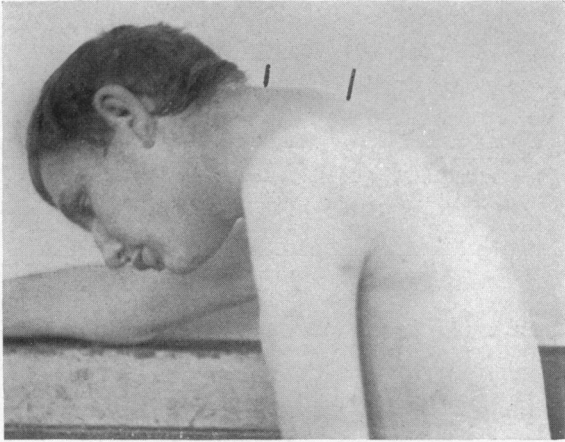
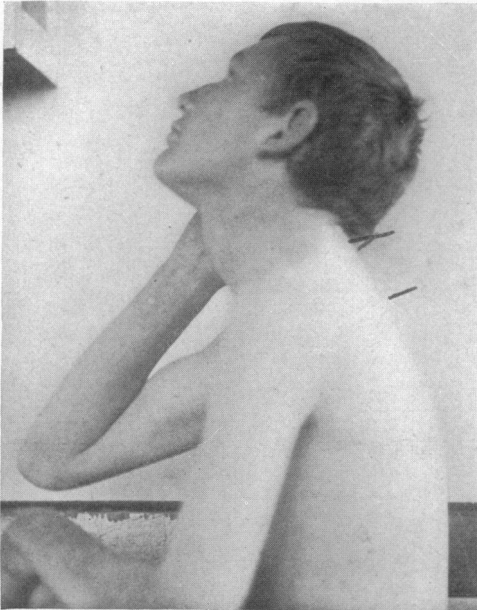

FIG. 14.



Case III. Boy, 17 years old. Eleven days after operation.—Figures 13 and 14 show the postoperative flexibility of the spine. The laminae removed are indicated by the ink marks.

the X-ray, can determine the loss of bone. The cord, therefore suffers practically no loss of protection.

In all of the cases so far done (five in number) there has been little or no shock, primary union has resulted, and there has been no loss of flexibility of the spine (Figs. 10 to 14 inclusive).

Much has been said of the dangers of allowing the spinal fluid to escape. In these cases it has escaped freely (6 to 12 ounces in different cases, estimated) and yet there has been little or no shock, and convalescence has been uneventful, so that the causes of the complications reported should, perhaps, be sought for elsewhere.

Systematic records of blood pressure, pulse and respiration during operation have not been kept. At the last operation Dr. Creevey noted that when the dura was first opened and the spinal fluid spurted out, there were one or two deep respirations, after which the breathing continued as before. There was no change in the pulse.

The neurological results in these cases will be reported at a later time by the neurologists for whom the operations were done.

The advantages of unilateral laminectomy are believed to be: Minimum loss of blood and of bone; and therefore minimum loss of bony protection to the cord. No postoperative deformity of the back or loss of flexibility of the spine. Exposure sufficient for all exploratory work except in certain cases of fracture of the spine; for all nerve root work on one or both sides; for the removal of many tumors, and for minimizing the operative trauma in others by first exposing their exact size and location. Exposure such as to diminish the chance of overlooking an anterior tumor.