

**A FURTHER NOTE ON THE CLINICAL USE OF
SCARLET RED AND ITS COMPONENT, AMIDO-
AZOTOLUOL, IN STIMULATING THE EPITHE-
LIATION OF GRANULATING SURFACES.***

BY JOHN STAIGE DAVIS, M.D.,

OF BALTIMORE,

Instructor in Surgery, Johns Hopkins University; Assistant Surgeon, Out-
Patient Department of the Johns Hopkins Hospital.

Introduction.—In a paper published in the *Johns Hopkins Bulletin*, in June, 1909, and in the *ANNALS OF SURGERY* of January, 1910, I reported the results of my observations during the treatment of 60 cases with scarlet red in various combinations.

Since that time I have been impressed by the great interest in the clinical use of this dyestuff by the large number of papers on this subject which have appeared in the foreign journals, and also by a number of personal communications reporting favorable results.

The object of this article is to bring this subject up to date as far as possible, and in addition to make a few observations on the clinical use of amidoazotoluol, which was first tried by Hayward²² and is a component of the scarlet red originally used by Fischer.¹⁴

I was very skeptical when I began to experiment with scarlet red. It was difficult to believe that by the application of a commercial dyestuff such rapid epithelial stimulation could take place in sluggish wounds, some of which had been unhealed for many years.

It has been suggested that possibly the wounds healed with scarlet red were in a period of development in which, after being inactive for a longer or shorter time, the rapid epithelial growth would have taken place just as well under any other method of dressing. This may be true in a few instances, but I hardly believe it could have been the case in the large number of cases reported, where the process of healing had been at a stand-still until this dressing was begun.

* Read before the Johns Hopkins Medical Society, April 3, 1911.

Carrel, in his very interesting article on "The Treatment of Wounds" (*Jour. Amer. Med. Assoc.*, December 17, 1910, p. 2148), says that when at the end of the period of "granulous retraction" of a large wound the edges of the old epidermis are still at a distance of 20-25 mm., the new epidermis cannot spread on the granulations and the cicatrization of the wound comes to a stand-still.

Now, in practically all of the wounds which I have treated with scarlet red and amidoazotoluol, the period of "granulous retraction" had long since ceased, the period of epidermization had also come to a stand-still, and the areas were, for the most part, very large. In spite of these facts, in the large majority of cases there was marked epithelial stimulation from the hitherto sluggish edges following the application of the dyestuff, and subsequent rapid healing.

Scarlet red was used exclusively as a dye until 1900, when Michealis⁸⁴ found that this coloring matter was very suitable for staining fat in the cellular tissue for microscopic examination.

Experimental Use.—B. Fischer,¹⁴ in 1906, in a paper on the "Experimental Generation of Atypical Epithelial Proliferation," produced by the subcutaneous injection of a saturated solution of scarlet red, in olive oil, in a rabbit's ear, first called attention to the remarkable stimulating properties of this dyestuff, and suggested that therapeutic advantage might be taken of it. Since his publication a number of investigators (Ritter,⁴² Jores,²⁷ Geipel,¹⁵ Snow,⁴⁹ Stahr,⁵² Wyss,⁵⁹ Helmholtz,²³ McConnell,⁸² Seckel,⁴⁷ Hertzler,²⁴ Schreiber and Wengler,⁴⁵ Werner,⁵⁶ Enroth,¹³ Stoeber,⁵⁴ Grimani,¹⁷ Dixon,⁹ Cords,⁷ Meyer,³³ Borst,³ Wessley,⁵⁷ following Fischer's lead, have repeated his experiments and extended them. As far as I can ascertain all, with the exception of Snow, have agreed that a new growth of epithelium is produced.

Several kinds of animals have been used, rabbits, Belgian hares, guinea pigs, white rats, mice, monkeys, dogs, cats, etc. These proliferations have also been produced in man. Wessley⁵⁷ experimented on himself and Stoeber⁵⁴ upon a man

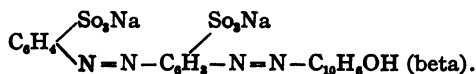
80 years old, whose leg was to be amputated for ununited fracture. The results were not as marked as in the rabbit's ear, on account of anatomical conditions, but were definitely positive. Stoeber injected scarlet red, amidoazotoluol and α -naphthylamin, but did not succeed in producing epithelial proliferation by α -naphthylamin. It is beyond the scope of this paper to discuss the theories as to the cause and source of these atypical epithelial proliferations.

An interesting point is made by Claribel Cone,⁶ who says that in the epidermis of man the fat which is shown by the scarlet red stain is especially noted in the basal (germinal) layer at the point of contact of the cell body and nucleus; in other words that the scarlet red attacks the living cell just at the point where physiological cell changes are most active. She suggests that this may cause a chemical or physical stimulation to the cell, and thus account for the active proliferation following its clinical use.

Chemistry.—In looking over the literature on the clinical and experimental use of scarlet red, I find that there are several chemically different dyestuffs which are marketed under the name scarlet red. I will consider the chemical formulæ of four of these.

1. The dye used in my series was the sodium salt of diazoazobenzene-disulphonic acid β -naphthol.


Commercial Names.—Biebrich Scarlet; Pouceau 3 RB; Pouceau B; Fast Pouceau B; New Red L; Imperial Scarlet. (Schultz and Julius⁴ (Green), 1904, p. 110, No. 163.)



Method of Preparation.—Amidoazobenzene-disulphonic acid and β -naphthol. It is a red powder, soluble in water and slightly soluble in alcohol. Insoluble in ether.

2. Benzeneazobenzeneazo β -naphthol.

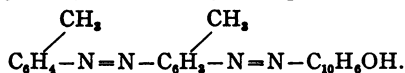
Commercial Names.—Soudan III; Cerasine Red. (Schultz and Julius, p. 106, No. 143.)



Method of Preparation.—Amidoazobenzene and β -naphthol. It is a brown powder, soluble in alcohol and fats. Insoluble in water.

3. Tolueneazotolueneazo β -naphthol. This is the scarlet red originally used by Fischer¹⁴ and Schmieden.⁴⁴

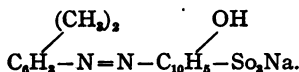Commercial Names.—Oil Scarlet; Red B Oil Soluble Extra-concentrated; Pouceau 3 B. (Schultz and Julius, p. 108, No. 150.)



Method of Preparation.—Amidoazoorthotoluene and β -naphthol. It is a dark reddish-brown powder which cakes at about 175° C. and melts at 184° to 186°. Insoluble in water, soluble in alcohol and chloroform, fats, fatty oils, and also warmed vaseline and paraffine.

4. Sodium salt of xyleneazo β -naphthol monosulphonic acid.

Commercial Names.—Scarlet GR; Scarlet R; Brilliant Orange R; Orange L. (Schultz and Julius, p. 86, No. 54.)

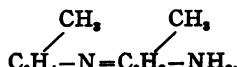


Method of Preparation.—Xylidene and β -naphthol monosulphonic acid. It is a cinnibar red powder, soluble in water.

I have used clinically the first three of these preparations with success, and also a xylidene scarlet (Schultz and Julius, p. 86, No. 55), which is closely related to the fourth preparation. I find the best and most consistent results with scarlet red have followed the use of the dyestuff originally employed by Fischer¹⁴ and Schmieden.⁴⁴ Hayward²² says that in the few cases reported where no result was attained, this special dye was probably not used. Hayward has also experimented with Soudan I, Soudan IV and Soudan G, with more or less success.

He says that Fischer and Schmieden thought that α -naphthylamin caused the epithelial stimulation in the most far-reaching way. Hayward used this substance clinically, and found that it caused only marked irritation. This was also my experience when I used β -naphthol ointment of a strength corresponding to that actually entering into the formation of 8 per cent. scarlet red, *i.e.*, 2.4 per cent.

Experimenting further, Hayward employed amidoazotoluol, the other component of scarlet red, and found that this substance caused a more marked stimulating effect on the growth of epithelium than did the scarlet red.



Method of Preparation.—Slowly add a saturated solution of sodium nitrate (1 mol.) to a mixture of orthotoluidine (4 mols.) and concentrated hydrochloric acid (2 mols.) and keep at a temperature of 30° to 40°. It is a reddish-brown granular powder. Melting point about 100°. Nearly insoluble in water but easily soluble in alcohol and ether.

Clinical Use.—A few words concerning the papers on the clinical use of these substances may be of interest.

Schmieden⁴⁴ was the first to follow Fischer's¹⁴ suggestion that scarlet red be used therapeutically, and in February, 1908, published a paper on his clinical results, which were very favorable. He reported rapid healing on sluggish ulcers of various kinds and in different situations. He used 8 per cent. ointment and alternated the dressing every 24 hours with some bland ointment on account of the irritating properties of the scarlet red. He also used with success adhesive plaster impregnated with 10 per cent. scarlet red for strapping leg ulcers.

He insisted that the granulations must be perfectly clean and flat, and said that it was useless to apply the ointment to an unclean ulcer. He noted that there was little chance of cicatricial contraction under this healing, and showed by microscopic examination that the newly-formed skin was the same as the normal skin.

In May, 1908, Kaehler²⁸ substantiated Schmieden's work and modified his technic. He found good results could also be obtained when scarlet red was used on unhealthy granulating wounds. He healed a varicose ulcer with scarlet red, and then was able to thoroughly clean up this new skin and operate through it for excision of varicose veins, thus showing the stability and quality of the newly-formed epithelium. He completely healed defects of similar size, one with grafts and one with scarlet red, in exactly the same time.

Krajča,³⁰ in September, 1908, described further good results. He was the first to use scarlet red in conjunction with Thiersch grafts, and found that the edges of the grafts were stimulated as well as the wound edges. He mentions a number of interesting cases. Some of the ulcers, although of large size, healed in a very short time under this treatment. He found the cutaneous irritation due to the scarlet red to be the exception rather than the rule.

Enderlen,¹² in September, 1908, published very satisfactory results, as did Cernezzì⁵ and Hübner,²⁶ in February, 1909. Wolfrom and Cords⁵⁸ in the same month wrote on the successful treatment of ulcers and wounds of the cornea by 5 per cent. scarlet red salve. Excellent results were obtained in a case of keratitis neuroparalytica. An old corneal fistula was closed by this means. A more rapid regeneration of the tissues was noted and sometimes an excess of tissue formation, but this soon flattened.

Sprecher,⁵¹ in March, 1909, reported good results in the treatment of ulcerated lupus vulgaris, ulcers of prepuce, vulva, labia, and cervix, varicose leg ulcers, syphilitic ulcers, ulcers of the breast, etc. He did not observe any local irritation or toxic effect in his series.

Rebaudi,⁴⁰ in April, 1909, described the use of scarlet red in gynæcological conditions, and obtained excellent results in the treatment of erosions, tears, etc.

Pleth and Pleth,³⁸ in May, 1909, detailed the successful use of scarlet red on ulcers of various kinds. Hermann,²⁵ in June, 1909, reported the success of his treatment with scarlet red of tympanic membrane perforations. He said the duration of the perforation seemingly had no effect on the rapidity of the healing. Suppuration did not appear during this treatment.

Ducros,¹¹ in July, 1909, reported favorable results on granulating wounds, as did Morawetz,³⁵ in September of the same year. Hayward²² wrote in the same month concerning the use of an 8 per cent. ointment of amidoazotoluol, which is, as we have mentioned before, a component of the scarlet red used by Fischer.¹⁴ His results on a number of granulating wounds were even more favorable than with the scarlet red, and he felt convinced that this was the stimulating portion of the dyestuff.

It does not seem possible that amidoazotoluol is alone responsible for the epithelial stimulation, as a number of observers, myself included, have noted very favorable results produced by the clinical use of dyestuffs which do not contain amidoazotoluol.

Grossmann,¹⁸ in December, 1909, reported favorable results with scarlet red salve, amidoazotoluol ointment, and amidoazotoluol gauze, in the treatment of wounds following operations on the nasal passages, and in perforated tympanic membranes. Halle²⁰ and also Levy⁸¹ said that they had been successful in similar cases with the scarlet red.

Hartmann²¹ and Beyer² stated at the same meeting that they had used scarlet red in a small number of cases without any particular success. Sonntag⁵⁰ and Brühl⁴ said they had failed to get rapid results in similar cases.

Auerbach,¹ in 1909, published a number of successful results in the treatment of ulcers occurring in skin and venereal diseases, varicose ulcers, etc. He was unsuccessful in only one case, a multiple leg ulcer which was complicated by extensive varices. The other leg of this patient had been previously amputated for leg ulcer. He used the treatment with success on wounds which were discharging copious purulent secretions. He had irritation with 8 per cent. scarlet red, so tried 4 per cent., which he found could be used continuously. Dauthuile⁸ also reported favorable results.

The papers which have appeared in 1910 are as follows: Rammstedt and Jacobsthal⁸⁹ mentioned excellent results in the healing of ulcers due to X-ray burns. Dreifuss¹⁰ reported favorable results in the treatment of granulating wounds. Cords⁷ said it was of use in the eye only in clean ulcers of the cornea, especially if there was deep loss of substance.

Pein³⁷ detailed a number of cases successfully treated with scarlet red, and gave a very interesting table of the measurements, taken from 25 leg ulcers, from the beginning of the treatment to the time of healing.

Strauss⁵⁵ published his very favorable results in the treatment of X-ray burns and other ulcers of various kinds. He says he does not value the use of scarlet red for the rapidity of epitheliation alone, which in some cases does away with the necessity of Thiersch grafting, but for the solid epithelium, which is of great value, especially in the region of the joints. By this healing, contractions and scar tensions can be avoided. Stein⁵⁸ reported good results in otiatrics. Scharezki⁴⁸ was

very successful in the treatment of skin defects of various kinds.

Katz²⁹ reported favorable results with 8 per cent. scarlet red and amidoazotoluol. Simin⁴⁸ had excellent results following the use of scarlet red.

Nance (*Jour. of Ophthalmology and Oto-Laryngology*, Feb., 1911, p. 41), reported very favorable results with scarlet red in the treatment of corneal defects.

It can be seen from the above that by the use of scarlet red and amidoazotoluol very satisfactory results have been obtained. The tone of nearly all of these papers has been enthusiastic, and the only unfavorable results are those reported by Hartmann²¹ and Beyer,² Sonntag⁵⁰ and Brühl.⁴ All of these were in aural cases.

Since the publication of my paper, I have continued to use scarlet red on a number of other cases with almost uniform success, and have little to add to the technic described at that time.

I find marked epithelial stimulation even when the wounds are unhealthy and the discharge is profuse. This has also been the experience of Kaehler²⁸ and Auerbach,¹ although nearly all the other writers, beginning with Schmieden, have stated that it is useless to apply the scarlet red ointment to any but a perfectly clean granulating wound. Of course the most rapid results are obtained on flat, healthy, granulating surfaces, but a great deal of progress can be made by its use while the granulations are being brought into this condition.

Strauss⁵⁵ objects to the use of scarlet red put up in balsam of Peru ointment, blue ointment, iodoform ointment, etc., as recommended by me, in the treatment of unhealthy granulating wounds, on the ground that the ointment is of no use on such ulcers, but my experience has evidently been very different from his. I consider the use of such combinations to be of value in the treatment of unhealthy granulating wounds, as the scarlet red in itself has no antiseptic qualities, and the cleansing process due to the balsam of Peru, etc., can in this way be carried on while the scarlet red is being used, as well as by the alternating dressing.

Technic.—An outline of the technic will suffice. Cleanse

the wound thoroughly with boric or salt solution and dry. Peroxide of hydrogen may be used before the boric solution if the granulations are unhealthy. The free use of nitrate of silver stick is advised to keep down exuberant granulations. Tincture of iodine, U.S.P. strength, may follow the silver nitrate or be used on alternating days, and is a powerful and rapid method of cleansing granulations.

The strength of the scarlet red ointment ordinarily used is 8 per cent., and it should be alternated every 24 to 48 hours with some bland ointment. By applying a weaker ointment, say 4 per cent., it can be used over longer periods without danger of the severe irritation which occasionally occurs.

The most satisfactory method of applying the ointment is as follows: Anoint the skin surrounding the defect with some bland ointment up to about one centimetre of the wound edge, as this prevents possible irritation. Then spread the scarlet red ointment in a thin layer on perforated old linen and apply to the wound, either along the edges or over the whole surface. A light dressing of sterile gauze secured by a bandage completes the procedure.

I have applied the scarlet red ointment to a number of wounds and then exposed them to the air and sunlight. The healing is very rapid and the drying out of the surface is most noticeable.

It is safe to use a 4 per cent. scarlet red ointment on partial skin grafts of all kinds 48 hours after grafting, and there is rapid stimulation of the wound edges and also of the grafts themselves.

Case Reports.—I will mention only one case to illustrate the efficacy of scarlet red:

A very feeble old lady, eighty-four years old, was badly burned across the shoulders six weeks before she came under my care. During that time she had been carefully treated by her family physician with the usual methods. The wounds had done well for several weeks, and then had become sluggish and no further progress could be made. The patient's general condition was bad on account of a weak heart and chronic nephritis, and was becoming serious under the strain. I was called to consider the advisability of grafting.

There were three ulcers, one over the right scapula, 5 x 10 cm., another over the left scapula, 5 x 8 cm., and a third ulcer 8 x 10 cm. situated in the midline between the other two. Those over the scapulæ were covered with clean but œdematous granulations, which had not yet reached the level of the skin. The central wound was still covered, to a large extent, by a slough which was made up of the whole thickness of the skin and some subcutaneous tissue. The epithelial edges of these ulcers were very sluggish.

On account of the condition of the patient and the situation of the wounds, I decided to try scarlet red instead of grafting.

November 26-27, 1910: The wounds were dressed with a balsam of Peru and castor oil mixture, 2 to 6.

November 28: Scarlet red, 8 per cent., was applied, and thereafter every third day, alternating with boric ointment.

December 7: The last of the slough was removed. December 16: The wound over the left scapula was healed. December 23: The central wound was healed. December 25: The wound over the right scapula was healed.

During the treatment the patient was in a critical condition almost continuously, and had to be strongly stimulated in order to preserve life.

The case is instructive from the fact that old age and great debility seem to have little deterrent effect on the stimulating power of scarlet red. The skin edges were stimulated in spite of the presence of a slough in the central wound. It was only necessary to use the scarlet red ointment in nine dressings to complete the healing. The result was a firm, thick, and stable skin, which showed no tendency to contract.

After the appearance of Hayward's²² paper on the efficacy of amidoazotoluol, I had the opportunity of using this substance on a number of granulating wounds of varying etiology. The results have been excellent.

Calculating the amount of amidoazotoluol in scarlet red from the molecular weights, we find that there is 3.76 per cent. of amidoazotoluol in an 8 per cent. scarlet red ointment. I have used this strength as well as 8 per cent. in simple vaseline, and also in the balsam of Peru and other ointments suggested earlier in the paper. I will illustrate the efficacy of amidoazotoluol by briefly reporting two cases.

CASE I.—A boy, fourteen years old, fell into the fire while in an epileptic attack and was severely burned. He was admitted to the hospital and was much improved, during his five months' stay, by grafting and various other methods. He was then sent to the Out-Patient Department for dressing, and as no further progress was made in the healing, he was referred to me eight months after the accident.

The size of the unhealed areas at this time can be well made out in the illustrations. The wounds were covered with very exuberant granulations which secreted actively. The epithelial edges were at a stand-still. The patient refused to be grafted, and it was decided to try 8 per cent. amidoazotoluol ointment. The granulations were trimmed off with scissors, then cauterized with silver nitrate, and this was followed by tincture of iodine. This procedure was carried out whenever necessary throughout the treatment.

February 24, 1910 (Fig. 1): All of the ulcers were dressed with amidoazotoluol ointment and this was alternated every 24 to 48 hours with balsam of Peru and oil, zinc oxide, or boric ointment. A stimulation of the epithelial edges was noticeable within 48 hours.

After the first dressing of the large areas with amidoazotoluol, a temporary change of color was noticed in the urine. The patient was dressed at 5 P.M. and the urine voided was as follows: February 24, 6.40 P.M., watery, 500 c.c.; 9.30 P.M., light lemon, 450 c.c.; February 25, 4.30 A.M., *amber*, 430 c.c.; 7.50 A.M., *reddish brown*, 240 c.c.; 11 A.M., *reddish brown, slightly darker*, 80 c.c.; 2.30 P.M., watery, 280 c.c.; 5.55 P.M., watery, 200 c.c.; 7 P.M., watery, 360 c.c. Otherwise the urine was negative. The subsequent dressings did not cause a change in the color of the urine.

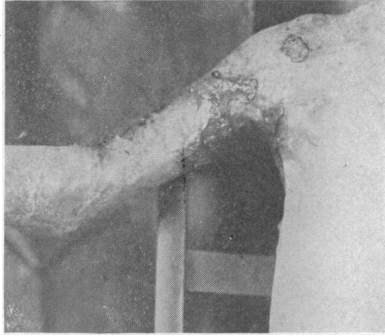
May 9: The patient was discharged entirely healed. The healing was firm, thick, and looked like normal skin. Examination of this patient six months later showed a firm, movable skin, with normal sensation and no tendency to contraction.

CASE II.—A man, thirty years old, was severely burned by an explosion of oil. He came under my care on May 5, six months after the accident, and one of the unhealed areas is well shown in the figure. This wound had improved for a time and then had become sluggish, and apparently no further progress could be made from the epithelial edges. Several unsuccessful graftings had been previously done.

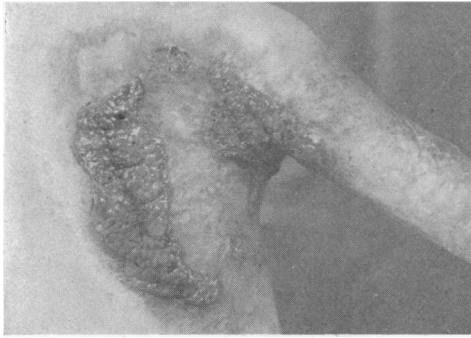The wound was covered with œdematous exuberant granula-

FIG. 1.

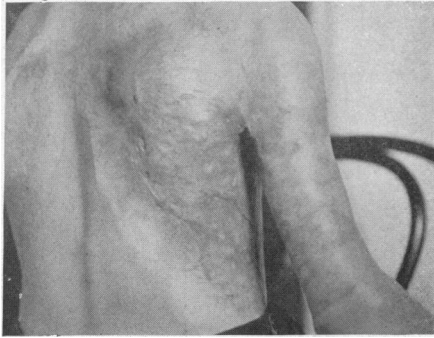
a.



b.

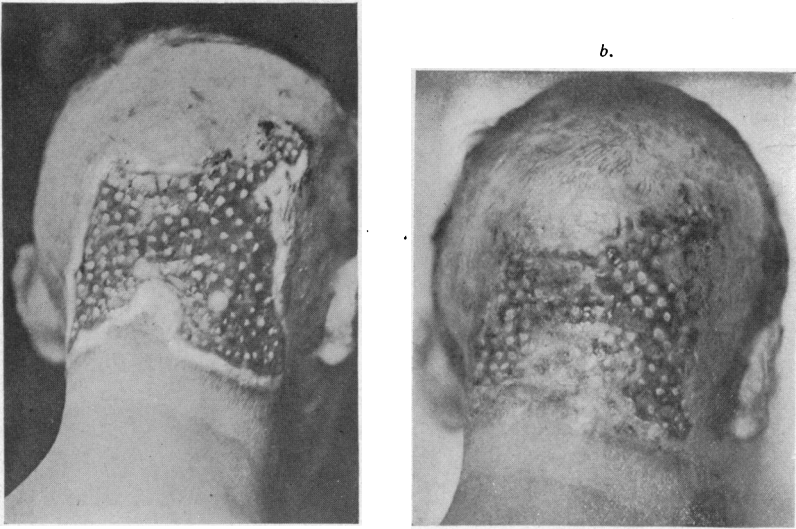


c.



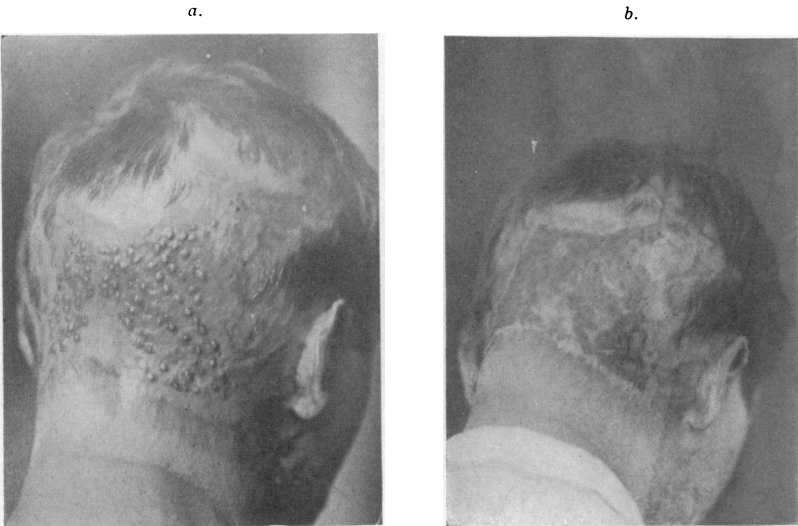
Case I. Sluggish ulcers following burn. Healed with amidoazotoluol. *a, b*, taken February 24, 1910, eight months after the accident. The ulcers are surrounded by scar tissue. There is partial web formation in the axilla. The exuberant granulations and sluggish wound edges can be well seen. *c*, taken May 9, 1910. Shows the character of the healing. There is no tendency to contraction. The web formation is less marked.

FIG. 2.



Case II. Sluggish ulcer following burn. Healed with small deep grafts and amidoazotoluol. *a*, taken May 30, 1910, six months after the accident. The ulcer is surrounded by scar tissue. The small deep grafts applied May 28 have all taken and the wound edges have begun to spread. *b*, taken June 4, 1910. Shows the very rapid epithelial stimulation from the grafts and wound edges after two dressings with amidoazotoluol. The entire wound is healed with the exception of a few small areas, whose aggregate size is not larger than a ten cent piece.

FIG. 3.



Case II. *a*, taken June 24, 1910. Shows the remarkable thickening of the grafts, which project like little warts above the skin level. *b*, taken August 9, 1910. The grafts have assumed the level of the surrounding skin. Considerable pigmentation can be seen in the healed area surrounding the grafts.

tions which were exquisitely tender. An effort was made to put the granulations in a healthy condition as soon as possible. Toward the end of this process 4 per cent. amidoazotoluol ointment was used as a dressing, and was followed by marked stimulation of the edges.

On account of the tenderness it was decided to graft. The patient refused to allow Thiersch or whole thickness grafts to be cut.

May 28: The granulations being in good condition, a number of small deep grafts were taken from the thigh under local anesthesia and transplanted on the undisturbed granulations. The grafts were dressed with narrow overlapping strips of protective, over which was placed a dry dressing.

May 30: The dressing was changed, and all the grafts were found to have taken (Fig. 2, *a*).

June 1: The grafts were dressed with 4 per cent. amidoazotoluol on old linen. When the dressing was removed 48 hours later it was noted that the grafts were markedly stimulated. Dressed with boric ointment.

June 4: The entire wound, with the exception of one or two small areas, was covered with epithelium (Fig. 2, *b*).

June 11: The wound was entirely healed with firm resistant epithelium, which required no further dressing. Four applications of amidoazotoluol had been made. The grafts themselves had become much thickened and projected above the surrounding skin like little warts (Fig. 3, *a*). This condition disappeared, and the entire area assumed the normal level (Fig. 3, *b*).

Examination of this patient eight months later showed a firm, movable skin with normal sensation. There was still some pigmentation around the grafts, but this was less marked than at date of discharge.

Comments.—I was able to compare the rapidity of healing caused by scarlet red and amidoazotoluol. Following an extensive burn, there were two granulating wounds of about the same size. One was dressed with 8 per cent. scarlet red ointment and the other with 8 per cent. amidoazotoluol ointment. The healing in both was rapid, but the wound dressed with amidoazotoluol healed first. The character of the healing was practically the same.

The age of the patient seems to have little effect on the stimulating power of these ointments. The general health of

the patient is most important, and in some instances forced feeding, fresh air, and tonics must be resorted to.

It is interesting that a number of patients with exquisitely painful ulcers have remarked that there is less discomfort after dressing with these substances than after any other dressing, however bland.

In none of the cases have I noted the slightest irritation of the surrounding skin following the use of amidoazotoluol. Although this dressing can be used continuously without irritation, it is best to apply it for 48 hours and then alternate with some bland ointment for 24 hours.

Dressing with both substances causes excess of secretion for one or two applications, but there is marked drying out of the granulations in a short time.

The use of scarlet red and amidoazotoluol in blue ointment is advantageous in the treatment of syphilitic ulcers, and in addition constitutional treatment should always be employed.

In the treatment of second degree burns the ointment can be used immediately after the blisters have been cut away. In third degree burns it is best to wait until the granulations have started.

For a time after healing, the newly formed skin has a tendency to be dry and somewhat scaly, but this is easily overcome by the application of olive oil or vaseline.

I have not yet seen a wound break down which was healed by the use of scarlet red or amidoazotoluol, although some of the cases have been under observation for over two years.

A grayish membrane is often seen on the granulations after the application of scarlet red ointment. I have not observed this formation following the use of amidoazotoluol.

Thiersch and Reverdin grafts are sometimes tremendously thickened following early dressings with these substances, but this thickening disappears within a few weeks.

At times it is advantageous to apply either ointment directly to the wound and then expose to the sunlight and air.

Scarlet red and amidoazotoluol gauze is prepared by saturating gauze with a 4 per cent. or 8 per cent. alcoholic solution of the substances and then allowing it to dry.

The substances can be used as a dusting powder by the

addition of 4 per cent. to 8 per cent. strength to boric powder. I have also tried the full strength powder on a few wounds without irritation. The effect of the scarlet red and amidoazotoluol used in this way is very rapid drying out of the wound and the formation of a tough scab under which the healing takes place.

A simple and satisfactory method of preparing scarlet red and amidoazotoluol ointment is to rub up the substance with a small amount of almond oil until the mass is smooth, and then mix this mass thoroughly with the base.

Both these ointments can be sterilized without interfering with their stimulating properties.

As a rule there is no toxic effect either from scarlet red or amidoazotoluol. Gurb ski¹⁹ reports the only case in which any general toxic effect was noted, as follows:

A child, eleven years old, was severely burned by an explosion of turpentine. The lower two-thirds of the thigh and the entire leg to the ankle were involved. After the granulations had formed Gurb ski applied 8 per cent. amidoazotoluol ointment. Fifteen hours after the application the patient, who had previously been in very good health, began to complain of headache and dizziness. This was followed by violent vomiting and gastralgia. The pulse rose to 110 and was of low tension. The temperature rose to 102.38. There were cyanosis of the lips and albumin in the urine.

The dressing was removed and the patient placed on a milk diet. In a few hours all of these phenomena disappeared. Eight days later amidoazotoluol ointment was again applied and the same symptoms reappeared with the exception of the albuminuria. A third dressing five days later caused the same symptoms except that the vomiting was less marked.

During the rest of the treatment he applied the ointment to only one-fourth of the wound at a time, and the toxic symptoms did not again occur. Rapid healing followed.

Gurb ski¹⁹ thinks the poisoning was due to the amido group in the amidoazotoluol.

I have dressed very large granulating areas for some time with these substances without any deleterious effect.

In this connection an observation by Stoeber is of interest. He says that it is not uncommon to have bladder disturbances among the men who work in the manufacturing of dyes. This trouble is principally among the workmen occupied in the

manufacture of amido combinations of benzol and naphthalin, or in factories where these products are used. The disease is characterized by cyanosis, vertigo and weakness, strangury, and bloody urine. In addition to the above symptoms, in long continued handling of these dyestuffs, hemorrhages and tumor formations in the bladder are observed. None of these symptoms have been noted following the clinical use of scarlet red or amidoazotoluol, except as noted above.

The consensus of opinion is that there is no danger of producing malignant growths by the clinical use of these substances. My own experience has convinced me of this, and although occasionally there is an overgrowth of epithelium, this soon assumes the level and the appearance of the normal skin.

Some authors have gone so far as to state that by the use of scarlet red and amidoazotoluol the majority of skin grafting can be eliminated. This is too broad a statement, but there is no doubt that wounds can be healed by these compounds which could not otherwise be satisfactorily closed except by grafting.

Scarlet red and amidoazotoluol will not heal every wound, but in the majority of cases, when applied with the proper technic, they will cause epithelial stimulation in the edges of the most sluggish wounds, and give a rapid healing which is stable and resistant, and which has the macroscopic and microscopic appearance of the normal skin. There is no tendency to subsequent contraction, and the skin becomes movable on the underlying tissues in a reasonable time. Any one of these characteristics would make the use of these substances well worth trying.

BIBLIOGRAPHY.

- ¹Auerbach: Ueber den Therapeutischen wert der Scharlachsälbe bei Haut und Geschlechtskrankheiten, *Klin. therapeutische Wochenschr.*, Nr. 14, 1909, p. 594.
- ²Beyer: Discussion of Grossmann's paper, *Deutsche. med. Wochenschr.*, Nr. 13, April 21, 1910, p. 777.
- ³Borst: Atypische Epithelwucherungen, *Deutsche. med. Wochenschr.*, Nr. 34, August 25, 1910, p. 1586.
- ⁴Brühl: Discussion of Grossmann's paper, *Deutsche. med. Wochenschr.*, Nr. 13, April 21, 1910, p. 777.

- ⁸ Cernuzzi: Dell'influenza Eccitatrice avolta dallo Scarlatto R (Michaelis), sulla Rigenerazione dell'Epitelio Cutaneo, Gazzetta degli Ospedali e delle Cliniche, No. 14, February 2, 1909, p. 145.
- ⁹ Cone: Zur Kenntniss der Zellveränderungen in der normalen und pathologischen Epidermis des Menschen. Franzfurter Zeitschrift f. Pathologie, vol. i, 1907, p. 37.
- ¹⁰ Cords: Experimentelle und klinische Erfahrungen über die Wirkungsweise des Scharlachrot bei Hornhautrekrankungen, Klin. Monatsbl. f. Augenheilkunde, January, 1910, p. 1.
- ¹¹ Dauthuille: Epidermisation rapide d'une vaste escarre gangreneuse de la face antero-externe de la cuisse gauche par des applications de Scharlachrot: Action remarquable de cette substance colorante sur les plaies atones, Nord. med. Lille, 1909, xvi, p. 169.
- ¹² Dixon: Proliferations of the Epithelium Induced by Soudan III, Scharlach Roth, and Paraffin; and the Effects of Röntgen Irradiation on the Same, Jour. Infectious Diseases, vol. vi, No. 2, April 1, 1908, p. 205.
- ¹³ Dreiffuss: Behandlung granulirender Wundflächen 8 per cent. Scharlachrotsalbe, Deutsche. med. Wochenschr., Nr. 1, January 6, 1910, p. 52.
- ¹⁴ Ducros: Ueber die behandlung granulirender Wunden mit Scharlachrot., Deutsche. med. Wochenschr., Nr. 29, July 22, 1909, p. 1294.
- ¹⁵ Enderlen: Empfehlung der Scharlachrotsalbe sur Beschleunigung der epithelisierung granulirender Flächen., Würzburger Aerzteabend., February 20, 1908; Münch. med. Wochenschr., Nr. 39, September 29, 1908, p. 2066.
- ¹⁶ Enroth: Epithelization of Granular Tumors by Scarlet Red, Finska lak.-sällsk. handl. Helisingfors, 1909, ii, v. 2, p. 217.
- ¹⁷ Fischer: Die experimentelle erzeugung atypischer Epithelwucherungen und die entstehung. bosartiger Geschwülste, Münch. med. Wochenschr., Nr. 42, October 16, 1906, p. 2041.
- ¹⁸ Geipel: Artefiziell erzeugten Geschwülsten, Münch. med. Wochenschr., Nr. 21, May 21, 1907, p. 1057.
- ¹⁹ Gottheil: Scarlet Red, Pro. Med., vol. xii, No. 3, September, 1910, p. 131.
- ²⁰ Grimani: Studio Sperimentale sulle Proliferazioni dell'epitelio Cutaneo., Rivista Veneta di Scienze Mediche, T. 50, April 15, 1909, p. 289.
- ²¹ Grossmann: Erfahrungen über die Anwendung der Scharlach-R-Salbe (Schmieden), der Scharlachsalsbe (Hayward), und der Amidoazotoluolgaze (Epidermolgaze), in der Ohrenheilkunde, Deutsche. med. Wochenschr., Nr. 16, April 21, 1910, p. 777.
- ²² Gurbiski: Beitrag. zur giftigen Wirkung der Scharlachsalsbe, Zentralbl. f. Chir., Nr. 49, December 3, 1910, p. 1550.
- ²³ Halle: Discussion of Grossmann's paper, Deutsche. med. Wochenschr., Nr. 13, April 21, 1910, p. 777.
- ²⁴ Hartmann: *Ibid.*
- ²⁵ Hayward: Weitere klinische Erfahrungen über die Anwendung der Scharlachfarbstoffe und Komponenten zur beschleunigten epithelialisierung granulirender Flächen., Münch. med. Wochenschr., Nr. 36, September 7, 1909, p. 1836.

- ²² Helmholtz: Experimental Epithelial Proliferations of Skin and Mucous Membranes, Johns Hopkins Hospital Bulletin, September, 1907, p. 365.
- ²³ Hertzler: The Etiology of Epithelioma; a Laboratory and Clinical Study, Jour. Amer. Med. Assoc., February 8, 1908, p. 425. The Etiology of Epithelioma, Jour. Amer. Med. Assoc., Dec. 31, 1910, 2290.
- ²⁴ Hermann: Scharlachrot bei Trommelfellperforationen, Deutsche. med. Wochenschr., Nr. 22, June 3, 1909, p. 977.
- ²⁵ Hübner: Aertzlicher Verein zu Marburg, December 16, 1908; Münch. med. Wochenschr., Nr. 8, February 23, 1909, p. 424.
- ²⁶ Jores: Ueber art und Zustandekommen der von B. Fischer Mittels scharlachöl erzeugten Epithelwucherungen, Münch. med. Wochenschr., Nr. 18, April 30, 1907, p. 879.
- ²⁷ Kaehler: Epithelisierung von Wundflächen unter Scharlachsälbe (Nack Fischer-Schmieden), Med. Klin., Nr. 22, May 31, 1908, p. 836.
- ²⁸ Katz: Ueber die behandlung granulirender Wunden mit Amidoazotoluolsälbe, Deutsche. med. Wochenschr., Nr. 36, September 8, 1910, p. 1665.
- ²⁹ Krajca: Zur epithelisierung granulirender Flächen durch Scharlachrot-sälbe, Münch. med. Wochenschr., Nr. 38, September 22, 1908, p. 1962.
- ³⁰ Levy: Discussion of Grossmann's paper, Deutsche. med. Wochenschr., Nr. 13, April 21, 1910, p. 777.
- ³¹ McConnell: The Experimental Production of Epithelial Proliferation, Jour. Amer. Med. Assoc., November 2, 1907, p. 1498.
- ³² Meyer: Experimentelle Epithelwucherungen. Ziegler's Beitrage z. pathologischen Anatomie und Allgemeinen Pathologie, B. 46, H. 3, 1909; Münch. med. Wochenschr., Nr. 8, March 8, 1910, p. 538.
- ³³ Michealis: Quoted by Reinhardt, Biebricher Scharlach R., Apotheker-Zeitung, Nr. 10, February 3, 1909, p. 90.
- ³⁴ Morawetz: Erfahrungen über die behandlung granulirender Wundflächen mit Scharlachrotsälbe, Therapeutische Monatshefte, Bd. 23, September, 1909, p. 479.
- ³⁵ Nietzki: Chemie der Organische Farbstoffe, 1901.
- ³⁶ Pein: Ueber die Behandlung des ulcus cruris mit Scharlachrot., Die Therapie der Gegenwart, March, 1910, p. 121.
- ³⁷ Pleth and Pleth: The Use of Fluorescent Salts (Eosin, Scarlet Red, etc.) in the Practice of Surgery, Amer. Jour. Surg., May, 1909, p. 162.
- ³⁸ Rammstedt and Jacobsthal: Ueber Schädigungen der Haut durch Röntgenstrahlen, Fortschritte auf den Gebiete der Röntgenstrahlen, B. 14, 1909-1910, p. 14.
- ³⁹ Rebaudi: Intorno alle utili Applicazioni Therapeutische dello Scharlachrot, La Ginecologia Moderna, April, 1909, p. 217.
- ⁴⁰ Reinhardt: Biebricher Scharlach R., Apotheker-Zeitung, Nr. 10, February 3, 1909, p. 90.
- ⁴¹ Ritter: Atypische Epithelwucherungen die durch Injection von Scharlachöl am Kaninchenohr Hervoggerufen sind, Münch. med. Wochenschr., Nr. 11, March 12, 1907, p. 542.
- ⁴² Scharezki: Zur Frage von der Bedeckung von Hautdefkten (Russki Wartsch, Nr. 21, 1910). Zentralbl. f. Chir., Nr. 32, August 6, 1910, p. 1061.

- “ Schmieden: Epithelwachstum unter Einwirkung von Scharlach R., *Zentralbl. f. Chir.*, Nr. 6, February 8, 1908, p. 153.
- “ Schreiber und Wengler: Ueber Wirkungen des Scharlachöls auf die Netzhaut mitosenbildung der Ganglienzellen, *Münch. med. Wochenschr.*, Nr. 35, September 1, 1908, p. 1854. Also, *V. Graefes Arch. f. Ophthalmologie*, Leipsic, 74, January, 1910, p. 1.
- “ Schultz and Julius: (Green.) A Systematic Survey of the Organic Coloring Matters, 1904.
- “ Seckel: Ueber experimentell erzeugte atypische Epithelwucherungen, *Münch. med. Wochenschr.*, Nr. 4, January 28, 1908, p. 199.
- “ Simin: Das Scharlachrot als ein Epithelisation ver stärkendes Mittel., *Zentralbl. f. Chir.*, Nr. 52, December 24, 1910, p. 1641.
- “ Snow: An Attempt to Produce an Atypical Epithelial Growth by Injection of Scharlach R. in Olive Oil, *Jour. Infectious Diseases*, vol. iv, No. 3, June 1, 1907, p. 385.
- “ Sonntag: Discussion of Grossmann's paper, *Deutsche. med. Wochenschr.*, Nr. 13, April 21, 1910, p. 777.
- “ Sprecher: Sul Valore Terapeutico del Scharlachrot, *Gazzetta degli Ospedali e delle Cliniche.*, xxx, No. 28, March 7, 1909, p. 289. Also, *Klin. therapeutische. Wochenschr.*, Nr. 13, March 29, 1909, p. 325.
- “ Stahr: Atypische Epithelwucherungen und Karzinom., *Münch. med. Wochenschr.*, Nr. 24, June 11, 1907, p. 1178.
- “ Stein: Ueber die Verwendbarkeit der Scharlachrotsalbe bei Ohrenerkrankungen, *Monatschrift f. Ohrenheilkunde und Laryngo-Rhinologie*, xlv, 2 Heft., 1910, p. 214.
- “ Stoeber: Experimentelle Untersuchungen über die erzeugung atypischer Epithelwucherungen, *Münch. med. Wochenschr.*, Nr. 3, January 19, 1909, p. 129. Die erzeugung atypischer Epithelwucherungen durch Injektion von Scharlachrot und Amidoazotoluöl in das subkutane Gewebe des Menschen., *Münch. med. Wochenschr.*, Nr. 14, April 5, 1910, p. 739.
- “ Strauss: Beitrag zur Kenntnis der Wirkung des Scharlach R. auf das Epithelwachstum., *Deutsche. med. Wochenschr.*, Nr. 19, May 12, 1910, p. 895. Pansements des Plaies avec la solution de la Pommade Rouge R., *Archives Gènerales de Chir.*, T. vi, August 25, 1910, p. 810.
- “ Werner: Ueber den Einfluss des Scharlachrottes auf Mäusentumoren, *Münch. med. Wochenschr.*, Nr. 44, November 3, 1908, p. 2267.
- “ Wessley: Ueber die Wirkung des Scharlachrotöls auf die menschliche Epidermis (Selbstversuch), *Med. Klin.*, Nr. 14, April 3, 1910, p. 542.
- “ Wolfrum und Cords: Ueber die Anwendung von Scarlachrot bei Augenaffectationen, *Münch. med. Wochenschr.*, Nr. 5, February 2, 1909, p. 242.
- “ Wyss: Zur Wirkungsweise der scharlachöl Injectionen B. Fischer's Bei der erzeugung karzinomänlicher Epithelwucherungen, *Münch. med. Wochenschr.*, Nr. 32, August 6, 1907, p. 1576.