

CAVERNOUS ANGIOMA OF THE SPLEEN *

By CHARLES N. DOWD, M.D.

OF NEW YORK

SURGEON TO THE ROOSEVELT HOSPITAL

THE surgery of the spleen has been developed largely in the effort to modify certain complex diseases in which splenic inflammation or splenic enlargement is believed to be a factor; hence the great majority of splenectomies in recent years have been done for splenic anæmia.

There is, however, a very distinct literature on splenic cysts, splenic angiomas and splenic sarcomas. The borders of these three divisions are not definite, for some splenic angiomas have ruptured so as to form blood cysts and have been described under that heading, and others have undergone such changes as to be classified under sarcomas.

Powers,¹ Huntington,² Johnston,³ and Musser⁴ made valuable contributions to the subject, 1906-1911.

In 1913, Fowler⁵ published an exhaustive study of cysts of the spleen. He follows the generally accepted classification into dermoid, parasitic and non-parasitic cysts. He confines his study mainly to the non-parasitic variety, of which he analyzes 82 cases, all that he could find recorded either from autopsies or from surgical clinics. In this entire series, only 2 were regarded as due to angiomas. This indicates the extreme rarity of cysts due to angiomas.

If we look for records of non-cystic angiomas we still find them very uncommon. Only 10 such records have been found which could fairly be included in the accompanying table.

Case Report.—The patient who forms the basis of this report was operated upon several years ago. The report was not then published as it was hoped that other similar cases would be observed. The extreme rarity of the condition, however, makes this unlikely, and, hence, it is offered as one member in the group of papers on the surgery of the spleen, which has been arranged for this meeting.

The patient, a well-nourished woman of thirty-seven, was admitted to the General Memorial Hospital, March 27. Her family and personal history had been negative excepting that 4 years previously a tumor had been removed from her neck, apparently a thyroglossal cyst. She had borne three children.

For six months she had suffered from pain in the splenic region. During a period of a week, two months ago, she had

* Read before the American Surgical Association, June 9, 1915.

suffered from repeated attacks of vomiting and epigastric pain, no blood in vomitus or stools. Three weeks ago she had noticed a lump in splenic region which had steadily increased in size. On admission to the hospital it had reached the proportions shown in Fig. 1.

Its margin was round, its consistency firm and it moved with respiration. There was no clinical evidence of abnormality in other organs.

Operation (April 1).—The mass was found to be a greatly enlarged spleen which was removed. It was adherent to the surrounding tissues and contained about 3 pints of blood in the parenchyma of its upper end. The so-called blood cyst thus formed was ruptured in removing the organ. There was no lining membrane in the resulting cavity.

The appearance of the specimen after shrinkage and hardening is indicated in Fig. 2.

Microscopical examination was made by Dr. William C. Clarke of Columbia University. Sections were examined from various parts of the organ. The spleen tissue had been practically replaced by a cavernous angioma.

Pathological Report (by Dr. Wm. C. Clarke).—Spleen measures $20 \times 12 \times 7$ cm. In the larger end there is a blood distended cavity measuring 10 cm. in diameter. This produces a bulging rounded mass that projects evenly at the upper end of the spleen. The spleen surface is slightly lobulated and wrinkled throughout. There are two notches on the border. In the cut surface there are seen many hemorrhages in the splenic pulp. Adjacent to the larger cyst there is a single large hemorrhagic area 4 cm. in diameter. Microscopical examination of the spleen shows there are very many blood spaces of large size through the specimen. Between the large vessels are countless small ones. In the stroma there are free red blood-cells, showing that there have been blood extravasations. The stroma itself is scanty between many of the vessels and elsewhere it is exceedingly dense and cellular. In none of the sections examined is it possible to find any true splenic tissue intact; at points there are small aggregations of round cells suggesting lymphoid tissue.

To conclude, the bulk of the spleen is made up of blood-vessels and stroma to which is added extravasated blood.

Diagnosis: "Cavernous angioma of the spleen."

Figs. 3 and 4 indicate the appearance of the microscopical specimens.

At the operation many small, dark, cyst-like spots were noticed on the under surface of the liver; they were about $\frac{1}{4}$ inch in diameter, dark blue in color and appeared to contain small amounts of fluid. They were not elevated above the surface of the liver.

The subsequent history of the patient is most noteworthy and shows the sad possibilities of this type of tumor.

Her immediate recovery from the operation was satisfactory,

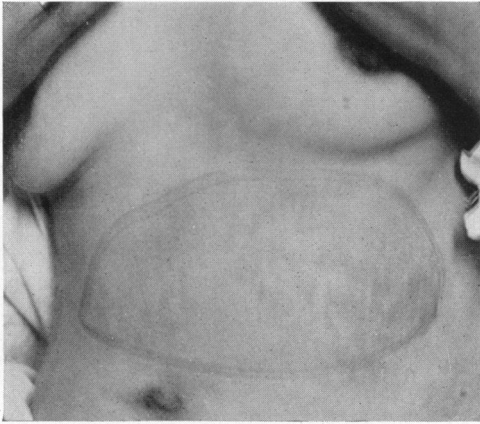


FIG. 1.—Showing outline of tumor as palpated through abdominal wall.

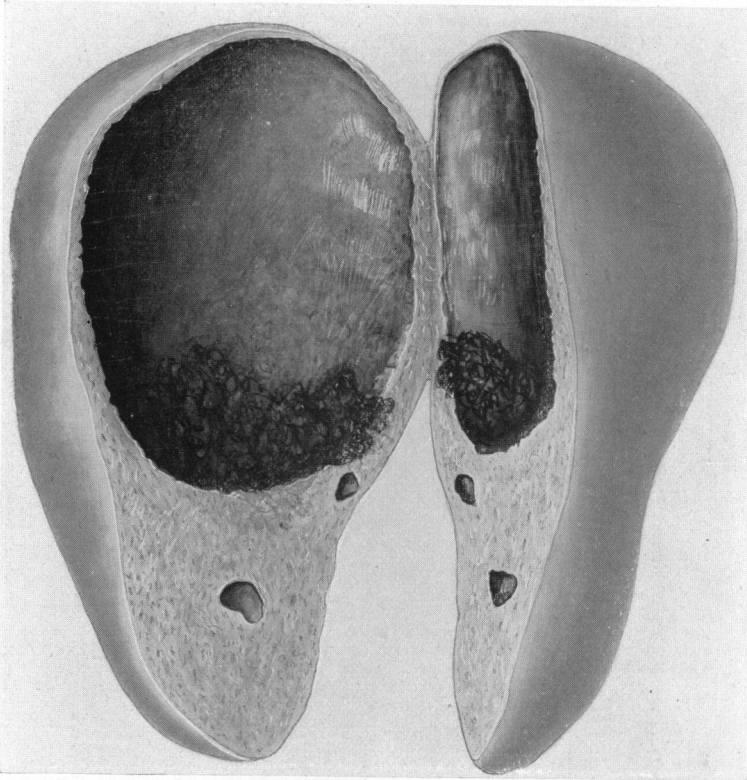


FIG. 2.—Drawing of spleen after shrinking and hardening. The splenic tissue was almost entirely replaced by cavernous angioma.

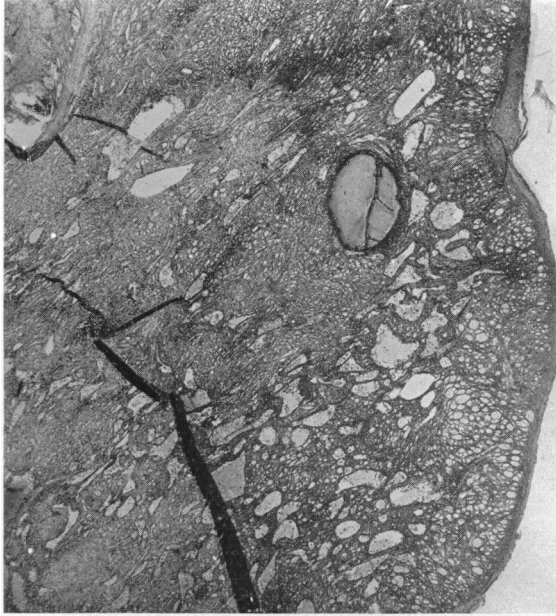

FIG. 3.—Microphotograph of cavernous angioma of spleen (low power).

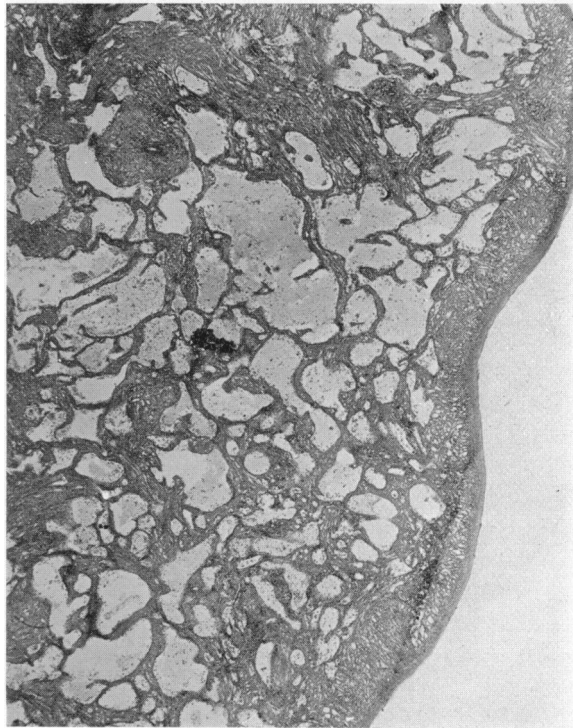

FIG. 4.—Microphotograph of cavernous angioma of spleen (high power).

CAVERNOUS ANGIOMA OF THE SPLEEN

and on the twelfth day she was permitted to sit up. On the evening of the thirteenth day she had an attack of pain in the epigastrium and right hypochondrium and felt faint. The liver was enlarged and over it there was fremitus on respiration. It was believed that she had suffered a liver hemorrhage similar to that which had previously occurred in the spleen. She was kept in bed, horse serum was injected and she improved steadily for about a week, when the symptoms were repeated; and they came on again two weeks later. By May, her condition had become alarming: her pallor was extreme, she had moderate jaundice, and was very weak. Her red blood-corpuscles numbered only 699,200 per cubic millimetre and her hæmoglobin was only 25 per cent. of the normal. Transfusion was done and the hæmoglobin percentage raised to 40 per cent. This was followed by improvement, but by May 20, her people were discouraged and took her home where she died during the following month.

Before she left the hospital, there were signs of fluid in the lower part of the right side of the chest and bloody fluid was obtained by aspiration. The liver also showed much enlargement. It could be felt within one inch of the umbilicus. Ecchymotic discoloration also appeared about the site of the incision.

The following 15 blood examinations are recorded by members of the house staff, April 2 to May 20.

	Hæmo- glo- bin per- cent- age	Red blood- cells per cubic millimetre	White blood- cells per cubic milli- metre	Poly- morpho- nuclears and transi- tionals	Eosino- philes	Baço- philes	Large lym- pho- cytes	Small lym- pho- cytes
April 2	70	4,448,000	30,600	88.3	5	6	3.7	1.5
April 3	70	28,000	88	0	0	7	5
April 4	70	4,960,000	17,600	87	0	0	9	4
April 5	70	4,572,000	9,200	74	3	0	7	16
April 6	70	4,375,000	10,200	73	2	0	6	19
April 7	65	3,325,000	14,130	73	1	0	6	20
April 10	60	2,756,000	14,180	76	1	0	5	18
April 14	70	3,280,000	13,500
April 21	55	3,232,000	17,860	83	..	2	7	11
April 28	45	1,136,000	25,000	91	0	0	8	1
May 6	25	699,200	22,230	91	0	0	2	7
May 10	40
May 12	40	1,904,000	22,800	86	0	0	5	9
May 13	35
May 20	35	864,000	23,600	88	0	0	2	10

It is noticed that her anæmia became progressively worse and that she had a decided leucocytosis.

The main interest in this record centres in the growth which led to these overwhelming symptoms. Cavernous angiomas of the spleen with metastasis in the liver are very uncommon.

Jores,⁶ in describing such a case in 1908, states that he is able to find records of only two other cases, those of Langhans and Theile.

In searching the literature, we have included in the accompanying table those cases which seem to bear directly on the subject. Some of the autopsy cases, however, showed very slight lesions. It is possible that under different headings records of other important cases exist; but this table is the result of many hours of search in the library of the Academy of Medicine by Dr. Charles E. Farr, and two weeks of continuous work there by Mr. Charles W. Lester.

The case of Langhans,⁷ which was recorded in 1875 and which has been very extensively quoted through the intervening years, is almost the counterpart of the one here recorded. A robust acrobat aged thirty had a sudden pain in the splenic region and developed a pulsating angioma which involved nine-tenths of the splenic tissue and reached a size of $23 \times 15 \times 10.5$ centimetres. This was accompanied by metastasis of a similar nature in the liver which reached 3 or 4 times its normal size. He died after $4\frac{1}{4}$ months from exhaustion and suffocation.

Jores' case was also similar, a woman of forty-five who had a cavernous angioma of the spleen with liver metastasis. Death after 11 months from dropsy and cardiac weakness.

In Homan's case, it was believed that the omentum was also involved.

In Ernst's case, a child of $1\frac{1}{4}$ years, the liver was more involved in the angioma than the spleen, and there were 85 angiomatous spots in the skin.

In Theile's case the liver, stomach and lungs were involved.

Thus we see that in 6 of the 13 cases the spleen was not the only organ involved in the angiomatous growth.

Three of the remaining cases (Martin, v. Benkendorf and Anzilotti) recovered from their splenectomies and it is uncertain whether they had involvement of other organs.

The other 4 cases (Albrecht, Theile and Lubarsch) were reported from autopsies. The angiomas were small, no history of symptoms is given and there is no mention of angioma in other organs in 3 of the cases; the 4th died from perforation of the gall-bladder. They are included in the tables as minor grades of spleen angioma.

Histogenesis.—In connection with the published reports much has been written about the histogenesis of these growths. If we follow Moschcowitz,⁸ who made an analogous study of cysts of the liver, we

TABULATION OF CASES WITH CAVERNOUS ANGIOMA OF THE SPLEEN PREPARED BY CHAS. W. LESTER

No.	Observer	Recorded	Sex	Age	Duration	Symptoms	Operation	Result	Pathology	Involvement of other organs
1	Langhans.....	Virchow's Archiv, Bd. 75, p. 273	M	30	2 1/2 mo...	Sudden pain, left side, region of ninth and tenth thoracic vertebrae. Swelling in left hypochondrium and epigastrium. Tumor evident on palpation. Pulsation and murmur	None.....	Tumor grew. Patient died two months after admission	Spleen enormously enlarged. 23x15x10.5 cm. Adhesions to diaphragm. Reddish-brown color. Cross-section—narrow periphery 1-5 cm. thick. Remainder cavernous with clots. Tissue of periphery somewhat like normal; no trabeculae or follicles. Cavernous part tough, coarse-grained substance extending along walls and into cavern	Liver involved. Enlarged 3-4 times, 30x30x18 cm. Soft, tough, contained numerous reddish-yellow knots. Cross-section showed substance to be filled with such knots—some containing clots. Knots measure 1-2 cm. in diameter.
2	Martin.....	Revue de Gyn. et de Chirurgie Abd., 1909, p. 67	F	..	Not reported	Pain in left hypochondrium. Loss of weight. Constipation. Tumor felt, supposed to be in spleen	Paramedian laparotomy and splenectomy	Cured. Discharged 2 months after admission	Spleen: Surface studded with violet-gray spots. Smallest size 2 fr. piece. Cross-section showed spongy, compact and intermediate areas. Structure: compact area normal. Spongy, cavernous—mixture of Malpighian corpuscles and pulp. Trabeculae of dense connective tissue. Microscopically: compact: slight connective tissue thickening, collections of red corpuscles. Intermediate: Venous sinuses enlarged. Central artery sclerotic. Lesion characterized by transition of splenic substance to cavernous. Filled with clots	None reported.
3	Homans.....	ANNALS OF SURGERY, 1897, vol. xxv, p. 732	F	22	1 year....	Swelling in abdomen. Very anemic. Pulse 142. No pain. Tumor on right side which later disappeared, also row of small lumps extending across abdomen. Abdomen tapped 5 times for ascitic fluid	First, laparotomy with removal of tumor in great omentum, ovaries, supernumerary spleen and much fluid. Second, splenectomy	First, recovered and showed temporary improvement. But ascitic fluid returned. Second, died in 20 hours from shock	First operation: Small supernumerary spleen. Second: Spleen. Weight 415 gms.; size 75x11x3 cm. Numerous slightly elevated purplish areas on surface separated by splenic pulp. Areas were cavernous structures filled with blood and coagulated serum. Walls of thin connective tissue with endothelial lining. Diagnosis: Cavernous angioma	Great omentum: Tumor 10x3 cm., spongy, and fibrous fluid and clotted blood in cavities. Cavities pea-sized and smaller and communicating. Poor in nuclei; spindle-shaped when present. Ovaries: Numerous retention cysts, hemorrhagic contents. Diagnosis: Cavernous angioma. No autopsy.
4	Jores.....	Centr. f. Allg. Path. und Path. Anat., 1909, vol. 19, p. 662	F	45	11 months	Tumor in spleen noticed December, 1906; in liver, Spring, 1907. Died November, 1907	None.....	Died from dropsy and cardiac weakness	Spleen: Greatly enlarged, 31x15x16 cm.; weight 3.6 kg. Numerous protuberances on surface, slightly elevated. Little normal tissue visible on cross-section. Inside: structureless mass. Clot at one pole. Microscopically: Spleen necrotic, firm at border. Strands given off to interior containing red blood-corpuscles in their meshes. Structure that of cavernous angioma	Liver involved. Much enlarged, 38x35x15 cm.; weight 8.60 kg. Knots size of apple extending into interior and containing blood. Centre of knots showed diffuse hemorrhage, many blood-vessels at periphery. Knots were metastases.
5	Ernst.....	Verhand. d. deutschen Path. Gesellschaft, 1912, p. 232	M	1	Congenital	85 angiomatous spots on body. Died at age of 1 yr. 3 mo.	None.....	Died, asthmatic dyspnea	Spleen: Involved secondarily. Angiomatous spots similar to those in liver but not so large or numerous	Skin: 85 angiomatous spots. Liver: filled with cherry-sized knots constructed from capillaries as in angioma simplex. Size 5-7 or 8 mm. in diameter. Liver, stomach and lungs involved. Liver: spots similar to dark-colored tumors of spleen. Other spots of spindle-cell formation. Lungs: Have tumorous spots filled with blood similar to those in liver. Stomach: Small submucous sarcomatous and angiomatous tumors.
6	Theile.....	Virch. Arch., Bd. 178, p. 296	M	56	6 months	Weakness in joints. Pressure and swelling in abdomen. No pain. Tumor felt in spleen. Blood examination: Hyperleucocytosis (1: 350)	Splenectomy....	Died, result of internal hemorrhage from small vessels day after operation	Spleen: Enlarged in all dimensions. Numerous round cavernous knots filled with blood under capsule. Knots of light and dark color. Light: elastic tissue enclosing spaces with very little blood. Dark: closely packed blood-vessels containing blood and thrombus. Spindle-cell strands in tumor. Diagnosis: Cavernous angioma	Liver, stomach and lungs involved. Liver: spots similar to dark-colored tumors of spleen. Other spots of spindle-cell formation. Lungs: Have tumorous spots filled with blood similar to those in liver. Stomach: Small submucous sarcomatous and angiomatous tumors.
7	Albrecht.....	Zeitschrift für Heilkunde, 3, 1902, p. 97	M	65	Autopsy report: Symptoms not given	None.....	Spleen: Much enlarged. Normal shape. About 6 cavernous knots, bean- and pea-sized. Contain blood. Hyperplasia of pulp cells. Radiating fissures connecting arteries, blood spaces, caverns and veins. Malpighian corpuscles around cavernous blood spaces	None.
8	Theile.....	Virch. Arch., Bd. 178, p. 296	M	22	Autopsy report by Lubarsch, S. No. 77, 1900	Spleen: Slightly enlarged, soft cherry-sized spots. Tumor sharply marked off. Numerous capillaries in periphery, endothelium swollen. Contain blood and thrombus. Spindle-cells between blood spaces: Centre cavernous, contains thrombus. Diagnosis: Obliterating angioma	None.
9	Theile.....	Virch. Arch., Bd. 178, p. 296	M	36	Autopsy report by Lubarsch, S. 123, 1901	Spleen: Enlarged 14x7 1/2x3 cm. Two firm reddish tumors, cherry-sized, at lower pole. Larger, similar to preceding case. Other composed of large and small freely-anastomosing blood spaces; mostly capillaries, some veins. Contain some thrombus. Diagnosis: Obliterating angioma	None. Gastric ulcer present.

TABULATION OF CASES WITH CAVERNOUS ANGIOMA OF THE SPLEEN. PREPARED BY CHAS. W. LESTER.—Continued

No.	Observer	Reported	Sex	Age	Duration	Symptoms	Operation	Result	Pathology	Involvement of other organs
10	Theile.....	Virch. Archiv, Bd. 178, p. 296	M	62	Autopsy report by Lubarsch, S. 75, 1903	<i>Spleen:</i> Normal size. Greenish protuberances on surface. Firm dark red protuberance at upper pole, bean-sized. Smaller knot inside spleen. Several knots at lower pole. Tumors have same appearance as in preceding cases but richer in thrombus and spindle-cells. Diagnosis: Obliterating angioma	None. Cysts in kidney and oesophagus.
11	v. Benkendorf..	Virch. Archiv, Bd. 194, p. 500	M	53	2 years...	Abdominal swelling. Tumor felt	Splenectomy....	Not reported.....	<i>Spleen:</i> Large cavernous area replacing three-fourths normal tissue. Sharply marked off from normal tissue. Sharply marked off from normal tissue. Venous capillaries enlarged, lengthened and walls thinned. Pulp between capillaries compressed and contains follicles and trabeculae. Cavern contains lymphocytes, pulp cells, red blood-cells and colloidal substance	None.
12	Anzilotti.....	Lo Spermantale, Archivio de Biologia, Suppl. vol. 67, 1913, p. 161	F	38	14 months	Severe epigastric pains not related to meals often terminating in vomiting. Blood examination: reds 4,580,000, whites 4700, hemoglobin 100 per cent., few platelets. Urine negative as to abnormalities. Leucocytosis followed operation lasting 45 days. Increase in platelets	Splenectomy....	Recovered.....	<i>Spleen:</i> Weight 1 kg. Several elevations on surface size of walnut, cyanotic color. In part cyst-like communicating structures lined with endothelium. Elastic fibres present. Were filled with fluid, blood clots, fibrin, or hyalin masses. Blood spaces dilated; pulp atrophic. Other localities showed transition into lymph tracts. Cross-section showed numerous angiomas giving cavernous structure. Malpighian corpuscles altered; trabeculae thickened	None.
13	Dowd.....	F	37	6 months	Pain in splenic region. Vomiting and epigastric pain. Lump noticed in splenic region, increasing in size	Splenectomy....	Died 2½ months later from hemorrhages in angioma of liver	<i>Spleen:</i> Measured 20×12×7 cm. Blood-distended cavity 10 cm. in diameter at larger end. Two notches on border. In cut surface many hemorrhages in splenic pulp. Adjacent to larger cyst is single hemorrhagic area 4 cm. in diameter. Microscopical: Many large vessels with small ones between. Free blood-cells in stroma. Stroma scanty. Diagnosis: Angioma of the spleen.	

CAVERNOUS ANGIOMA OF THE SPLEEN

find that studies in histogenesis have conformed to one of three theories: (1) inflammation; (2) tumor formation; (3) maldevelopment.

The inflammation theory represents the work of the older pathologists and was developed before bacterial infection was considered as important as we now believe. Virchow, for instance, wrote of intra-uterine inflammation due to chemical irritation or mechanical obstruction. The painstaking description of the histological findings and the importance which is ascribed to blood-pressure and congestion and occlusion of vessels indicates a belief that some inflammatory change has been an element in the production of these growths. The writers, however, have been unable to give satisfactory evidence of such change.

As to the second, it is to be noticed that Jores found, in parts of his specimen, tissue resembling spindle-celled sarcoma, and hence used the term sarcomatous angioma.

Theile found in his case sarcomatous areas in the spleen, liver, lungs and stomach, and also used the terms angioma and sarcomatous angioma.

In most of the cases, however, there is no proof of sarcoma; the tumors are reported as angiomas and must be so regarded. They certainly have not shown the characteristics of malignant tumors.

If, however, we study the cases on the theory of maldevelopment, we have an explanation which at least is more plausible and more easily understood than either of the others. We are accustomed to observe congenital cutaneous and subcutaneous angiomas. Occasionally we find that they take on unexpected and even extensive growth; why they do so we do not know, but since the tissues themselves are abnormal, it does not seem very remarkable that their growth should be peculiar. We can better understand the existence of these angiomas on this basis than on any other which has been advanced.

REFERENCES

- ¹ Powers: Non-parasitic Cysts of Spleen. *ANNALS OF SURGERY*, vol. xliii, p. 48.
- ² Huntington, Thos. P.: *Transact. Am. Surg. Assn.*, 1907, vol. xxv, p. 366.
- ³ Johnston, Geo. Ben.: Splenectomy. *ANNALS OF SURGERY*, vol. xlviii, p. 50.
- ⁴ Musser, Jr., John H.: Cysts of the Spleen. *Am. Jour. Med. Sciences*, vol. cxlii, p. 501.
- ⁵ Fowler, Royale Hamilton: Cysts of the Spleen. A Pathological and Surgical Study. *ANNALS OF SURGERY*, vol. lvii, p. 658.
- ⁶ Jores: Ein Fall von sarkomatösen Angiom der Milz und Leber. *Cent. f. allg. Path. und Path. Anat.*, 1909, vol. xix, p. 662.
- ⁷ Langhans: Pulsirende Carvernöse Geschwulst der Milz mit metastatische Knoten in der Leber. *Virchow's Archives*, Bd. 75, p. 273.
- ⁸ Moschowitz, Eli: *American Journal of Medical Sciences*, vol. cxxxi, p. 675.